

# Lower limb malperfusion in type B aortic dissection: a systematic review

Mauro Gargiulo<sup>1</sup>, Claudio Bianchini Massoni<sup>1</sup>, Enrico Gallitto<sup>1</sup>, Antonio Freyrie<sup>1</sup>, Santi Trimarchi<sup>2</sup>, Gianluca Faggioli<sup>1</sup>, Andrea Stella<sup>1</sup>

<sup>1</sup>Vascular Surgery, Department of Experimental, Diagnostic and Specialty Medicine, University of Bologna, Policlinico Sant'Orsola-Malpighi, Bologna, Italy; <sup>2</sup>Vascular Surgery, Department of Cardiovascular Surgery, Thoracic Aortic Research Center, Policlinico San Donato I.R.C.C.S., University of Milan, Italy

Correspondence to: Mauro Gargiulo, MD. Vascular Surgery, University of Bologna, Policlinico Sant'Orsola-Malpighi, Via Massarenti, 9, 40138 Bologna, Italy. Email: mauro.gargiulo2@unibo.it.

**Background:** Lower limb malperfusion (LLM) syndrome occurs in up to 40% of complicated type B aortic dissections (TBAD) and in up to 71% of TBAD with malperfusion syndrome. This syndrome is associated with higher 30-day mortality. The aim of this systematic review was to provide clinical and procedural data of patients with LLM syndrome secondary to TBAD.

**Methods:** The PubMed database was systematically searched from January 2000 to June 2014 for English-language publications reporting on demographic data of patients with LLM secondary to TBAD.

**Results:** A total of 29 papers were included (10 original articles and 19 case reports), reporting on a total of 138 patients (mean age =58±12 years; male =87%). Lower limb complications developed in acute and chronic TBAD in 134 (97%) and 4 (3%) cases, respectively. LLM presented with acute limb ischemia in 120 (87%) patients. Bilateral clinical presentation occurred in 56% (40/72) of cases. LLM was the only clinically detected malperfusion in 52% of cases (44/84). In 40% (35/84) and 25% (21/84) of cases, LLM was clinically associated with renal and visceral malperfusion, respectively. Radiological imaging showed renal, celiac trunk and superior mesenteric artery involvement in 53% (47/88), 31% (27/88) and 34% (30/88) of cases, respectively. Medical, surgical and endovascular treatments were performed in 22 (16%), 51 (37%) and 65 (47%) patients, respectively. Thirty-day morbidity was 31% (13/42) and 46% (6/13) following surgical and endovascular treatment, respectively. Thirty-day mortality was 14% (5/36) and 8% (2/26) following surgical and endovascular treatment, respectively.

**Conclusions:** LLM syndrome secondary to TBAD usually developed during the acute phase and, in most cases, presented with acute limb ischemia. Bilateral clinical presentation occurred in more than half of cases. Renal and visceral malperfusion were frequently associated with lower limb flow reduction but LLM was the only clinically detected malperfusion in more than half of patients. Surgical fenestration was burdened with significant complication rates and 30-day mortality. Endovascular procedures showed lower mortality but complication rates remained high.

**Keywords:** Type B dissection; malperfusion; acute limb ischemia; lower extremity



Submitted Jul 17, 2014. Accepted for publication Jul 19, 2014.

doi: 10.3978/j.issn.2225-319X.2014.07.05

View this article at: <http://dx.doi.org/10.3978/j.issn.2225-319X.2014.07.05>

## Introduction

Type B aortic dissection (TBAD) is a life-threatening disease and its management remains challenging. TBAD is classified as acute ( $\leq 14$  days) or chronic ( $> 14$  days) (1)

according to the time taken for onset of symptoms. The development of complications, such as rupture, aneurysmatic dilatation or malperfusion syndrome, necessitates surgical or endovascular treatment.

**Table 1** Incidence of lower limb malperfusion secondary to type B aortic dissection in recent case series

First author	Year of publication	Study period	Classification of TBAD	Incidence of LLM in TBAD	Incidence of LLM in complicated TBAD	Incidence of LLM in TBAD with malperfusion
Szeto (3)	2008	February 2004-October 2007	Acute, complicated	–	34% (12/35)	71% (12/17)
Pearce (4)	2008	March 2005-November 2007	Acute, complicated	–	33% (5/15)	63% (5/8)
Patel (5)	2009	1997-2008	Acute, with malperfusion	–	–	38% (26/69)
Botsios (6)	2010	March 2001-January 2006	Acute, complicated	5% (3/59)	9% (3/32)	50% (3/6)
Steuer (7)	2010	December 1999-December 2009	Acute and chronic, complicated	–	15% (9/60)	–
Midulla (8)	2011	December 1999-November 2007	Acute, with malperfusion	5% (16/352)	–	–
White (2)	2011	2000-2008	Acute, complicated	–	40% (34/85)	56% (34/61)
Lombardi (9)	2012	December 2007-August 2009	Acute and chronic, complicated	–	38% (15/40)	56% (15/27)
Shu (10)	2013	July 2003-May 2012	Acute	8% (36/426)	–	28% (36/127)
Alsac (11)	2014	June 2011-June 2013	Acute, with malperfusion	12% (6/52)	–	40% (6/15)

LLM, lower limb malperfusion; TBAD, type B aortic dissection. Data expressed as % (fraction).

Malperfusion complications may involve renal, visceral, spinal cord and lower limb arterial circulations, inducing occlusion or thrombosis in branch arteries at high risk of end-organ ischemia. Lower limb malperfusion (LLM) is defined as abnormal pulse upon examination in conjunction with leg pain, pallor, paresthesia or paralysis (2). Recent case series (2-11) (*Table 1*) have reported development of LLM in 5-12% of type B dissections, in up to 40% of complicated TBAD and in up to 71% of dissections with malperfusion syndrome. The presence of LLM syndrome is statistically associated with higher in-hospital mortality (12).

The primary goal of treatment is to restore perfusion of the lower limbs as soon as possible. Extra-anatomic bypass grafting (femoro-femoral, axillo-femoral or axillo-bifemoral) or surgical fenestration represent the traditional treatment approaches. Since the 1990s, less invasive treatments employing an endovascular approach have been proposed. Occlusion of proximal entry tear with stentgraft and endovascular fenestration are two attractive options. Few studies have specifically analyzed lower limb ischemic complication because it is usually not discriminated from

ischemia of abdominal visceral districts.

The aim of this systematic review is to provide clinical and procedural data of patients with acute or chronic TBAD complicated by LLM or acute limb ischemia.

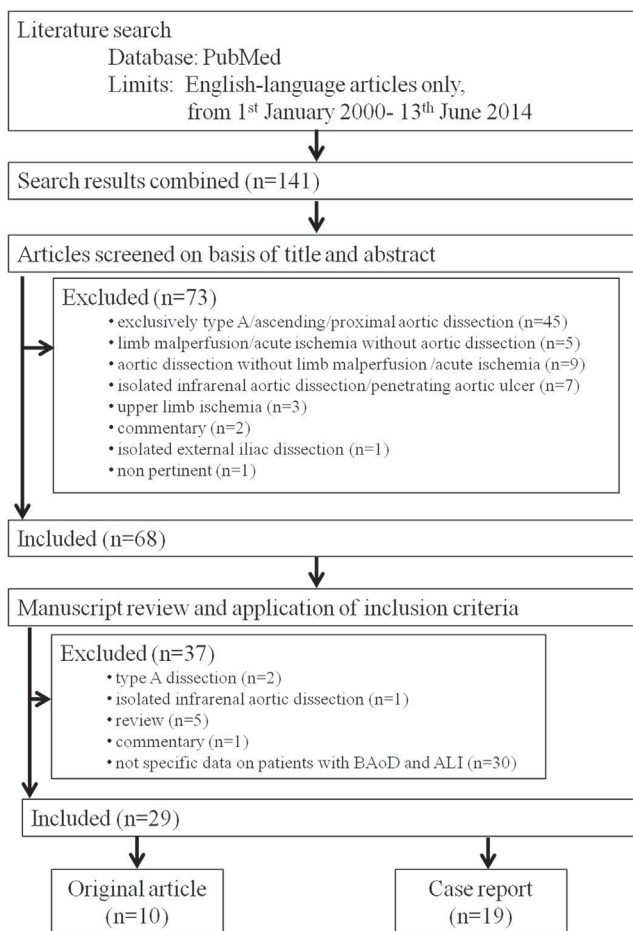
## Methods

### Search strategy

The PubMed database was systematically searched from 1<sup>st</sup> January 2000 to 13<sup>th</sup> June 2014 for English-language publications reporting on TBAD complicated by acute limb ischemia or LLM. Search terms were “acute limb ischemia and aortic dissection” or “limb malperfusion and aortic dissection”. The reference lists of retrieved articles were also scanned to further identify potentially relevant studies. The search method and results have been reported according to the PRISMA statement (13).

### Study selection

Inclusion criteria for study selection were the following: (I)



**Figure 1** Flow chart of study selection.

reporting on LLM and/or lower limb ischemia secondary to TBAD; (II) reporting on demographics of patients with LLM and/or lower limb ischemia. Studies that did not provide demographic data for patients were not included. Case reports were eligible for inclusion, while review and commentary articles were excluded. Articles reporting exclusively on type A, ascending, proximal dissection or isolated infrarenal abdominal aortic disease were also excluded.

Two reviewers (C.B.M. and E.G.) independently screened the title and abstract of records identified in the search. Full text publications were sought and retrieved for studies that the authors agreed to be potentially relevant. Disagreements about final study inclusion were resolved by consensus (i.e., discussion between reviewers).

## Data extraction

Data were extracted for the following: patient demographics (age, gender), etiology of dissection disease (hypertensive, traumatic, iatrogenic), classification of TBAD (acute:  $\leq 14$  days; chronic:  $>14$  days), symptoms and signs (malperfusion or acute limb ischemia; chest, back, abdominal or limb pain; weakness, numbness, paralysis or paresthesia of lower extremity; peripheral pulse deficit), clinical and radiological evidence of associated renal or mesenteric hypoperfusion, type of treatment (medical, surgical, endovascular), and post-operative outcomes (technical success, 30-day clinical success, morbidity, reintervention and mortality).

Treatment type was defined as the procedure performed to treat LLM and, for this reason, hybrid treatments (e.g., aortic stentgraft associated with femoro-femoral bypass graft) were classified as surgical procedures. Technical success was defined as a procedure completed without any intraoperative complication (e.g., thrombosis of bypass graft or accidental coverage of visceral vessel by stentgraft). Clinical success was defined as absence of clinical symptoms and signs of preoperative malperfusion/ischemia at discharge. Post-operative morbidity was defined as new onset of any procedure-related complication. Thirty-day outcomes refer to either the first 30 postoperative days or period of hospitalization. Data were independently extracted by two vascular surgeons (C.B.M. and E.G.) and any discrepancies were clarified through consensus.

## Results

### Search results

The study selection process is summarized in *Figure 1*. In total, 29 articles met the criteria for inclusion and their characteristics are displayed in *Table 2*. Of these, 10 (34%) were original articles and 19 (66%) case reports. Two original articles (26,42) only included patients with LLM syndrome secondary to TBAD. The other eight original articles (15,17,21,28,30,33,36,40) did not report exclusively on LLM syndrome, but separate data was provided for patients with LLM.

### Incidence

LLM occurred in 5.7-30% of all TBAD cases, representing 19-48% of all complicated type B dissections and 50-73% of all malperfusion complications (*Table 2*). Among patients

Table 2 Incidence of lower limb malperfusion and demographic characteristics of patients in included studies										
First author	Year	n	Study period	Publication type	Age <sup>#</sup> [years]	Male [%]	Etiology	Incidence of LLM in TBAD	Incidence of LLM in complicated TBAD	Incidence of LLM in TBAD with malperfusion
Joo (14)	2000	1	–	Case report	63	0	NS	–	–	–
Panneton (15)	2000	5	1979-1999	Retrospective	69 [51-81]	4 [80]	NS	NS	NS	NS
Lookstein (16)	2001	1	–	Case report	50	1 [100]	NS	–	–	–
Lauterbach (17)	2001	11	1990-1999	Retrospective	53 [35-76]	10 [91]	NS	NS	NS	50% (11/22)
Liu (18)	2002	1	–	Case report	42	1 [100]	NS	–	–	–
Frahm (19)	2002	1	–	Case report	75	1 [100]	NS	–	–	–
Eggebrecht (20)	2003	1	–	Case report	61	1 [100]	NS	–	–	–
Vedantham (21)	2003	7	1998-2002	Retrospective	47 [42-76]	7 [100]	NS	NS	NS	73% (8/11)
Fleck (22)	2004	1	–	Case report	63	1 [100]	Iatrogenic	–	–	–
Lorenzen (23)	2004	1	–	Case report	33	1 [100]	Traumatic	–	–	–
Tan (24)	2004	1	–	Case report	48	1 [100]	NS	–	–	–
Yamaghchi (25)	2006	1	–	Case report	53	1 [100]	NS	–	–	–
Henke (26) (IRAD data)*	2006	26	1996-2002	Retrospective and prospective	59±14	19 [73]	NS	5.7% (26/458)	NS	NS
Henke (26) (local series)*	2006	28	1997-2002	Retrospective	56±12	26 [93]	NS	30.1% (28/93)	NS	NS
Nakahira (27)	2007	2	–	Case report	73, 47	2 [100]	NS	–	–	–
Shiia (28)	2007	4	1991-2005	Retrospective	61 [51-87]	3 [75]	NS	NS	NS	57% (4/7)
Lakshmanan (29)	2008	1	–	Case report	83	1 [100]	NS	–	–	–
Verhoye (30)	2008	3	1996-2004	Retrospective	53 [46-62]	3 [100]	2 hypertension 1 trauma	NS	19% (3/16)	NS
Fujita (31)	2009	1	–	Case report	53	1 [100]	NS	–	–	–
Iyer (32)	2009	1	–	Case report	77	1 [100]	NS	–	–	–
Trimarchi (33)	2010	10	1988-2002	Retrospective	60 [50-82]	8 [80]	1 iatrogenic (AAA)	17.0% (10/60)	48% (10/21)	NS

Table 2 (continued)

Table 2 (continued)

First author	Year	n	Study period	Publication type	Age <sup>#</sup> [years]	Male [%]	Etiology	Incidence of LLM in TBAD	Incidence of LLM in complicated TBAD	Incidence of LLM in TBAD with malperfusion
Umeda (34)	2011	1	–	Case report (previous AAA graft)	56	1 [100]	NS	–	–	–
Vulev (35)	2011	1	–	Case report	25	1 [100]	NS	–	–	–
Sfyroereas (36)	2011	12	1998-2009	Retrospective	62 [46-77]	10 [83]	NS	14.0% (12/85)	NS	52% (12/23)
Lee (37)	2012	1	–	Case report	62	1 [100]	NS	–	–	–
Narita (38)	2012	1	–	Case report	54	1 [100]	NS	–	–	–
Kuo (39)	2013	1	–	Case report	58	1 [100]	NS	–	–	–
Ito (40)	2013	3	2006-2011	Retrospective	61 [61-74]	3 [100]	NS	75.0% (3/4)	NS	100% (3/3)
Kim (41)	2014	1	–	Case report	78	1 [100]	NS	–	–	–
Corfield (42)	2014	9	2002-2009	Retrospective and prospective	53 [40-78]	8 [89]	NS	NS	NS	NS
Overall	–	138	–	–	58±12	120 [87]	–	–	–	–

<sup>\*</sup>, overlap of 18 patients; <sup>#</sup>, age reported as mean ± standard deviation or median (range) for studies with multiple patients. Incidence calculated for case series only. N, number of patients with lower limb malperfusion; LLM, lower limb malperfusion; TBAD, type B aortic dissection; n, number of patients; NS, not specified; AAA, abdominal aortic aneurysm.

with previous abdominal aortic graft replacement, LLM or ischemic lower limb complications occurred in 75% of patients with TBAD (40).

### Patient and etiology

There were a total of 138 patients in the included studies (with an overlap of 18 patients). This included 118 (86%) patients from original articles and 20 (14%) from case reports. The mean age of patients was 58±12 years, and 120 (87%) were male. The etiology of TBAD was rarely reported. Hypertension, trauma and iatrogenic causes were the reported etiologies in two, two and one case respectively (22,23,30). TBAD and LLM syndrome were also observed in association with untreated abdominal aortic aneurysm (29) or in patients treated with surgical graft or endovascular exclusion (32-34).

### Clinical presentation and symptoms

Clinical presentation and symptoms are reported in Table 3. LLM was described as a complication of acute or chronic

TBAD in 134 (97%) and 4 (3%) cases, respectively. In 120 (87%) cases, LLM presented as acute limb ischemia. The other 18 (13%) patients presented with mild lower limb hypoperfusion. Bilateral clinical presentation occurred in 56% (40/72) of cases. Pulse deficit was present in all reported cases. Chest, back and abdominal pain were present in 42% (31/73), 45% (33/73) and 13% (6/47) of cases, respectively. Pain, weakness, paresthesia, numbness and paralysis occurred in 41% (25/61), 14% (5/35), 18% (7/38), 19% (5/26) and 13% (6/48) of patients, respectively.

### Associated malperfusions

Clinical and radiological malperfusions are reported in Table 4. In 52% (44/84) of cases, LLM was the only detected malperfusion. LLM was clinically associated with renal and visceral malperfusion in 40% (35/84) and 25% (21/84) of patients, respectively. According to radiological imaging, renal, celiac trunk and superior mesenteric artery involvement was reported in 53% (47/88), 31% (27/88) and 34% (30/88) of cases, respectively.

**Table 3** Clinical features of lower limb malperfusion secondary to type B aortic dissection in included studies

First author	Year	n	Acute TBAD	Chronic TBAD	Rupture	Bilateral presentation	LLM	Acute limb ischemia	Chest pain	Back pain	Abdominal pain	Limb weakness	Limb paresthesia	Limb numbness	Limb paralysis	Pulse deficit
Joo (14)	2000	1	1	0	0	1	1	0	0	0	0	1	1	1	0	NS
Panneton (15)	2000	5	3	2	0	4	2	3	NS	NS	NS	NS	NS	NS	NS	NS
Lookstein (16)	2001	1	1	0	0	0	1	0	0	1	0	0	0	0	0	1 0
Lauterbach (17)	2001	11	11	0	0	NS	0	11	NS	NS	NS	NS	NS	NS	NS	NS
Liu (18)	2002	1	1	0	0	0	0	1	0	0	0	1	1	1	0	1
Frahm (19)	2002	1	1	0	0	0	0	1	0	0	0	1	0	0	0	1
Eggebrecht (20)	2003	1	1	0	0	0	0	1	1	1	0	0	0	0	0	1
Vedantham (21)	2003	7	7	0	0	1	0	7	0	0	0	7	0	0	0	7
Fleck (22)	2004	1	1	0	0	0	0	1	NS	NS	NS	NS	NS	NS	NS	NS
Lorenzen (23)	2004	1	1	0	1	1	0	1	0	0	0	0	0	0	1	1
Tan (24)	2004	1	1	0	0	1	0	1	0	0	1	0	1	0	0	1
Yamaguchi (25)	2006	1	1	0	0	0	0	1	0	1	0	1	0	0	0	NS
Henke (26) (IRAD data)*	2006	26	26	0	NS	NS	0	26	13	13	NS	12	NS	NS	NS	17
Henke (26) (local series)*	2006	28	28	0	0	22	0	28	NS	NS	NS	NS	NS	NS	NS	NS
Nakahira (27)	2007	2	0	2	0	1	2	0	0	0	0	0	0	1	0	1
Shiiba (28)	2007	4	4	0	0	NS	4	0	NS	NS	NS	NS	NS	NS	NS	NS
Lakshmanan (29)	2008	1	1	0	0	1	0	1	0	1	1	0	1	0	1	1
Verhoye (30)	2008	3	3	0	0	NS	1	2	NS	NS	NS	NS	NS	NS	NS	NS

**Table 3** (continued)

Table 3 (continued)

First author	Year	n	Acute TBAD	Chronic TBAD	Rupture	Bilateral presentation	LLM	Acute limb ischemia	Chest pain	Back pain	Abdominal pain	Limb weakness	Limb paresthesia	Limb numbness	Limb paralysis	Pulse deficit
Fujita (31)	2009	1	1	0	0	1	0	1	0	1	1	0	0	0	0	1
Iyer (32)	2009	1	1	0	0	1	0	1	0	1	1	0	1	0	1	1
Trimarchi (33)	2010	10	10	0	0	NS	0	10	NS	NS	NS	NS	NS	NS	1	NS
Umeda (34)	2011	1	1	0	0	1	0	1	0	0	0	1	1	0	1	1
Vulev (35)	2011	1	1	0	0	1	0	1	0	0	0	1	0	1	0	1
Sfyroreas (36)	2011	12	12	0	NS	NS	6	6	10	4	0	NS	1	NS	2	NS
Lee (37)	2012	1	1	0	0	0	0	1	0	0	0	1	1	0	0	10
Narita (38)	2012	1	1	0	0	0	0	1	0	1	0	0	0	0	0	1
Kuo (39)	2013	1	1	0	0	0	0	1	0	1	1	0	1	0	0	1
Ito (40)	2013	3	3	0	0	3	0	3	NS	NS	NS	NS	NS	NS	NS	NS
Kim (41)	2014	1	1	0	0	0	0	1	0	1	1	1	0	0	0	1
Corfield (42)	2014	9	9	0	0	1	1	8	7	7	0	0	NS	NS	NS	NS
Overall	-	138	97% (134/138)	3% (4/138)	1% (1/138)	56% (40/72)	13% (18/138)	87% (120/138)	42% (31/73)	45% (33/73)	13% (6/47)	41% (25/61)	18% (7/38)	19% (5/26)	13% (6/48)	100% (40/40)

\*, overlap of 18 patients. LLM, lower limb malperfusion; TBAD, type B aortic dissection; n, number of patients; NS, not specified.

**Table 4** Extent of dissection, clinical malperfusion, radiological involvement and treatment approach in included studies

First author	Year	n	Proximal origin of TBAD	Distal end of TBAD	Clinical malperfusion			Radiological involvement			Treatment		
					LLM + LLM + renal	LLM + visceral	Isolated LLM	Renal	CT	SMA	Medical	Surgical	Endovascular
Joo (14)	2000	1	Descending arch	Just proximal to renal arteries	0	0	1	0	0	0	1	0	0
Panneton (15)	2000	5	-	-	3	1	2	NS	NS	NS	0	5	0
Lookstein (16)	2001	1	NS	NS	1	1	0	1	0	1	0	0	1
Lauterbach (17)	2001	11	-	-	5	3	5	5	4 <sup>^</sup>	4 <sup>^</sup>	3	6	2
Liu (18)	2002	1	Distal arch	Abdominal aorta	0	0	1	0	0	0	1 <sup>§</sup>	0	0
Frahm (19)	2002	1	NS	Right common and external iliac artery	0	0	1	0	0	0	0	1	0
Eggebrecht (20)	2003	1	Thoracic aorta	Iliac arteries	0	0	1	0	0	0	0	0	1
Vedantham (21)	2003	7	-	-	4	4	2	5	4 <sup>^</sup>	4 <sup>^</sup>	0	0	7
Fleck (22)	2004	1	Left subclavian artery	Iliac arteries	0	0	1	1	1	1	0	0	1
Lorenzen (23)	2004	1	Just distal to left subclavian artery	NS	0	0	1	0	0	0	0	0	1
Tan (24)	2004	1	NS	Abdominal infrarenal aorta	0	0	1	0	0	0	0	0	1
Yamaguchi (25)	2006	1	Proximal descending aorta	Right common iliac artery	0	0	1	0	0	0	0	0	1
Henke (26) (IRAD data)*	2006	26	-	-	NS	NS	NS	NS	NS	NS	13	5	8
Henke (26) (local series)*	2006	28	-	-	NS	NS	NS	22	15	15	2	2	24
Nakahira (27)	2007	2	NS	NS, right common iliac artery	0	0	1	0	0	0	0	0	2
Shiyya (28)	2007	4	-	-	1	0	3	1	0	0	2	2	0
Lakshmanan (29)	2008	1	Aortic arch	Infrarenal aorta	0	0	1	0	0	0	0	1	0
Verhoye (30)	2008	3	-	-	1	1	1	2	0	2	0	0	3

**Table 4** (continued)



Table 4 (continued)

First author	Year	n	Proximal origin of TBAD	Distal end of TBAD	Clinical malperfusion		Radiological involvement			Treatment			
					LLM + renal	LLM + visceral	Isolated LLM	Renal	CT	SMA	Medical	Surgical	Endovascular
Fujita (31)	2009	1	Descending aorta	Right common iliac and left internal iliac arteries	0	1	0	1	1	0	0	0	1
Iyer (32)	2009	1	Just distal to left subclavian artery	Upper half of aortic stentgraft	0	0	1	1	1	1	0	0	1
Trimarchi (33)	2010	10	-	-	7	4	5	NS	NS	NS	0	10	0
Umeda (34)	2011	1	Proximal descending aorta	Proximal anastomosis site of AAA repair	0	0	1	1	0	0	0	1	0
Vulev (35)	2011	1	Intimal flap at distal end of implanted endograft	NS	1	0	0	0	0	0	0	0	1
Styroreas (36)	2011	12	-	-	6	1	6	6	1	1	0	2 aortic stentgraft + fem-fem BP	10
Lee (37)	2012	1	NS	NS	0	0	1	0	0	0	0	1	0
Narita (38)	2012	1	Distal aortic arch	Bilateral external iliac arteries	0	0	1	0	0	0	0	0	1
Kuo (39)	2013	1	Aortic arch	Bilateral iliac arteries	1	1	0	1	0	0	0	1	0
Ito (40)	2013	3	-	-	2 <sup>?</sup>	2	1	0	0	0	0	3 (1 TEVAR + ax-bif BP)	0
Kim (41)	2014	1	Distal aortic arch	External iliac artery	0	1	0	0	0	1	0	1	0
Corfield (42)	2014	9	-	-	3	1	5	NS	NS	NS	0	8 (2 TEVAR + fem-fem BP)	1
Overall	-	138			35/84 (40%)	21/84 (25%)	44/84 (52%)	47/88 (53%)	27/88 (31%)	30/88 (34%)	22/138 (16%)	51/138 (37%)	65/138 (47%)

\* , overlap of 18 patients; ^ , not specified if SMA or CT involvement; § , previous surgical embolectomy for misdiagnosis; ? , unclear association with dissection. LLM, lower limb malperfusion; TBAD, type B aortic dissection; CT, celiac trunk; SMA, superior mesenteric artery; fem-fem BP, femoral-femoral bypass; AAA, abdominal aortic aneurysm; TEVAR, thoracic endovascular aortic repair; n, number of patients.

## Treatment

Medical, surgical and endovascular treatments were performed in 22 (16%), 51 (37%) and 65 (47%) patients, respectively (Tables 5-7). In the surgical group, open fenestration, extra-anatomic bypass and aortic replacement were performed in 50% (23/46), 46% (21/46) and 4% (2/46) of cases, respectively. In the endovascular group, percutaneous fenestration was performed in 54% (31/57) and aortic and/or iliac stenting/stent-grafting in 95% (54/57) of cases, thoracic endovascular aortic repair (TEVAR) in 32% (18/57), aortic stenting in 37% (21/57) and iliac stenting in 42% (24/57).

## Perioperative results

Medical therapy was the treatment of choice in 22 patients (16%). Thirty-day clinical success was 100% (6/6) with no 30-day morbidity and mortality (0/6).

In TBAD patients treated by a surgical approach, technical success was 100% (13/13). Thirty-day clinical failure occurred in 27% of cases (10/37) (five after surgical fenestration and five after extra-anatomic bypass). In addition, 30-day morbidity was 31% (13/42). Systemic complications included five cases of acute renal failure, three cases of myocardial infarction, two cases of paraplegia, and one case each of paraparesis, chest infection, colectomy contralateral lower limb ischemia and amputation above the knee. And amputation above the knee. Thirty-day mortality was 14% (five cases; four after fenestration and one after axillo-bifemoral bypass with associated TEVAR).

Technical success of endovascular treatment was 88% (15/17); procedure failure occurred in two cases (one case of asymptomatic thrombosis of renal artery stent and one case of endovascular fenestration with clinical worsening of the patient). Thirty-day clinical failure developed in 11 cases (33%), of which 6 (18%) were managed with TEVAR. Thirty-day morbidity was 46% (n=6), 3 (23%) of which occurred after TEVAR. Systemic complications included three cases of compartment syndrome with acute renal failure and transient hemodialysis, two cases of gastrointestinal ischemia, and one case each of liver ischemia, isolated acute renal failure and recurrent implanted stent collapse. Thirty-day mortality was 8% (2/26).

## Discussion

Aortic dissection is a catastrophic event affecting the aorta and producing morphological and hemodynamic

subversion in thoracic and abdominal arterial districts. TBAD represents about 38% of all aortic dissections (43). Complications occur in 20-45% of acute TBAD cases (44,45) and, in such instances, there is a dramatic increase in associated mortality (45,46). LLM occurs in 28-56% (2,47) of acute TBAD cases and, unlike renal or visceral malperfusion, is associated with poor 30-day outcomes (5).

In our systematic review, we included 29 publications reporting on a total of 138 patients with TBAD and LLM. LLM usually developed during the sixth and seventh decades of life, most frequently affected male patients, with hypertension and typically presented as acute limb ischemia (almost 90% of cases). In a minority of cases, reduced blood flow was associated with pulse deficit without leg threatening disease. In these cases, occurring generally in chronic phase, dissection causes a true lumen diameter decrease that does not result in critical reduction of arterial flow. Another possible mechanism of LLM is the movement of the intimal flap with postural changes. Nakahira *et al.* (27) reported two cases of atypical leg malperfusion arising due to compression of the true lumen and expansion of the false lumen upon standing.

LLM symptoms vary greatly according to the morphology of TBAD. This condition may actually present more frequently with chest or back pain than limb pain, as limb numbness, weakness or paresthesia only occurred in 15-20% of cases. Complete limb paralysis is not rare and can be caused either by severe acute limb or spinal cord ischemia.

Bilateral clinical presentation is a frequent event (56%). Flow reduction in both lower limbs can be induced by two different mechanisms: collapse of true aortic lumen (14,24,29,35) or bilateral iliac obstruction (31). Therefore, it is not only the iliac districts that should be carefully evaluated.

Isolated LLM was reported in more than 50% of patients included in the present review. However, clinical malperfusion syndrome involving other arterial districts is frequent, with associated renal malperfusion (40%) being more common than visceral (25%). Radiological involvement of the renal or visceral arteries is higher, since not all dissections lead to end-organ ischemia. Renal and visceral arteries were involved in a half and third of cases, respectively. As reported in the literature, radiological involvement of aortic branches is more common in patients with acute limb ischemia (P=0.004), and both mesenteric and renal malperfusion are significantly associated with acute limb ischemia (P=0.002 and P=0.048, respectively) (26).

TBAD and its related complications are routinely

**Table 5** Thirty-day outcomes of patients treated with medical therapy

First author	Year of publication	n	30-day clinical success	30-day morbidity	30-day redo	30-day mortality
Joo (14)	2000	1	1	0	0	0
Lauterbach (17)	2001	3	3	0	0	0
Liu (18)	2002	1 <sup>§</sup>	NS	NS	NS	NS
Henke (26) (IRAD data)*	2006	13	NS	NS	NS	NS
Henke (26) (local series)*	2006	2	NS	NS	NS	NS
Shiyya (28)	2007	2	2	0	0	0
Overall	–	22	6/6 (100%)	0/6 (0%)	0/6 (0%)	0/6 (0%)

\* , overlap of 18 patients; <sup>§</sup> , previous surgical embolectomy for misdiagnosis. NS, not specified; n, number of patients.

**Table 6** Thirty-day outcomes of patients treated with surgery

First author	Year	n	Surgical fenestration	Extra-anatomic bypass	Technical success	30-day clinical success	30-day morbidity	30-day redo	Type of redo	30-day mortality
Panneton (15)	2000	5	5	0	5	NS	2 (1 ARF + dialysis, 1 MI)	NS	NS	2
Lauterbach (17)	2001	6	6	0	NS	5	1 ARF + permanent dialysis, colectomy, AKA	NS	NS	NS
Frahm (19)	2002	1	0	1	1	0	1 contralateral lower limb ischemia	1	After 3 days, 1 bilateral acute limb ischemia for new left common iliac dissection: balloon-expandable stent deployment (Jostent peripheral, Jomed, Switzerland) in left iliac axis	0
Henke (26) (IRAD data)*	2006	5	NS	NS	NS	NS	NS	NS	NS	NS
Henke (26) (local series)*	2006	2	0	2 endovascular + fem-fem BP	NS	NS	NS	NS	NS	NS
Nakahira (27)	2007	2	1	1	2	2	0	NS	NS	0
Shiyya (28)	2007	2	2	0	NS	NS	NS	NS	NS	NS
Lakshmanan (29)	2008	1	0	1	1	1	0	NS	NS	0

**Table 6** (continued)

Table 6 (continued)

First author	Year	n	Surgical fenestration	Extra-anatomic bypass	Technical success	30-day clinical success	30-day morbidity	30-day redo	Type of redo	30-day mortality
Trimarchi (33)	2010	10	10	0	NS	6	4 (2 IMA, 1 paraplegia, 1 paraparesis)	NS	NS	2
Umeda (34)	2011	1	0	1	1	1	0	NS	NS	0
Sfyroereas (36)	2011	2	0	2 aortic stentgraft + fem-fem BP	NS	2	1 paraplegia	NS	NS	0
Lee (37)	2012	1	1	0	1	1	0	NS	NS	0
Kuo (39)	2013	1	0	1	1	1	0	NS	NS	0
Ito (40)	2013	3	0	3 (1 TEVAR + ax-bif BP)	NS	2	2 (2 ARF)	0	NS	1
Kim (41)	2014	1	0	1	1	1	0	NS	NS	0
Corfield (42)	2014	8	0	8 (2 TEVAR + fem-fem BP)	NS	5	2 (1 MOF, 1 ARF + chest infection)	1	NS	0
Overall	-	51	25/46 (54%)	21/46 (46%)	13/13 (100%)	27/37 (73%)	13/42 (31%)	2/12 (17%)	-	5/36 (14%)

\*, overlap of 18 patients. NS, not specified; n, number of patients; ARF, acute renal failure; MI, myocardial infarction; AKA, above the knee amputation; BP, bypass; TEVAR, thoracic endovascular aortic repair; MOF, multi-organ failure.

diagnosed with computed tomography angiography (CTA), while LLM can be evaluated with color duplex ultrasound. It is critical to distinguish LLM syndrome from the differential diagnosis of peripheral arterial embolism. In the case of acute onset of isolated lower limb ischemic symptoms, this distinction can be difficult. Liu *et al.* (18) report a case of unilateral lower limb ischemia without thoracic or abdominal symptoms or signs related with TBAD. Angiography was the diagnostic procedure performed, but iliac dissection was not detected. The patient underwent embolectomy without complete proximal progression of Fogarty catheter due to unrecognized iliac dissection. CTA finally revealed the real cause of limb ischemia.

Antihypertensive medical treatment is the first line of therapy in uncomplicated and complicated TBAD, and spontaneous recovery of LLM has been described in some cases. In the present review, 22 (16%) patients were deemed to require no interventional therapy for adequate limb perfusion. Thirty-day outcomes were only available in 6 of these cases, with optimal 30-day clinical success and freedom from mortality. As in uncomplicated TBAD, medical therapy seems to be the gold standard in the case

of spontaneous resolution of lower limb symptoms. In these patients, the modification of intimal flap positioning during the acute phase could be the cause of apparent regression of the clinical syndrome.

Open surgical approach of LLM includes two different strategies: surgical fenestration and extra-anatomic bypass grafting. The former is usually performed in case of concomitant renal or mesenteric malperfusion and consists of supra-iliac or supra-renal aortic clamping and wide excision to the aortic flap in order to equalize the pressure between the true and false lumen. The latter is preferred in high-risk patients with isolated LLM. In these patients, a femoro-femoral supra-pubic (monolateral LLM) or axillo-bifemoral (bilateral LLM) bypass graft is usually performed. Extra-anatomic bypass can be associated with endovascular deployment of aortic or iliac stent/stentgraft into the true lumen to promote false lumen collapse. In the present review, surgical fenestration and extra-anatomic bypass were reported in a similar proportion of patients. The perioperative mortality of surgical fenestration was higher than that of extra-anatomic bypass (17% *vs.* 5%) but morbidity was similar (30.4% *vs.* 31.6%). Complications

**Table 7** Thirty-day outcomes for patients treated with endovascular approach

First author	Year	n	Endovascular fenestration	Aortic stenting	Aortic stent-graft	Iliac stenting	Technical success	30-day clinical success	30-day morbidity	30-day redo	Date of redo (time post-treatment)	Type of redo	30-day mortality
Lookstein (16)	2001	1	1	0	0	0	0	0	1 GI and liver ischemia	1	36 hours	Exploratory laparotomy	1
Lauterbach (17)	2001	2	2 (1 balloon & + 1 balloon & iliac stenting)	0	0	0	NS	2	0	NS	-	-	0
Eggebrecht (20)	2003	1	1 (14 mm balloon)	0	0	1	1	0	ARF and transient HD for reperfusion syndrome	1	NS	1 thoracic aortic stent-graft to seal proximal entry tear	0
Vedantham (21)	2003	7	7	4	0	5	6	5	NS	NS	-	-	NS
Fleck (22)	2004	1	0	0	1 (2 Talent stent-grafts)	0	1	0	Bowel ischemia and compartment syndrome of lower limb and ARF with temporary dialysis	1	1st and 2nd days	1 inferior mesenteric artery stenting for bowel ischemia; 1 left lower limb fasciotomy	0
Lorenzen (23)	2004	1	0	0	1 Talent stent-graft	0	1	0	ARF for rhabdo-myolysis and temporary hemodialysis	1	1st, 4th, 6th and 9th days fasciotomies	3 wound debridements and fasciotomies of right forearm; 1 right forearm amputation	0
Tan (24)	2004	1	1 (stenting)	0	0	0	1	1	0	0	-	-	0
Yamaguchi (25)	2006	1	1 (12 mm balloon)	0	0	0	1	1	0	1	14th day	Adjunctive endovascular fenestration + wall stent deployment	0
Henke (26) (IRAD data)*	2006	8	NS	NS	NS	NS	NS	NS	NS	NS	NS	NS	NS
Henke (26) (local series)*	2006	24	18	13	0	12	NS	NS	NS	NS	NS	NS	NS

**Table 7** (continued)

Table 7 (continued)

First author	Year	n	Endovascular fenestration	Aortic stenting	Aortic stent-graft	Iliac stenting	Technical success	30-day clinical success	30-day morbidity	30-day redo	Date of redo (time post-treatment)	Type of redo	30-day mortality
Verhoye (30)	2008	3	0	0	3	1	NS	2	NS	NS	-	-	1
Fujita (31)	2009	1	0	1 (bare metal 10 mm x 57 mm)	0	0	1	1	0	0	-	-	0
Iyer (32)	2009	1	0	0	1 (valiant free-flo)	0	1	0	ARF	0	-	-	0
Vulev (35)	2011	1	0	0	1 (valiant)	0	1	1	0	0	-	-	0
Sfyroreas (36)	2011	10	0	3	10	3	NS	8	NS	NS	-	-	0
Narita (38)	2012	1	0	0	0	1	1	0	Recurrent implanted stent collapse	1	4th and 9th days	1-adjunctive common iliac stenting. 2-endovascular aortic fenestration with stent deployment	0
Corfield (42)	2014	1	0	0	1	1	NS	1	0	0	-	-	0
Overall	-	65	31/57 (54%)	21/57 (37%)	18/57 (32%)	24/57 (42%)	15/17 (88%)	22/33 (67%)	6/13 (46%)	6/11 (55%)	-	-	2/26 (8%)

\*, overlap of 18 patients. NS, not specified; n, number of patients; GI, gastrointestinal; ARF, acute renal failure; HD, hemodialysis.

may develop not only after surgical fenestration but also after extra-anatomic bypass graft, probably due to the preoperative comorbidities present in such patients.

Endovascular approach has been proposed as a less invasive procedure for TBAD since the 1990s. This approach includes TEVAR for covering the proximal entry tear with or without distal aortic/iliac stentgrafting and/or endovascular fenestration. In endovascular fenestration, septectomy of intimal septum is performed with guidewire, catheters and balloon, and sometimes with stent deployment to maintain the patency of fenestration. TEVAR with or without adjunctive distal (iliac ± abdominal aortic) stenting/endografting may induce true lumen expansion and the regression of LLM. In the present review, endovascular fenestration was performed in half of all endovascular procedures. The overall mortality of endovascular treatment was 8%; however both endovascular procedures were associated with severe complications, including gastrointestinal ischemia, acute renal failure and reperfusion syndrome.

### Limitations of the study

This review has several limitations. Many studies could not be included for analysis as they omitted patient demographics. Of the included studies, several publications failed to report on outcomes and clinical and procedural data. Another key limitation was the lack of standardization in reporting data and outcomes across studies.

### Conclusions

LLM syndrome secondary to TBAD was observed mainly during the acute phase (97%). In the vast majority of patients, LLM led to acute limb ischemia. Bilateral clinical presentation occurred in more than half of all cases, owing to flow limitation or thrombosis involving aorta of bilateral iliac axis. LLM was frequently associated with renal and visceral malperfusion while concomitant spinal cord ischemia was less common. Treatment of hypertension is essential and some cases of mild LLM improved with medical therapy alone. Surgical treatment displayed a higher rate of complications and surgical fenestration had higher mortality. Although the endovascular approach is less invasive, complication rates remained high.

### Acknowledgements

*Disclosure:* The authors declare no conflict of interest.

### References

1. DeSanctis RW, Doroghazi RM, Austen WG, et al. Aortic dissection. *N Engl J Med* 1987;317:1060-7.
2. White RA, Miller DC, Criado FJ, et al. Report on the results of thoracic endovascular aortic repair for acute, complicated, type B aortic dissection at 30 days and 1 year from a multidisciplinary subcommittee of the Society for Vascular Surgery Outcomes Committee. *J Vasc Surg* 2011;53:1082-90.
3. Szeto WY, McGarvey M, Pochettino A, et al. Results of a new surgical paradigm: endovascular repair for acute complicated type B aortic dissection. *Ann Thorac Surg* 2008;86:87-93; discussion 93-4.
4. Pearce BJ, Passman MA, Patterson MA, et al. Early outcomes of thoracic endovascular stent-graft repair for acute complicated type B dissection using the Gore TAG endoprosthesis. *Ann Vasc Surg* 2008;22:742-9.
5. Patel HJ, Williams DM, Meerkov M, et al. Long-term results of percutaneous management of malperfusion in acute type B aortic dissection: implications for thoracic aortic endovascular repair. *J Thorac Cardiovasc Surg* 2009;138:300-8.
6. Botsios S, Schuermann K, Maatz W, et al. Complicated acute type B dissections: a single-center experience with endovascular treatment. *Thorac Cardiovasc Surg* 2010;58:280-4.
7. Steuer J, Eriksson MO, Nyman R, et al. Early and long-term outcome after thoracic endovascular aortic repair (TEVAR) for acute complicated type B aortic dissection. *Eur J Vasc Endovasc Surg* 2011;41:318-23.
8. Midulla M, Renaud A, Martinelli T, et al. Endovascular fenestration in aortic dissection with acute malperfusion syndrome: immediate and late follow-up. *J Thorac Cardiovasc Surg* 2011;142:66-72.
9. Lombardi JV, Cambria RP, Nienaber CA, et al. Prospective multicenter clinical trial (STABLE) on the endovascular treatment of complicated type B aortic dissection using a composite device design. *J Vasc Surg* 2012;55:629-640.e2.
10. Shu C, Fang K, Luo M, et al. Emergency endovascular stent-grafting for acute type B aortic dissection with symptomatic malperfusion. *Int Angiol* 2013;32:483-91.
11. Alsac JM, Girault A, El Batti S, et al. Experience of the Zenith Dissection Endovascular System in the emergency setting of malperfusion in acute type B dissections. *J Vasc Surg* 2014;59:645-50.
12. Suzuki T, Mehta RH, Ince H, et al. Clinical profiles and outcomes of acute type B aortic dissection in the current

- era: lessons from the International Registry of Aortic Dissection (IRAD). *Circulation* 2003;108 Suppl 1:II312-7.
13. Moher D, Liberati A, Tetzlaff J, et al. Preferred reporting items for systematic reviews and meta-analyses: the PRISMA statement. *Ann Intern Med* 2009;151:264-9, W64.
  14. Joo JB, Cummings AJ. Acute thoracoabdominal aortic dissection presenting as painless, transient paralysis of the lower extremities: a case report. *J Emerg Med* 2000;19:333-7.
  15. Panneton JM, Teh SH, Cherry KJ Jr, et al. Aortic fenestration for acute or chronic aortic dissection: an uncommon but effective procedure. *J Vasc Surg* 2000;32:711-21.
  16. Lookstein RA, Mitty H, Falk A, et al. Aortic intimal dehiscence: a complication of percutaneous balloon fenestration for aortic dissection. *J Vasc Interv Radiol* 2001;12:1347-50.
  17. Lauterbach SR, Cambria RP, Brewster DC, et al. Contemporary management of aortic branch compromise resulting from acute aortic dissection. *J Vasc Surg* 2001;33:1185-92.
  18. Liu WP, Chen WK, Ng KC. Aortic dissection presenting as acute lower extremity ischemia: report of a case. *Yale J Biol Med* 2002;75:211-4.
  19. Frahm C, Widmer MK, Brossmann J, et al. Bilateral leg ischemia due to descending aortic dissection: combined treatment with femoro-femoral cross-over bypass and unilateral aorto-iliac stenting. *Cardiovasc Intervent Radiol* 2002;25:444-6.
  20. Eggebrecht H, Baumgart D, Dirsch O, et al. Percutaneous balloon fenestration of the intimal flap for management of limb threatening ischaemia in acute aortic dissection. *Heart* 2003;89:973.
  21. Vedantham S, Picus D, Sanchez LA, et al. Percutaneous management of ischemic complications in patients with type-B aortic dissection. *J Vasc Interv Radiol* 2003;14:181-94.
  22. Fleck T, Wisser W, Cejna M, et al. Complicated acute aortic dissection type B caused by femoral cannulation for endoscopic coronary artery bypass surgery. *J Endovasc Ther* 2004;11:80-3.
  23. Lorenzen HP, Geist V, Hartmann F, et al. Endovascular stent-graft implantation in acute traumatic aortic dissection with contained rupture and hemorrhagic shock. *Z Kardiol* 2004;93:317-21.
  24. Tan ME, Morshuis WJ, Ernst SM, et al. Endovascular stenting for aortic dissection with lower extremity malperfusion. *Ann Thorac Surg* 2004;78:1098.
  25. Yamaguchi M, Sugimoto K, Tsuji Y, et al. Percutaneous balloon fenestration and stent placement for lower limb ischemia complicated with type B aortic dissection. *Radiat Med* 2006;24:233-7.
  26. Henke PK, Williams DM, Upchurch GR Jr, et al. Acute limb ischemia associated with type B aortic dissection: clinical relevance and therapy. *Surgery* 2006;140:532-9; discussion 539-40.
  27. Nakahira A, Ogino H, Matsuda H, et al. Postural change causing leg malperfusion resulting from expansion of a patent false lumen in type B aortic dissection. *J Thorac Cardiovasc Surg* 2007;134:1046-7.
  28. Shiiya N, Matsuzaki K, Kunihara T, et al. Management of vital organ malperfusion in acute aortic dissection: proposal of a mechanism-specific approach. *Gen Thorac Cardiovasc Surg* 2007;55:85-90.
  29. Lakshmanan R, Aung M, Hoong CK. Limb ischaemia in a Stanford B aortic dissection into an abdominal aortic aneurysm. *ANZ J Surg* 2008;78:660-1.
  30. Verhoye JP, Miller DC, Sze D, et al. Complicated acute type B aortic dissection: midterm results of emergency endovascular stent-grafting. *J Thorac Cardiovasc Surg* 2008;136:424-30.
  31. Fujita W, Daitoku K, Taniguchi S, et al. Endovascular stent placement for acute type-B aortic dissection with malperfusion--an intentional surgical delay and a possible 'bridging therapy'. *Interact Cardiovasc Thorac Surg* 2009;8:266-8.
  32. Iyer V, Rigby M, Vrabec G Sr. Type B aortic dissection after endovascular abdominal aortic aneurysm repair causing endograft collapse and severe malperfusion. *J Vasc Surg* 2009;50:413-6.
  33. Trimarchi S, Jonker FH, Muhs BE, et al. Long-term outcomes of surgical aortic fenestration for complicated acute type B aortic dissections. *J Vasc Surg* 2010;52:261-6.
  34. Umeda Y, Imaizumi M, Mori Y, et al. Severe limb ischemia related to previous abdominal aortic aneurysm repair induced by acute aortic dissection. *Ann Vasc Dis* 2011;4:37-9.
  35. Vulev I, Klepanec A, Balázs T, et al. Endovascular treatment of late in-stent-graft dissection after thoracic endovascular aneurysm repair. *Cardiovasc Intervent Radiol* 2011;34:864-7.
  36. Sfyroeras GS, Rubio V, Pagan P, et al. Endovascular management of malperfusion in acute type B aortic dissections. *J Endovasc Ther* 2011;18:78-86.
  37. Lee CH, Chang CH, Tsai YT, et al. Isolated lower limb



- ischaemia as an unusual presenting symptom of aortic dissection. *Cardiovasc J Afr* 2012;23:e13-4.
38. Narita K, Akutsu K, Yamamoto T, et al. Simultaneous fenestration with stent implantation for acute limb ischemia due to type B acute aortic dissection complicated with both static and dynamic obstructions. *Ann Thorac Cardiovasc Surg* 2012;18:158-61.
  39. Kuo HN, Lai HC, Chang YW, et al. Axillofemoral bypass relieves visceral malperfusion in type B aortic dissection. *Ann Thorac Surg* 2013;95:703-5.
  40. Ito T, Kawaharada N, Kurimoto Y, et al. Infradiaphragmatic malperfusion of acute aortic dissection associated with previous abdominal aortic aneurysm repair. *Surg Today* 2013;43:1019-24.
  41. Kim KH, Choi JB, Kuh JH. Simultaneous relief of acute visceral and limb ischemia in complicated type B aortic dissection by axillobifemoral bypass. *J Thorac Cardiovasc Surg* 2014;147:524-5.
  42. Corfield L, McCormack DJ, Bell R, et al. Role of the femorofemoral crossover graft in acute lower limb ischemia due to acute type B aortic dissection. *Vascular* 2014;22:121-6.
  43. Toda R, Moriyama Y, Masuda H, et al. Organ malperfusion in acute aortic dissection. *Jpn J Thorac Cardiovasc Surg* 2000;48:545-50.
  44. Hagan PG, Nienaber CA, Isselbacher EM, et al. The International Registry of Acute Aortic Dissection (IRAD): new insights into an old disease. *JAMA* 2000;283:897-903.
  45. Trimarchi S, Tolenaar JL, Tsai TT, et al. Influence of clinical presentation on the outcome of acute B aortic dissection: evidences from IRAD. *J Cardiovasc Surg (Torino)* 2012;53:161-8.
  46. Shu C, He H, Li QM, et al. Endovascular repair of complicated acute type-B aortic dissection with stentgraft: early and mid-term results. *Eur J Vasc Endovasc Surg* 2011;42:448-53.
  47. Shu C, Fang K, Luo M, et al. Emergency endovascular stent-grafting for acute type B aortic dissection with symptomatic malperfusion. *Int Angiol* 2013;32:483-91.

**Cite this article as:** Gargiulo M, Bianchini Massoni C, Gallitto E, Freyrie A, Trimarchi S, Faggioli G, Stella A. Lower limb malperfusion in type B aortic dissection: a systematic review. *Ann Cardiothorac Surg* 2014;3(4):351-367. doi: 10.3978/j.issn.2225-319X.2014.07.05