

## Morphology of functioning trabeculectomy blebs using anterior segment optical coherence tomography

Mayuri B Khamar, Shruti R Soni, Siddharth V Mehta, Samaresh Srivastava, Viraj A Vasavada

**Purpose:** To image trabeculectomy blebs using anterior segment optical coherence tomography (AS-OCT), and to correlate the bleb morphologic features at one month postoperatively with bleb function at six months. **Materials and Methods:** This prospective, observational study included 56 eyes undergoing trabeculectomy with MMC, followed up for minimum of six months. Postoperatively, bleb imaging was done using AS-OCT at one and six month. Bleb morphology was assessed for bleb wall reflectivity, bleb pattern in multiform reflectivity, visibility of drainage route and presence of hyper-reflectivity area. Bleb function was considered successful if IOP was <18 mmHg without medication at six month. Bleb morphology one month postoperatively was correlated with bleb function at six months. **Results:** At six months successful bleb function was noted in 44 (81.5%) eyes. Morphology of bleb at one month showed uniform bleb wall reflectivity in 6 eyes (11%) and multiform wall reflectivity in 48 eyes (89%). In eyes with multiform wall reflectivity, microcysts with multiple layers was seen in 26 eyes (48%), microcysts with subconjunctival separation in 12 eyes (22%) and only microcyst in 10 eyes (19%). When bleb features at one month were correlated with the bleb function at six months, logistic regression analysis revealed that blebs with multiform reflectivity with multiple internal layers with microcysts were associated with higher chances of success ( $P < 0.001$ ). **Conclusion:** AS-OCT demonstrated early bleb morphological features that may be used to predict the functioning of a bleb. Multiform bleb wall reflectivity with a pattern of multiple internal layers and microcysts was associated with increased chances of success of a bleb.

**Key words:** AS-OCT, bleb morphology, trabeculectomy

The outcome of trabeculectomy largely depends on the formation of a functioning filtration bleb, which enables the egress of aqueous from the eye. Further, the ability of the bleb to remain functional determines the maintenance of desired intraocular pressures and the long-term success of surgery.

Bleb morphology has always been an important clinical parameter as an indicator for bleb function and a predictor of bleb related complications.<sup>[1]</sup> Bleb appearance has been assessed using slit-lamp biomicroscopy, and subsequent bleb grading systems have been designed for the assessment of various bleb parameters such as vascularity, height, width, encystment using reference photographic standards (viz, the Indiana Bleb Appearance Grading Scale-IBAGS, Moorfields Bleb Grading System-MBGS).<sup>[1-3]</sup> Early postoperative morphologic features have also been described that predict late bleb failure.<sup>[4]</sup> However, slit-lamp biomicroscopy does not show the internal structures of bleb, which may be essential in determining the bleb function.

Imaging techniques like ultrasound biomicroscopy (UBM) and optical coherence tomography (OCT) have been used to study bleb morphology *in vivo*, earlier. In previous studies UBM and AS-OCT have been used to show that mature blebs with walls that appear hyporeflexive are more likely to function.<sup>[5-12]</sup> However, there are limited studies that have used imaging,

to identify features of blebs early in their development after trabeculectomy, that may predict success of these blebs in the longterm.<sup>[13]</sup>

In this study, we attempt to recognize bleb morphology features in the early postoperative period that may predict in determining the functionality of filtering bleb, and thereby, success of trabeculectomy.

### Materials and Methods

A prospective observational study was designed to include 56 eyes (forty-eight patients) undergoing trabeculectomy with mitomycin-C (MMC). We included all patients with primary glaucoma (open angle/angle closure) uncontrolled on maximal medical treatment. Baseline IOP was considered as an average of minimum two measurements, atleast two weeks apart. They were measured during different times of the day. We excluded patients with previous ocular surgery, secondary glaucoma and congenital glaucoma. The study adhered to the tenets of the declaration of Helsinki, and was approved by the Institutional Review Board. Written informed consent was obtained from all patients before start of the study. A single surgeon performed all surgeries using a standardized surgical technique. Following creation of a fornix based conjunctival flap, sponge soaked in MMC (200 µg) was applied under the conjunctiva for a duration of 2 minutes, taking care that the MMC-soaked sponge did not come in contact with the edge of the conjunctival flap. A partial thickness triangular scleral flap was created followed by creation of a sclerostomy of 2 × 2 mm with scissors or Kelly's punch. Closure of scleral flap was done using two side permanent sutures and one apical releasable 10-0 Nylon sutures. Conjunctiva was closed with 10-0 Nylon

Access this article online

Website:

www.ijo.in

DOI:

10.4103/0301-4738.136227

Quick Response Code:



Glaucoma Centre, Raghudeep Eye Hospital, Ahmedabad, India

**Correspondence to:** Dr. Mayuri Khamar, Raghudeep Eye Clinic, Gurukul Road, Memnagar, Ahmedabad - 380 052, Gujarat, India. E-mail: glaucoma@raghudeepeclinic.com

Manuscript received: 05.12.2012; Revision accepted: 02.11.2013

sutures. Postoperatively antibiotic and steroid drops were given in tapering dose over a period of two months.

The patients were followed up at one day, one week, one month and six months. At every follow up, intraocular pressure was measured using Goldmann applanation tonometer. As a part of the follow-up protocol, the patient was called at different times of the day for each follow-up, so that any major diurnal fluctuations in IOP can be detected. In this study, none of the eyes underwent suturolysis, as a part of the study protocol.

All blebs were imaged using slit-lamp photography under standard illumination and magnification settings. All blebs were imaged by AS-OCT (Visante, Carl Zeiss, Germany) using a standardized protocol. Patients were asked to look down, and the upper lid was gently elevated to expose the bleb as much as possible, taking care to avoid exerting any pressure on the globe or bleb. Two scans, radial and tangential, were taken through the maximum point of elevation on the bleb [Fig. 1].

The AS-OCT images were evaluated to assess bleb morphologic features by a single, skilled observer, who was blinded to the clinical data. All blebs were assessed qualitatively for bleb wall reflectivity. Bleb wall reflectivity was classified as uniform reflectivity or multiform reflectivity depending on presence or absence of hyper-reflective areas in the bleb wall itself [Fig. 2]. In uniform reflectivity there were no fluid filled hyporefective spaces in the subconjunctival space. It was seen as smooth, hyperreflective wall [Fig. 2a]. In multiform reflective wall there was presence of small multiple fluid filled spaces seen as hyporefective areas in the conjunctiva or bleb wall [Fig. 2b]. Depending on the appearance of the shape and the site of these multiform area they were further classified as microcystic multiform or subconjunctival separation or multiple internal layers. As shown in Fig. 3, multiple internal layers [Fig. 3a] was identified as hyporefective spaces seen in the deeper layers of conjunctiva, seen as channels of fluid parallel to the surface of the sclera. Subconjunctival separation [Fig. 3b] was seen as multiple small spaces in more superficial layers of the conjunctiva. Microcystic pattern [Fig. 3c] was identified as multiple, rounded, cystic, defined as hyporefective areas in the deeper layers. These patterns were observed to be present alone or in combination. Other features that were noted were the scleral flap and route beneath the scleral flap [Fig. 4].

Bleb function was considered to be successful if IOP was  $\leq 18$  mm Hg without glaucoma medication and a failure if IOP was  $>18$  mm Hg with or without glaucoma medications at the end of six months.

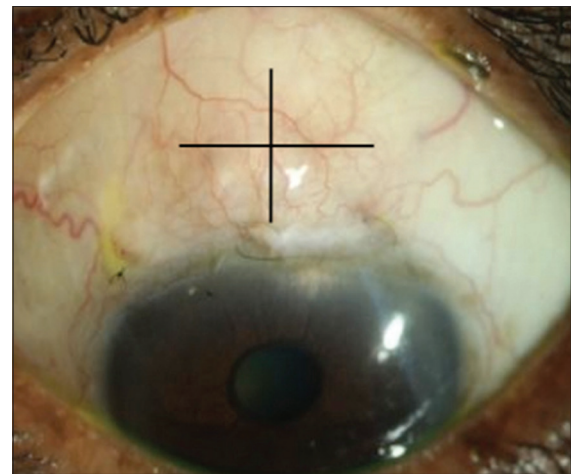
Our primary aim was to correlate internal bleb morphology and bleb wall features on AS-OCT at one month with bleb function (IOP) six months postoperatively.

### Statistical Analysis

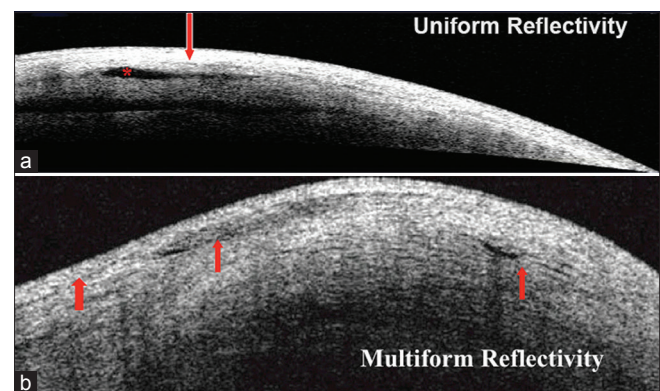
In the present study logistic regression was used to predict odds of surgical success at six months with the observations of AS-OCT at one month using predictor variables including bleb wall reflectivity (uniform and multiform), bleb pattern (subconjunctival separation, multiple internal layers and microcysts) and bleb wall hyperreflectivity (present and absent).

## Results

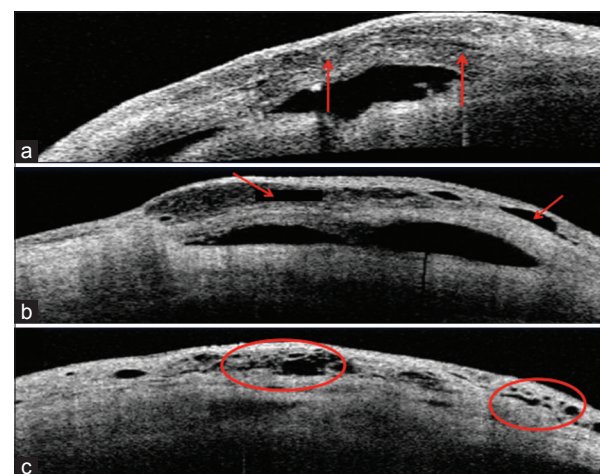
Two patients (two eyes) were lost to follow-up. Of the 54 eyes included, 30 eyes had primary open angle glaucoma (55.6%)



**Figure 1:** Radial and tangential OCT scans were taken at the area of maximum elevation of bleb for each eye



**Figure 2:** (a) Representative AS-OCT image of bleb wall showing Uniform Reflectivity in the bleb wall, Hyper-reflective areas seen as a dense white area within the bleb wall. Here the asterisk marks the single cavity for aqueous drainage while rest of the wall of the bleb has a uniform reflectivity. (b) Multiform Reflectivity of the bleb. The arrows indicate multiple tiny cavities of aqueous drainage and hence multiform reflectivity of the bleb wall



**Figure 3:** (a-c) Representative AS-OCT images of eyes with Multiform Reflectivity, showing multiple internal layers, as indicated by the two arrows (3a), subconjunctival separation, as indicated by the two arrows (3b) and presence of microcysts, as indicated by the circles (3c)

and 24 eyes had primary angle closure glaucoma (44.4%). The mean age was  $61.9 \pm 9.6$  years. (Range: 37-80 years) The study included 36 males and 20 females. Mean preoperative IOP was  $22.4 \pm 9.03$  mmHg (Range: 11.5-47.0 mmHg). Postoperatively, mean IOP at one and six months was  $15.1 \pm 5.1$  and  $15.8 \pm 4.6$  mmHg respectively.

Bleb function was successful in 44 (81.5%) eyes with mean IOP of  $13.9 \pm 2.6$  and a failure in 10 eyes (18.5%) with mean IOP of  $21.5 \pm 4.8$  mmHg.

Bleb morphology features are depicted in Table 1. Morphology of bleb on AS-OCT at one month showed uniform bleb wall reflectivity in 6 eyes (11.0%) and multiform wall reflectivity in 48 eyes (89.0%). Further, at one month, in eyes having multiform wall reflectivity, bleb pattern of microcysts with multiple layers was seen in 26 eyes (48.0%), microcysts with subconjunctival separation in 12 eyes (22.0%) and only microcyst pattern in 10 eyes (19.0%). Further on AS-OCT, hyper reflective areas were absent in 46 (85.0%) eyes at one month, while route beneath the scleral flap was visible in all eyes (100.0%).

When the bleb features at one month were compared with the bleb function at six months, it was found that, with uniform wall reflectivity only 4 out of 6 eyes (66.0%) had successful bleb function at six months and with multiform wall reflectivity 40 out of 48 eyes (83.1%) had successful bleb function at six months ( $P = 0.30$ ) [Table 2]. Amongst blebs with multiform wall reflectivity, bleb pattern of microcysts with multiple internal layers was seen in 26 eyes. Of these, 20 eyes (76.9%) had successful bleb function at six months. All 12 eyes with bleb pattern of microcysts with subconjunctival separation had successful bleb function at six months (100.0%). While 10 eyes with bleb pattern of only microcysts, 8 eyes (80.0%) had successful bleb function at six months [Table 2].

So at six months the results showed the correlation as follows:

Bleb walls with multiform reflectivity showed increased chances of success of functioning filtering blebs at six months ( $P < 0.001$ ).

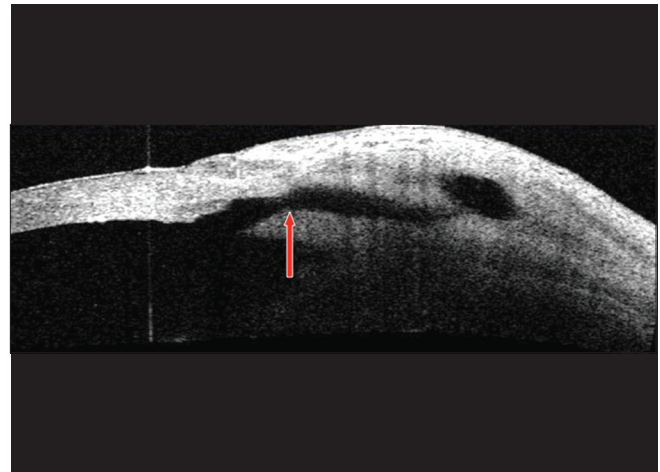
Bleb walls with the pattern of multiple internal layers and microcysts showed increased chances of success of functioning filtering bleb at six months ( $P < 0.001$ ).

Bleb walls with uniform wall reflectivity showed increased chances of failure of functioning filtering blebs at six months.

We found that bleb pattern at one month emerged as statistically significant predictor of odds of surgical success at six months. Further, when we evaluated the odds of surgical success at six months with bleb pattern we found multiple layers combined with microcystic pattern was associated 35 times more with surgical success when compared with the eyes having subconjunctival separation at 1 month attaining statistical significant difference ( $P < 0.001$ ). The logistic model achieved a high predictive accuracy of 86% and Nagelkerke R-square was 52.3% signifies that the model has a sound explanatory power achieving  $P$  value of 0.001.

## Discussion

AS-OCT has been shown to be useful in showing cross-sectional images of internal bleb structures that were previously inferred



**Figure 4:** Visible route beneath the sclera, as indicated by the arrow

**Table 1: Bleb wall pattern at 1 month**

Bleb wall pattern	No of eyes (%)
Uniform	6 (11)
Multiform	48 (89)
Pattern within multiform Bleb	
Microcysts+multiple layers	26 (48)
Microcysts+subconjunctival separation	12 (22)
Only microcysts	10 (19)

**Table 2: Correlation of Bleb wall pattern at 1 month with bleb functions at 6 months after surgery**

Bleb pattern	Success (%)	Failure (%)	Total (%)
Uniform bleb	4 (66.7)	2 (33.3)	6 (11)
Microcysts+multiple layers	20 (76.9)	6 (23.1)	26 (48)
Microcysts+subconjunctival separation	12 (100)	0 (0)	12 (22)
Only microcysts	8 (80)	2 (25)	10 (19)

$P$  value of Chi-square test=0.36

from slit lamp examination. It is possible to demonstrate qualitative characteristics such as bleb structure, location of sclera flap, patency of internal ostium and presence of cystic spaces.<sup>[7]</sup>

A variety cross-sectional imaging modalities (UBM or AS-OCT) have been used to determine the association between the bleb wall features and the bleb function.<sup>[5,6,8]</sup> However, the relationship between these bleb wall features in the early post-operative period and long-term postoperative outcome is still to be established clearly. We noted that bleb walls having a uniform reflectivity in the early postoperative period, as early as one month, had a poor bleb function at the end of six months. Identifying this feature may provide an early on predictor of bleb failure. These eyes can be monitored more tightly for IOP control, and necessary interventions (eg. laser suturelysis or release of releasable sutures) maybe planned at an earlier stage postoperatively. Previously, other studies have also concluded in their findings that multiform walls (i.e. areas of

hypo reflectivity) in the early bleb may have better bleb function at six months which is consistent with findings of our study.<sup>[8,9]</sup>

To describe hyporeflexive areas in multiform early bleb walls, subconjunctival separation (or subconjunctival fluid spaces) and microcysts were also identified in images of mature bleb walls obtained by others using AS-OCT.<sup>[8-10]</sup> However, the pattern and areas of subconjunctival separation seen in early blebs in our subjects seem to be much larger than the areas previously reported for mature blebs. The bleb wall pattern of multiple internal layering observed in our study is similar to, but has some differences from patterns in the walls of functioning mature blebs within areas described as "hyporeflexive cystic spaces" by previous studies.<sup>[8,10]</sup> Bleb wall features seen in previous studies are not completely similar to the features reported in our study. A variety of factors like differences in surgical procedure, variation in terms of duration and concentration of application of Mitomycin C, as well as differences in post-operative manipulations such as suturolysis, releasable sutures may modify the pattern of bleb wall.<sup>[9,10]</sup> As a result, the presence of hyporeflexivity areas in the bleb wall *per se* are more important to bleb function than the small variations in the actual pattern of these hyporeflexivity areas. It is believed that, these areas of hypo reflectivity in mature bleb walls seen on OCT, whether in a cystic or layered pattern, represent the collections of aqueous humor.<sup>[8,9]</sup> Previous studies on the histopathology of filtering blebs or the appearance of blebs on confocal microscopy have also supported this assumption.<sup>[11]</sup>

Our study showed that multiform hyporeflexive features were actually present as early as one month postoperatively, which was predictive of good bleb function at 6 months postoperatively.

We hypothesize that these areas of hyporeflexivity may represent the connective tissue in these bleb walls that contain an abundance of aqueous humor, which can protect the developing blebs from fibrosis related to early bleb failure. The application of MMC may also modify the bleb wall patterns, because MMC is expected to inhibit intrableb fibrosis actively in early postoperative period. In our study, this may have increased the frequency and/or degree of hyporeflexive multiform bleb wall formation.

Previous studies using the slit lamp biomicroscopy found out that presence of microcysts in blebs in the early or late postoperative period are associated with good function of the mature bleb.<sup>[3,10]</sup> In our study, we also found that microcysts remained in all eyes with good bleb function at six months after surgery, whereas they were no longer seen in mature blebs with poor function. This finding seems to support an association between microcysts in mature blebs and good bleb function. Therefore, it is understood that microcysts seen in developing blebs can be lost during maturation, especially in mature blebs with poor function.

IOP is susceptible to daily fluctuations in the early postoperative period, which may be due to the changes in the amount of aqueous humor outflow, reflecting the outflow efficiency through the scleral flap rather than filtration efficiency of the bleb. In the late postoperative period, IOP seems to reflect

mainly the filtration efficiency of the bleb, which depends on the degree of intra-bleb scarring and bleb dimensions.

A limitation of this study is that we have not correlated clinical morphologic features of the bleb, such as bleb vascularity, with the anterior segment oct features. In future we do plan to correlate the clinically visible features along with the internal morphologic features in relation to functional success.

In conclusion, bleb walls with multiform wall reflectivity with the pattern of multiple internal layers with microcysts showed increased chances of success of functioning filtering bleb at six months. Thus, AS-OCT is a promising tool not only to image trabeculectomy blebs but it is also able to demonstrate features of bleb morphology, which are not visible on the slit lamp.

## References

1. Wells AP, Crowston JG, Marks J, Kirwan JF, Smith G, Clarke JC, *et al.* A pilot study of a system for grading of drainage blebs after glaucoma surgery. *J Glaucoma* 2004;13:454-60.
2. Picht G, Grehn F. Classification of filtering blebs in trabeculectomy: Biomicroscopy and functionality. *Curr Opin Ophthalmol* 1998;9:2-8.
3. Cantor LB, Mantravadi A, WuDunn D, Swamynathan K, Cortes A. Morphologic classification of filtering blebs after glaucoma filtration surgery: The Indiana bleb appearance grading scale. *J Glaucoma* 2003;12:266-71.
4. Sacu S, Rainer G, Findl O, Georgopoulos M, Vass C. Correlation between the early morphological appearance of filtering blebs and outcome of trabeculectomy with Mitomycin C. *J Glaucoma* 2003;12:430-5.
5. Pavlin CJ, Harasiewicz K, Foster FS. Ultrasound biomicroscopy of anterior segment. *Am J Ophthalmol* 1992;113:381-9.
6. Yamamoto T, Sakuma T, Kitazawa Y. An ultrasound biomicroscopic study of filtering blebs after Mitomycin C trabeculectomy. *Ophthalmology* 1995;102:1770-6.
7. McWhae JA, Crichton AC. The use of ultrasound biomicroscopy following trabeculectomy. *Can J Ophthalmol* 1996;31:187-91.
8. Savini G, Zanini M, Barboni P. Filtering blebs imaging by optical coherence tomography. *Clin Experiment Ophthalmol* 2005;33:483-9.
9. Babighian S, Rapizzi E, Galan A. Stratus OCT of filtering bleb after trabeculectomy. *Acta Ophthalmol Scand* 2006;84:270-1.
10. Singh M, Chew PT, Friedman DS, Nolan WP, See JL, Smith SD, *et al.* Imaging of trabeculectomy blebs using anterior segment optical coherence tomography. *Ophthalmology* 2007;114:47-53.
11. Guthoff R, Klink T, Schlunck G, Grehn F. *In vivo* confocal microscopy of failing and functioning filtering blebs: Results and clinical correlations. *J Glaucoma* 2006;15:552-8.
12. Labbé A, Dupas B, Hamard P, Baudouin C. *In vivo* confocal microscopy study of blebs after filtering surgery. *Ophthalmology* 2005;112:1979-86.
13. Nakano N, Hangai M, Nakanishi H, Inoue R, Unoki N, Hirose F, *et al.* Early trabeculectomy bleb walls on anterior-segment optical coherence tomography. *Graefes Arch Clin Exp Ophthalmol* 2010;248:1173-82.

**Cite this article as:** Khamar MB, Soni SR, Mehta SV, Srivastava S, Vasavada VA. Morphology of functioning trabeculectomy blebs using anterior segment optical coherence tomography. *Indian J Ophthalmol* 2014;62:711-4.

**Source of Support:** Nil. **Conflict of Interest:** None declared.