

Chlamydia pneumoniae (TWAR) in coronary arteries of young adults (15–34 years old)

(cytomegalovirus/atherosclerosis)

C.-C. KUO*†, J. T. GRAYSTON*‡, L. A. CAMPBELL*, Y. A. GOO*, R. W. WISSLER§, AND E. P. BENDITT¶

Departments of *Pathobiology, †Epidemiology, and ‡Pathology, University of Washington, Seattle, WA 98195; and §Department of Pathology, University of Chicago, Chicago, IL 60637

Contributed by E. P. Benditt, April 12, 1995

ABSTRACT An association of *Chlamydia pneumoniae* with atherosclerosis of coronary and carotid arteries and aorta has been found by seroepidemiology and by demonstration of the organism in atheromata. Age-matched control tissue from persons without atherosclerosis was usually not available. We studied autopsy tissue from young persons, many with no atherosclerosis, to determine whether *C. pneumoniae* is present in atheroma in young persons with early atherosclerosis and to compare the findings in age- and sex-matched persons without atherosclerosis. A left anterior descending coronary artery sample, formalin-fixed, from 49 subjects, 15–34 years of age, from the multicenter study called Pathobiological Determinants of Atherosclerosis in Youth (PDAY), was examined by immunocytochemistry and the polymerase chain reaction (PCR) for the presence of *C. pneumoniae* and by PCR for cytomegalovirus. A hematoxylin/eosin-stained section was used to determine disease present in the studied sample. Seven of the artery samples were found to have atheromatous plaque, 11 had intimal thickening, and 31 had no lesions. Eight of the samples were positive for *C. pneumoniae* by immunocytochemistry ($n = 7$) and/or PCR ($n = 3$). Six of the 7 (86%) atheroma, 2 of the 11 (18%) with intimal thickening, and none of the 31 normal-appearing coronary samples were positive. Four were positive by PCR for cytomegalovirus, 2 from diseased arteries and 2 from normal arteries. Examination of the adjacent left coronary artery sample with a fat stain found abnormalities in 25 of the patients, but 19 still showed no evidence of atherosclerosis as a result of either examination. Thus, *C. pneumoniae* is found in coronary lesions in young adults with atherosclerosis but is not found in normal-appearing coronary arteries of both persons with and without other evidence of atherosclerosis.

A single cause for lesions of atherosclerosis has, thus far, not been found. A number of risk factors have been discovered that enhance the rate of progression of atherosclerotic lesions and increase the frequency of its sequelae, such as myocardial infarction. The concept that causation of atherosclerosis likely involves several factors is now considered reasonable.

The possibility that infectious agents might play a role in the development of atherosclerosis that one of us (E.P.B.) proposed some years ago (1) has received increasing attention in recent years. The presence of herpes simplex virus (2) and more recently cytomegalovirus (CMV) (3) in atherosclerotic lesions has been described, and the role of viruses in the development of the vascular sclerosis associated with organ allograft rejection of both heart and kidney is now established (4). A newly recognized infectious agent, *Chlamydia pneumoniae* TWAR, has more recently been associated with atherosclerosis (10–19).

The TWAR strain of *Chlamydia* was first isolated from a respiratory infection in 1983 (5) and in 1989 was established (6) as the third species of *Chlamydia*, called *Chlamydia pneumoniae*. It has been shown to be an important cause of pneumonia and other respiratory infections in adults (7) and children (8).

All three of the chlamydial species that infect humans (*Chlamydia trachomatis*, *Chlamydia psittaci*, and *C. pneumoniae*) have been associated with endocarditis and myocarditis (9). Seroepidemiological studies have associated *C. pneumoniae* with coronary artery disease (10–14) and carotid artery disease (15).

The *C. pneumoniae* organism has been demonstrated in atheromatous plaques of coronary arteries in autopsy tissue by electron microscopy, immunocytochemistry (ICC), and the polymerase chain reaction (PCR) (16, 17). In autopsy aorta tissue, *C. pneumoniae* was found in macrophages and smooth muscle cells of atheroma by double ICC staining (18). The organism was found in 20 of 38 tissue specimens removed at coronary atherectomy (19). Similar results have been obtained with tissue removed at carotid endarterectomy, where >50% of such tissue from different sources showed *C. pneumoniae* by ICC and/or PCR (unpublished data). While normal-appearing segments of coronary and carotid arteries and aorta have been studied and found negative for *C. pneumoniae*, tissue from age-matched control persons without atherosclerosis have not been available.

In an effort to better understand the significance of finding *C. pneumoniae* in atheromata, this paper reports a study of autopsy coronary artery segments from young adults (15–34 years old) whose autopsies conducted by means of an exacting protocol have been thoroughly evaluated for atherosclerosis. Those studied included persons with and without evidence of atherosclerosis.

MATERIALS AND METHODS

Tissue. The tissues studied came from the multicenter research program entitled the Pathobiological Determinants of Atherosclerosis in Youth (PDAY). This is an investigator-initiated study that has obtained and evaluated standardized pathologic specimens and risk factor data from nearly 3000 individuals 15–34 years of age (21–23). The protocol for our study called for 60 specimens from Caucasian males, 50% from persons with some atherosclerosis demonstrated in routine PDAY studies, and the other 50% from persons with no atherosclerotic lesions. Half of each of the diseased and control groups were to be in the age group 15–24 years and half in the age group 25–34 years. The PDAY autopsy protocol called for

Abbreviations: PDAY, Pathobiological Determinants of Atherosclerosis in Youth; ICC, immunochemistry; LAD, left anterior descending; CMV, cytomegalovirus.

†To whom reprint requests should be addressed at: Department of Pathobiology, SC-38, University of Washington, Seattle, WA 98195.

coronary artery samples that were from predetermined sites and were consistently sized, preserved, and prepared for study. We were provided sample 46, which is a segment of the left anterior descending (LAD) coronary artery that was formalin-fixed by pressure perfusion. It was directly adjacent distally from the core reference sample 45, and the presence of disease and the severity and type of the lesions were classified for all samples. Because of the small number of specimens in each age and disease category, no effort was made in this initial study to determine differences by gender or race.

A total of 49 specimens was available for this study and due to the absence of some of the types of samples requested, the age group 15–24 years was somewhat underrepresented. The unmounted tissues were stored and shipped in formalin.

Procedure. The samples were trimmed and paraffin-embedded. Four-micrometer sections were mounted and

stained for microscopic study with hematoxylin/eosin and with monoclonal antibodies for ICC described below. Sixteen-micrometer sections were used for PCR. The coronary arteries of the patients studied had been classified as to disease from the adjacent LAD coronary sample (sample 45) with oil red O fat stains. The hematoxylin/eosin-stained sections were used for determining intimal lesions in sample 46, the same sample that was studied for the presence of *C. pneumoniae*.

ICC. The ICC of chlamydial antigens employed a *Chlamydia* genus-specific mouse monoclonal antibody, CF-2, directed against chlamydial lipopolysaccharide and the avidin–biotin complex immunoperoxidase system with diaminobenzidine/nickel chloride color modification (ABC Elite; Vector Laboratories). The slides were counter stained with methyl green. For negative controls, duplicate tissue sections were stained

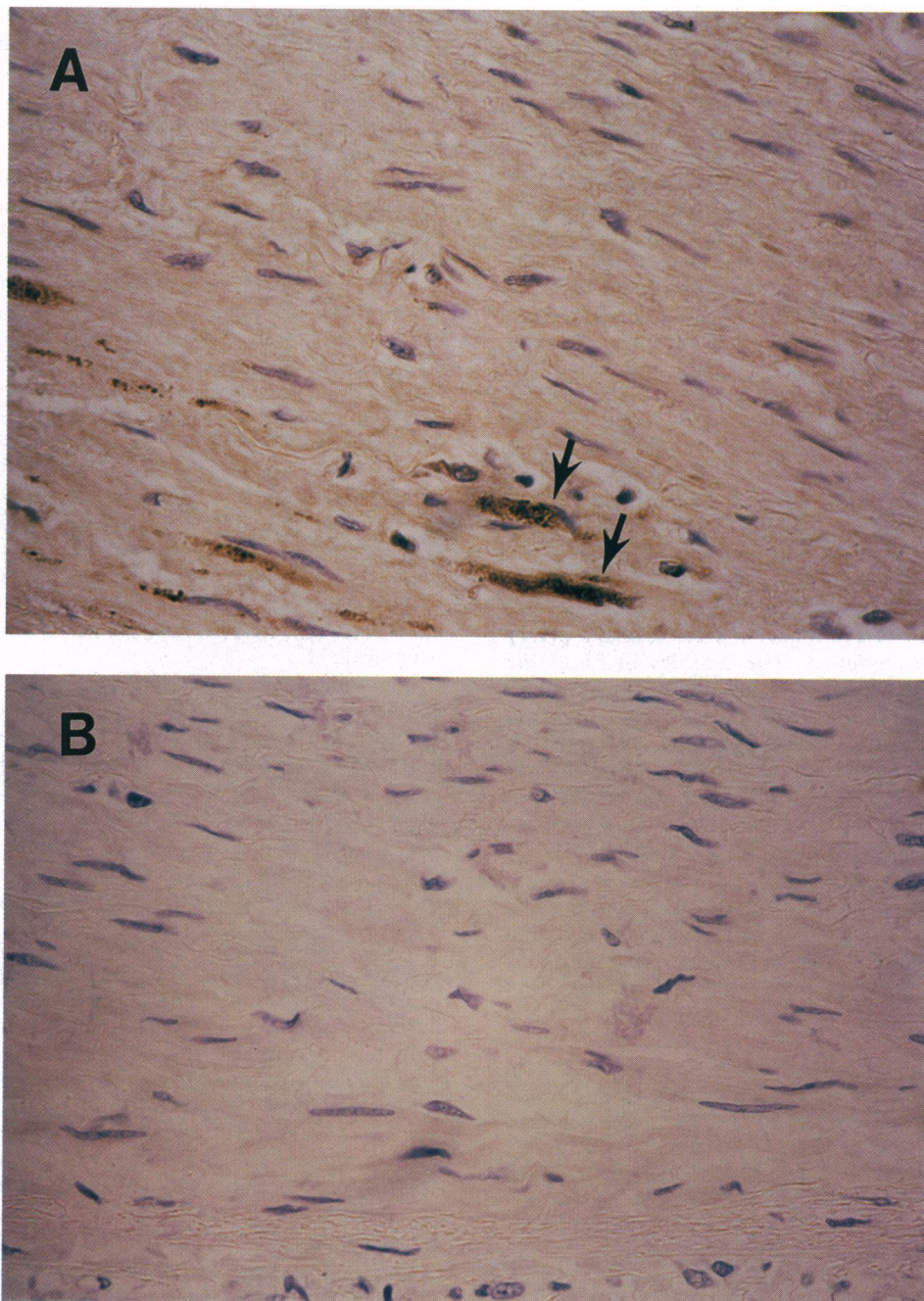


FIG. 1. Immunocytochemical staining of a fibrous plaque with *C. pneumoniae* species-specific monoclonal antibody (TT-401, 1:1000 dilution) illustrates positively stained (dark brown) foam cells (arrows) localized in the deep layer of plaque (A) and the adjacent section stained with negative control antibody (normal ascitic fluid) shows no immunostaining (B). The tissues were counterstained with hematoxylin. ($\times 400$.)

with normal mouse ascitic fluids and positive controls were sections of formalin-fixed cell pellets of HeLa cells infected with *C. pneumoniae* and stained with CF-2 antibody.

All tissues that were positive with the genus antibody CF-2 were also stained with a *C. pneumoniae* species-specific monoclonal antibody, TT-401, and a *C. trachomatis* species-specific monoclonal antibody, KK-12, to determine the *Chlamydia* species present.

PCR. PCR for *C. pneumoniae* was done by using the HL-1, HR-1 primer set as described by Campbell *et al.* (24). DNA was purified from tissues either as described (17) or by Qiagen columns by the directions of the manufacturer (Qiagen, Chatsworth, CA). Mock extractions of buffer were done and amplified to ensure that no contamination occurred during DNA isolation. A control consisting of PCR reagents without any specimen and various dilutions of purified *C. pneumoniae* DNA were used in each PCR as the negative and positive controls, respectively. Confirmation of presumptive positives and detection of products below the sensitivity of agarose gels were done by immunochemiluminescence with the 474-bp *Pst* I *C. pneumoniae*-specific fragment as a probe of Southern blot transfers as described by Kuo *et al.* (17). If the specimen was negative, aliquots were seeded with 100 fg of *C. pneumoniae* DNA and reamplified to rule out that the negative results were due to inhibition of PCR. If inhibition was observed, drop dialysis against sterile water was performed and PCR was repeated.

For detection of CMV DNA by PCR, the MIE4 and MIE5 primers and reaction mixtures described by Demmler *et al.* (25) were used with minor modifications. Both primers were synthesized without the 5 bases on the 5' end resulting in 20-mer primers instead of the 25-mer primers as described (25). Each cycle consisted of denaturation of DNA at 94°C for 1 min, reannealing at 50°C for 1 min, and primer extension at 72°C for 1 min. A total of 46 cycles was done. CMV DNA at various dilutions was used as the positive control. All other controls were performed as described above. Confirmation of products was made by using the 430-bp sequence as the probe.

To minimize the risk of contamination appropriate precautions were taken as described (17, 19).

RESULTS

Eight of the 49 coronary tissue samples were positive for *C. pneumoniae* by ICC and/or PCR. Of the 7 samples ICC-positive by the *Chlamydia* genus-specific antibody, 5 were also positive by the *C. pneumoniae* species-specific antibody (Fig. 1), and all were negative by the *C. trachomatis* species-specific antibody. Table 1 shows these results by age group and by disease description based on the immediately adjacent hematoxylin/eosin-stained slide. Tissue from only one of the youngest persons (15–24 years) was positive. All *C. pneumoniae*-positive tissues had lesions, either definite atheromatous plaques or at least more than a diffuse intimal thickening (26).

Table 1. Results of ICC and PCR studies for *C. pneumoniae* with LAD coronary artery samples

Sample	No. tested	No. positive		
		ICC	PCR	ICC and/or PC
Age group				
15–24 years	22	1	0	1
25–34 years	27	6	3	7
Classification				
Atheroma	7	6	1	6
Intimal thickening	11	1	2	2
Normal	31	0	0	0
Total	49	7	3	8

C. pneumoniae was not found in any coronary samples without lesions.

There is a highly statistically significant difference between the *C. pneumoniae* results in Table 1. The difference between atheroma and normal, between atheroma plus intimal thickening and normal, and between atheroma and normal plus intimal thickening had values of $P < 0.0001$ by the Fisher exact two-tailed test.

The adjacent coronary sample 45, stained with oil red O for fat, was reviewed by the scientists at the PDAY administrative center where most of the evaluation of histopathological preparation was carried out. There were 24 samples without evidence of any atherosclerotic disease and 25 samples with disease (5 with fatty streaks, 17 with fatty plaques, and 3 with fibrous plaques). When we compared these findings to the disease classification of sample 46 (Table 1), we found that there were 19 studied persons without evidence of atherosclerosis in either examination. With one exception, all of the sample-46 artery segments classified with atheromatous plaques had plaques demonstrated by fat stain in segment 45. That one was positive for *C. pneumoniae*. Of the two *C. pneumoniae*-positive segments classified as intimal thickening, one had plaque in segment 45 and the other had no lesion.

Four of the 49 LAD coronary artery samples (sample 46) tested by PCR for CMV were positive. One positive was a segment with atheromatous plaque that was also positive for *C. pneumoniae*. One was from a segment with intimal thickening that was negative for *C. pneumoniae*. The other two were from normal-appearing tissue.

DISCUSSION

There are two major results from this study of coronary arteries obtained at autopsy of young adults. One is that *C. pneumoniae* can be found in a high proportion of atheromatous plaque lesions of coronary arteries of young people. The other is that in tissue from age- and sex-matched controls without evidence of atherosclerosis, no *C. pneumoniae* is found by the same ICC and PCR techniques.

While both the ICC and PCR were positive in the diseased samples and not in the normal tissue, the PCR test appeared to be less sensitive. It is possible that the long exposure to formalin may have had a deleterious effect on the DNA of *C. pneumoniae* (20, 27–30).

The PCR results with CMV primers may also have been affected by the formalin fixation. While the number of positives ($n = 4$) is small for meaningful correlations, the fact that two were from diseased and two from normal arteries suggests that there is a less important association with atherosclerosis than observed with *C. pneumoniae*.

These results, as did those of previous studies of arterial tissue (16–19) and the seroepidemiological studies (10–15), show an association of *C. pneumoniae* with atherosclerosis but do not prove an etiologic or pathogenic role for the organism in the disease. This study's frequent finding of the organism in lesions in young persons and the lack of organisms in normal arteries of matched controls add important circumstantial evidence that *C. pneumoniae* may be influencing the disease process.

This study was supported in part by National Institutes of Health Grants AI 21885 and HL33740.

We thank the PDAY research group for supplying specimens for this study. The PDAY research group is as follows:

PDAY Research Group, Program Director, Robert W. Wissler. *Steering Committee*

J. Frederick Cornhill, Ohio State University; Henry C. McGill, Jr., and C. Alex McMahan, University of Texas Health Science Center at San Antonio; Abel L. Robertson, Jr., University of Illinois; Jack P. Strong, Louisiana State University Medical Center; Robert W. Wissler, University of Chicago.

Participating Centers

University of Alabama, Birmingham, AL, Department of Medicine [Principal Investigator, Steffen Gay; Coinvestigators, Renate E. Gay and Guo-quiang Huang (HL-33733)] and Department of Biochemistry [Principal Investigator, Edward J. Miller; Coinvestigators, Donald K. Furuto, Margaret S. Vail, and Annie J. Narkates (HL-33728)].

Albany Medical College, Albany, NY [Principal Investigator, Asaad Daoud; Coinvestigators, Adriene S. Frank, Mary A. Hyer, and E. Carol McGovern (HL-33765)].

Baylor College of Medicine, Houston, TX [Principal Investigator, Louis C. Smith; Coinvestigator, Faith M. Strickland (HL-33750)].

University of Chicago, Chicago, IL [Principal Investigator, Robert W. Wissler; Coinvestigators, Dragoslava Vesselinovitch, Akio Komatsu, Yoshiaki Kusumi, R. Timothy Bridenstine, Robert J. Stein, Robert H. Kirschner, Gregory Culen, Manuela Bekermeier, Blanche Berger, Laura Hiltcher, and Alexis Demopoulos (HL-33740)].

The University of Illinois, Chicago, IL [Principal Investigator, Abel L. Robertson, Jr.; Coinvestigators, Robert J. Stein, Edmund R. Donoghue, Jr., Robert J. Buschmann, Eugene E. Emeson, Luna Ghosh, Herbert M. Yamashiroya, Tae Lyong An, Eupil Choi, Nancy Jones, Mitra S. Kalelkar, Yuksel Konakci, Barry Lifschultz, V. Ramana Gumidyalala, Rose Harper, Frances Norris, Mei-Ling Shen, and Richard Yang (HL-33758)].

Louisiana State University Medical Center, New Orleans, LA [Principal Investigator, Jack P. Strong; Coinvestigators, Gray T. Malcolm, William P. Newman III, Margaret C. Oalman, Paul S. Roheim, Ashim K. Bhattacharyya, Miguel A. Guzman, Ali A. Hatem, Conrad A. Hornick, Carlos D. Restrepo, and Richard E. Tracy (HL-33746) and Cecilia C. Breau, Stephanie E. Hubbard, Cynthia S. Zsembik, and DeAnne G. Gibbs (HL-33746)].

University of Maryland, Baltimore, MD [Principal Investigator, Wolfgang J. Mergner; Coinvestigators, James H. Resau, Robert D. Vigorito, Q.-C. Yu, and J. Smialek (HL-33752)].

Medical College of Georgia, Augusta, GA [Coprincipal Investigators, A. Bleakley Chandler and Raghunatha N. Rao; Coinvestigators, D. Greer Falls, and Benjamin O. Spurlock; Associate Investigators, Kalish B. Sharma and Joel S. Sexton; Research Assistants, K. K. Smith and G. W. Forbes (HL-33772)].

University of Nebraska Medical Center, Omaha, NB [Principal Investigator, Bruce M. McManus; Coinvestigators, Jerry W. Jones, Todd J. Kendall, Jerrold A. Remmenga, and William C. Rogler (HL-33778)].

Ohio State University, Columbus, OH [Principal Investigator, J. Fredrick Cornhill; Coinvestigators, William R. Adrion, Patrick M. Fardel, Brian Gara, Edward Herderick, John Meimer, and Larry R. Tate (HL-33760)].

Southwest Foundation for Biomedical Research, San Antonio, TX [Principal Investigators, James E. Hixson and Patricia K. Powers (HL-39913)].

University of Texas Health Science Center, San Antonio, TX [Principal Investigator, C. Alex McMahan; Coinvestigators, George M. Barnwell, Henry C. McGill, Jr., Yolana N. Martinez, Thomas J. Prihoda, and Herman S. Wigodsky (HL-33749)].

Vanderbilt University, Nashville, TN [Principal Investigator, Renu Virmani; Coinvestigators, James B. Atkinson and Charles W. Harlan (HL-33770)].

West Virginia University Health Sciences Center, Morgantown, WV [Principal Investigator, Singanallur N. Jagannathan; Coinvestigators, Bruce Caterson, James L. Frost, K. Murali K. Rao, Syamala Jagannathan, Peggy Johnson, and Nathaniel F. Rodman (HL-33748)].

1. Benditt, E. P., Barrett, T. & McDougall, J. K. (1983) *Proc. Natl. Acad. Sci. USA* **80**, 6386–6389.
2. Hendrix, M. G., Salimans, M. D., van Boven, C. P. & Bruggeman, C. A. (1990) *Am. J. Pathol.* **136**, 23–28.
3. Bayad, J., Galteay, M. M. & Siest, G. (1993) *Ann. Biol. Clin. Paris* **51**, 101–107.
4. Melnick, J. L., Adam, E. & DeBakey, M. E. (1993) *Eur. Heart J.* **14** (Suppl. K), 30–38.
5. Grayston, J. T., Kuo, C.-C., Wang, S.-P. & Altman, J. (1986) *N. Engl. J. Med.* **315**, 161–168.
6. Grayston, J. T., Kuo, C.-C., Campbell, L. A. & Wang, S.-P. (1989) *Int. J. Syst. Bacteriol.* **39**, 88–90.
7. Grayston, J. T. (1992) *Clin. Infect. Dis.* **15**, 757–763.
8. Grayston, J. T. (1994) *Pediatr. Infect. Dis. J.* **13**, 675–685.
9. Odeh, M. & Oliver, A. (1992) *Eur. J. Clin. Microbiol. Infect. Dis.* **11**, 885–893.
10. Saikku, P., Leinonen, M., Matilla, K., Ekman, M.-R., Nieminen, M. S., Makela, P. H., Huttunen, J. K. & Valtonen, V. (1988) *Lancet* **ii**, 983–986.
11. Thom, D. H., Wang, S.-P., Grayston, J. T., Siscovick, D. S., Stewart, D. K., Kronmal, R. A. & Weiss, N. S. (1991) *Arterioscler. Thromb.* **11**, 547–551.
12. Saikku, P., Leinonen, M., Tenkanen, L., Manttari, M., Frick, M. H., Huttunen, J. K., Linnanmaki, E., Ekman, M.-R. & Manninen, V. (1992) *Ann. Intern. Med.* **116**, 273–278.
13. Thom, D. H., Grayston, J. T., Siscovick, D. S., Wang, S.-P., Weiss, N. S. & Daling, J. R. (1992) *J. Am. Med. Assoc.* **268**, 68–72.
14. Linnanmaki, E., Leinonen, M., Mattila, K., Nieminen, M. S., Valtonen, V. & Saikku, P. (1993) *Circulation* **87**, 1130–1134.
15. Melnick, S. L., Shahar, E., Folsom, A. R., Grayston, J. T., Sorlie, P. D., Wang, S.-P. & Szklo, M. (1993) *Am. J. Med.* **95**, 499–504.
16. Shor, A., Kuo, C.-C. & Patton, D. L. (1992) *S. Afr. Med. J.* **82**, 158–161.
17. Kuo, C.-C., Shor, A., Campbell, L. A., Fukushi, H., Patton, D. L. & Grayston, J. T. (1993) *J. Infect. Dis.* **167**, 841–849.
18. Kuo, C.-C., Gown, A. M., Benditt, E. P. & Grayston, J. T. (1993) *Arterioscler. Thromb.* **13**, 1501–1504.
19. Campbell, L. A., O'Brien, E. R., Cappuccio, A. L., Kuo, C.-C., Wang, S.-P., Stewart, D., Patton, D. L., Cummings, P. & Grayston, J. T. (1995) *J. Infect. Dis.*, in press.
20. Goelz, S. E., Hamilton, S. R. & Vogelstein, B. (1985) *Biochem. Biophys. Res. Commun.* **30**, 18–126.
21. Wissler, R. W. (1991) *Ann. N.Y. Acad. Sci.* **623**, 26–39.
22. Wissler, R. W. & PDAY Collaborating Investigators (1994) *Atherosclerosis (Dallas)* **108** (Suppl.), S3–S20.
23. Wissler, R. W., Hiltcher, L., Oinuma, T. & the PDAY Research Group (1995) in *Atherosclerosis and Coronary Artery Disease*, eds. Fuster, V., Ross, R. & Topol, E. (Raven, New York), in press.
24. Campbell, L. A., Perez-Melgosa, M., Hamilton, D. J., Kuo, C.-C. & Grayston, J. T. (1992) *J. Clin. Microbiol.* **30**, 434–439.
25. Demmler, G. J., Buffone, G. J., Schimbor, C. M. & May, R. A. (1988) *J. Infect. Dis.* **158**, 1177–1184.
26. Stary, H. C., Blankenhorn, D. H., Chandler, A. B., Glagov, S., Insull, W., Jr., Richardson, M., Rosenfeld, M. E., Schaffer, S. A., Schwartz, C. J., Wagner, W. D. & Wissler, R. W. (1992) *Circulation* **85**, 391–405.
27. Dubeau, L., Chandler, L. A., Gralow, J. R., Nicholas, P. W. & Jones, P. A. (1986) *Cancer Res.* **46**, 2964–2969.
28. Greer, C. E., Peterson, S. L., Kiviat, N. B. & Manos, M. M. (1990) *Am. J. Clin. Pathol.* **95**, 117–124.
29. Greer, C. E., Lund, J. K. & Manos, M. M. (1991) *PCR Methods Appl.* **1**, 46–50.
30. Wright, D. K. & Manos, M. M. (1990) in *PCR Protocols: A Guide to Methods and Applications*, eds. Innis, M. A., Gelfand, D. H., Sninsky, J. J. & White, T. J. (Academic, San Diego), pp. 153–158.