

Published in final edited form as:

Am J Med Genet A. 2014 September ; 164(9): 2240–2249. doi:10.1002/ajmg.a.36633.

Diamond-Blackfan Anemia with Mandibulofacial Dystostosis is Heterogeneous, Including the Novel DBA Genes *TSR2* and *RPS28*

Karen W. Gripp¹, Cynthia Curry², Ann Haskins Olney³, Claudio Sandoval⁴, Jamie Fisher⁵, Jessica Xiao-Ling Chong⁶, UW Center for Mendelian Genomics^{6,X}, Lisa Pilchman⁷, Rebecca Sahraoui⁷, Deborah L. Stabley⁷, and Katia Sol-Church⁷

¹Division of Medical Genetics, A. I. duPont Hospital for Children, Wilmington, Delaware, USA

²University of California, San Francisco, California, USA

³Munroe-Meyer Institute for Genetics and Rehabilitation, University of Nebraska Medical Center, Omaha, Nebraska, USA

⁴Department of Pediatrics, New York Medical College, Valhalla, New York, USA

⁵Genetic Medicine Central California, Fresno, California, USA

⁶University of Washington, Seattle, Washington, USA

⁷Department of Biomedical Research, Nemours' Children's Clinic, Wilmington, Delaware, USA

Abstract

Patients with physical findings suggestive of Treacher Collins syndrome (TCS) or mandibulofacial dystosis (MFD) and macrocytic anemia diagnostic of Diamond Blackfan anemia (DBA) have been reported. Disease causing genes have been identified for TCS and other MFDs. Mutations in several ribosomal protein genes and the transcription factor GATA1 result in DBA. However, no disease causing mutation had been identified in the reported patients with the combination of TCS/MFD and DBA phenotype, and we hypothesized that pathogenic mutations in a single gene could be identified using whole exome analysis. We studied probands from 6 unrelated families. Combining exome analysis and Sanger sequencing, we identified likely pathogenic mutations in 5/6 families. Two mutations in unrelated families were seen in *RPS26*, the known DBA10 gene. One variant was predicted to affect mRNA splicing, and the other to lead to protein truncation. In another family a likely pathogenic X-linked mutation affecting a highly conserved residue was

Correspondence to: Karen W. Gripp, MD; Division of Medical Genetics, A. I. duPont Hospital for Children, 1600 Rockland Road, Wilmington, DE 19803. Phone: 302 651 5916. Fax: 302 651 5033. kgripp@nemours.org.

^XUniversity of Washington Center for Mendelian Genomics (UW CMG): Michael J. Bamshad^{1,2}, Jay Shendure¹, and Deborah A. Nickerson¹ Gonçalo R. Abecasis⁴, Peter Anderson¹, Marcus Annable¹, Mallory Beightol¹, Brian L. Browning¹, Kati J. Buckingham¹, Christina Chen¹, Jennifer Chin¹, Jessica X Chong¹, Gregory M. Cooper⁵, Colleen Davis¹, Lindsay Felker¹, Christopher Frazer¹, David Hanna¹, Zongxiao He³, Preti Jain⁵, Gail P. Jarvik¹, Eric Johanson¹, Goo Jun⁴, Martin Kircher¹, Tom Kolar¹, Suzanne M. Leal³, Daniel Luksic¹, Margaret J. McMillin¹, Sean McGee¹, Brenton Munson¹, Brian J. O'Roak¹, Bryan Paepfer¹, Karynne Patterson¹, Eric Phillips¹, Jessica Pijoan¹, Christa Poel¹, Peggy D. Robertson¹, Regie Santos-Cortez³, Tristan Shaffer¹, Cindy Shephard¹, Deborah L. Siegel¹, Joshua D. Smith¹, Jeffrey C. Staples¹, Holly K. Tabor^{1,2}, Monica Tackett¹, Gao Wang³, and Qian Yi¹

¹University of Washington; ²Seattle Children's Hospital; ³Baylor College of Medicine; ⁴University of Michigan; ⁵HudsonAlpha Institute of Technology

The authors declare no conflict of interest.

found in *TSR2*, which encodes a direct binding partner of RPS26. De novo mutations affecting the *RPS28* start codon were found in two unrelated probands, identifying *RPS28* as a novel disease gene. We conclude that the phenotype combining features of TCS with DBA is genetically heterogeneous. Each of the pathogenic variants identified is predicted to impede ribosome biogenesis, which in turn could result in altered cell growth and proliferation, causing abnormal embryologic development, defective erythropoiesis and reduced growth. The phenotype combining TCS/MFD and DBA is highly variable, overlaps with DBA and lies within the phenotypic spectrum of ribosomopathies.

Keywords

Cleft palate; Diamond-Blackfan anemia; macrocytic anemia; microtia; ribosomopathy; Treacher Collins syndrome; RPS26; RPS28; TSR2

Introduction

Rare patients with combined physical findings suggestive of Treacher Collins syndrome (TCS) or mandibulofacial dysostosis (MFD) and macrocytic anemia diagnostic of Diamond Blackfan anemia (DBA) have been reported in hematology, genetics and craniofacial surgery journals [Hasan and Inoue, 1993; Gripp et al., 2001; McFarren et al., 2007; Handler et al., 2009]. Treacher Collins syndrome is characterized by variable expressivity of zygomatic hypoplasia, downslanting palpebral fissures with lower lid coloboma and medial eye lash deficiency, microtia with hearing loss, preauricular hair displacement onto the cheeks, mandibular hypoplasia and cleft palate for review see Katsanis and Jabs, 2012]. Treacher Collins syndrome belongs to the mandibulofacial dysostoses (MFD), a group of disorders including Nager syndrome, Miller syndrome and MFD with macrocephaly amongst others. Most TCS patients have a heterozygous *TCOF1* mutation, while heterozygous *POLR1D* and biallelic *POLR1C* mutations account for additional cases [Dauwerse et al., 2011]. Diamond-Blackfan anemia typically presents in early infancy with macrocytic anemia, elevated erythrocyte adenosine deaminase (eADA) and hemoglobin F, and less commonly associated physical findings such as short stature or thumb anomalies. Expressivity is variable and penetrance is incomplete. The anemia remits spontaneously in about 20%, is steroid responsive in 40% and requires long term transfusions in about 40% [for review see Clinton and Gazda, 2013]. In about 25% of DBA patients a *RPS19* mutation is present. Mutations in nine additional ribosomal genes and the erythroid transcription factor *GATA1* account for another 25-30% of cases, leaving a substantial proportion unaccounted for. As no disease causing mutation had been identified in individuals with findings combining DBA and TCS/MFD [Hasan and Inoue, 1993; Gripp et al., 2001; McFarren et al., 2007; Handler et al., 2009], we hypothesized that pathogenic mutations in a single gene would be identified using whole exome sequencing.

Materials and Methods

The study was approved by our institutional review board (Nemours #212117). After obtaining informed consent, cheek swab and peripheral white blood cell (PWBC) derived DNA samples were obtained from probands, parents and family members as available.

Clinical Reports

Family 1

This family was reported in detail in Gripp et al. [2001].

Patient 1

Briefly, the propositus (Fig. 1; Family 1, III-1) was delivered by cesarean for breech position at term. Bilateral grade 2 microtia with absent external auditory canals and abnormal middle ears, micrognathia and unilateral cryptorchidism were present (Table I). Diamond-Blackfan anemia was diagnosed at age 10 months and responded to steroid treatment. A number of surgical procedures, including submucous cleft palate repair and otoplasties, were well tolerated. Downslanting palpebral fissures and midfacial hypoplasia remained notable. Hearing loss was treated with aids. The patient was in good health at age 24 years.

Family members: Affected Cousin

A maternal cousin of Patient 1 (Fig. 1, Family 1, III-2) was also affected with facial features suggestive of Treacher Collins syndrome. He was delivered at term by cesarean for breech position. He had bilateral microtia without visible external auditory canals, micrognathia and a cleft palate. He tolerated corrective surgical procedures well. Hearing loss was treated with hearing aids. Downslanting palpebral fissures, mild midfacial hypoplasia and micrognathia remained notable. The patient never had overt anemia, but elevated mean corpuscular volume, eADA and hemoglobin F were consistent with DBA markers. He was in good health at age 16 years.

Family Members

Patient 1 and Patient 2's mothers are sisters. Neither had facial features suggestive of Treacher Collins syndrome, other malformation or a history of DBA. No other family member had congenital facial anomalies.

Family 2: Patient 2

This female was described in detail in Handler et al. [2009]. Briefly, she (Fig. 1, Family 2, II-2) was delivered vaginally at 36-weeks gestation. She had bilaterally low-set and posteriorly angulated ears, bilateral external auditory canal atresia, choanal atresia, micrognathia and cleft palate (Fig. 2, A-D). Airway obstruction led to mandibular distraction osteogenesis and choanal atresia repair. A small muscular ventriculo-septal defect (VSD) did not require treatment and 13 rib pairs were noted on skeletal survey. Hearing loss was treated with a bone-anchored hearing aid. DBA was initially treated with prednisone, but due to a partial response it was discontinued at age 3 ½ years. She required multiple red cell transfusions, including nine in the first three weeks of life. At age 5 years she received

transfusions every 3-4 weeks. Her motor and cognitive development was grossly age appropriate. Her height was 100.4 cm (<5th centile; 50th centile for age 4 years); weight 13.8 kg (<5th centile; 50th centile for 3 years) and OFC 48.5 cm (10th centile).

Family Members

The proposita's 34-year-old father (Fig. 1, Family 2, I-1) was diagnosed with steroid responsive DBA at age 2 years. He did not require an increased steroid dosage for many years, never required a transfusion and was of normal stature.

The proposita's sister (Fig. 1, Family 2, II-1) was diagnosed with DBA at age 5 weeks with initiation of steroid therapy and first transfusion at that time. She had 7 transfusions in total, including 4 in the past year. She had a duplicated right kidney. She was in good health at age 7 years with normal development for age and stature at the 5th centile.

Family 3-Patient 3

This patient was reported in McFarren et al. [2007]. Briefly, the proposita (Fig. 1, Family 3, II-1) was delivered at 37 weeks gestation with a birth weight of 2.6 kg (25-50th centile). She had a soft palate cleft and bilateral atresia of the external ear canals, reminiscent of TCS. Subsequently identified malformations included anomalous right sided middle ear ossicles, vestibule and semicircular canals, two muscular VSDs, left sided cross-fused renal ectopia and right sided Morgagni hernia with liver eventration. At age 2 weeks she was hospitalized for jaundice and failure-to-thrive; at 5 weeks she was again hospitalized for failure-to-thrive and DBA was diagnosed. Cognitive development was grossly age appropriate. At age 8 years (Fig. 2, E-G) she continued to be transfusion dependent and her height was 108 cm (<3rd centile; 50th centile for age 5 years), weight 18.4 kg (<3rd centile; 50th centile for 5 years), and OFC was 48.5 cm (<3rd centile; 50th centile for 3 years). Laboratory studies performed clinically with normal results included a banded karyotype and Sanger sequencing of *RPS19* and *RPS24*.

Family 4: Patient 4

The proposita (Fig. 1, Family 4, II-1) was born after an uneventful pregnancy at term to a 31-year-old G1 mother and a 33-year-old father. Both parents were in good health without a personal or family history of anemia or congenital anomalies. The proband's birth weight was 1.98 kg (<10th centile; 50th centile for 33.5 weeks gestation), length was 46 cm (10th centile). Micrognathia, submucous cleft palate, downslanting palpebral fissures, absence of lashes on the medial aspects of the lower lids and midfacial hypoplasia resulted in a diagnosis of TCS (Fig. 3, A-D). Bilaterally, her thumbs did not bend at the interphalangeal joint. Unilateral mixed hearing loss was not treated. A left diaphragmatic Morgagni hernia was surgically repaired at five months. Persistent feeding and respiratory problems resulted in Nissen fundoplication and G-tube placement at age six months; tracheostomy at one year; and pyloric myotomy at 15 months. Mandibular distraction osteotomy was performed at age 4 years, and the tracheostomy was subsequently reversed. Macrocytic anemia required multiple transfusions, beginning at age 5 days and continuing until age 1 year, and DBA was diagnosed. Intermittent granulocytopenia was treated with granulocyte colony-stimulating factor until age 5 years.

Development was delayed with walking independently at age 2 years and using language at 4-5 years. A neuropsychological assessment reportedly showed results in the range of mild intellectual disability. At age 11 years her height was 118 cm (<3rd centile; 50th centile for 6.5 years), weight was 22.8 kg (<3rd centile; 50th centile for 7.5 years), and OFC 49.5 cm (<-2SD of mean for age; 50th centile for 3 years). At age 22 years her health remained stable. Laboratory studies performed with nondiagnostic results included array CGH and Sanger sequencing of *TCOF1* and *RPS19*.

Family 5-Patient 5

This patient (Fig. 1 Family 5, V-2) was delivered without complication at 35 weeks gestation to nonconsanguineous parents. Bilateral severe sensorineural hearing loss was documented in infancy and treated with aids. When first evaluated at age 4 months she had normal growth parameters, micrognathia, and posteriorly angulated ears of normal size with decreased cartilage and deficient antihelices bilaterally. Ear canals were small. She had sparse eyebrows and downslanting palpebral fissures. Eyelashes were intact on both lids. Hair extended onto the lateral face. She had a bifid uvula. She had full cheeks, malar hypoplasia and a full, mildly webbed neck (Fig. 3, E, F). Pallor prompted a hematologic evaluation revealing hemoglobin of 6 gm and a hematocrit of 18%. She underwent serial transfusions for DBA in infancy until age 3 years, but was steroid responsive and required no further treatment after age 7 years. She had short stature (< 3rd centile) at 2 years and her development was mildly delayed. At age 14 years her growth had improved with a height of 154.5 cm (5-10th centile), weight of 50.9 kg (10-25th centile) and OFC of 57 cm (97th centile). She was a good student in classes for the hearing impaired and communicated exclusively in sign language. She had a low posterior hairline and a full neck anteriorly (Fig. 3 G,H). Mild bilateral ptosis was also seen in her father and brother.

Family members

Her family evaluation revealed unaffected parents and a normal brother. Mother, maternal grandmother and maternal great grandmother had no history of anemia, cognitive issues or dysmorphic features, although all had head circumferences at the 3rd centile for adults. A half-sister of the great-grandmother (Fig. 1, Family 5, II-3) had no history of anemia, but had bilateral severe conductive hearing loss and abnormal ears with deficient cartilage and stenotic canals, and mild micrognathia.

Family 6, Patient 6

This child was first seen at age 9 days for bilateral microtia and micrognathia. She was the product of a term pregnancy and second live birth to nonconsanguineous Hispanic parents. She weighed 2.8 kg (10th centile). She failed newborn hearing screening. In the neonatal period she had nasopharyngeal regurgitation and occasional apnea. Examination showed bilateral microtia with blind-ending canals, more severe on the left. There were downslanting palpebral fissures without lid colobomas, a bow shaped mouth with downturned corners and micrognathia. She had a small amount of hair anterior to the ears bilaterally. Echocardiography revealed 2 small VSD's that closed spontaneously. At age seven weeks her mother reported pallor and the patient had a hematocrit of 9.5% and

hemoglobin of 3.3 gm/dl. She was transfused and treated with corticosteroids. Steroids were tapered and discontinued at about 18 months and her hemoglobin remained stable. At age 2 years she has severe growth failure with a weight of 9.18 kg (50th centile for age 10 months) and microcephaly with an OFC of 42 cm (50th centile for 5.5 months). She walked independently at 13 months and her speech was delayed with only 5 words at age 2 years. The patient had normal Sanger sequencing of *TCOF1*, *POLRID*, *RPL11*, *RPL5* and *RPS19*. A SNP microarray performed clinically had a normal result. Red cell adenosine deaminase levels were elevated in the proposita, the clinically unaffected brother and mother.

Family members

Her mother was diagnosed with DBA at age 7 months. She was steroid-responsive and remained on steroids until age 14 years. Examination revealed a normal head circumference and normal ears, eyes and palate. She has mild displacement of the inner canthi and has a small amount of hair anterior to the ears. Physical examination of the proposita's brother was normal. The more distant family history was entirely negative for symptoms of TCS or DBA.

Exome sequencing

1 ug of genomic DNA was subjected to a series of shotgun library construction steps, including fragmentation through acoustic sonication (Covaris), end-polishing and A-tailing, ligation of sequencing adaptors and PCR amplification with 8 bp barcodes for multiplexing. Libraries underwent exome capture using the Roche/Nimblegen SeqCap EZ v2.0. Library quality was assessed by triplicate qPCR and molecular weight distributions verified on the Agilent Bioanalyzer (consistently 125 ± 15 bp). Pooled, barcoded libraries were sequenced via paired-end 50 bp reads with an 8 bp barcode read on Illumina HiSeq2000/2500 (RTA 1.13.48.0) sequencers.

BAM files were aligned to a human reference (hg19) using BWA (Burrows-Wheeler Aligner; v0.6.2). Read-pairs not mapping within ± 2 standard deviations of the average library size ($\sim 125 \pm 15$ bp for exomes) were removed. All aligned read data were subject to the following steps: (1) removal of duplicate reads using Picard MarkDuplicates; v1.70 (2) indel realignment with GATK IndelRealigner v1.6-11-g3b2fab9 (3) base qualities recalibration with GATK TableRecalibration; v1.6-11-g3b2fab9. Variant detection and genotyping were performed using the UnifiedGenotyper (UG) tool from GATK (v1.6-11-g3b2fab9) and variants were flagged using the filtration walker (GATK) to mark sites that were of lower quality/false positives [e.g., strand bias ≥ 0.1 , SNPs found in a cluster (3 SNPs in a 10 bp window), low quality scores (Q50), allelic imbalance (ABHet 0.75), long homopolymer runs (HRun > 3) and/or low quality by depth (QD < 5)]. Variants were annotated with the SeattleSeq137 Annotation Server.

While exome analysis is ideally performed on the trio of proband and parents, in this study exome analysis was limited by available samples of sufficient quality and quantity and was performed on the following samples: Family 1 (II-2; II-4; III-1; III-2; III-3), Family 2 (I-1; I-2; II-1; II-2); Family 3 (no exome analysis, mutation identified by Sanger sequencing); Family 4 (II-1); Family 5 (V-2) and Family 6 (II-2) (see Fig. 1).

Confirmatory Studies

Candidate variants were validated using Sanger sequencing of DNA extracted from buccal swabs and PWBC when available. Effect of variants on RNA processing was validated using RT-PCR, and confirmed by standard gel electrophoresis and cDNA sequencing. The Coriell genome-wide human SNP array 6.0 core genotyping service was used in Family 5 to determine the extent of allelic imbalance and copy number variation. Parental origin of the mutation in this proband was determined using allele specific amplification of informative SNPs.

Results

Exome analysis

Under the hypothesis that mutations in a single gene caused the DBA/TCS phenotype, we filtered for genes that had rare (MAF<0.005 in ESP or 1000 Genomes), likely functional (not intronic, intergenic, or UTR) variants in at least three of the five kindreds. Seven genes (*IST1*, *PCDHA9*, *ADRA2B*, *AXDND1*, *LTBP2*, *GRIK3*, and *FBN3*) met these criteria; however none had a convincing connection to known DBA biology. Therefore, we checked each kindred for candidate variants in ribosomal protein genes that segregated with the phenotype.

Family 1

In Family 1, we identified 27 variants that segregated with the DBA/TCS phenotype, e.g. homozygous or hemizygous in the two affected cousins and heterozygous in their obligate carrier mothers. Hence, we focused on a highly conserved (GERP 5.91) missense mutation, p.E64G in *TSR2* (Table II and Supplemental Fig. 1), because its protein product is involved in processing/maturation of rRNA and binds to RPS26. Further, the gene is located on the X chromosome, consistent with phenotypic expression in the males only.

Family 2

In Family 2, we identified a highly conserved (GERP 5.06) nonsense mutation, p.R87*, in *RPS26* (Table II), a gene known to be associated with DBA10. Although this mutation is present in dbSNP (rs148942765), it is not present in 1000 Genomes or the ESP6500. This mutation, which is absent from the unaffected mother, is found in the affected father and his two daughters.

Family 3

An unrelated kindred, Family 3, became available after the exome analysis was performed. Sanger sequencing in the proband identified a de novo 3' splice site mutation in *RPS26*, affecting the adenine in the conserved AG dinucleotide acceptor splice site of intron 1. Indeed, RT-PCR analysis revealed that the variant affects mRNA splicing, with loss of exon 2 resulting in an aberrant gene product (Supplemental Fig. 2).

Families 4 and 5

In Patient 5, we identified a missense variant, *RPL18* p.D10E, which has been previously reported with a minor allele frequency of 0.001 in the ClinSeq population (rs143728553) and was heterozygous in her mother. When we expanded our analysis to include variant calls regardless of GATK filter flags or low coverage (DP<=6), we identified a novel mutation on chromosome 19 in the translation initiation codon of *RPS28* (c.A1G) in unrelated probands from Families 4 (DP=10) and 5 (DP=2). This highly conserved variant (GERP 5.08) was not present in 1000 Genomes or the ESP6500. It was initially excluded from our analyses because it failed the allele balance, quality by depth, and strand bias filters (read depth of 10 and 2, genotype quality of 42.66 and 0.97 in the two probands). However, Sanger sequencing confirmed this de novo variant in PWBC and in buccal cell derived DNA of both patients, suggesting a germline origin for this mutation. Strikingly, Sanger sequencing revealed allelic imbalance, with loss of the mutant allele in Patient 4 PWBC DNA, but not in her buccal cell derived DNA (Supplemental Fig. 3). Though no additional SNPs were present in *RPS28*, by inspecting the vcf files we identified additional imbalanced heterozygous sites in *FBN3* (19p13.3) and *ZNF414* (19p13.2), which were validated by Sanger sequencing. The same phenomenon was observed in Patient 5, though loss of the mutant allele occurred only in the buccal cells (Supplemental Fig. 3). Using heterozygous SNPs found in *FBN3*, *CD320*, *NDUFA7*, *KANK3*, and *ZNF414*, this tissue-specific allelic imbalance was confirmed to extend along 19p13.3-p13.2. *RPL18*, located on 19q13.33, did not show allelic imbalance, thus indicating the phenomenon may be limited to 19p. To test this hypothesis, Family 5's samples underwent SNP microarray analysis. Supplemental figure 4 shows the copy number status, as well as allelic difference in the buccal cell derived DNA. Though no copy number variation was observed along chromosome 19 (Panel A), there is evidence of allelic imbalance in the proband's DNA extending from 19pter to 19p13.2 (Panel B). Compared to 19p in the parental samples, the proband shows a wider or uneven distribution of the heterozygous SNP markers (AB). In contrast, in regions without allelic imbalance such as pericentromeric 19p and 19q, there is a typical display of the homozygous (AA or BB) or heterozygous (AB) calls.

Because a concern for possible Noonan syndrome was raised for Patient 5 due to low-set ears, wide neck and familial ptosis, we searched the exome data for likely pathogenic mutations in rasopathy genes (*PTPN11*; *RAF1*; *SOS1*; *RIT1*; *KRAS*; *HRAS*; *NRAS*; *SHOC2*; *MEK1*; *MEK2*; *BRAF*) and none was found.

Family 6

No likely pathogenic mutation was identified in Patient 6. A review of the exome sequencing data of DBA genes (*RPS19*; *RPS24*; *RPS17*; *RPL35A*; *RPL5*; *RPL11*; *RPS7*; *RPS10*; *RPS26*; *RPL26*; *RPL15*) and MFD genes (*TCOF1*; *POLR1C*; *POLR1D*; *POLR3C*; *EFTUD2*; *SF3B4*; *DHODH*) revealed only a single potentially pathogenic change in *POLR1C* (5'UTR region, c.-15G>A, rs2231757, MAF/MinorAlleleCount: A=0.012/27; GERP 3.25; and polyphen unknown). However, only biallelic *POLR1C* mutations have been found to cause TCS, thus this single mutation is highly unlikely to be pathogenic, regardless of its effect on the protein product.

Discussion

The phenotype combining facial features typical for TCS or MFD with DBA has been reported several times [Hasan and Inoue, 1993; Gripp et al., 2001; McFarren et al., 2007; Handler et al., 2009]. We used exome sequencing to test whether all families studied herein had a mutation in the same gene. However, no single causal gene was found. Rather, we identified likely pathogenic mutations in multiple different genes, including a known DBA gene and two novel DBA genes.

In Family 1, the probands are male cousins whose mothers are sisters. The novel *TSR2* mutation is hemizygous in the proband and his affected cousin, and heterozygous in their mothers, consistent with X-chromosomal inheritance. This mutation has not previously been reported (Table II). *TSR2*, or 20S rRNA accumulation homolog (*S. cerevisiae*), encodes a 191 amino acid pre-rRNA processing protein with amino acids 11 to 92 forming a WGG domain of unknown function. The predicted amino acid change from glutamic acid to glycine is considered “disease causing” by the prediction program mutation taster (www.mutationtaster.org), and the glutamic acid residue located within the WGG domain is highly conserved across different species (Supplemental Fig. 1B). *TSR2* interacts with *RPS26*, as indicated in Genecard (www.genecards.org) and the UniProtKB database (www.uniprot.org). This is relevant because *RPS26* is a known DBA causing gene [Doherty et al., 2010]. Furthermore, we identified pathogenic *RPS26* mutations in Families 2 and 3.

Affected family members in Family 2 share a heterozygous nonsense mutation in *RPS26* predicted to result in a premature termination of the protein product (p.Arg87*). Mutations in *RPS26* account for about 6.4% of patients with DBA, and numerous mutations, including those affecting the start codon and others resulting in frame shifts, were reported by Doherty et al. [2010]. Doherty et al. [2010] mention cleft lip and cleft palate in one individual with a *RPS26* mutation, however this information is absent in the accompanying table listing the patients' findings. Cleft palate in the context of cleft lip is typically considered etiologically distinct from isolated cleft palate or clefting seen in TCS. The mutation present in Family 2 was recently reported by Gerrard et al. [2013] in a DBA patient of Arab ancestry. Interestingly, this patient had choanal and auditory canal atresia, skeletal anomalies and a VSD, similar to the proband in Family 2 reported here. A novel de novo 3' splice site mutation in intron 1 of *RPS26* was present in the proband in Family 3, and mRNA analysis confirmed that the acceptor site mutation resulted in exon 2 skipping and premature termination (Supplemental Fig. 2). Previously, donor splice site mutations in intron 1 and 2 were identified in three DBA patients. Our findings confirm *RPS26*'s role in the phenotype combining DBA and TCS.

A de novo mutation in *RPS28* was identified in Patients 4 and 5. The c.A1G mutation affects the natural AUG translation initiation codon of *RPS28*. Though GUG can be used in eukaryotes as a non AUG start site, it often results in severe inhibition of protein translation leading to haploinsufficiency. Allele specific amplification showed Patient 5's mutation to be of maternal origin. Interestingly, the mutation was partially lost in different cell lineages by a mechanism akin to loss of heterozygosity (LOH), which could be coincidental or may suggest a selective advantage after coincidental loss of this mutation. Allelic imbalance at

19p is observed in a fraction of PWBC in Patient 4, while it is absent in buccal cells. In contrast Patient 5, allelic imbalance at 19p is observed in the buccal cells, but not in PWBC. It is not known whether this tissue specific allelic imbalance contributes to the clinical presentation. Whereas mutations in the *RPS26* start codon have been reported to cause DBA, mutations in *RPS28* have not been associated with human disease. However, *RPS28* interacts with other RPS and RPL proteins and non-ribosomal proteins to generate ribosomes. Experimental depletion of *RPS28* through siRNA resulted in decreased levels of other ribosomal proteins within the same subunit, comparable to the knockdown of *RPS19* [Robledo et al., 2008]. This experimental evidence is consistent with *RPS28* causing DBA through a mechanism similar to *RPS19*.

The reported patients showed extracranial findings, including short stature, cardiac defects, renal abnormalities and the wide neck of Patient 5. While each of these findings is present in a minority of DBA patients, they are all characteristic of the phenotype associated with DBA [Vlachos et al., 2008, Table IV]. Further, because a concern for Noonan syndrome was raised based on the facial features and wide neck in Patient 5, we reviewed the exome analysis data for a mutation consistent with Noonan syndrome and did not identify a pathogenic change. Lastly, we do not consider the reported facial features in Patient 5's distant maternal relative causally related to the proband's presentation or the de novo mutation, but chose to include the information as it was originally obtained and considered consistent with MFD.

Mutations in ribosomal genes, or a gene whose product interacts with a ribosomal protein, are a plausible explanation for the hematologic findings in these patients whose phenotype combines DBA with facial features of TCS. Treacher Collins syndrome is characterized by variable expressivity of malar hypoplasia, downslanting palpebral fissures with lower lid coloboma and medial eye lash deficiency, microtia with hearing loss, mandibular hypoplasia and cleft palate. Most TCS patients have a heterozygous *TCOF1* mutation, while heterozygous *POLRID* and biallelic *POLRIC* mutations account for additional cases [Dauwerse et al., 2011]. The treacle protein encoded by *TCOF1* regulates rRNA transcription by interaction with an upstream binding factor and is essential for recruitment of PolII, the RNA transcriptional machinery [Valdez et al., 2004]. *POLRIC* and *POLRID* encode subunits of RNA polymerases, which in turn are involved in rRNA transcription. The identification of TCS causing mutations in *POLRIC* and *POLRID* confirmed that this phenotype results from abnormal ribosome biosynthesis, and like DBA, TCS is now considered a ribosomopathy [Fisher 2011]. Both, TCS and DBA, have incomplete penetrance and variable expressivity. Patients with DBA may show malformations, and “cleft lip and/or palate” were seen in 9/14 patients with a *RPL5* mutation; in addition, 8/20 with mutated *RPL5* and 8/18 with mutated *RPL11* had thumb abnormalities [Gazda et al., 2008]. Review of photographs of previously published DBA patients suggests that some had craniofacial findings in the TCS spectrum, for example the individual with “absent lower eyelashes, deformed external ears, and micrognathia” shown in Figure 2A in Narla and Ebert [2010]. As the patients reported by Gazda et al. [2008] were ascertained through a DBA registry, information on physical findings is limited. In combination with the previously published reports on single patients with DBA and TCS/MFD findings, this

information illustrates the notable overlap between conditions originally defined by their hematologic and physical phenotype, respectively. It is thus not surprising that, contrary to our expectations, we did not identify a single gene responsible for the combined phenotype of DBA and TCS/MFD, but rather several genes with likely pathogenic mutations. As shown in Table II, these genes include a known DBA gene, *RPS26*; a X-chromosomal gene encoding a binding partner of *RPS26*, *TSR2*; and *RPS28* with a recurrent mutation in two unrelated probands. These genes share in common that their products are likely involved in ribosome biogenesis. Perturbed ribosome function underlies congenital disorders predominantly affecting different organ systems, such as pancreatic insufficiency and bone marrow failure in Shwachman-Diamond syndrome, liver in North American Indian childhood cirrhosis [Freed et al., 2012], spleen in isolated congenital asplenia [Bolze et al., 2013], bone marrow in Diamond-Blackfan anemia and craniofacial bones in Treacher Collins syndrome. In order to explain these phenotypic variations amongst different ribosomopathies, McCann and Baserga [2013] suggested that the composition of ribosomes may vary between different cell types, which in turn would account for the various effects of ribosomal protein haploinsufficiency.

The MFDs share in common the facial features, but result for mutations in different genes. Since our study did not identify pathogenic mutations in genes causally associated with TCS, and the patients craniofacial and bony features have been referred to as TCS or MFD in publications, we think that MFD is a more appropriate term to describe the patients' facial findings. Of note, the MFDs Nager syndrome (*SF3B4* related) [Bernier et al., 2012] and MFD with microcephaly (*EFTUD2*) [Lines and et., 2012] have now been characterized as spliceosomopathies. Like ribosome biosynthesis, splicing is critically important for protein synthesis, suggesting this may be the common limiting factor resulting in the craniofacial deficiencies.

Limitations of this study

As in all clinical studies, our work was limited by the patients' and families' preference for sample collection and use of information for publication. Tissues other than the blood and cheek swab derived DNA in Families 4 and 5 could not be studied for allelic imbalance of the de novo mutation because samples are not available. Functional studies of the newly identified and presumably disease causing genes would strengthen the evidence for pathogenicity, but is at this time out of our purview.

Conclusions

The phenotype combining features of TCS with DBA is genetically heterogeneous. It can be caused by mutations in *RPS26* or *RPS28*, which result in haploinsufficiency for the functional gene product. *TSR2*, a X-chromosomal gene encoding a direct binding partner of *RPS26*, may be responsible for the phenotype in one family with a mutation affecting a highly conserved residue. The hematologic consequences and the facial features, as well associated skeletal malformations and growth retardation, are likely a direct consequence of abnormal ribosome biogenesis resulting from the respective mutations. These conditions are thus considered ribosomopathies. Variable expressivity for DBA and TCS has previously been recognized, and this encompasses the phenotype combining both conditions.

Supplementary Material

Refer to Web version on PubMed Central for supplementary material.

Acknowledgments

We thank the patients and their families for sharing this information. Families 1 and 4 were in the past evaluated by Dr. Elaine Zackai. We thank the Center for Pediatric Research COBRE-funded Biomolecular Core for sequencing support. This work was supported in part by the Nemours Foundation to KWG, and by the NIH-NIGMS grants P20GM103464 and grant P20GM103446 to KSC.NIH – National Human Genome Research Institute grant U54 HG006493 (to the University of Washington Mendelian Genomics Center).

References

- Abecasis GR, Auton A, Brooks LD, DePristo MA, Durbin RM, Handsaker RE, Kang HM, Marth GT, McVean GA. 1000 Genomes Project Consortium. An integrated map of genetic variation from 1,092 human genomes. *Nature*. 2012; 491:56–65. [PubMed: 23128226]
- Adzhubei IA, Schmidt S, Peshkin L, Ramensky VE, Gerasimova A, Bork P, Kondrashov AS, Sunyaev SR. A method and server for predicting damaging missense mutations. *Nat Methods*. 2010; 7:248–249. [PubMed: 20354512]
- Bernier FP, Caluseriu O, Ng S, Schwartztruber J, Buckingham KJ, Innes AM, Jabs EW, Innis JW, Schuette JL, Gorski JL, Byers PH, Andelfinger G, Siu V, Lauzon J, Fernandez BA, McMillin M, Scott RH, Racher H, FORGE Canada Consortium. Majewski J, Nickerson DA, Shendure J, Bamshad MJ, Parboosingh JS. Haploinsufficiency of SF3B4, a component of the pre-mRNA spliceosomal complex, causes Nager syndrome. *Am J Hum Genet*. 2012; 90:925–933. [PubMed: 22541558]
- Bolze A, Mahlaoui N, Byun M, Turner B, Trede N, Ellis SR, Abhyankar A, Itan Y, Patin E, Brebner S, Sackstein P, Puel A, Picard C, Abel L, Quintana-Murci L, Faust SN, Williams AP, Baretto R, Duddridge M, Kini U, Pollard AJ, Gaud C, Frange P, Orbach D, Emile JF, Stephan JL, Sorensen R, Plebani A, Hammarstrom L, Conley ME, Selleri L, Casanova JL. Ribosomal protein SA haploinsufficiency in humans with isolated congenital asplenia. *Science*. 2013; 340:976–978. [PubMed: 23579497]
- Clinton C.; Gazda, HT. Diamond-Blackfan Anemia. 2009 Jun 25 [Updated 2013 Jul 25]. In: Pagon, RA.; Adam, MP.; Bird, TD., et al., editors. *GeneReviews™* [Internet]. Seattle (WA): University of Washington, Seattle; 1993-2013. Available from: <http://www.ncbi.nlm.nih.gov/books/NBK7047/>
- Cooper GM, Stone EA, Asimenos G, NISC Comparative Sequencing Program. Green ED, Batzoglu S, Sidow A. Distribution and intensity of constraint in mammalian genomic sequence. *Genome Res*. 2005; 15:901–913. [PubMed: 15965027]
- Dauwerse JG, Dixon J, Seland S, Ruivenkamp CA, van Haeringen A, Hoefsloot LH, Peters DJ, Boers AC, Daumer-Haas C, Maiwald R, Zweier C, Kerr B, Cobo AM, Toral JF, Hoogeboom AJ, Lohmann DR, Hehr U, Dixon MJ, Breuning MH, Wieczorek D. Mutations in genes encoding subunits of RNA polymerases I and III cause Treacher Collins syndrome. *Nat Genet*. 2011; 43:20–22. [PubMed: 21131976]
- Doherty L, Sheen MR, Vlachos A, Choessel V, O'Donohue MF, Clinton C, Schneider HE, Sieff CA, Newburger PE, Ball SE, Niewiadomska E, Matysiak M, Glader B, Arceci RJ, Farrar JE, Atsidaftos E, Lipton JM, Gleizes PE, Gazda HT. Ribosomal protein genes RPS10 and RPS26 are commonly mutated in Diamond-Blackfan anemia. *Am J Hum Genet*. 2010; 86:222–228. [PubMed: 20116044]
- Fisher E. Exploring the genetic origins of Treacher Collins syndrome. *Clin Genet*. 2011; 79:330–332. [PubMed: 21261602]
- Freed EF, Prieto JL, McCann KL, McStay B, Baserga SJ. NOL11, implicated in the pathogenesis of North American Childhood Cirrhosis, is required for pre-rRNA transcription and processing. *PLOS*. 2012; 8:e1002892.10.1371/journal.pgen.1002892
- Gazda HT, Sheen MR, Vlachos A, Choessel V, O'Donohue MF, Schneider H, Darras N, Hasman C, Sieff CA, Newburger PE, Ball SE, Niewiadomska E, Matysiak M, Zaucha JM, Glader B, Niemeyer C, Meerpohl JJ, Atsidaftos E, Lipton JM, Gleizes PE, Beggs AH. Ribosomal protein L5

- and L11 mutations are associated with cleft palate and abnormal thumbs in diamond-Blackfan anemia patients. *Am J Hum Genet.* 2008; 83:769–780. [PubMed: 19061985]
- Gerrard G, Valgañón M, Foong HE, Kasperaviciute D, Iskander D, Game L, Müller M, Aitman TJ, Roberts I, de la Fuente J, Foroni L, Karadimitris A. Target enrichment and high-throughput sequencing of 80 ribosomal protein genes to identify mutations associated with Diamond-Blackfan anaemia. *Br J Haematol.* 2013; 162:530–536. [PubMed: 23718193]
- Gripp KW, McDonald-McGinn DM, LaRossa D, McGain D, Federman N, Vlachos A, Glader BE, McKenzie SE, Lipton JM, Zackai EH. Bilateral Microtia and Cleft Palate in Cousins with Diamond-Blackfan Anemia. *Am J Med Genet.* 2001; 101:268–274. [PubMed: 11424144]
- Handler MZ, Alabi O, Miller J. Curvilinear mandibular distraction in a patient with mandibulofacial dysostosis associated with Diamond-Blackfan Anemia. *J Craniofac Surg.* 2009; 20:1417–1419. [PubMed: 19816270]
- Hasan R, Inoue S. Diamond-Blackfan anemia associated with Treacher Collins syndrome. *Pediatr Hemato Oncol.* 1993; 10:261–265.
- Katsanis, SH.; Jabs, EW. Treacher Collins Syndrome. 2004 Jul 20 [Updated 2012 Aug 30]. In: Pagon, RA.; Adam, MP.; Bird, TD., editors. *GeneReviews™* [Internet]. Seattle (WA): University of Washington, Seattle; 1993-2013. Available from: <http://www.ncbi.nlm.nih.gov/books/NBK1532/>
- Kumar P, Henikoff, Ng PC. Predicting the effects of coding non-synonymous variants on protein function using the SIFT algorithm. *Nat Protoc.* 2009; 4:1073–1081. [PubMed: 19561590]
- Lines MA, Huang L, Schwartzenruber J, Douglas SL, Lynch DC, Beaulieu C, Guion-Almeida ML, Zechi-Ceide RM, Gener B, Gillissen-Kaesbach G, Nava C, Baujat G, Horn D, Kini U, Caliebe A, Alanay Y, Utine GE, Lev D, Kohlhase J, Grix AW, Lohmann DR, Hehr U, Böhm D, FORGE Canada Consortium. Majewski J, Bulman DE, Wieczorek D, Boycott KM. Haploinsufficiency of a spliceosomal GTPase encoded by EFTUD2 causes mandibulofacial dysostosis with microcephaly. *Am J Hum Genet.* 2012; 90:369–377. [PubMed: 22305528]
- McCann KL, Baserga SJ. Mysterious ribosomopathies. *Science.* 2013; 341:849–850. [PubMed: 23970686]
- McFarren A, Jayabose S, Fevzi Ozkaynak M, Tugal O, Sandoval C. Cleft palate, bilateral external auditory canal atresia, and other midline defects associated with Diamond-Blackfan anemia: case report. *J Pediatr Hematol Oncol.* 2007; 29:338–340. [PubMed: 17483715]
- Narla A, Ebert BL. Ribosomopathies: Human disorders of ribosome dysfunction. *Blood.* 2010; 115:3196–3205. [PubMed: 20194897]
- Robledo S, Idol RA, Crimmins DL, Ladenson JH, Mason PJ, Bessler M. The role of human ribosomal proteins in the maturation of rRNA and ribosome production. *RNA.* 2008; 14:1918–19129. [PubMed: 18697920]
- Valdez BC, Henning D, So RB, Dixon J, Dixon MJ. The Treacher Collins syndrome (TCOF1) gene product is involved in ribosomal DNA gene transcription by interacting with upstream binding factor. *Proc Natl Acad Sci USA.* 2004; 101:10709–10714. [PubMed: 15249688]
- Vlachos A, Ball S, Dahl N, Alter BP, Sheth S, Ramenghi U, Meerpohl J, Karlsson S, Liu JM, Leblanc T, Paley C, Kang EM, Leder EJ, Atsidaftos E, Shimamura A, Bessler M, Glader B, Lipton JM. Diagnosing and treating Diamond Blackfan anaemia: results of an international clinical consensus conference. *Brit J Haematol.* 2008; 142:859–876. [PubMed: 18671700]

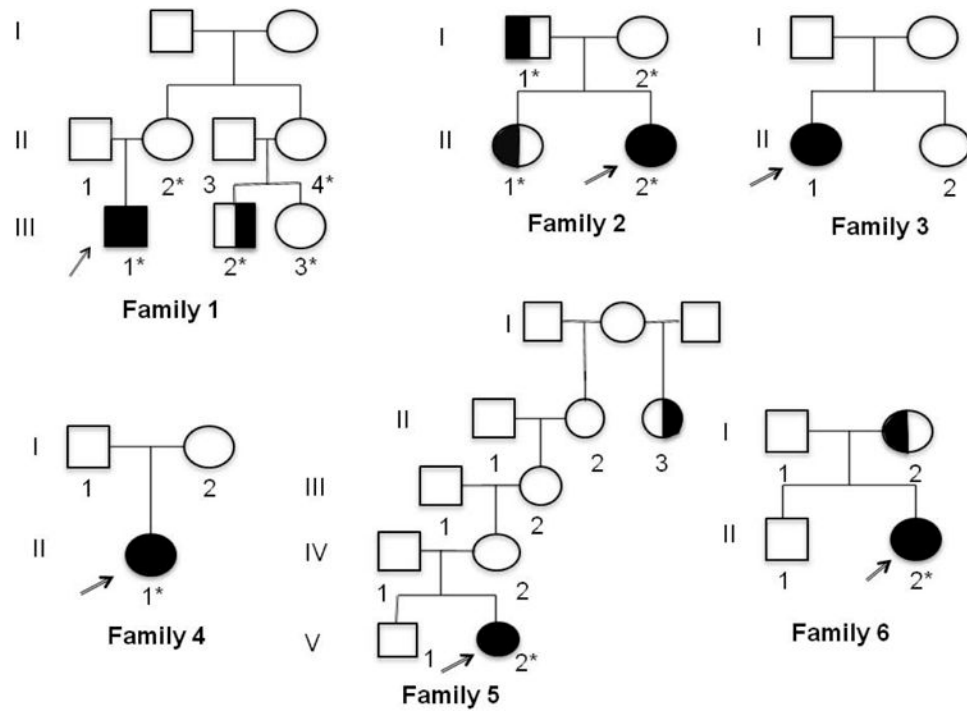


Figure 1.

Abbreviated pedigrees of Families 1-6.

■: Male with overt Diamond-Blackfan anemia

◼: Male with facial features suggestive of Treacher Collins syndrome, such as bilateral microtia, micrognathia, cleft palate, midfacial hypoplasia and downslanting palpebral fissures.

*denotes individuals in whom exome analysis was performed.

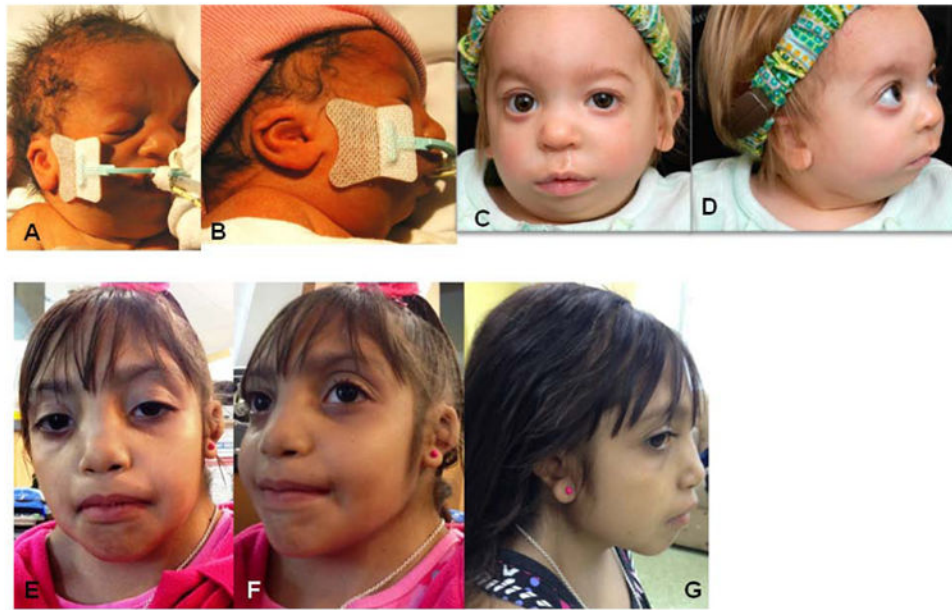

Figure 2. Facial photographs of Patient 2 (Family 2, II-2) as neonate (A, B) and at age 15 months (C,D) after mandibular distraction osteotomy, note micrognathia, low set posteriorly angulated right ear and hearing aid. Facial photographs of Patient 3 (Family 3, II-1) at age 8 years (E, F, G), note microtia, midfacial hypoplasia, and wide neck.

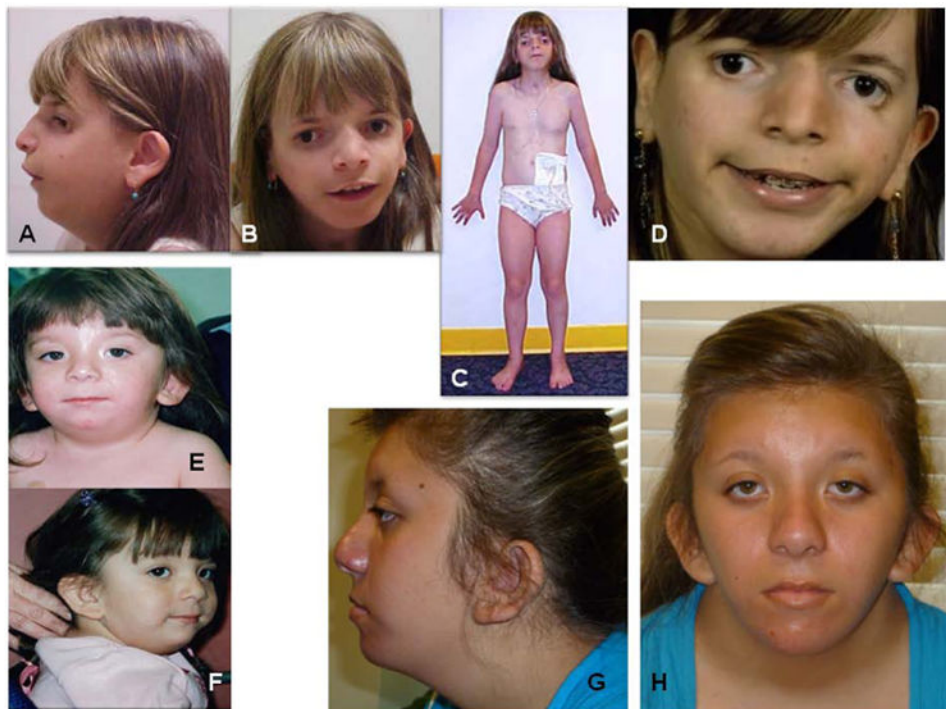


Figure 3. Facial photographs of Patient 4 (Family 4, II-1) at age 11 (A-C) and 13 years (D). Note micrognathia, low set left ear, downslanting palpebral fissures, absence of lashes at medial rim of lower lid; and multiple scars and gastric tube shown in C. Facial photographs of Patient 5 (Family 5, V-2) as infant (E, F) and at age 14 years (G,H), note mild micrognathia, low set, posteriorly angulated and mildly cupped ears, hairline extending anterior to the ears, epicanthal folds and wide neck.

Table 1

Phenotypic Findings in Probands and Affected Family Members

	Family 1 III-1	Family 1 III-2	Family 2 I-1	Family 2 II-1	Family 2 II-2	Family 3 II-1	Family 4 II-1	Family 5 V-2	Family 6 I-2	Family 6 II-1
Macrocytic anemia	+	-	+	+	+	+	+	+	+	+
Microtia/atretic external canals	+	+	-	-	+	+	+	Small canals	-	+
Hearing Loss	+	+	-	-	+	+	+	+	-	+
Downslanting palpebral fissures	+	+	-	-	-	-	+	+	-	+
Micrognathia	+	+	-	-	+	-	+	+	-	+
Cleft palate/uvula Submucous cleft	+	+	-	-	+	+	+	+	-	-
Malar hypoplasia	+	+	-	-	+	+	+	+	-	-
Choanal atresia	-	-	-	-	+	-	-	-	-	-
CHD/ASD/VSD	-	-	-	-	VSD	VSD	-	-	-	VSD
Diaphragmatic hernia/Morgagni	-	-	-	-	-	+	+	-	-	-
Genito-urinary anomalies	Cryptorchidism	-	-	-	Duplicated kidney	Renal ectopia	-	-	-	-
Skeletal anomaly	-	-	-	-	13 rib pairs	-	Thumbs	Wide neck	-	-
Short stature	-	-	-	-	+	+	+	+	-	+
Developmental Delay/ID	-	-	-	-	-	-	+	mildly	-	+

Legend: - absent; + present

Overview of Molecular Results

Table II

	Gene	Mutation	dbSNP137	ESP/1000 Genomes	De novo/familial	Known DBA gene?	Polyphen score	SIFT score	GERP score	Comments
Patient 1/Family 1	<i>TSR2</i>	ChrX: 54469851 c.191A>G p.Glu64Gly	None	Not found	Familial, present in affected cousins	No	1.0 (Probably damaging)	0 (Damaging)	5.91	X-linked gene; TSR2 interacts with RPS26
Patient 2/Family 2	<i>RPS26</i>	Chr12:56437224 c.259C>T p.Arg87*	rs148942765	Not found	Familial, segregates with DBA	Yes	N/A	N/A	5.060	Identical mutation reported in Gerrard et al. [2013]
Patient 3/Family 3	<i>RPS26</i>	Chr12:56436207 c.4-2A>T	None	Not known	De novo	Yes	N/A	N/A	1.88	Novel splice site mutation results in exon skipping and early termination
Patient 4/Family 4	<i>RPS28</i>	Chr19:8386415 c.1A>G p.Met1Val	None	Not Found	De novo	No	0.76 (Possibly damaging)	0.055 (Tolerated)	5.080	Allelic imbalance in peripheral white blood cells
Patient 5/Family 5	<i>RPS28</i>	Chr19:8386415 c.1A>C p.Met1Val	None	Not found	De novo	No	0.76 (Possibly damaging)	0.055 (Tolerated)	5.080	Allelic imbalance in cheek swab derived DNA

Legend: ESP: NHLBI Grand Opportunity Exome Sequencing Project (<http://evs.gs.washington.edu/EVS/>)[1000 Genomes Project et al., 2112].

Polyphen score as per Adzhubei et al. [2010]. SIFT score as per Kumar et al. [2009]. GERP scores as per Cooper et al. [2005]. N/A: Not available.