

Published in final edited form as:

Circulation. 2002 July 9; 106(2): 180–183.

Positron Emission Tomography Imaging of Cardiac Reporter Gene Expression in Living Rats

Joseph C. Wu, MD, Masayuki Inubushi, MD, Gobalakrishnan Sundaresan, PhD, Heinrich R. Schelbert, MD, and Sanjiv S. Gambhir, MD, PhD

Crump Institute for Molecular Imaging (J.C.W., G.S., S.S.G.); Department of Molecular and Medical Pharmacology (J.C.W., M.I., G.S., H.S., S.S.G.); Jonsson Comprehensive Cancer Center (S.S.G.); and Department of Medicine, Division of Cardiology (J.C.W.), UCLA School of Medicine, Los Angeles, Calif.

Abstract

Background—Imaging reporter gene expression is useful for noninvasive monitoring of gene therapy. In this study, we imaged cardiac reporter gene expression in living rats using micro positron emission tomography (microPET).

Methods and Results—Rats (n=10) underwent intramyocardial injection with 1×10^9 pfu of adenovirus carrying cytomegalovirus promoter-driving herpes simplex virus type 1 mutant thymidine kinase (Ad-CMV-HSV1-sr39tk) as PET reporter gene. Control rats (n=4) received 1×10^9 pfu of adenovirus carrying cytomegalovirus promoter-driving firefly luciferase (Ad-CMV-Fluc). On days 2 to 4, microPET images were obtained after a tail vein injection of nitrogen-13 ammonia ($[^{13}\text{N}]\text{-NH}_3$) as myocardial perfusion tracer, followed by 9-(4- $[^{18}\text{F}]\text{-fluoro-3}$ hydroxymethylbutyl) guanine ($[^{18}\text{F}]\text{-FHBG}$) to assess HSV1-sr39tk expression. After imaging, hearts were removed for ex vivo $[^{18}\text{F}]$ gamma counting and thymidine kinase enzyme assay. Results show homogenous myocardial distribution of $[^{13}\text{N}]\text{-NH}_3$ on all microPET images. Rats injected with Ad-CMV-HSV1-sr39tk have significant $[^{18}\text{F}]\text{-FHBG}$ uptake in the anterolateral wall compared with background signal in controls. Gamma counting shows 20.0 ± 4.4 -fold increase of radioactivity, whereas enzyme assay shows 22.1 ± 6.1 -fold increase of thymidine kinase activity in Ad-CMV-HSV1-sr39tk injected rats ($P < 0.05$).

Conclusions—Successful imaging of cardiac HSV1-sr39tk expression was performed in living rats with microPET. The presence of $[^{18}\text{F}]\text{-FHBG}$ uptake is confirmed by gamma counting and the presence of HSV1-sr39TK protein by thymidine kinase enzyme assay. Cardiac reporter gene imaging by PET may eventually be applied toward human gene therapy studies.

Keywords

gene therapy; viruses; heart diseases; imaging; nuclear medicine

Gene therapy holds much promise as a potential treatment for various cardiovascular diseases. These treatments include prevention of restenosis after angioplasty, promotion of angiogenesis, and treatment for end-stage heart failure.¹ Analysis of gene transfer often relies on subjective symptom improvement in clinical studies or postmortem histology in animal studies. Therefore, the development of noninvasive multi-modality imaging approaches for monitoring gene transfer is needed.

Methods of imaging gene expression in living animals include positron emission tomography (PET), single photon emission computed tomography (SPECT), MRI, optical bioluminescent imaging, and optical fluorescent imaging. Each modality has its own advantages and disadvantages. A detailed review is reported elsewhere.² Recently, we have demonstrated the feasibility of monitoring cardiac³ and skeletal⁴ reporter gene expression using optical bioluminescent imaging. This approach allows rapid analysis of gene delivery and expression, but is currently limited to small animal imaging.

In contrast, PET imaging offers tomographic as well as quantitative information and can be used to assess several variables (eg, metabolism, perfusion). We have been developing methods for monitoring reporter gene expression by using herpes simplex virus type 1 mutant thymidine kinase (HSV1-sr39tk) as a PET reporter gene and 9-(4-[¹⁸F]-fluoro-3-hydroxymethylbutyl) guanine ([¹⁸F]-FHBG) as a PET reporter probe in animal models.⁵ The HSV1-sr39tk gene encodes for a mutant thymidine kinase enzyme that phosphorylates and accumulates [¹⁸F]-FHBG intracellularly, which can be imaged by microPET (Figure 1A, insert). By linking a therapeutic gene with a reporter gene, one can indirectly infer the location, magnitude, and duration of therapeutic gene expression by imaging the reporter protein.²

To date, no cardiac gene transfer studies have been done using PET imaging. We now present the first in vivo study demonstrating the feasibility of imaging cardiac reporter gene expression in living rats.

Methods

Construction of Recombinant Adenoviruses

Construction and purification of replication-defective adenovirus carrying cytomegalovirus promoter-driving herpes simplex virus type 1 mutant thymidine kinase (Ad-CMV-HSV1-sr39tk) and of the control adenovirus carrying cytomegalovirus promoter-driving firefly luciferase (Ad-CMV-Fluc) viruses have been described previously.^{4,5} Henceforth, the thymidine kinase gene and enzyme are referred to as “HSV1-sr39tk” and “HSV1-sr39TK,” respectively.

Myocardial Injection of Adenoviruses

Fifteen Sprague-Dawley rats (weighing 250 to 350 g; Charles River Laboratories, Wilmington, Mass) were studied under protocols approved by the University Committee on the Use and Care of Animals. Rats received a 4:1 mixture of ketamine (80 mg/kg) and xylazine (10 mg/kg) intraperitoneally for anesthesia, banamine (2.5 mg/kg) for pain relief, atropine (40 µg/kg) for prevention of bradycardia, and normal saline (3 to 4 mL) for volume

replacement. Anesthetized rats were mechanically ventilated before aseptic left thoracotomy. The anterolateral wall of the left ventricular myocardium was injected with 1×10^9 pfu of Ad-CMVHSV1-sr39tk (n=11) and Ad-CMV-Fluc viruses (n=4) using a 30-gauge needle containing 30 to 50 μ L of viral volume. Except for one rat injected with Ad-CMV-HSV1-sr39tk that died perioperatively, all animals recovered uneventfully.

PET Imaging of Cardiac Reporter Gene Expression

Two to 4 days after viral injection, rats were anesthetized with pentobarbital (40 mg/kg) and imaged using a microPET scanner developed at the Crump Institute for Molecular Imaging.⁶ Perfusion tracer nitrogen-13 ammonia ($[^{13}\text{N}]\text{-NH}_3$) (2.65 ± 0.68 mCi) was injected via the tail vein, and the rat was imaged for 10 minutes to identify the position of and perfusion to the myocardium. After 30 minutes to allow for $[^{13}\text{N}]\text{-NH}_3$ decay, rats were injected with $[^{18}\text{F}]\text{-FHBG}$ (1.82 ± 0.47 mCi), synthesized as described previously.⁷ Images from 50 to 60 minutes post- $[^{18}\text{F}]\text{-FHBG}$ injection were reconstructed by filtered back projection and were reoriented into short, vertical, and horizontal long axis slices. From regions of interest (ROI) on the anterolateral wall (short axis cut), derived counts/pixel per min were converted to counts/mL per min using a calibration constant obtained from scanning a cylindrical phantom. The ROI counts/mL per min were converted to counts/g per min (assuming a tissue density of 1 g/mL) and divided by the injected dose to obtain an image ROI-derived $[^{18}\text{F}]\text{-FHBG}$ percentage injected dose per gram of heart (% ID/g). No corrections were made for partial volume or attenuation.⁶

Gamma Counting of $[^{18}\text{F}]$ Radioactivity in Explanted Heart

After completion of microPET imaging, the animals were killed and the hearts were removed and rinsed clean of blood before well counting (Cobra II Auto-Gamma) for $[^{18}\text{F}]$ radioactivity.⁵

Thymidine Kinase Enzyme Assays

Cardiac tissues were homogenized and enzyme activity was determined as described.⁵ Rat glioma (C6) and C6 HSV1-sr39tk stable transfectant cells (C6-stb-sr39tk+) served as negative and positive control for HSV1-sr39TK assay, respectively. The growth conditions for both cell lines have been described.⁵ The radioisotope 8- $[^3\text{H}]\text{penciclovir}$ (8- $[^3\text{H}]\text{PCV}$) (11 Ci/mmol) was obtained from Moravek Biochemicals. Results are expressed as percent conversion of 8- $[^3\text{H}]\text{PCV}$ in (dpm/ μ g protein per min of cell or tissue extract)/ (dpm of control sample) $\times 100$.⁵

Data Analysis

Data are given as mean \pm SEM. For statistical analysis, the 2-tailed Student's *t* test was used. Differences were considered significant at $P < 0.05$.

Results

MicroPET Imaging of Cardiac Reporter Gene Expression

Figure 1A shows the whole-body image of a rat 4 days after cardiac injection of Ad-CMV-HSV1-sr39tk. [^{18}F]-FHBG uptake is present in the heart. Because of systemic viral leakage and subsequent hepatic transduction, however, [^{18}F]-FHBG activity is also seen in the liver. The control rat shows no cardiac or hepatic [^{18}F]-FHBG activity. Figure 1B shows tomographic views of the heart in short, vertical, and horizontal long axis. [^{13}N]- NH_3 distributes homogeneously in the myocardium of all rats. Rats injected with Ad-CMV-HSV1-sr39tk show significant [^{18}F]-FHBG activity in the anterolateral wall compared with background signals seen in control Ad-CMV-Fluc rats. ROI-derived myocardial [^{18}F]-FHBG activity differs significantly between experimental ($0.72 \pm 0.09\%$ ID/g) and control rats ($0.08 \pm 0.03\%$ ID/g) ($P < 0.001$). Hepatic [^{18}F]-FHBG activity was also higher in rats injected with Ad-CMV-HSV1-sr39tk ($1.72 \pm 0.51\%$ ID/g) than in control rats ($0.14 \pm 0.04\%$ ID/g; $P < 0.01$).

Confirmation of MicroPET Imaging With Ex Vivo Gamma Counting and Thymidine Kinase Enzyme Assays

Myocardial [^{18}F] radioactivity differs significantly between rats injected with Ad-CMV-HSV1-sr39tk ($0.15 \pm 0.03\%$ ID/g) and control rats ($0.01 \pm 0.002\%$ ID/g), representing a 20.0 ± 4.4 -fold increase ($P < 0.05$). To confirm intracellular HSV1-sr39tk expression on microPET images, HSV1-sr39TK enzyme activity from homogenized heart tissues also varies significantly between experimental ($0.45 \pm 0.17\%$ conversion/ μg protein per min) and control rats ($0.02 \pm 0.01\%$ conversion/ μg protein per min), representing a 22.1 ± 6.1 -fold increase ($P < 0.05$; Table).

Discussion

Initial autoradiography studies of euthanized rats by Bengel et al⁸ detected uptake of 2'-fluoro-2'-deoxy-5-iodo-1- β -D-arabinofuranosyluracil ([^{125}I]FIAU) radioisotopes in myocardium transduced with adenoviral-mediated HSV1-tk reporter gene. The authors hypothesized that in vivo cardiac gene imaging is feasible. We now report the first demonstration of cardiac reporter gene imaging using PET in living experimental animals. Rat myocardium was transduced surgically under direct visualization. Two to 4 days later, [^{13}N]- NH_3 (perfusion tracer) and [^{18}F]-FHBG (PET reporter probe) were injected before microPET imaging. Homogeneous distribution of [^{13}N]- NH_3 is seen in all rats, as expected. Significant [^{18}F]-FHBG signal is seen in the anterolateral wall of experimental rats on tomographic images. Control rats injected with Ad-CMV-Fluc show background signal only. Myocardial [^{18}F]-FHBG uptake in experimental rats is confirmed by gamma counting. Expression of myocardial HSV1-sr39TK protein specific for rats injected with Ad-CMV-HSV1-sr39tk is confirmed by thymidine kinase enzyme assay.

PET offers several advantages over SPECT, MRI, and optical approaches for imaging reporter gene expression. First, PET imaging is highly sensitive; as low as 10^{-12} mol/L of radiolabeled reporter probe can be detected.⁶ This may allow monitoring of gene delivery by

vectors with relatively weak promoters (eg, tissue specific) or low transduction efficiency (eg, plasmid DNA). Second, PET imaging is quantitative. Because myocardial radioactivity can be measured, dynamic imaging with tracer kinetic modeling should provide for an analysis of the rate constants of the underlying biochemical processes. Third, PET imaging is tomographic, so a relatively precise location of gene expression can be identified. In general, a clinical PET scanner has a resolution of $\approx (6 \text{ to } 8)^3 \text{ mm}^3$, whereas microPET has $\approx 2^3 \text{ mm}^3$ resolution.⁶

Our study focused on the initial development of microPET imaging for cardiac applications. We performed relative but not absolute quantification of [¹⁸F]-FHBG activity because the latter would require correction for myocardial wall size, photon attenuation, and dynamic imaging for tracer kinetic modeling using time-activity data.⁶ As expected, the in vivo ROI-derived [¹⁸F]-FHBG activity established by microPET was higher compared with ex vivo [¹⁸F] activity from gamma counting because ROI was drawn only over the anterolateral wall compared with gamma counting of the whole explanted heart. Studies exploring absolute quantification are needed to correlate levels of HSV1-sr39TK with [¹⁸F]-FHBG phosphorylation rates. In our experiment, we used mutant HSV1- sr39tk as a PET reporter gene and [¹⁸F]-FHBG as a PET reporter probe. This combination has improved imaging sensitivity compared with HSV1-tk and [¹⁸F]-FHBG, although imaging with HSV1-tk and [¹²⁴I]-FIAU is also possible.^{2,5} Direct comparisons will be needed for each approach, including detection thresholds for various viral titers and dosage analysis of each PET reporter probe.

In our study, we also observed significant [¹⁸F]-FHBG uptake within the liver at days 2 to 4, which was likely due to the quality of cardiac injection with egress of adenovirus from the myocardium into the systemic circulation and eventual binding to coxsackie-adenovirus receptors on hepatocytes.³ Substituting a cardiac tissue-specific promoter (eg, myosin light chain kinase) for the constitutive CMV promoter may diminish extra-cardiac activity. Finally, the E1-deleted adenovirus have been shown to elicit a strong host immune response, which may hamper longitudinal imaging of reporter gene expression.⁹ For these reasons, we are currently exploring non-immunogenic lentivirus vectors with cardiac-specific promoters driving both bioluminescent (firefly luciferase) and PET reporter genes (HSV1-sr39tk), which can be chronically co-expressed and repetitively imaged. The goal is to rapidly evaluate any vector or gene of interest first by optical imaging and then to finalize the validation by microPET imaging before advancing to human studies using clinical PET scanners.

In summary, reliable assessment of gene transfer remains a major challenge in the field of cardiac gene therapy. We have demonstrated noninvasive monitoring of cardiac reporter gene expression by microPET imaging. Further validation and refinement of the approaches described should help to transition reporter gene imaging into routine clinical applications with PET.

Acknowledgments

This work was supported by funds from Department of Energy contract DE-FC03-87ER60615 (Dr Gambhir), National Institute of Health RO1 CA82214-01 (Dr Gambhir), Small Animal Imaging Resource Program R24

CA92865 (Dr Gambhir), and American Heart Association Western Affiliate postdoctoral grant (Dr Wu). We thank the UCLA cyclotron crew for their technical assistance and Dr Arion Chatziioannou for help with image reconstruction.

References

1. Hajjar RJ, del Monte F, Matsui T, et al. Prospects for gene therapy for heart failure. *Circ Res.* 2000; 86:616–621. [PubMed: 10746995]
2. Ray P, Bauer E, Iyer M, et al. Monitoring gene therapy with reporter gene imaging. *Semin Nucl Med.* 2001; 31:312–320. [PubMed: 11710773]
3. Wu JC, Inubushi M, Sundaresan G, et al. Optical imaging of cardiac reporter gene expression in living rats. *Circulation.* 2002; 105:1631–1634. [PubMed: 11940538]
4. Wu JC, Sundaresan G, Iyer M, et al. Noninvasive optical imaging of firefly luciferase reporter gene expression in skeletal muscles of living mice. *Mol Ther.* 2001; 4:297–306. [PubMed: 11592831]
5. Gambhir SS, Bauer E, Black ME, et al. A mutant herpes simplex virus type 1 thymidine kinase reporter gene shows improved sensitivity for imaging reporter gene expression with positron emission tomography. *Proc Natl Acad Sci U S A.* 2000; 97:2785–2790. [PubMed: 10716999]
6. Cherry SR, Gambhir SS. Use of positron emission tomography in animal research. *ILAR J.* 2001; 42:219–232. [PubMed: 11406721]
7. Yaghoubi S, Barrio JR, Dahlbom M, et al. Human pharmacokinetic and dosimetry studies of [(18)F]FHBG: a reporter probe for imaging herpes simplex virus type-1 thymidine kinase reporter gene expression. *J Nucl Med.* 2001; 42:1225–1234. [PubMed: 11483684]
8. Bengel FM, Anton M, Avril N, et al. Uptake of radiolabeled 2'-fluoro-2'-deoxy-5-iodo-1-beta-d-arabinofuranosyluracil in cardiac cells after adenoviral transfer of the herpesvirus thymidine kinase gene: the cellular basis for cardiac gene imaging. *Circulation.* 2000; 102:948–950. [PubMed: 10961956]
9. Yang Y, Li Q, Ertl HC, et al. Cellular and humoral immune responses to viral antigens create barriers to lung-directed gene therapy with recombinant adenoviruses. *J Virol.* 1995; 69:2004–2015. [PubMed: 7884845]

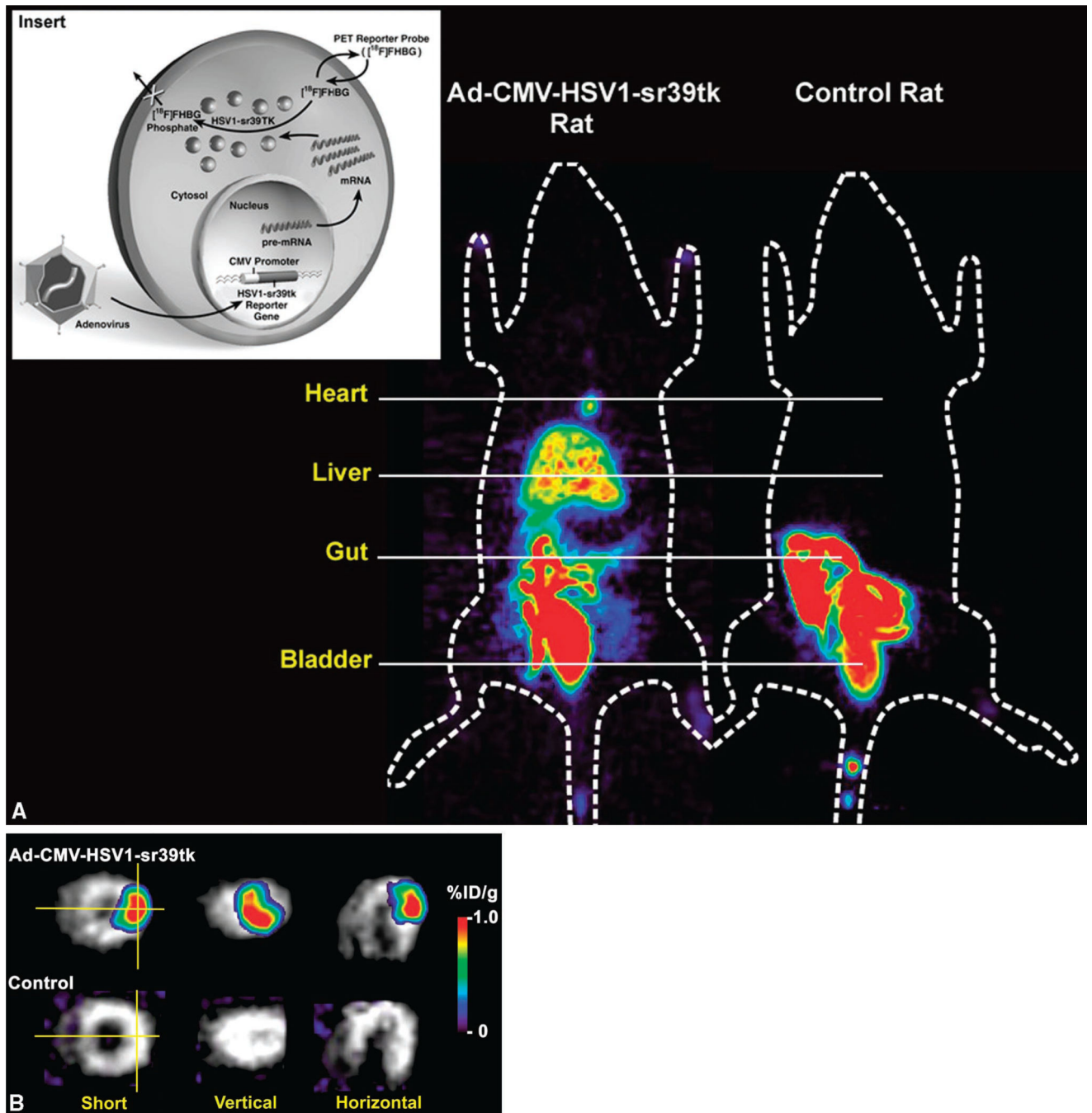


Figure 1. Insert, Imaging cardiac gene expression using adenoviral-mediated mutant thymidine kinase (HSV1-sr39tk) as PET reporter gene and $[^{18}\text{F}]\text{-FHBG}$ as PET reporter probe. Trapping of tracer occurs only in cells expressing the reporter gene. A, At day 4, whole-body micro-PET image of a rat shows focal cardiac $[^{18}\text{F}]\text{-FHBG}$ activity at the site of intramyocardial Ad-CMV-HSV1-sr39tk injection. Liver $[^{18}\text{F}]\text{-FHBG}$ activity is also seen because of systemic adenoviral leakage with transduction of hepatocytes. Control rat injected with Ad-CMV-Fluc shows no $[^{18}\text{F}]\text{-FHBG}$ activity in either the cardiac or hepatic regions.

Significant gut and bladder activities are seen for both study and control rats because of route of [^{18}F]-FHBG clearance. B, Tomographic views of cardiac microPET images. The [^{13}N]- NH_3 (gray scale) images of perfusion are superimposed on [^{18}F]-FHBG images (color scale), demonstrating HSV1-sr39tk reporter gene expression. [^{18}F]-FHBG activity is seen in the anterolateral wall for experimental rat compared with background signal in control rat. Perpendicular lines represent the axis for vertical and horizontal cuts. Color scale is expressed as % ID/g.

Table

Comparison of Cardiac Activities in Study and Control Rats

	HSV1-sr39tk Rat (n=10)	Control Rat (n=4)	<i>P</i>
MicroPET image, ROI % ID/g	0.72±0.09	0.08±0.03	<0.001
Gamma counting, % ID/g	0.15±0.03	0.01±0.002	<0.05
TK assay, % conversion/μg per min	0.45±0.17	0.02±0.01	<0.05

Data are expressed as mean±SEM.

% ID/g indicates percent injected dose of [¹⁸F]-FHBG per gram of myocardium.