

Protective Effect of a Synthetic Polynucleotide Complex (Poly I:C) on Ocular Lesions Produced by Trachoma Agent in Rabbits

J. O. OH, H. B. OSTLER, AND J. SCHACHTER

Francis I. Proctor Foundation and George Williams Hooper Foundation, University of California Medical Center, San Francisco, California 94122

Received for publication 16 February 1970

Live trachoma agent (TE55) injected into the anterior chamber of the rabbit eye produced the following agent-specific ocular lesions: corneal opacity, corneal neovascularization, and iritis. Three intravenous injections of 1 mg of a potent interferon (IF) inducer, polyriboinosinic acid-polyribocytidylic acid complex (poly I:C), markedly suppressed the ocular lesions produced by the trachoma agent but failed to inhibit the growth of the agent in the ocular tissues. Furthermore, a single intravenous injection of 1 mg of polyriboinosinic acid or of polyribocytidylic acid was also protective, although each failed to induce any detectable circulating IF. These results indicate that a factor or factors other than IF may play a role in the suppression of the ocular lesions produced by trachoma agent in poly I:C-injected rabbits.

A synthetic polyriboinosinic acid-polyribocytidylic acid complex (poly I:C) has been shown to be a potent interferon (IF) inducer (3) and to mediate resistance to viral and nonviral infections *in vivo* as well as *in vitro*. Recently, Park and Baron (12) reported the effective suppression of herpetic keratitis in rabbit eyes by poly I:C.

It was previously reported that live trachoma agent (TE55) injected into the anterior chamber of the rabbit eye produced agent-specific ocular lesions; namely, corneal opacity resulting from extensive damage of the corneal endothelium, neovascularization of the cornea, and iritis (11). Because the growth of trachoma agent in both cell cultures and embryonated chick eggs could be suppressed by IF (4, 5, 8), we studied the effect of poly I:C on the ocular lesions produced by the trachoma agent. This communication reports that (i) intravenous injections of poly I:C markedly suppressed the lesions produced by the trachoma agent in rabbit eyes but failed to inhibit agent growth, and (ii) some factor or factors other than IF played a role in the suppression of the ocular lesions in the poly I:C-injected animals.

MATERIALS AND METHODS

Rabbits. The experimental animals were random-bred, healthy, male New Zealand white rabbits. They weighed approximately 2 kg each and were housed in individual cages at a room temperature of 25 C.

Trachoma agent. The source of the infective agent, T'ang strain (TE55) of trachoma agent, was described

in a previous paper (11). A monolayer of HeLa cells, strain 229 (American Type Culture Collection, Rockville, Md.), in a Falcon plastic tissue-culture flask (25 cm²) was inoculated with 5 ml of a 10⁻² dilution of trachoma-infected yolk sac material containing 10^{4.1} 50% chick embryo lethal doses (ELD₅₀). The culture medium (consisting of medium 199, 5% heat-inactivated fetal calf serum, and 100 µg of streptomycin per ml) was replaced daily. On the seventh day, the infected cells were scraped off the flask with a sterile cotton swab and dispersed by pushing the cell suspension through a 23-gauge hypodermic needle. The medium was then centrifuged at 100 × g for 10 min at 4 C, and the resulting supernatant fluid was used for intraocular injection.

Synthetic polynucleotides. A lyophilized form of poly I:C (Miles Laboratories, Elkhart, Ind.; control no. 11-4-321) was reconstituted by the addition of sterile phosphate-buffered saline (PBS) at pH 7.2, containing 100 units of penicillin and 100 µg of streptomycin per ml. Polyriboinosinic acid (poly I), lot no. M-8, and polyribocytidylic acid (poly C), lot no. M-8, both from Biopolymers, Dover, N.J., were reconstituted by the addition of sterile distilled water containing penicillin and streptomycin, 100 units and 100 µg per ml, respectively. All polynucleotide solutions were tested for bacterial sterility prior to use.

Intraocular inoculation with trachoma agent. Rabbits were anesthetized by intravenous (iv) injection of sodium pentobarbital and their corneas were treated with a topical application of tetracaine hydrochloride. By means of a previously described technique (10), 0.2 ml of the rabbit's aqueous humor was removed from the anterior chamber of the eye with a 26-gauge hypodermic needle. This was replaced with an equal

amount of the inoculum, which contained approximately 10^5 ELD₅₀ of the trachoma agent. In all experiments, both eyes were used for inoculation of the agent.

Evaluation of ocular lesions. The eyes were examined with a slit-lamp three times during the first week after the inoculation of the agent and twice weekly thereafter. The trachoma agent injected into the anterior chamber produced corneal opacity, neovascularization of the cornea, and iritis (11). The neovascularization occurred irregularly, and the iritis could not be evaluated after the corneal opacity appeared. For these reasons, the corneal opacity was the sign used for the preliminary evaluation of the effect of the polynucleotides on the trachoma lesions because it appeared regularly and was easy to observe. In evaluating the corneal opacity, any degree of edema of the central cornea observed with a slit-lamp was scored as "positive corneal opacity." Peripheral corneal edema without central corneal involvement was scored as "negative corneal opacity." In the subsequent main experiment, however, all ocular lesions were examined with a slit-lamp and the findings were confirmed by histological examination.

Detection of IF in serum and aqueous humor. The serum was separated from blood that had been collected aseptically from an ear vein and was incubated for 1 hr at 36 C. Aqueous humor was collected from both eyes of each rabbit and pooled. Aqueous humor specimens showing gross contamination with blood cells were discarded. The titration of IF was carried out with the Indiana strain of vesicular stomatitis

virus (VSV) in tubes of primary cultures of rabbit kidney cells according to a previously described technique (9). The titer of IF (units per milliliter) was expressed as the reciprocal of the highest dilution of each specimen that completely inhibited the cytopathic effects of VSV. IF so detected had the same properties as those described by Field et al. (3).

Titration of trachoma agent in ocular tissues. The cornea, rim of the sclera, and iris were excised aseptically from each rabbit eye, minced to 1-mm cubes, and ground with a mortar and pestle. To facilitate the grinding, 1 ml of crystalline alumina (90 mesh) was added. A 2-ml amount of Eagle's minimal essential medium containing 4 mg of streptomycin per ml was then mixed with the ground tissue. This mixture was centrifuged at 4 C for 5 min at $100 \times g$. The infectivity of the resulting supernatant fluid was titrated by immediately inoculating 0.1-ml samples into the yolk sacs of 6- to 8-day-old embryonated Leghorn eggs according to standard procedures. Ten eggs were inoculated with each specimen. The average day of death of the embryo was used to estimate the ELD₅₀ of the inoculum as described by Tarizzo and Nabli (13).

Staining of tissue sections. The eyes were removed, fixed in 10% buffered neutral Formalin, and embedded in paraffin. Tissues were sectioned at 7.0 μ m, and the sections were divided into three series. One series was stained with hematoxylin and eosin, one series with Giemsa stain (Wolbach's modification), and the third series with periodic acid-Schiff stain.

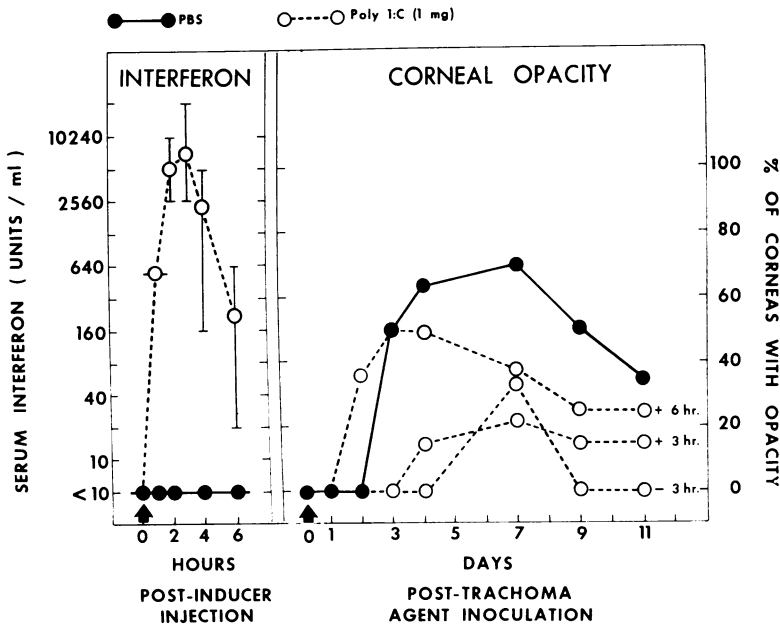


FIG. 1. Induction of circulating interferon (IF) and suppression of trachoma lesions after single intravenous injection of poly I:C (1 mg). Four groups of four rabbits each received poly I:C at various times relative to intracocular inoculation of trachoma agent, or received phosphate-buffered saline. Arrows indicate intravenous injection. Circles represent mean titers, and vertical lines represent ranges of IF titers.

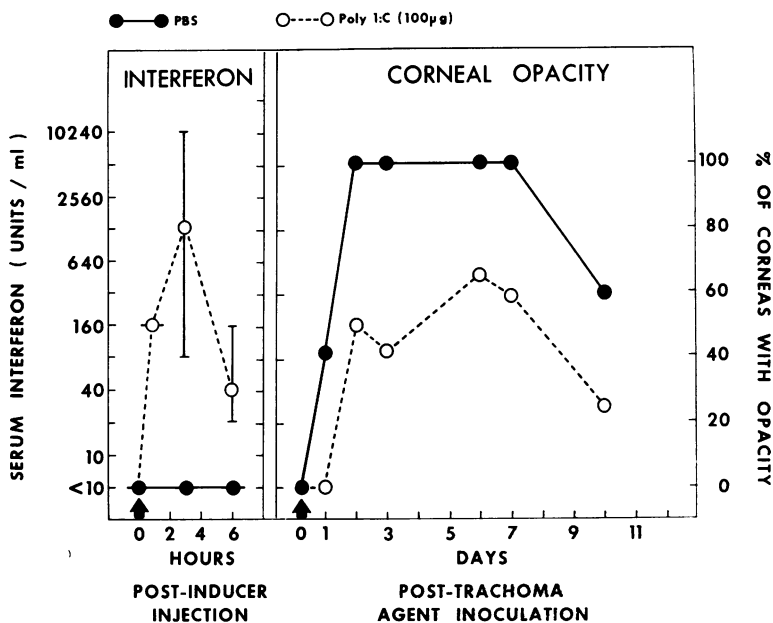


FIG. 2. Induction of circulating IF and suppression of trachoma lesions after intravenous injection of poly I:C (100 μ g). Two groups of six rabbits each received poly I:C or phosphate-buffered saline 3 hr prior to intraocular inoculation of trachoma agent. Symbols are defined in legend for Fig. 1.

RESULTS

Induction of IF and suppression of corneal lesions by polynucleotides. An effort was made to correlate the amount of IF in the serum and aqueous humor of rabbits with the degree of suppression of the trachoma lesions after iv injections of poly I:C, poly I, or poly C. Corneal opacity was the only sign evaluated as a measure of clinical activity.

A single iv injection of 1 mg of poly I:C induced IF in blood within 1 hr and peak titers (averaging 8,000 units/ml) at 3 hr (Fig. 1). At 6 hr, the titers of IF in the sera were still elevated (averaging 250 units/ml). Aqueous humor specimens collected 3 hr after the injection of poly I:C contained very high titers of IF (averaging 5,000 units/ml).

In the control rabbits, more than 75% of the eyes developed corneal opacity (Fig. 1). However, corneal opacity was observed in only 20 to 30% of the eyes if a single iv injection of poly I:C (1 mg) was administered 3 hr before or 3 hr after the intraocular injection of trachoma agent. In these poly I:C-treated rabbits, the development of opaque cornea was delayed 1 or 2 days. Injection of poly I:C 6 hr after the trachoma infection had no effect.

A single iv injection of 100 μ g of poly I:C also rendered significant protection if the poly I:C was given 3 hr before the trachoma agent (Fig. 2).

However, the degree of protection and the amount of IF induced in these animals were less than in those that received 1 mg of poly I:C by the same route.

The lesions were suppressed in almost all eyes when three iv injections of 1 mg of poly I:C were given, the first at 3 hr before the inoculation of the trachoma agent, the second on the second post-inoculation day, and the third on the fourth post-inoculation day (Fig. 3). High titers of serum IF were detected at 3 hr after each of the three injections, but the titers diminished markedly after each subsequent injection.

Surprisingly, the development of both corneal opacity and iritis was also suppressed in a significant number of eyes with a single iv injection of 1 mg of poly I or poly C, although neither of these compounds induced any detectable IF in these rabbits (Fig. 4).

Effect of poly I:C on various ocular lesions and on the growth of trachoma agent in ocular tissues. To determine whether ocular lesions other than corneal opacity were also suppressed by treatment with poly I:C, the following experiment was carried out. A titration of the agent in the ocular tissues was done at the same time that the lesions were evaluated so that growth of the agent could be correlated with inflammatory reactions in the tissues.

A group of rabbits received an intraocular

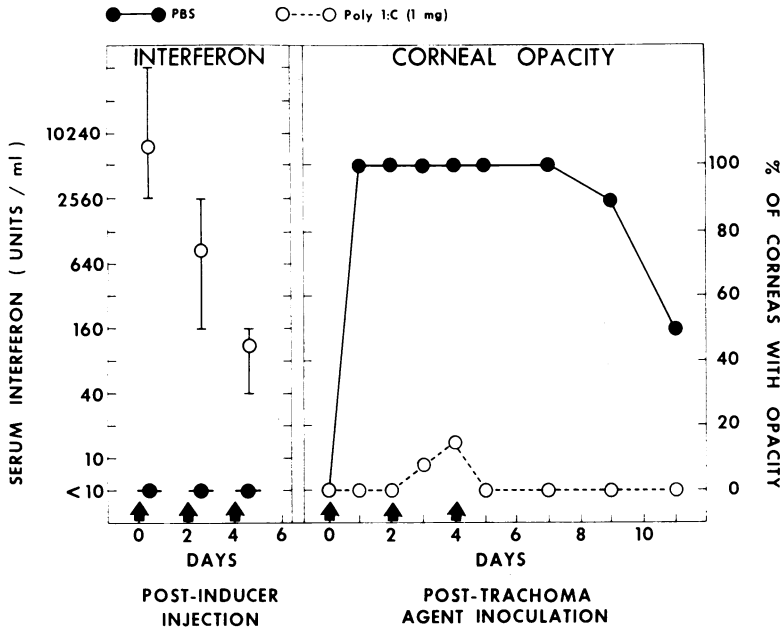


FIG. 3. Induction of circulating IF and suppression of trachoma lesions after three intravenous injections of poly I:C (1 mg) or phosphate-buffered saline in two groups of seven rabbits each. Symbols are defined in legend for Fig. 1.

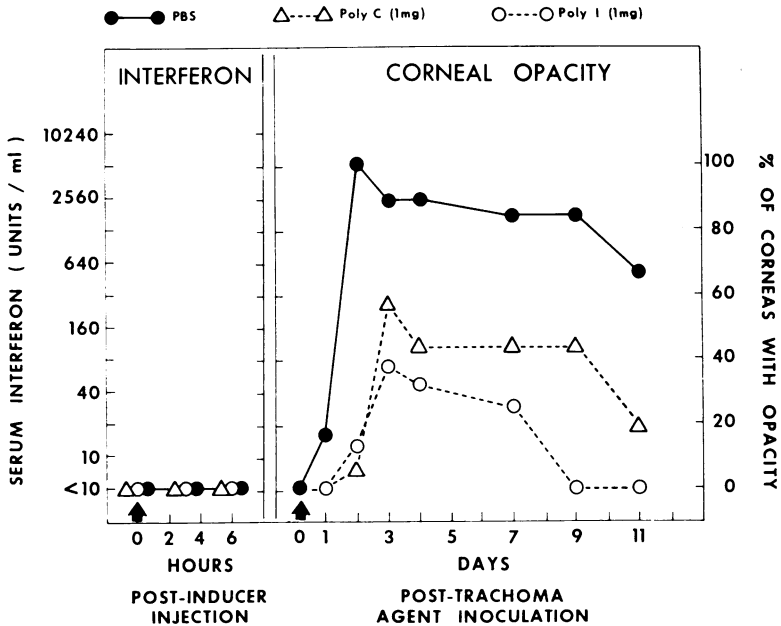


FIG. 4. Suppression of trachoma lesions by single intravenous injection of poly I (1 mg) or poly C (1 mg). Three groups of nine rabbits each received poly I, poly C, or phosphate-buffered saline 3 hr prior to intraocular injection of trachoma agent. Symbols are defined in legend for Fig. 1.

inoculation with trachoma agent and three iv injections of 1 mg of poly I:C, as described in the preceding experiment. Control rabbits were also inoculated with trachoma agent but received

three iv injections of PBS. The ocular lesions were examined daily with a slit-lamp. At various intervals, between three and seven rabbits were sacrificed and the eyes were removed. One-half of each

eye was fixed in Formalin for histologic study, and the other half was used for titrating the infectivity of the trachoma agent in the tissues.

In the control rabbits, gross lesions consisting of severe corneal opacity, iritis, and (occasionally)

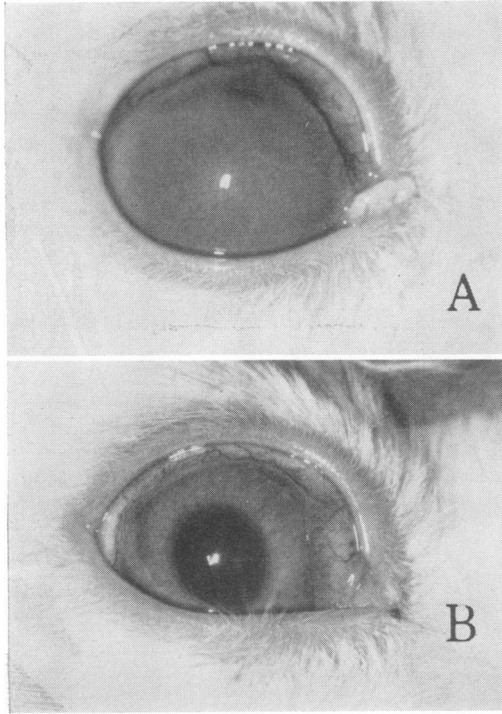


FIG. 5. Rabbit eyes 7 days after inoculation of anterior chamber with trachoma agent. (A) Rabbit received three intravenous injections of phosphate-buffered saline (control). Note severe opacity and neovascularization of cornea. (B) Rabbit received three intravenous injections of 1 mg of poly I:C. No lesions except slight perilimbal congestion.

neovascularization (Fig. 5A) were produced. The histological sections revealed extensive infiltration of inflammatory cells (chiefly polymorphonuclear leukocytes) in the edematous corneal stroma, limbus, filtration angle, and iris (Table 1 and Fig. 6A and 6B). On days 1 and 2, trachoma inclusion bodies were found frequently in the filtration angle and less frequently in the iris. On day 4, they were found in only a few of the eyes, and none was found on day 7. No inclusions were seen in the cornea or limbus during the entire period of the experiment.

In contrast to the controls, the poly I:C-treated rabbits were free from clinical ocular changes (Fig. 5B), and the sections showed only a few inflammatory cells in the filtration angle and limbus (Table 1 and Fig. 6C and 6D). The corneas and irises appeared to be normal. Inclusion bodies were found only in the filtration angle of these eyes, and only on days 1 and 2.

Although treatment with poly I:C markedly suppressed the ocular inflammation, it failed to inhibit the growth of agent in these eyes. As shown in Fig. 7, the infectivity titers of the ocular homogenates of the poly I:C-treated rabbits were of the same order of magnitude as the infectivity titers of the controls.

DISCUSSION

In this study, a single iv injection of 100 µg of poly I:C induced a significant level of IF in both blood and aqueous humor. The production of ocular lesions by the trachoma agent was also suppressed in these rabbits. Both induction of IF and suppression of the lesions were more marked when the rabbits received a dose of 1 mg of poly I:C. The maximum suppression of the lesions was produced by three iv injections of 1 mg of poly I:C. However, single-stranded homopolymers of the ribonucleotides (poly I or poly C),

TABLE 1. Inflammatory reaction produced by trachoma agent in eyes of poly I:C-treated and control rabbits

Ocular region	Inflammatory reaction ^a							
	Controls				Poly I:C-treated			
	Day 1 ^b	Day 2	Day 4	Day 7	Day 1	Day 2	Day 4	Day 7
Cornea.....	±	+	+	+	-	-	-	-
Iris.....	+ ^c	+ ^c	+	+	-	-	-	-
Limbus.....	+	+	+	+	±	±	±	±
Filtration angle.....	+ ^d	+ ^d	+ ^c	+	± ^d	± ^d	±	±

^a Inflammatory reaction seen in histological sections: edema, infiltration of inflammatory cells (mainly polymorphonuclear leukocytes), and occasional hemorrhage. Symbols: +, moderate to severe inflammatory reaction; ±, slight inflammatory reaction; -, no or negligible inflammatory reaction.

^b Days postinoculation.

^c Positive for trachoma inclusions in a few eyes.

^d Positive for trachoma inclusions in almost all eyes.

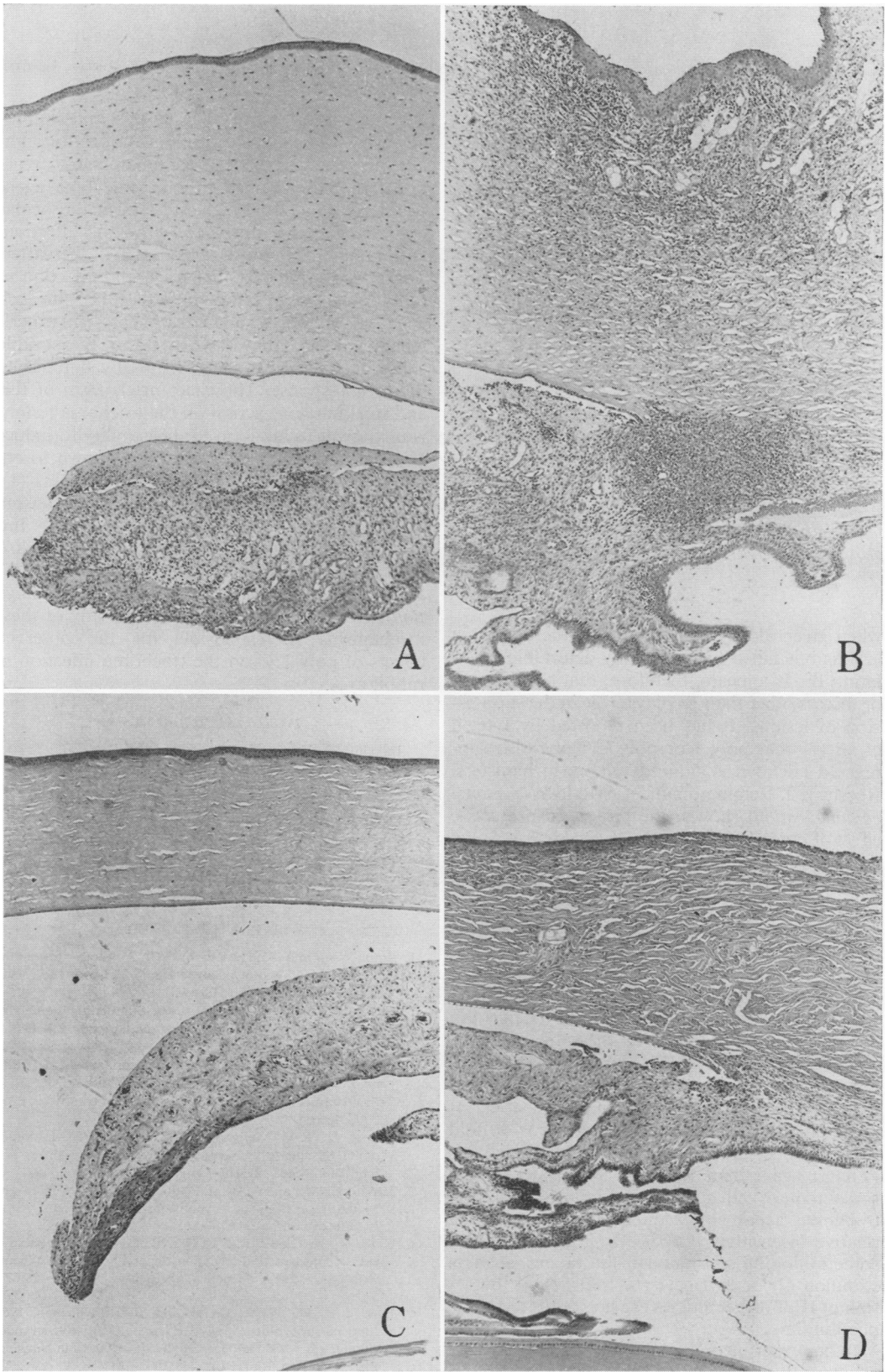


FIG. 6. Sections of control and poly I:C-treated rabbit eyes. (A and B) Section of control eye shown in Fig. 5A. Hematoxylin and eosin stain. $\times 60$. Heavy infiltration of inflammatory cells in edematous corneal stroma, limbus, filtration angle, and iris. (C and D) Section of poly I:C-treated rabbit eye shown in Fig. 5B. Hematoxylin and eosin stain. $\times 60$. Slight inflammatory response in limbus and filtration angle. Appearance of eye otherwise normal.

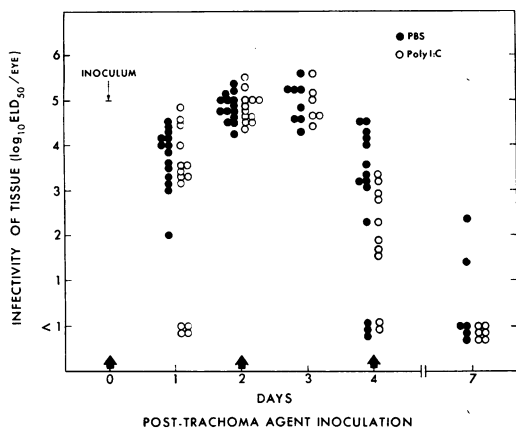


FIG. 7. Isolation of trachoma agent from ocular tissues of poly I:C-treated and control rabbits. Arrows indicate intravenous injections of poly I:C (1 mg) or phosphate-buffered saline. Each circle represents one eye.

when given alone, also suppressed the trachoma lesions but failed to induce any detectable circulating IF. It appears, therefore, that some factor or factors other than IF play a role in the suppression of lesions. It has been reported by Larsen et al. (7) that poly I or poly C alone also suppressed adenovirus-induced tumors in hamsters. Recently, J. Remington and T. Merigan (*personal communication*) showed the prolonged protective effect of pyren and poly I:C against *Listeria monocytogenes* infection in mice even long after the disappearance of circulating IF, suggesting mechanisms other than IF for the resistance.

IF has been shown to inhibit the growth of trachoma agent in cell cultures and eggs (4, 5, 8), but in this study, although both serum and aqueous humor of poly I:C-injected rabbits contained extremely high titers of IF, growth of the agent in the eyes of these rabbits was the same as in the controls. The failure of IF to inhibit the growth of the agent in these animals cannot be explained with certainty at the present time. Hanna et al. (4) reported that activity of mouse IF was 10-fold lower against trachoma-inclusion conjunctivitis (TRIC) agent than against VSV titrated in the same mouse cell strain. The failure to inhibit trachoma agent could thus be attributed to a relative insensitivity to IF. Or it could be that some inhibiting substance in the tissues, such as stimulon (2) or enhancer (6), suppressed the action of IF. Further studies are needed to test these possibilities.

In our experimental model, trachoma inclusions were seen in both the filtration angle and iris of control rabbit eyes for only the first 4 days after

injection of the agent. The cornea and limbus, however, were devoid of such inclusions throughout the period of their severe inflammatory reactions. In these control rabbits, trachoma agent could be isolated in high titers from the ocular tissues up to the fourth day after the infection, and little or no agent was isolated thereafter. These results indicate that trachoma infection in rabbit eyes is self-limiting in nature. Despite such a nature of the infection in the present experimental model, poly I:C had no measurable effect on the agent, but it markedly diminished the host response. The exact mechanism of this anti-inflammatory action on the trachoma lesions is unknown. In addition to their ability to induce IF, the polynucleotides have been known to enhance *in vivo* immunological responsiveness (1), to stimulate phagocytic activities (A. Munson, W. Regelson, and T. Merigan, *Abstr.*, 5th Int. Congr. Chemother., Wiener Med. Akad., p. 407, 1967), and to inhibit serum complement (W. Regelson and A. Munson, *personal communication*). It remains to be seen whether any of these mechanisms is responsible for the observed effects of poly I:C on the trachoma infection in rabbit eyes.

ACKNOWLEDGMENTS

This investigation was supported by Public Health Service grants NB-06207 from the National Institute of Neurological Diseases and Blindness and AI-07698 from the National Institute of Allergy and Infectious Diseases.

We are most grateful to K. F. Meyer, P. Thygeson, E. Jawetz, and T. Merigan for reviewing the manuscript and offering valuable suggestions. We also thank Ruth L. Thygeson for editorial advice and Nancy Stover and Silke Balas for excellent technical assistance.

LITERATURE CITED

- Braun, W., and M. Nakano. 1967. Antibody formation: Stimulation by polyadenylic and polycytidylic acids. *Science* (Washington) 157:819-821.
- Chany, C., and C. Brailovsky. 1967. Stimulating interaction between viruses (stimulon). *Proc. Nat. Acad. Sci. U.S.A.* 57:87-94.
- Field, A. K., A. A. Tytell, G. P. Lampson, and M. R. Hilleman. 1967. Inducers of interferon and host resistance. II. Multistranded synthetic polynucleotide complex. *Proc. Nat. Acad. Sci. U.S.A.* 58:1004-1010.
- Hanna, L., T. C. Merigan, and E. Jawetz. 1966. Inhibition of TRIC agents by virus-induced interferon. *Proc. Soc. Exp. Biol. Med.* 122:417-421.
- Jenkin, H. M., and Y. K. Lu. 1967. Induction of interferon by the Bour strain of trachoma in HeLa 229 cells. *Amer. J. Ophthalmol.* 63:1110-1115.
- Kato, N., A. Okada, and F. Ota. 1965. A factor capable of enhancing virus multiplication appearing in parainfluenza virus type 1 (HVJ)-infected allantoic fluid. *Virology* 26:630-637.
- Larson, V. M., W. R. Clark, and M. R. Hilleman. 1969. Influence of synthetic (poly I:C) and viral double-stranded ribonucleic acids on adenovirus 12 oncogenesis in hamsters. *Proc. Soc. Exp. Biol. Med.* 131:1002-1011.
- Mordhorst, C. H., V. Reinicke, and E. Schonne. 1967. *In ovo* inhibition by concentrated chick interferon on the

- growth of TRIC agents. *Amer. J. Ophthalmol.* 63:1107-1109.
9. Oh, J. O. 1966. An interferon-like viral inhibitor in body fluids of endotoxin-injected rabbits. *Proc. Soc. Exp. Biol. Med.* 123:493-496.
 10. Oh, J. O., and C. A. Evans. 1960. Suppressive effects of pyrrolamine maleate and d-lysergic acid diethylamide (LSD-25) on early corneal lesions produced in vitro by Newcastle disease virus (NDV) and compound 48/80. *Virology* 10:127-143.
 11. Oh, J. O., and M. L. Tarrizo. 1969. Ocular lesions induced by the trachoma agent in rabbits. *J. Bacteriol.* 97:1042-1047.
 12. Park, J. H., and S. Baron. 1968. Herpetic keratoconjunctivitis: Therapy with synthetic double-stranded RNA. *Science (Washington)* 162:811-813.
 13. Tarizzo, M. L., and B. Nabli. 1963. Etudes sur le trachome. 7. Action comparée des antibiotiques sur différents virus de groupe du trachome cultivés dans les oeufs embryonnés. *Bull. World Health Organ.* 29:289-298.