

# Responses of the Peyer's Patches in Germ-Free Mice to Antigenic Stimulation

MORRIS POLLARD AND NEHAMA SHARON

*Lobund Laboratory, University of Notre Dame, Notre Dame, Indiana 46556*

Received for publication 30 March 1970

Lymph nodes, spleens, and Peyer's patches of germ-free mice are relatively inactive. The tissues are small and contain rare, small, indistinct, germinal zones. When exposed to antigenic stimuli (*Salmonella paratyphi* A and lymphocytic choriomeningitis virus), the tissues become larger and germinal zones appear coincident with antibodies in the blood. The Peyer's patches were activated if antigen was absorbed from the intestinal lumen into the circulation but not if the antigen was administered parenterally. There was no demonstrable immunological response by the germ-free mouse to *Streptococcus faecalis*.

The Peyer's patches are aggregations of lymphoid cells in the intestinal wall, distal to the mesentery, which are thought to have an immunological function. Through experiments with rabbits, Cooper and associates (1) suggested that the Peyer's patches are part of a system with a unique role in the production of humoral antibodies, analogous to that of the bursa of Fabricius in avian species. However, this has been difficult to prove decisively, because of the uncertainty of complete extirpation of the Peyer's patches due to variable sizes and multiple locations in a vital organ.

Except for the thymus glands, the lymphoreticular systems of disease-free, germ-free mice are relatively inactive. The lymph nodes and spleens are small, germinal zones and plasma cells are detected very infrequently (Fig. 1); in consequence, the globulin level is much lower than that observed in the conventional counterpart animal (3; B. S. Wostman et al., *Immunology, in press*). The Peyer's patches are small accumulations of small lymphocytes in which it is unusual to observe germinal or reaction zones (Fig. 2), and the lamina propriae are thin and sparsely populated with mononuclear cells. However, the immunological mechanisms in germ-free mice are functionally intact, and, when activated by antigenic stimuli, appropriate histological changes appear in the lymph nodes and spleen: (i) they become enlarged through increased cell content; (ii) germinal zones with globulin-containing plasma cells can be detected in and around them; and (iii) serum globulin levels increase, as does the development of specific circulating antibodies. The Peyer's patches of germ-free mice, with their

low level of activity, have provided us with a reference base line on which responses to local or general antigenic stimuli could be more clearly defined. The correlation between the development of germinal zones in the Peyer's patches and the appearance of specific serum antibodies as a result of a known antigenic stimulus could be of use in analyzing the function of these lymphoid aggregates. This report describes and interprets the reactions of Peyer's patches in germ-free mice, after exposure to a variety of antigenic stimuli by a variety of routes.

## MATERIALS AND METHODS

**Mice.** The Lobund strain of random-bred Swiss-Webster (SW) mice, propagated through the 24th generation under controlled germ-free conditions, was used in the described procedures. Routine examinations of the mice at regular intervals were negative for bacteria, fungi, and macroparasites (12); however, leukemia virus was detected in them as well as in other strains of mice (6, 8). In this report, therefore, the mice are referred to as "germ-free" only for convenience. At 4 weeks of age, control uninfected mice were removed from each experimental isolator for examinations, and the remaining germ-free mice were exposed to bacterial or viral antigenic contamination by swabbing the oral cavity or by intraperitoneal (ip) injection of viable or of heat-killed microorganisms. In addition, a mouse strain (LCM) with congenitally acquired, persistent infection with lymphocytic choriomeningitis (LCM) virus was used (9, 10). At intervals, three mice were removed from the germ-free isolator; each was anesthetized by ether inhalation, exsanguinated from the heart, and examined by culture techniques for bacterial content and for gross and microscopic tissue changes. Each experiment involved at least 20 germ-free mice.

The tissues examined from each mouse, including the controls, consisted of all detectable Peyer's patches, lymph nodes, spleen, thymus, liver, kidney, and lung. Each Peyer's patch was cut from one end to the other as was the cross section of the intestine in which it was embedded. The tissues were fixed in Bouin's solution, embedded in paraffin, sectioned serially, stained by haematoxylin and eosin, and exam-

ined by conventional microscopy. The lymph nodes, spleens, and Peyer's patches were examined carefully for germinal zones: clearly defined aggregations of distinctive larger, lighter-staining lymphoid cells in the primary follicles, along with mitotic, pyknotic, and fragmented cells. The serum samples were examined for antibody by the microtiter technique.

**Microorganisms.** Each experiment involved one of

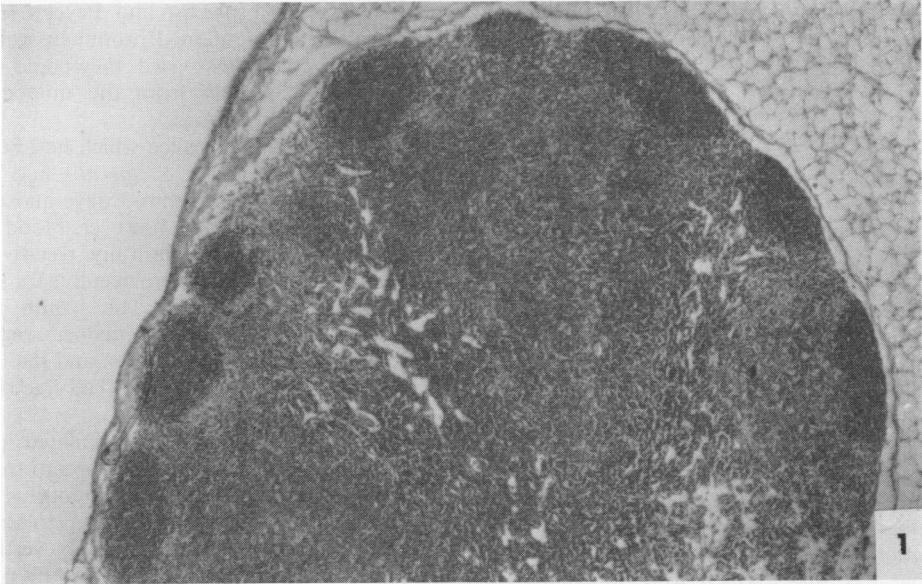


FIG. 1. Lymph node from germ-free mouse. The primary follicles in the cortex do not contain germinal zones. Haematoxylin and eosin stain.  $\times 50$ .

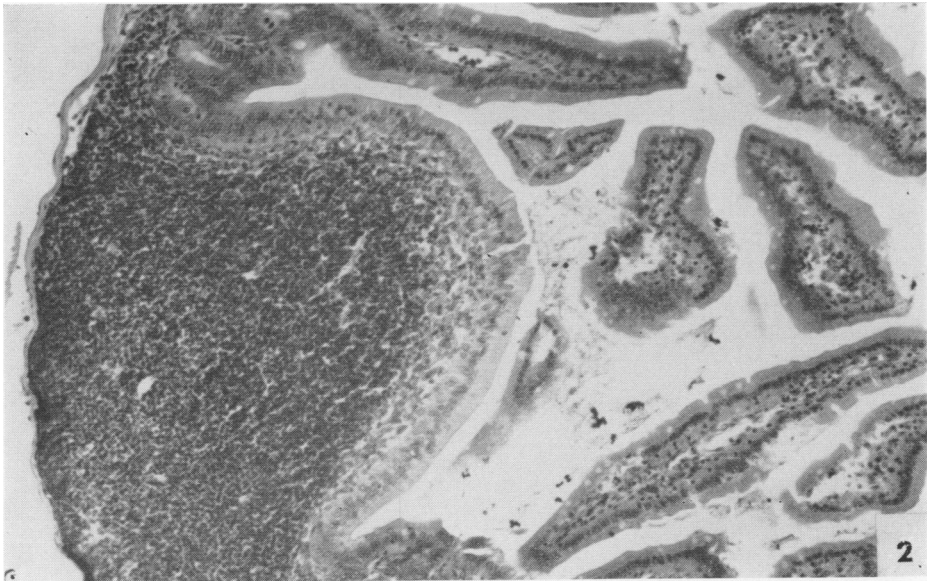


FIG. 2. Peyer's patch from germ-free mouse. The mass of lymphoid cells does not contain a germinal zone. The lamina propriae are thin and contain few cells. Haematoxylin and eosin stain.  $\times 100$ .

three types of the following microorganisms: viable nonpathogenic *Streptococcus faecalis*, viable and heat-killed pathogenic *Salmonella paratyphi A*, and viable LCM virus (7), the latter either congenitally acquired or injected ip. The bacteria were propagated in Brain Heart Infusion broth and were transferred into the germ-free isolator in glass-sealed ampoules. Bacteria were killed by immersion of glass ampoules containing the organism in boiling water for 1 hr and then they were transferred into the isolator. Viable LCM virus stock was the clarified extract of 20% infected brain in Eagle's minimal essential medium (MEM).

Individual exposed mice were tested for bacterial content by inoculating pieces of intestine, or a few drops of heart blood, into thioglycolate broth and incubating at 37 C. The test for LCM virus involved intracerebral inoculation of blood into mature susceptible mice, which developed distinctive fatal convulsions on the seventh day after the inoculation.

### RESULTS

**LCM virus.** All mice with congenital LCM virus infection were persistently viremic (7). Those over 3 months of age had enlarged lymph nodes and spleens with prominent germinal zones. The serum globulin levels were elevated; however, antibodies were not detected in them. The Peyer's patches were swollen but rarely contained germinal zones. The cells in the Peyer's patches were predominantly large reticulum-type cells and few small lymphocytes.

Normal SW mice, which were inoculated ip with 1,000 LD<sub>50</sub> of LCM virus, developed significant levels of complement-fixing antibodies within

21 days after inoculation, which persisted for at least 100 days. At 21 days after inoculation, the lymph nodes and spleens were enlarged and contained very prominent germinal zones (Fig. 3); however, the Peyer's patches remained small and contained no germinal zones. The mice were not viremic. In control conventional mice, which were exposed to LCM virus by both routes of infection, the lymph nodes, spleens, and Peyer's patches were swollen and contained prominent germinal zones; however, in this regard, they could not be distinguished decisively from the uninoculated control conventional mice.

***S. faecalis.*** All of the mice which had been infected orally with viable *S. faecalis* had viable organisms in the feces within 3 days and during the following 45 test days; however, blood specimens from them were culturally negative. All serum specimens but one were negative for significant levels of agglutinins. The lymph nodes, spleens, and Peyer's patches remained small and free from distinct germinal zones, and the lamina propriae were thin and relatively cell-free (Fig. 1, 2).

The mice, which had been inoculated ip with 10<sup>8</sup> viable *S. faecalis*, remained symptom-free, but they showed the organism continuously in the blood and in the feces from day 3 up to termination of the experiment on day 29. Nevertheless, their lymph nodes, spleens, and Peyer's patches remained small and inactive, and antibody was not detected in their sera.

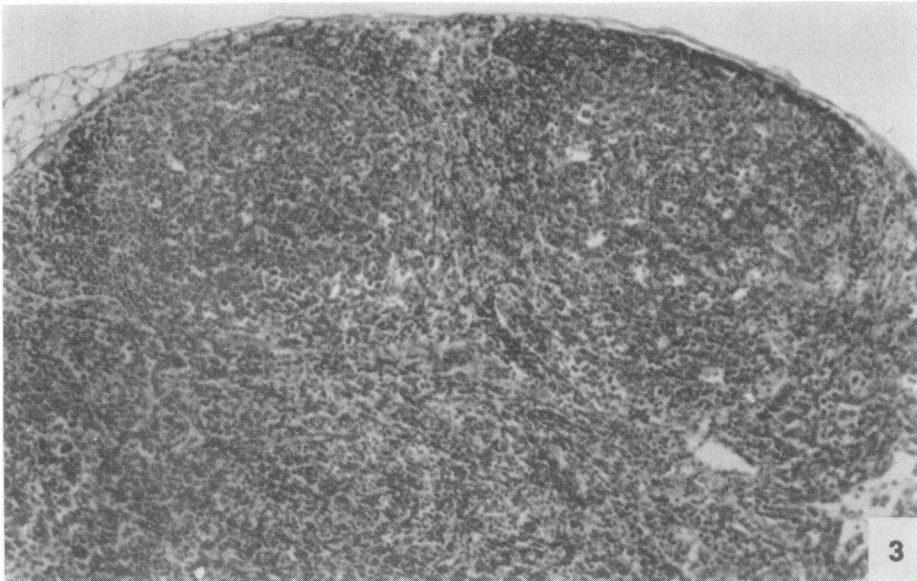


FIG. 3. Lymph node from germ-free mouse which had been inoculated intraperitoneally with LCM virus. Note very large germinal zones in the cortical follicles. Haematoxylin and eosin stain.  $\times 125$ .

**S. paratyphi A.** Oral administration of viable bacteria resulted in positive intestinal cultures from day 2 (first day of examination) until the termination of the experiment 37 days later. Blood specimens from the same mice were positive for *S. paratyphi A* on day 9 after oral inoculation, and thereafter they were negative. Their

lymph nodes and spleens were swollen from day 9 on, and they contained distinct germinal zones from day 16 on (Fig. 4). The Peyer's patches were swollen at 2 days after exposure to the bacteria, and distinct germinal zones were observed in them at 16 days (Fig. 5). The lamina propriae of the intestines were thickened and more cellular at

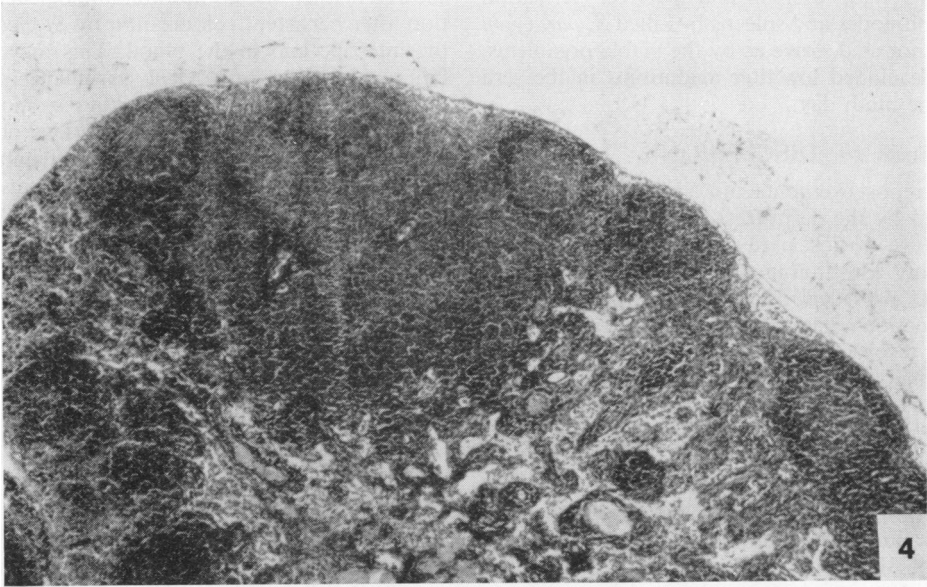


FIG. 4. Lymph node from germ-free mouse which had been fed *S. paratyphi A*. Note large germinal zones in cortical follicles. Haematoxylin and eosin stain.  $\times 50$ .

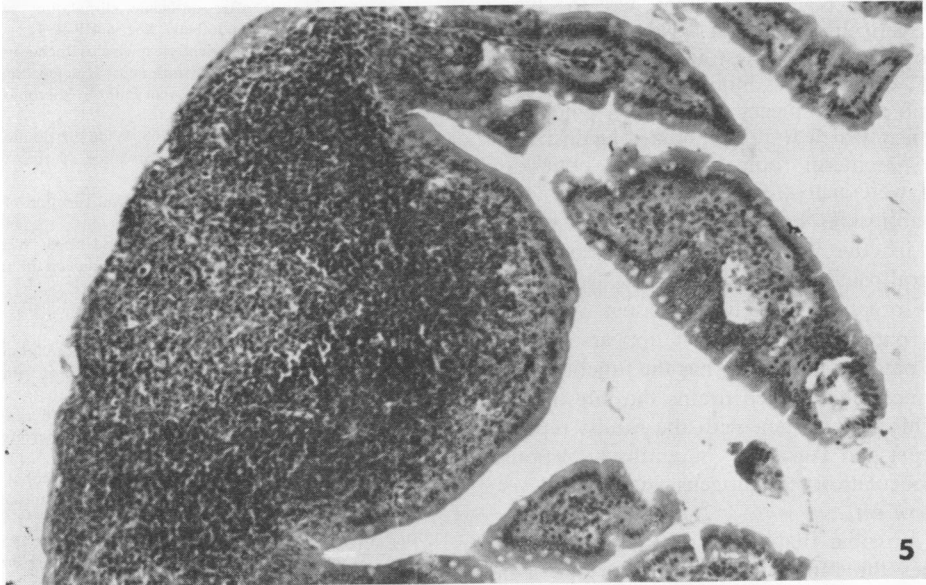


FIG. 5. Peyer's patch from germ-free mouse which had been fed *S. paratyphi A*. Note distinct germinal zones in subserosal part of lymphoid nodule and thick cellular lamina propriae. Haematoxylin and eosin stain.  $\times 125$ .

9 days after inoculation. Serum antibody was detected in the mice on day 9 after inoculation, and it remained elevated during the experimental period. None of the mice died from the infection. In mice which had been inoculated ip with  $10^8$  heat-killed *S. paratyphi* A, some of the lymph nodes and the spleens were swollen and contained small germinal zones; however, the Peyer's patches remained small and inactive. Activation of lymph nodes and spleens by killed *S. paratyphi* A was not as decisive as by the viable organisms. They developed low-titer agglutinins in the sera from the ninth day.

### DISCUSSION

This report exemplifies an additional advantage afforded by the germ-free animal for studies on the nature of host-parasite interactions (7). The uniformly low immunohistological base line of activities provided a basis for interpreting structure-function relationships. On the basis of the results recorded here, a unique immunological role, analogous to that of the avian bursa of Fabricius, cannot be assigned to the murine Peyer's patches; however, they do manifest characteristics of lymph nodes. It is of significance that both the bursa and the thymus glands of germ-free chickens have well-defined cortex and medulla, in which distinct morphological changes could not be associated with immunological activations (*personal observations*). After exposure to directed antigenic stimuli, the Peyer's patches of the germ-free mice were enlarged and developed distinct germinal zones, like the lymph nodes. Antigen, which entered the circulation of the mouse via the intestinal mucosa (as with viable *S. paratyphi* A), induced activation changes in lymph nodes, spleen, and Peyer's patches. In adult mice, which were immunized against LCM by the parenteral route, the lymph nodes and spleens were activated and the sera contained LCM antibody, but their Peyer's patches remained inactive. Thus, antigen, which entered via parenteral routes (LCM virus and killed *S. paratyphi* A organisms), activated tissues other than Peyer's patches. Therefore, it appears that the Peyer's patch in the mouse has the functional role of a lymph node which drains the intestinal lumen. This is consistent with the results reported by Cooper and Turner (2) on antibody responses after inoculation of antigens into the Peyer's patches of rats.

It is possible that the murine thymus gland combines the functional elements of the avian thymus and the bursa of Fabricius. Neonatal thymectomy deprives the mouse of the capacity for manifesting cell-associated immunity but not

as decisively for manifesting humoral immunity (5, 6); however, analysis of bursal functions required abrogation of that organ prior to hatching through the use of hormonal agents (11). Prenatal thymectomy may be necessary for demonstration of its role in production of humoral antibody in the mouse.

It is significant that the germ-free mouse showed neither disease nor immunological activation after persistent colonization by *S. faecalis* in the intestine and in the blood. This may reflect failure of the immunological surveillance mechanism of the host to recognize, or to respond to, an alien antigen, or the organism contains no alien antigens. We are extending this experimental protocol to determine whether other organisms of the so-called "normal flora" manifest similar limited interactions with the host. If some bacterial species can infect mice without inducing detectable host responses in them, then the microbiological monitoring capabilities of the germ-free mouse may not be as sensitive as was anticipated (7).

### ACKNOWLEDGMENTS

This investigation was supported by funds from the Office of Naval Research, The John A. Hartford Foundation, Inc., and the National Institutes of Health.

### LITERATURE CITED

- Cooper, M. D., D. Y. Percy, M. F. McKneally, A. E. Gabrielsen, D. E. R. Sutherland, and R. A. Good. 1966. A mammalian equivalent of the avian bursa of Fabricius. *Lancet*, p. 1388-1391.
- Cooper, G. N., and K. Turner. 1969. Development of IgM memory in rats after antigenic stimulation of Peyer's patches. *J. Reticuloendothelial Soc.* 6:419-434.
- Glimstedt, G. 1936. Bacterienfreie mierschweinchchen. Aulzucht, Lebensfähigkeit und Wachstum nebst Untersuchungen über das lymphatische Gewebe. *Acta Pathol. Microbiol. Scand.* (Suppl.) 30:1.
- Kajima, M., and M. Pollard. 1968. Wide distribution of leukemia virus in strains of laboratory mice. *Nature (London)* 218:188-189.
- Miller, J. F. A. P. 1961. Immunological function of the thymus. *Lancet* 2:748-749.
- Miller, J. F. A. P., G. F. Mitchell, and N. S. Weiss. 1967. Cellular basis of the immunological defects in thymectomized mice. *Nature (London)* 214:992-997.
- Pollard, M. 1965. The use of germfree animals in virus research. *Progr. Med. Virol.* 7:362.
- Pollard, M., and T. Matsuzawa. 1964. Radiation-induced leukemia in germfree mice. *Proc. Soc. Exp. Biol. Med.* 116:967-971.
- Pollard, M., and N. Sharon. 1969. Immunoproliferative effects of lymphocytic choriomeningitis virus in germfree mice. *Proc. Soc. Exp. Biol. Med.* 132:242-246.
- Pollard, M., N. Sharon, and B. A. Teah. Congenital lymphocytic choriomeningitis virus infection in gnotobiotic mice. *Proc. Soc. Exp. Biol. Med.* 127:755-761.
- Rao, M. A., R. L. Aspinall, and K. E. Buchanan. 1958. Effect of 19-nortestosterone and 19-nortestosterone benzoate on the development of the bursa of Fabricius and other lymphoid tissues in chickens and ring-necked pheasants. *Anat. Rec.* 130:459.
- Wagner, M. 1959. Determination of germfree status. *Ann. N.Y. Acad. Sci.* 78:89-100.