

# Bevacizumab in Japanese patients with malignant glioma: from basic research to clinical trial

Shingo Takano<sup>1</sup>  
Eiichi Ishikawa<sup>1</sup>  
Kei Nakai<sup>1</sup>  
Masahide Matsuda<sup>1</sup>  
Tomohiko Masumoto<sup>2</sup>  
Tetsuya Yamamoto<sup>1</sup>  
Akira Matsumura<sup>1</sup>

<sup>1</sup>Department of Neurosurgery,

<sup>2</sup>Department of Radiology, Faculty of Medicine, University of Tsukuba, Tsukuba, Japan

**Abstract:** An antiangiogenic approach is especially suitable for the treatment of malignant gliomas. Recently, two large clinical trials in newly diagnosed glioblastoma (the Avastin in Glioblastoma study and Radiation Therapy Oncology Group 0825 study) showed a 3- to 4-month prolongation of progression-free survival (PFS) with bevacizumab, but no significant effect on overall survival (OS). Japan is the first, and so far only, country to approve the use of bevacizumab in newly diagnosed glioblastoma in combination with radiotherapy and temozolomide chemotherapy. The drug is also approved for use as monotherapy for recurrent glioblastoma and certain other types of high-grade glioma after previous therapy. The effectiveness of bevacizumab on Japanese malignant glioma patients was reviewed. The Phase II clinical trial demonstrated that the PFS with bevacizumab alone was 34% at 6 months and 3.3 months at median for 32 patients with recurrent malignant gliomas. In the Avastin in Glioblastoma study, 44 Japanese patients were registered from Japan. PFS and OS for bevacizumab combined with standard temozolomide and radiotherapy were 12.2 months and 29.2 months at median, respectively, for the patients with newly diagnosed glioblastoma. PFS and OS tended to be longer for those treated with bevacizumab than for those not treated with the drug. In addition, biomarkers of bevacizumab effectiveness were investigated in Japanese patients. Vascular endothelial growth factor concentration, matrix metalloproteinase 9 activities in urine, and apparent diffusion coefficient values on magnetic resonance imaging may be biomarkers that predict patient prognosis. Finally, novel experiments for vascular endothelial growth factor antibody action were described; these include the induction of glioma cell apoptosis, an antibody treatment failure model, and a study of the synergistic effect with chemotherapeutic agents.

**Keywords:** angiogenesis, brain tumor, VEGF antibody, bevacizumab, clinical trial, Japanese

## Introduction

Glioblastoma is one of the most richly neovascularized solid tumors in terms of vasoproliferation, endothelial cell hyperplasia, and endothelial cell cytology; hence, an antiangiogenic approach may be especially suitable for the treatment of malignant gliomas.<sup>1</sup> Recently, two large clinical trials on newly diagnosed glioblastomas – the Avastin in Glioblastoma (AVAglio study) and the Radiation Therapy Oncology Group study – showed a 3- to 4-month prolongation of progression-free survival (PFS) with bevacizumab, but no significant effect on overall survival (OS).<sup>2,3</sup> However, Japan is the first, and so far only, country to approve the use of bevacizumab in newly diagnosed glioblastoma in combination with radiotherapy and temozolomide chemotherapy. The drug is also approved for use as a monotherapy for recurrent glioblastoma and for certain other types of high-grade gliomas after previous therapy. In this paper,

Correspondence: Shingo Takano  
Department of Neurosurgery, Faculty of Medicine, University of Tsukuba, 1-1-1 Tennoudai, Tsukuba, Ibaraki 305-8575, Japan  
Tel +81 2 9853 3220  
Fax +81 2 9853 3214  
Email shingo4@md.tsukuba.ac.jp

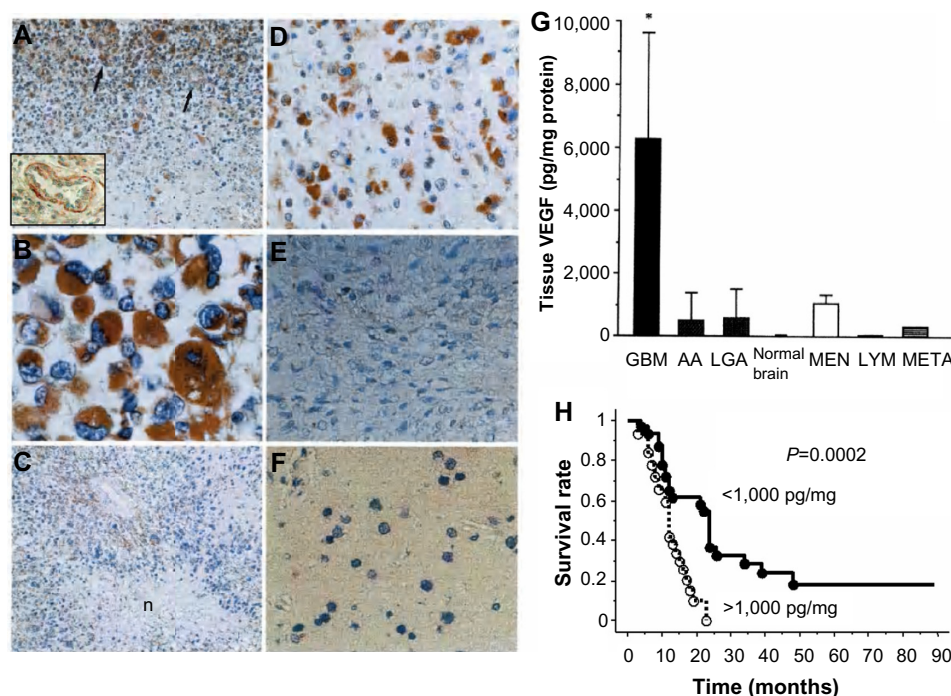
the effectiveness of bevacizumab in Japanese patients with malignant glioma was reviewed from basic research to clinical trial and from some new findings.

## Vascular endothelial growth factor concentration in the serum and tumor tissues of brain tumor patients

Immunolocalization of vascular endothelial growth factor (VEGF) was investigated in the brain tumors of 19 Japanese patients; the types of tumors included glioblastoma, anaplastic astrocytoma, low-grade astrocytoma, meningioma, malignant lymphoma, and metastatic brain tumor. Normal brain tissue was also examined.<sup>4</sup> Strong expression was seen in the blood vessels in the tumor and in the edge of the glioblastoma (Figure 1A). In addition, strong expression was seen in the cytoplasm of tumor cells (Figure 1B) and around areas of necrosis (Figure 1C). Expression was weaker in the anaplastic astrocytoma (Figure 1D) and in the low-grade astrocytoma (Figure 1E) compared to the glioblastoma. VEGF was not expressed in the normal brain (Figure 1F).

Using a VEGF enzyme-linked immunosorbent assay, we determined the concentration of VEGF in the serum and tumor extracts of 19 brain tumor patients, just as we did in the immunohistochemical study.<sup>4</sup> VEGF concentration in the tissue of glioblastomas was significantly higher than that in other types of tumors, as well as that in the normal brain (Figure 1G). Although the VEGF concentration in the serum was not correlated with that in the tissue, the VEGF concentration of glioblastoma cyst fluid was 200–300-fold higher than that in the serum of the patients. VEGF concentration in the tumors was significantly correlated with the vascularity measured by counting the vessels stained with von Willebrand factor antibody. There was a significant correlation between tissue concentration and a positive rate of expression of VEGF.

In another series, human malignant glioma samples (24 glioblastomas, 13 anaplastic astrocytomas) were stored at  $-80^{\circ}\text{C}$ . The protein expression of the most potent angiogenic factor, VEGF, and its specific natural inhibitor, soluble Flt-1 (data not shown), was measured via enzyme-linked immunosorbent assay (R&D Systems, Inc., Minneapolis, MN, USA).<sup>5</sup> Our treatment strategy for malignant gliomas at this time was total or subtotal removal, followed by 40 Gy



**Figure 1** VEGF concentration and immunolocalization in brain tumors.

**Notes:** (A) Strong expression is seen in the blood vessels in the tumor (arrow and high magnification at left lower corner) and in the edge of glioblastoma. In addition, strong expression is seen in the (B) cytoplasm of tumor cells (C) and around the areas of necrosis (n). (D) Expression is weaker in the anaplastic astrocytoma and (E) in the low-grade astrocytoma than in the glioblastoma. (F) VEGF is not expressed in the normal brain. (G) VEGF concentration in the tissue of glioblastomas is significantly higher than that in the tissues of other types of tumors, and in the tissue of the normal brain. (\* $P < 0.01$ ) (H) A VEGF concentration  $> 1,000$  pg/mg indicates a poor prognosis for malignant gliomas.

**Abbreviations:** VEGF, vascular endothelial growth factor; GBM, glioblastoma; AA, anaplastic astrocytoma; LGA, low grade astrocytoma; MEN, meningioma; LYM, lymphoma; META, metastatic tumor.

whole-brain and 20 Gy local boost irradiation combined with procarbazine, nimustine (ACNU), and vincristine chemotherapy and interferon-beta. At recurrence, cisplatin and etoposide chemotherapy and/or immunotherapy, including locolesional natural killer or cytotoxic T-lymphocyte injection, was carried out. The median survival rate of all malignant gliomas was 19.2 months (glioblastoma, 11.2 months; anaplastic astrocytoma, 30.9 months). A VEGF concentration of more than 1,000 pg/mg was a prognostic factor. Median OS of the patients with VEGF concentration  $\geq 1,000$  pg/mg (number [n]=20) was significantly shorter than in those with  $< 1,000$  pg/mg (n=17) at 11.8 months and 24.8 months, respectively ( $P=0.0025$ ; Figure 1H).

These results demonstrate that VEGF is localized in tumor cells and tumor endothelial cells in glioma, especially in glioblastoma, and its concentration predicts malignant glioma survival.

## Effect of VEGF antibody on an experimental glioma model

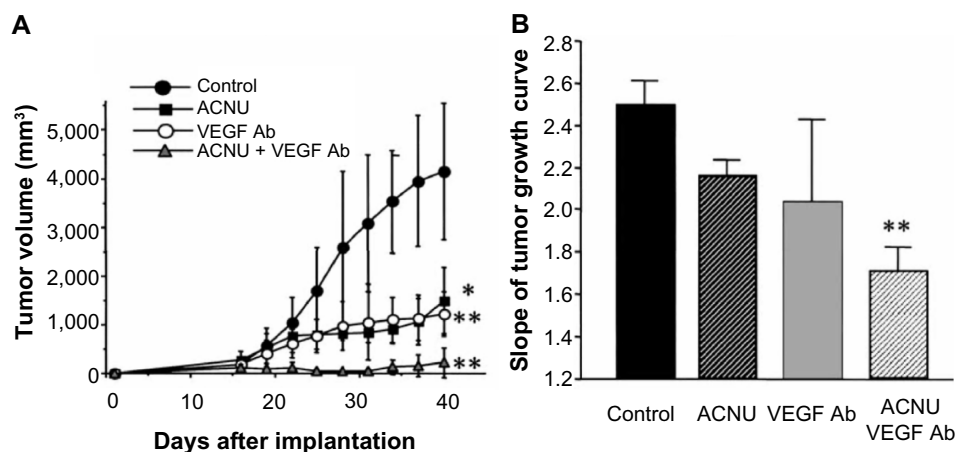
Antiangiogenesis properties and tumor growth inhibition were proven on an experimental human glioma xenograft model.<sup>6</sup> In the subcutaneous model, the additive effect of ACNU combined with VEGF antibody treatment on U87 MG subcutaneous growth was examined. Intraperitoneal injections of ACNU at 20 mg/kg (days 15, 19, and 23) and of VEGF antibody at 100  $\mu$ g/mouse (every 3 days, days 15–40, for a total of eight times) were given. Tumor volume was measured every 2 days in each group (n=6) and compared to the control (n=6) (Figure 2A). The experiment was repeated two times. The values of slopes of tumor growth were calculated.

The slope of the growth curve for each mouse in each group was measured; the slopes were then compared between groups. The value of the slope was significantly lower in the combined therapy group compared with the control and ACNU groups ( $P<0.01$ ; Figure 2B).

This combined effect of ACNU and VEGF antibody treatment for U87 MG growth and survival was also confirmed with the intracerebral model. The median survival times after implantation were  $34.0 \pm 1.9$  days (control group),  $41 \pm 1.9$  days (ACNU group),  $45.0 \pm 4.1$  days (VEGF antibody group), and  $52.8 \pm 5.5$  days (ACNU plus VEGF antibody group). Combination therapy significantly prolonged the survival of the mice bearing intracerebral U87 MG ( $P=0.0006$ ; Mantel–Cox log–rank test).

MIB-1 positivities and vessel densities for each group are shown in Table 1. Compared with each therapy alone, the combination of ACNU with the VEGF antibody demonstrated a stronger effect on the inhibition of the glioma cell's proliferative potential, as well as on vessel densities; in particular, the inhibitory effects on glioma cell proliferation were synergistic, not additive (one-way analysis of variance and Bonferroni test,  $P<0.001$ ).

Further study was conducted by investigating the direct action of the VEGF antibody on the glioma cell. VEGF receptor (VEGFR)2 is a tyrosine kinase receptor essential for VEGF-mediated physiological responses in endothelial cells. Traditionally, the VEGFRs were thought to be almost exclusively expressed by endothelial cells. Recent studies, however, suggest that tumor-derived VEGF provides not only paracrine survival cues for endothelial cells, but they may also fuel autocrine processes in glioblastoma cells (tumor-secreted



**Figure 2** VEGF antibody and ACNU inhibit glioma growth.

**Notes:** (A) With the subcutaneous model, ACNU combined with VEGF antibody treatment had an additive effect on U87 MG subcutaneous growth. The slope of the growth curve for each mouse in each group was measured. (B) The value of the slope is significantly lower in the combined therapy group than in the control and ACNU groups (\*\* $P<0.01$ ).

**Abbreviations:** ACNU, nimustine; VEGF, vascular endothelial growth factor; Ab, antibody.

**Table 1** MIB-1 positivities and vessel densities of U87 MG cells exposed to ACNU and VEGF Ab treatments

|  | Control  | ACNU       | VEGF Ab   | ACNU + VEGF Ab |
|--|----------|------------|-----------|----------------|
| MIB-1 (%)  | 73.5±6.4 | 54.4±11.4* | 51.5±5.6* | 7.9±2.7**      |
| Vessel density (number of vessels/0.13 mm <sup>2</sup> ) | 29.7±6.7 | 11.5±0.7*  | 6.8±5.9*  | 3.3±3.2**      |

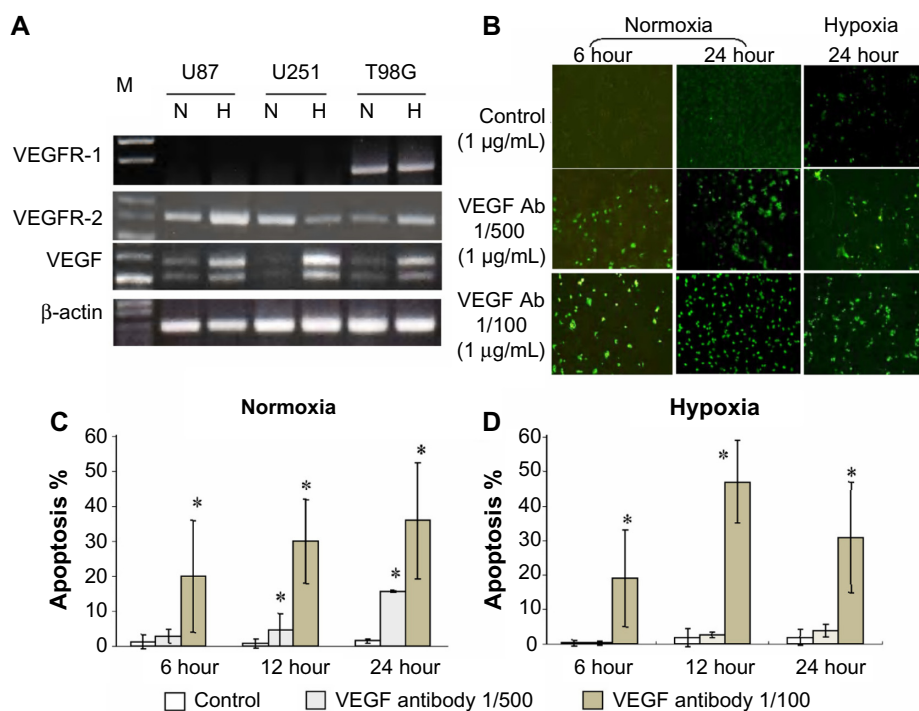
**Notes:** U87 MG cells were exposed to no treatment (control), only VEGF Ab treatment, only ACNU treatment, or to a combination of ACNU and VEGF Ab treatment. Values are mean ± standard deviation; \* $P < 0.05$ ; \*\* $P < 0.001$ .

**Abbreviations:** ACNU, nimustine; VEGF Ab, vascular endothelial growth factor antibody.

VEGF provides prosurvival signaling through VEGFRs expressed by the tumor cells themselves).<sup>7</sup> However, the precise mechanisms of the VEGF autocrine process have not been fully investigated. Blockade of VEGFR2 signaling decreased the survival of glioma cells and glioma stem-like cells.<sup>7,8</sup> We investigated the mechanism of VEGF blockade using the VEGF antibody for glioma cells.

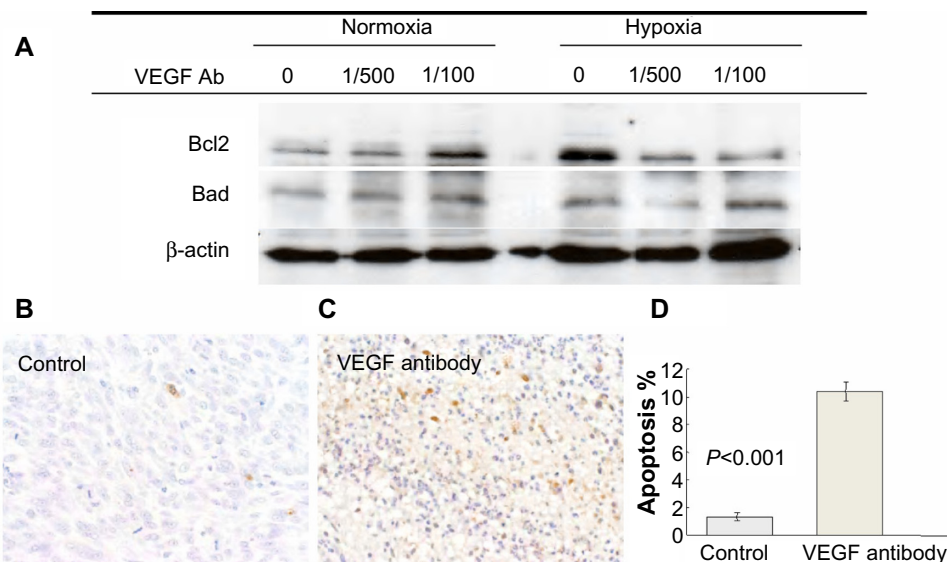
Three glioma cell lines, U87, U251, and T98G, revealed the expression of VEGFR1 and VEGFR2 in addition to VEGF. VEGFR2 expression was upregulated under hypoxic conditions with VEGF expression (Figure 3A). These results

suggest that the VEGF antibody may directly influence the glioma cell. Whether VEGF antibody exposure to glioma cells induces apoptosis was investigated using U87 cells. The cells were incubated with 5% CO<sub>2</sub> at 37°C for 6 hours and 24 hours under hypoxic (0.1% O<sub>2</sub>) or normoxic conditions (20% O<sub>2</sub>). Hypoxic conditions were established by placing cells in a GasPak Pouch (BD, Franklin Lakes, NJ, USA).<sup>9</sup> Cells were exposed to VEGF antibody at concentrations of 1 µg/mL (1/100 dilution), 0.2 µg/mL (1/500 dilution), and 0.0 µg/mL for 6 hours and 24 hours. With the Oncor ApopTag<sup>®</sup> in situ detection kit (EMD Millipore, Billerica, MA, USA), apoptotic cells were visualized as fluorescent-labeled cells. Under both normoxic and hypoxic conditions, glioma cell apoptosis increased significantly with the dose of VEGF antibody and the length of exposure to the antibody (Figure 3B–D). The molecular mechanisms of the induction of apoptosis with the VEGF antibody were investigated for the expression of apoptosis-related proteins, Bcl2 and Bad, on Western blot analysis. VEGF antibody exposure to glioma cells inhibited the upregulation of Bcl2 expression under hypoxic conditions (Figure 4A). VEGF antibody treatment induced apoptosis significantly more when compared to the control in the U87 subcutaneous

**Figure 3** Autocrine action of the VEGF Ab on glioma cells.

**Notes:** RT-PCR analysis of three glioma cell lines, U87, U251, and T98G, reveals the expression of VEGFR1 and VEGFR2 in addition to VEGF expression. (A) VEGFR2 expression was upregulated under hypoxic conditions with VEGF expression. (B–D) Under both normoxic and hypoxic conditions, glioma cell apoptosis increased significantly with the dose of VEGF antibody and the length of exposure to the Ab. \* $P < 0.01$ .

**Abbreviations:** VEGFR, vascular endothelial growth factor receptor; VEGF, vascular endothelial growth factor; M, molecular marker; N, normoxia; H, hypoxia; Ab, antibody; RT-PCR, reverse transcription polymerase chain reaction.



**Figure 4** Molecular mechanism of the VEGF Ab induction of glioma cells in vitro and in vivo.

**Notes:** (A) VEGF Ab exposure to glioma cells inhibited the upregulation of Bcl2 expression under hypoxic conditions. (B–D) VEGF Ab treatment induced apoptosis significantly compared to the control with the U87 subcutaneous tumor model.

**Abbreviations:** VEGF, vascular endothelial growth factor; Ab, antibody.

tumor model (Figure 4B–D). The experiment was repeated three times.

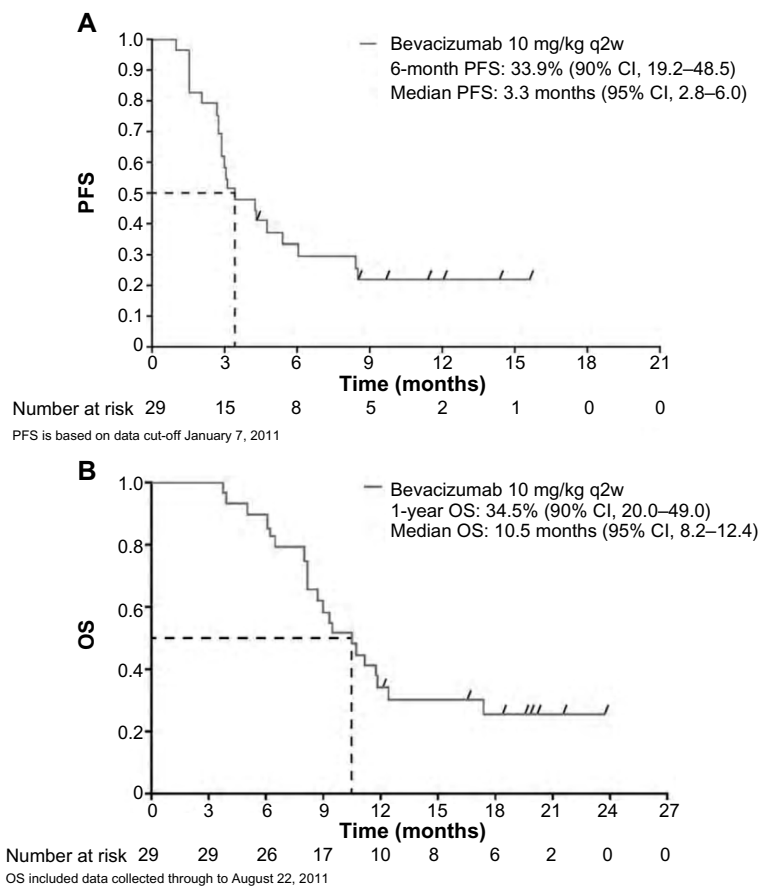
One mechanism by which the VEGF antibody blockades the autocrine VEGF–VEGFR system is the induction of apoptosis on glioma cells; this was demonstrated under both hypoxic conditions and normoxic ones. Anti-VEGF treatment induced a more than sevenfold increase in the percentage of apoptotic endothelial cells in the thyroid glands of healthy mice.<sup>10</sup> Because it caused enhanced apoptosis, the knockdown of *VEGFR2* dramatically decreased the survival of glioma stem-like cells.<sup>8</sup> Taken together, autocrine VEGF blockade on glioma cells are considered an important part of tumor growth inhibition through the induction of apoptosis.

## Clinical benefit of bevacizumab for Japanese glioma patients

Given the current evidence for bevacizumab effectiveness for recurrent glioblastomas in Western patient populations,<sup>11–14</sup> the efficacy and safety of single-agent bevacizumab in a Phase II, single-arm, open-label study in Japanese patients with recurrent malignant glioma was investigated.<sup>15</sup> Between August 2009 and July 2010, 31 patients were enrolled, 29 of whom were included in the efficacy analysis population. Patients with histologically confirmed, measurable glioblastoma or World Health Organization grade 3 glioma, previously treated with temozolomide plus radiotherapy, received a 10 mg/kg bevacizumab intravenous infusion every 2 weeks. The primary endpoint was 6-month PFS in the patients

with recurrent glioblastoma. Of the 31 patients enrolled, 29 (93.5%) had glioblastoma and two (6.5%) had grade 3 glioma.

All enrolled patients received a median of six bevacizumab doses. Treatment was discontinued in a total of 25 patients: 23 (74.2%) due to progressed disease; and two (6.5%) due to adverse effects. Efficacy and safety analyses, except for OS, were performed after an observation period of 6 months (data cutoff: January 7, 2011); the OS analyses, which included data collected through to August 22, 2011, were performed after all enrolled patients had been observed for 1 year. The 6-month PFS rate in the 29 patients with recurrent glioblastoma (primary endpoint) was 33.9% (90% confidence interval [CI], 19.2–48.5), and this exceeded the 15% threshold ( $P=0.0170$ ). Kaplan–Meier estimates of PFS showed a steady decline over the initial 6 months with a median PFS of 3.3 months (95% CI, 2.8–6.0) (Figure 5A). The 1-year survival rate for these patients was 34.5% (90% CI, 20.0–49.0) with a median OS of 10.5 months (95% CI, 8.2–12.4) (Figure 5B). There were eight responders (all partial responses) giving an objective response rate (Macdonald criteria) of 27.6%. Five patients (16.1%) had grade 3 adverse effects of special interest to bevacizumab. One patient (3.2%) had congestive heart failure, one patient (3.2%) had venous thromboembolism, and three patients (9.7%) had hypertension. Bevacizumab was well tolerated in our study, and the incidence of adverse effects of special interest to bevacizumab was similar to that seen in other published studies of single-agent bevacizumab.



**Figure 5** Clinical effect of bevacizumab on recurrent glioblastoma.

**Note:** Kaplan–Meier estimates of **(A)** PFS and **(B)** OS.

**Abbreviations:** q2w, every 2 weeks; PFS, progression-free survival; CI, confidence interval; OS, overall survival.

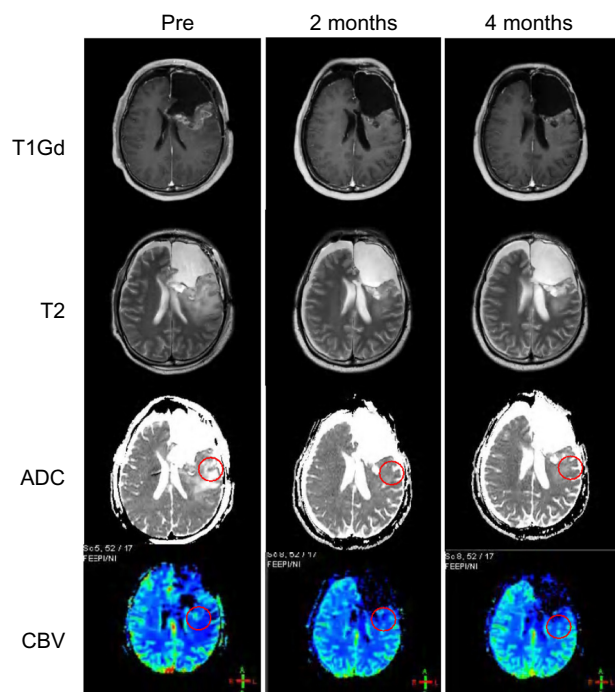
No new bevacizumab safety concerns were seen in this Japanese population.

This is the first clinical trial to investigate the safety and efficacy of single-agent bevacizumab in Japanese patients with recurrent glioblastoma. Our data demonstrated that 10 mg/kg of single-agent bevacizumab was effective in terms of the 6-month PFS, the objective response rate, as well as with respect to the OS and 1-year survival rate, and it was well tolerated in this Japanese population.

Prior to this Phase II study, we investigated the cohort study for the efficacy of bevacizumab on recurrent glioblastoma at a single institution; we especially focused on the response on magnetic resonance imaging (MRI) findings.<sup>16</sup> The anti-edema and antiangiogenic effects of bevacizumab were evaluated using the apparent diffusion coefficient (ADC) of peritumoral edema associated with the regional cerebral blood volume (rCBV) of the tumor. Ten patients with recurrent glioblastoma after temozolomide and radiation treatment were treated by bevacizumab every 2 weeks for 4–36 months (average: 12 months). An MRI

was performed every 2 months. On each MRI, the ADC value, the Gd-enhanced area on the T1 image, the area of peritumoral edema on the T2 image, and the rCBV on the perfusion image were measured. ADC and rCBV values were determined by the use of regions of interest positioned in areas of high signal intensities, as seen on T2-weighted images and ADC maps.

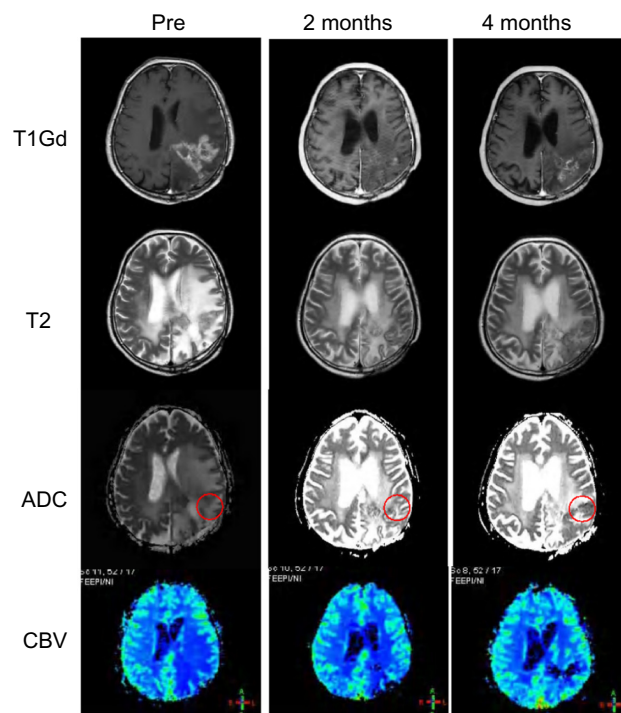
The Gd-enhanced area (Macdonald method), the T2 high-intensity area (Macdonald method), the ADC value, and the rCBV value were measured at pretreatment, 2 months after treatment, and 4 months after treatment for each case. After 2 months with bevacizumab treatment, the ADC and rCBV values decreased 49% and 32%, respectively; this was associated with a markedly smaller Gd-enhanced area compared to pretreatment. After 4 months, six of ten cases (group A) sustained diminished ADC values (2 months, 45.8%±8.1% and 4 months, 46.4%±8.6%) and rCBV values (2 months, 28.5%±36.1% and 4 months, 24.8%±24.7%). After 4 months, four of ten cases (group B) revealed elevated ADC values (2 months, 54.8%±19.7% and 4 months,



**Figure 6** Group A serial change with bevacizumab treatment at baseline, 2 months, and 4 months.

**Notes:** The patient was a 33-year-old male and had recurrent left frontal glioblastoma. Please note that even at 4 months, there is no tumor progression associated with the decrease of ADC and CBV values (red circle). This patient progressed for 30 months and died 39 months after bevacizumab treatment.

**Abbreviations:** Pre, pretreatment; T1Gd, Gd-enhanced T1 image; ADC, apparent diffusion coefficient; CBV, cerebral blood volume.



**Figure 7** Group A serial change with bevacizumab treatment at baseline, 2 months, and 4 months.

**Notes:** The patient was a 62-year-old male with recurrent left parietal glioblastoma. Please note at 4 months, the ADC and CBV values still remained low, even as the tumor progressed. This patient progressed for 4 months and died 10 months after bevacizumab treatment.

**Abbreviations:** Pre, pretreatment; T1Gd, Gd-enhanced T1 image; ADC, apparent diffusion coefficient; CBV, cerebral blood volume.

91.3%±10.3%) and rCBV values (2 months, 46.3%±5.3% and 4 months, 76.3%±19.4%). Two representative cases of group A were shown in Figure 6 (sustained diminished ADC and rCBV, with a sustained diminished Gd enhancement area) and Figure 7 (sustained diminished ADC and rCBV with increased Gd enhancement). The differences in each parameter change in groups A and B were demonstrated in Figure 8.

For groups A and B, PFS and OS were determined. The median PFS in group A was significantly longer than that in group B (27.9 months and 3.0 months, respectively; Figure 9A, log-rank test;  $P<0.01$ ). Also, the median OS in group A was significantly longer than that in group B (40.9 months and 7.0 months, respectively; Figure 9B, log-rank test;  $P<0.05$ ).

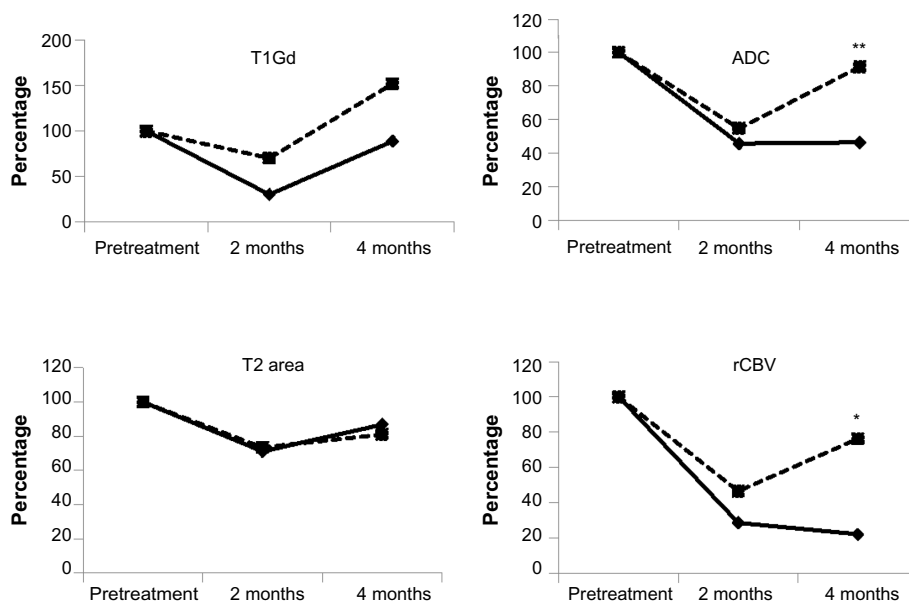
These results indicate that the anti-edema and antiangiogenic effects of bevacizumab for recurrent glioblastoma, demonstrated by the decreased ADC and rCBV values, was dramatic and prolonged OS for 4 months despite tumor progression. Most importantly, the ADC and rCBV values predicted the effectiveness of bevacizumab on recurrent glioblastoma in terms of patient prognosis, particularly after

an observation period of 4 months. An observation period of 2 months is not sufficient.

## Molecular mechanism of bevacizumab treatment failure on recurrent glioblastoma

A fraction of patients with cancer, including glioblastoma, are refractory to VEGF-inhibitor treatment.<sup>17</sup> For glioblastoma patients treated with bevacizumab, tumor recurrence inevitably occurs. Furthermore, recurrent tumors after bevacizumab failure are reported to be more aggressive and occur with rebound edema.<sup>17</sup> Potential mechanisms of resistance to targeted VEGF therapy in cancer are closely related to the mechanism of tumor vascular formation and to tumor biology. A solution to all the mechanisms of resistance is one promising method for future antiangiogenic treatment directed at the glioma microenvironment.<sup>17</sup>

We investigated the target molecule for bevacizumab treatment resistance in clinical cases and in an experimental model.<sup>18</sup> In this study, we detected the failure of bevacizumab treatment for treating malignant glioma through the



**Figure 8** Serial change of each parameter for pretreatment, 2 months, and 4 months after bevacizumab treatment.

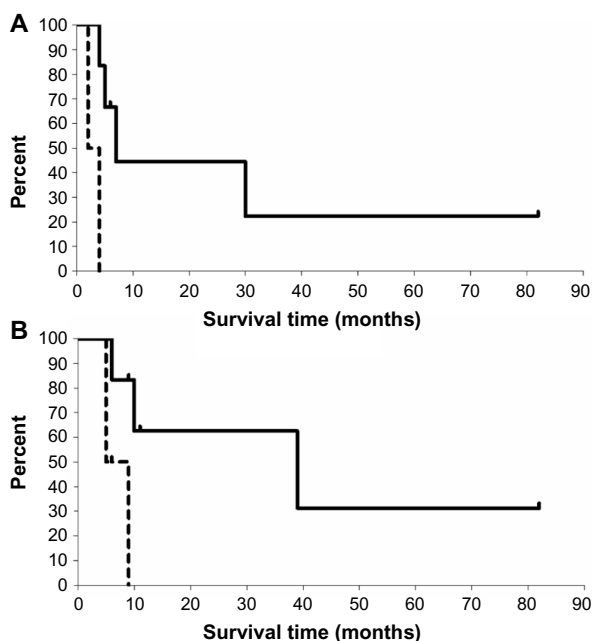
**Notes:** The solid line is group A and the dotted line is group B. At 2 months, each parameter significantly diminished compared to pretreatment. At 4 months, the T1Gd-enhanced area increased until it was equal to the pretreatment level (group A) and to over the pretreatment level (group B). At 4 months, the ADC and rCBV values diminished in group A, but they elevated to pretreatment levels in group B. \* $P < 0.05$ , \*\* $P < 0.01$  compared to group A.

**Abbreviations:** T1Gd, Gd-enhanced T1 image; ADC, apparent diffusion coefficient; rCBV, relative cerebral blood volume.

upregulation of metalloproteinase activity in the urine, as well as through infiltrative tumors seen on MRIs in clinical cases. In addition, matrix metalloproteinase (MMP)9 has been shown to be a molecule that facilitates its infiltrative behavior in vivo in the brain animal model. In a clinical case,

a 44-year-old female patient with right frontal recurrent glioblastoma was treated by bevacizumab monotherapy, 10 mg/kg, every 2 weeks for 12 weeks. Bevacizumab treatment resulted in the dramatic diminishment of a Gd-enhanced lesion with the improvement of clinical symptoms, such as headaches, during the 12 weeks. However, an MRI evaluation at 20 weeks demonstrated recurrence with diffuse progression (Figure 10A). MMP activities in urine at sequential periods were analyzed on gelatin zymogram (Figure 10B). The gelatinolytic activity of MMPs was evident as a clear band of lysis against the blue background of stained gelatin gel. Gelatin zymogram can differentiate active from inactive forms and detect the complex form with tissue inhibitor of metalloproteinases of gelatinases. MMP activities in the urine appeared as only MMP2 in pretreatment; it disappeared during the weeks 1, 2, 6 and 12, and appeared as both MMP2 and MMP9 at 20 weeks. The time course of MMP activities was well correlated with the clinical course of bevacizumab usage. In another case, MMP activities in urine were similar to the MMP9 activity that appeared during tumor progression (data not shown).

For further study, an animal model of bevacizumab failure was examined. For in vivo animal experiments, green fluorescent protein-labeled U87 glioblastoma cells ( $5 \times 10^5$ ) were implanted intracranially into seriously compromised immunodeficient mice (three mice per group). Beginning 4 days after implantation, animals were treated with VEGF antibody (5 mg/kg, intraperitoneally) once a week. One

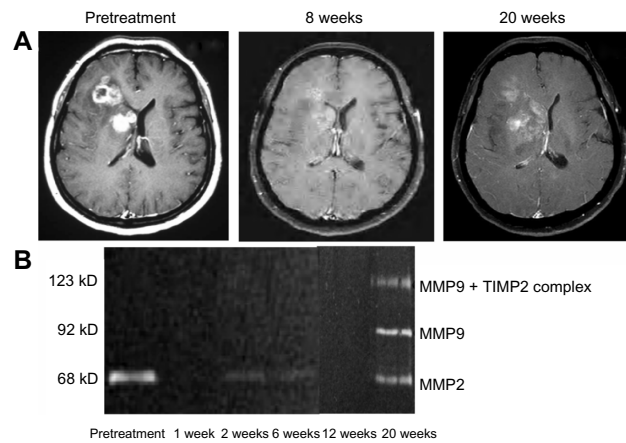


**Figure 9** Kaplan-Meier curve for PFS and OS between group A and group B.

**Notes:** (A) PFS; (B) OS. Solid line, group A; dotted line, group B. Median PFS is significantly longer in group A (27.9 months) than in group B (3.0 months) ( $P < 0.01$ ). Median OS is significantly longer in group A (40.9 months) than in group B (7.0 months) ( $P < 0.05$ ).

**Abbreviations:** PFS, progression-free survival; OS, overall survival.





**Figure 10** Clinical case: 44-year-old female patient with right frontal recurrent glioblastoma.

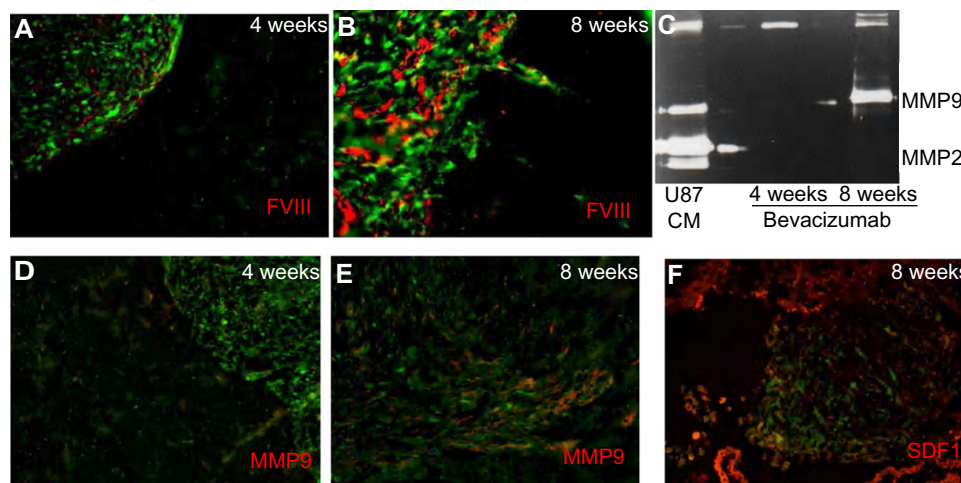
**Notes:** Serial MRI during bevacizumab monotherapy (10 mg/kg every 2 weeks for 12 weeks). **(A)** T1Gd-enhanced MRI on pretreatment, 8 weeks after treatment, and 20 weeks after treatment. Gelatin zymogram for MMP activities in urine at sequential periods. **(B)** MMP activity in urine appeared only as MMP2 at pretreatment, disappeared during 1 week, 2 weeks, 6 weeks, and 12 weeks, and appeared as both MMP2 and MMP9 at 20 weeks.

**Abbreviations:** MMP, matrix metalloproteinase; TIMP2, tissue inhibitor of metalloproteinase 2; MRI, magnetic resonance imaging; T1Gd, Gd-enhanced T1 image.

group was treated for 4 weeks (short-term treatment) and another group was treated for 8 weeks (long-term treatment). In the short-term treatment group, intracerebral glioma was well demarcated with little expression of MMP9 and stromal cell-derived factor (SDF)-1 $\alpha$  (Figure 11A and D). In the long-term treatment group, intracerebral glioma was invasive in the surrounding brain, and it markedly increased angiogenesis with upregulation of MMP9 and SDF-1 $\alpha$  expression (Figure 11B–F). In this animal model, MMP

activities in the urine were measured on gelatin zymogram. MMP9 activity was demonstrated only on animals treated for 8 weeks (Figure 11C). The pathological upregulation of MMP9 in this animal experiment and upregulation of urine MMP9 activities in these animal experiments and these clinical cases indicated that the invasive phenotype that develops after long-term bevacizumab treatment could be related to elevated levels of MMP9 activity.

The signals that regulate angiogenesis in primary tumors are distinct from those that are active in invasive tumors. Recently, a novel glioma model has been used to demonstrate, histologically, two distinct patterns of invasion – namely, angiogenesis-dependent invasion with the overexpression of angiogenesis-related genes such as those for VEGF, MMP9, hypoxia-inducible factor 1, and platelet-derived growth factor, and angiogenesis-independent invasion with overexpression of invasion-related genes such as those for integrin  $\alpha$ -v  $\beta$ -3, MMP2, nestin, and secreted protein acidic and rich in cysteine.<sup>19</sup> In another aspect, SDF-1 $\alpha$ , interleukin-6, basic fibroblast growth factor, and circulating progenitor cells are considered other escape biomarkers for antiangiogenic therapy.<sup>17</sup> In addition, new “anti-angiogenesis–response genes” such as mitotic checkpoint intermediates (*Bub1*, *Aurora-A*, and *Aurora-B*) and histone-encoding genes merit further investigation as markers of treatment efficacy in glioma patients treated with angiogenesis inhibitors, and they might constitute new therapeutic targets in cases of treatment failure.<sup>17</sup> This issue has been addressed in a prospective manner in a large international Phase III AVAglio trial for patients with newly diagnosed glioblastoma.<sup>2</sup> Patterns of



**Figure 11** An experimental bevacizumab failure glioma model.

**Notes:** In the short-term treatment group, **(A)** intracerebral glioma is well demarcated and less angiogenic, **(D)** with little expression of MMP9 and SDF-1 $\alpha$  (not shown). In the long-term treatment group, intracerebral glioma invades into surrounding brain and causes **(B)** marked angiogenesis with upregulation of **(E)** MMP9 and **(F)** SDF-1 $\alpha$  expression. In this animal model, MMP activities in the urine are measured on gelatin zymogram. **(C)** MMP9 activity is demonstrated only in animals treated for 8 weeks. U87 CM: U87 cell conditioned medium, positive control.

**Abbreviations:** FVIII, factor VIII; MMP, matrix metalloproteinase; SDF, stromal cell-derived factor.

radiographic progression were assessed in 65% of patients enrolled in the study, and they were compared to the baseline. At baseline, a diffuse pattern was observed in 60% of the placebo arm and 70% of the bevacizumab arm. Nondiffuse tumors (placebo arm, 40%; bevacizumab arm, 30%) changed to a diffuse pattern at progression in 22.8% and 24.7% cases, respectively, indicating no significant increase in the induction of an invasive pattern of recurrence following upfront bevacizumab treatment. These data from clinical trials and experiments indicate that it does not seem to be a universal phenomenon that antiangiogenic therapies induce preferentially diffuse invasive progression in glioblastoma, although a number of basic research studies have implicated it through several distinct mechanisms, including a shift of major proangiogenic factors ranging from VEGF to others, such as c-Met or SDF.<sup>20</sup>

Although antiangiogenic therapies for malignant gliomas are promising, the duration of response with available regimens is modest. As yet, there are no effective treatments for patients undergoing antiangiogenic therapies in whom the tumor progresses. Further understanding of the mechanisms and early detection of resistance to antiangiogenic therapies, such as through urinary MMP activity and serum MMP levels,<sup>21</sup> will be crucial for improvement in patients with malignant glioma.

## Effectiveness of bevacizumab on newly diagnosed glioblastoma: Japanese patients

Recently, two well-conducted, placebo-controlled, randomized trials – the AVAglio trial and the Radiation Therapy Oncology Group 0825 trial<sup>2,3</sup> – addressed the clinical benefit of adding bevacizumab to the best standard treatments (radiotherapy and temozolomide) for newly diagnosed glioblastoma.<sup>2,3</sup> The two trials were nearly identical in terms of design, patient characteristics, and the primary endpoints of PFS and OS. The consistency between the trial designs was mirrored by the consistency between the primary outcomes, with both trials showing a 3- to 4-month prolongation of PFS with bevacizumab, but no significant effect of the drug on OS.

Although survival remains the standard by which efficacy is measured, clinical benefit, measured by such variables as quality of life and other patient-reported outcomes, can potentially be used as a criterion for United States Food and Drug Administration approval of a new therapy for cancer. The AVAglio trial showed that bevacizumab improved or prolonged maintenance of quality of life and performance status.<sup>2</sup> This means a strong argument can be made for the

drug's use as part of the initial treatment of glioblastoma regardless of its effect on survival.

With regard to the AVAglio study, 44 patients from Japan were registered in the study. Bevacizumab's efficacy and safety were presented by Nakamura et al (Kumamoto University) at the 2013 annual meeting of the Japan Society of Neuro-Oncology. A total of 19 patients were assigned to the bevacizumab group and 25 patients to the placebo group. The median PFS was longer in the bevacizumab group than in the placebo group (12.2 months versus 8.7 months, respectively; stratified hazard ratio for progression or death, 0.71; 95% CI, 0.35–1.44;  $P=0.3356$ ). The benefit with respect to PFS was not statistically significant. OS was longer in the bevacizumab group than in the placebo group (29.2 months versus 20.2 months; stratified hazard ratio for progression or death, 0.58; 95% CI, 0.35–1.44;  $P=0.1752$ ). OS did not differ significantly between groups. Although not statistically significant, in the Japanese population, the median survival in the bevacizumab group was 9 months longer compared to the placebo group. For the total AVAglio study population, the median survival was almost similar in the bevacizumab group and the placebo group (16.8 months and 16.7 months, respectively). One of the reasons for this discrepancy between the Japanese population and the total study population may be the paucity of crossover usage of bevacizumab on tumor progression in the Japanese population. In the entire AVAglio study population, one third of the patients (144/463, 31%) in the placebo group received bevacizumab at the time of recurrence, thereby potentially diluting a bevacizumab-mediated survival advantage because of patient crossover.<sup>22</sup> By contrast, in the Japanese population, only four among 25 patients (16%) in the placebo group received bevacizumab at the time of recurrence, because bevacizumab was not approved for recurrent glioblastoma at that time in Japan.

Baseline health-related quality of life was maintained longer in the bevacizumab group than in the control group. In the bevacizumab group, grade 3 or higher adverse events associated with bevacizumab were observed: hypertension in five out of 19 patients (26.5%); and proteinuria in three out of 19 patients (15.8%). Other bevacizumab-specific adverse events such as intracerebral bleeding, intratumoral bleeding, and venous thromboembolism were not recognized. The researchers concluded that the additive effect of bevacizumab on newly diagnosed glioblastoma is considerable, but limited by tolerable safety.<sup>2</sup>

A representative long-term glioblastoma survivor with AVAglio study is presented from our institution. A 65-year-old

man with a newly diagnosed left parietal glioblastoma was registered in the AVAglio study. After partial removal and concomitant temozolomide and 60 Gy radiation therapy, temozolomide and bevacizumab maintenance therapy started in March 2010. Partial response was seen in serial MRIs. However, temozolomide and bevacizumab therapy were discontinued at the seventh cycle of bevacizumab monotherapy in November 2011 because of grade 3 thrombocytopenia, grade 2 hypertension, and grade 2 proteinuria. The tumor was well controlled until regrowth on July 2012, and the patient had a good Karnofsky performance score of 70%. PFS was 28 months. Stereotactic radiation (3 Gy  $\times$  13 times) was administered, but tumor growth control was insufficient and the patient died in June 2013. OS was 39 months. Because he survived for more than 3 years, he is considered a long-term glioblastoma survivor. Interestingly, in this case, the bevacizumab-specific adverse effects of hypertension and proteinuria were observed during therapy. This case shows that hypertension and proteinuria may be effective biomarkers in patients with newly diagnosed glioblastoma who are treated with bevacizumab, just as they are in patients with recurrent glioblastoma. In particular, it may be associated with a favorable effect on disease control, 6-month PFS, and median OS.<sup>23</sup>

Japan is the first, and so far only, country to approve the use of bevacizumab in combination with radiotherapy and temozolomide chemotherapy for newly diagnosed glioblastoma. The drug is also approved for use as a monotherapy for recurrent glioblastoma and for certain other types of high-grade glioma after previous therapy. The Japanese approval was based on the AVAglio study, the Phase II BRAIN study, and a Japanese Phase II study (JO22506).<sup>2,15,24</sup> Finally, it is worth noting that despite its limitations, bevacizumab remains the single most important therapeutic agent for glioblastoma since temozolomide was first used. Ongoing and future trials such as those targeting unresectable glioma and those conducted on elderly patients<sup>25,26</sup> will better define how and when bevacizumab should be used in this population of patients for whom so few treatment options currently exist.<sup>22</sup>

## Conclusion

- VEGF was highly expressed in glioblastoma.
- The VEGF concentration in tissue, but not in the serum, predicted the survival of the patients with malignant glioma; those with VEGF concentrations  $>1,000$  pg/mg had poor prognoses.
- Bevacizumab with and without ACNU inhibited glioma growth and angiogenesis in experimental glioma.

- PFS with bevacizumab alone was 34% at 6 months and 3.3 months at median for the patients with recurrent malignant glioma.
- MMP9 and SDF-1 were important molecules for bevacizumab failure (for example, invasive phenotype). Urine MMP9 may be a useful biomarker for bevacizumab failure.
- Bevacizumab decreased ADC values and rCBV values on MRIs even after glioma progression.
- PFS and OS with bevacizumab combined with standard temozolomide and radiotherapy were 12.2 months and 29.2 months at median, respectively, for the patients with newly diagnosed glioblastoma. PFS and OS tended to be longer for those treated with bevacizumab than for those not treated with the drug.

## Acknowledgments

We gratefully acknowledge Yoshiko Tsukada and Makiko Miyagawa for their excellent technical assistance. This work was supported in part by a Grant-in-Aid for Scientific Research from the Ministry of Education, Culture, Sports, Science and Technology of Japan (ST, no.24390339), the Japan Brain Foundation (ST), and the Japanese Foundation for Multidisciplinary Treatment of Cancer (ST).

## Author contributions

All authors contributed toward data analysis, drafting and revising the paper and agree to be accountable for all aspects of the work.

## Disclosure

The authors report no conflicts of interest in this work.

## References

1. Norden AD, Drappatz J, Wen PY. Novel anti-angiogenic therapies for malignant gliomas. *Lancet Neurol*. 2008;7(12):1152–1160.
2. Chinot OL, Wick W, Mason W, et al. Bevacizumab plus radiotherapy-temozolomide for newly diagnosed glioblastoma. *N Engl J Med*. 2014;370(8):709–722.
3. Gilbert MR, Dignam JJ, Armstrong TS, et al. A randomized trial of bevacizumab for newly diagnosed glioblastoma. *N Engl J Med*. 2014;370(8):699–708.
4. Takano S, Yoshii Y, Kondo S, et al. Concentration of vascular endothelial growth factor in the serum and tumor tissue of brain tumor patients. *Cancer Res*. 1996;56(9):2185–2190.
5. Takano S, Kamiyama H, Tsuboi K, Matsumura A, Nose T. Angiogenesis and antiangiogenic therapy for malignant gliomas. *Brain Tumor Pathol*. 2004;21(2):69–73.
6. Takano S, Tsuboi K, Matsumura A, Nose T. Anti-vascular endothelial growth factor antibody and nimustine as combined therapy: effects on tumor growth and angiogenesis in human glioblastoma xenografts. *Neuro Oncol*. 2003;5(1):1–7.

7. Knizetova P, Ehrmann J, Hlobilkova A, et al. Autocrine regulation of glioblastoma cell cycle progression, viability and radioresistance through the VEGF-VEGFR2 (KDR) interplay. *Cell Cycle*. 2008;7(16):2553–2561.
8. Hamerlik P, Lathia JD, Rasmussen R, et al. Autocrine VEGF-VEGFR2-Neuropilin-1 signaling promotes glioma stem-like cell viability and tumor growth. *J Exp Med*. 2012;209(3):507–520.
9. Kamiyama H, Takano S, Tsuboi K, Matsumura A. Anti-angiogenic effects of SN38 (active metabolite of irinotecan): inhibition of hypoxia-inducible factor 1 alpha (HIF-1alpha)/vascular endothelial growth factor (VEGF) expression of glioma and growth of endothelial cells. *J Cancer Res Clin Oncol*. 2005;131(4):205–213.
10. Yang Y, Zhang Y, Cao Z, et al. Anti-VEGF- and anti-VEGF receptor-induced vascular alteration in mouse healthy tissues. *Proc Natl Acad Sci U S A*. 2013;110(29):12018–12023.
11. Kreisl TN, Kim L, Moore K, et al. Phase II trial of single-agent bevacizumab followed by bevacizumab plus irinotecan at tumor progression in recurrent glioblastoma. *J Clin Oncol*. 2009;27(5):740–745.
12. Lai A, Filka E, McGibbon B, et al. Phase II pilot study of bevacizumab in combination with temozolomide and regional radiation therapy for up-front treatment of patients with newly diagnosed glioblastoma multiforme: interim analysis of safety and tolerability. *Int J Radiat Oncol Biol Phys*. 2008;71(5):1372–1380.
13. Narayana A, Kelly P, Golfinos J, et al. Antiangiogenic therapy using bevacizumab in recurrent high-grade glioma: impact on local control and patient survival. *J Neurosurg*. 2009;110(1):173–180.
14. Norden AD, Young GS, Setayesh K, et al. Bevacizumab for recurrent malignant gliomas: efficacy, toxicity, and patterns of recurrence. *Neurology*. 2008;70(10):779–787.
15. Nagane M, Nishikawa R, Narita Y, et al. Phase II study of single-agent bevacizumab in Japanese patients with recurrent malignant glioma. *Jpn J Clin Oncol*. 2012;42(10):887–895.
16. Takano S, Kimu H, Tsuda K, et al. Decrease in the apparent diffusion coefficient in peritumoral edema for the assessment of recurrent glioblastoma treated by bevacizumab. *Acta Neurochir Suppl*. 2013;118:185–189.
17. Takano S. Glioblastoma angiogenesis: VEGF resistance solutions and new strategies based on molecular mechanisms of tumor vessel formation. *Brain Tumor Pathol*. 2012;29(2):73–86.
18. Takano S, Mashiko R, Osuka S, Ishikawa E, Ohneda O, Matsumura A. Detection of failure of bevacizumab treatment for malignant glioma based on urinary matrix metalloproteinase activity. *Brain Tumor Pathol*. 2010;27(2):89–94.
19. Inoue S, Ichikawa T, Kurozumi K et al. Novel animal glioma models that separately exhibit two different invasive and angiogenic phenotypes of human glioblastomas. *World Neurosurg*. 2012;78(6):670–682.
20. McCarty JH. Glioblastoma resistance to anti-VEGF therapy: has the challenge been MET? *Clin Cancer Res*. 2013;19(7):1631–1633.
21. Tabouret E, Boudouresque F, Barrie M, et al. Association of matrix metalloproteinase 2 plasma level with response and survival in patients treated with bevacizumab for recurrent high-grade glioma. *Neuro Oncol*. 2014;16(3):392–399.
22. Fine HA. Bevacizumab in glioblastoma – still much to learn. *N Engl J Med*. 2014;370(8):764–765.
23. Lombardi G, Zustovich F, Farina P, et al. Hypertension as a biomarker in patients with recurrent glioblastoma treated with antiangiogenic drugs: a single-center experience and a critical review of the literature. *Anticancer Drugs*. 2013;24(1):90–97.
24. Friedman HS, Prados MD, Wen PY, et al. Bevacizumab alone and in combination with irinotecan in recurrent glioblastoma. *J Clin Oncol*. 2009;27(28):4733–4740.
25. Chauffert B, Feuvret L, Bonnetain F, et al. Randomized phase II trial of irinotecan and bevacizumab as neo-adjuvant and adjuvant to temozolomide-based chemoradiation compared with temozolomide-chemoradiation for unresectable glioblastoma: final results of the TEMAVIR study from ANOCEF†. *Ann Oncol*. 2014;25(7):1442–1447.
26. Holdhoff M, Chamberlain MC. Controversies in the treatment of elderly patients with newly diagnosed glioblastoma. *J Natl Compr Canc Netw*. 2013;11(9):1165–1172; quiz 1173.

## OncoTargets and Therapy

### Publish your work in this journal

OncoTargets and Therapy is an international, peer-reviewed, open access journal focusing on the pathological basis of all cancers, potential targets for therapy and treatment protocols employed to improve the management of cancer patients. The journal also focuses on the impact of management programs and new therapeutic agents and protocols on

Submit your manuscript here: <http://www.dovepress.com/oncotargets-and-therapy-journal>

patient perspectives such as quality of life, adherence and satisfaction. The manuscript management system is completely online and includes a very quick and fair peer-review system, which is all easy to use. Visit <http://www.dovepress.com/testimonials.php> to read real quotes from published authors.

Dovepress