

Blake's pouch cyst and Werdnig-Hoffmann disease: Report of a new association and review of the literature

Sherien A. Shohoud, Waleed A. Azab¹, Tarek M. Alsheikh¹, Rania M. Hegazy²

Neonatal Intensive Care Unit, ¹Department of Neurosurgery, Ibn Sina Hospital, ²Department of Diagnostic Radiology, Jahra Hospital, Kuwait City, Kuwait

E-mail: Sherien A. Shohoud - sherienshohoud@hotmail.com; *Waleed A. Azab - waleedazab@hotmail.com; Tarek M. Alsheikh - tmalsheikh@gmail.com;

Rania M. Hegazy - raniahegazy@hotmail.com

*Corresponding author

Received: 23 December 13 Accepted: 19 June 14 Published: 21 August 14

This article may be cited as:

Shohoud SA, Azab WA, Alsheikh TM, Hegazy RM. Blake's pouch cyst and Werdnig-Hoffmann disease: Report of a new association and review of the literature. *Surg Neurol Int* 2014;5:S282-8.

Available FREE in open access from: <http://www.surgicalneurologyint.com/text.asp?2014/5/5/282/139390>

Copyright: © 2014 Shohoud SA. This is an open-access article distributed under the terms of the Creative Commons Attribution License, which permits unrestricted use, distribution, and reproduction in any medium, provided the original author and source are credited.

Abstract

Background: We report a case of a neonate with proximal spinal muscular atrophy (SMA) type 1 (also known as Werdnig-Hoffmann disease or severe infantile acute SMA) associated with a Blake's pouch cyst; a malformation that is currently classified within the spectrum of Dandy-Walker complex. The association of the two conditions has not been previously reported in the English literature. A comprehensive review of the pertinent literature is presented.

Case Description: A male neonate was noted to have paucity of movement of the four limbs with difficulty of breathing and poor feeding soon after birth. Respiratory distress with tachypnea, necessitated endotracheal intubation and mechanical ventilation. Pregnancy was uneventful except for decreased fetal movements reported by the mother during the third trimester. Neurological examination revealed generalized hypotonia with decreased muscle power of all limbs, nonelicitable deep tendon jerks, and occasional tongue fasciculations. Molecular genetic evaluation revealed a homozygous deletion of both exons 7 and 8 of the survival motor neuron 1 (SMN1) gene, and exon 5 of the neuronal apoptosis inhibitory protein (NAIP) gene on the long arm of chromosome 5 consistent with Werdnig-Hoffmann disease (SMA type 1). At the age of 5 months, a full anterior fontanelle and abnormal increase of the occipito-frontal circumference were noted. Computed tomographic (CT) scan and magnetic resonance imaging (MRI) of the brain revealed a tetraventricular hydrocephalus and features of Blake's pouch cyst of the fourth ventricle.

Conclusions: This case represents a previously unreported association of Blake's pouch cyst and SMA type 1.

Key Words: Blake's Pouch Cyst, Dandy-Walker complex, spinal muscular atrophy, Werdnig-Hoffmann disease

Access this article online

Website:

www.surgicalneurologyint.com

DOI:

10.4103/2152-7806.139390

Quick Response Code:



INTRODUCTION

The spinal muscular atrophies (SMAs) are a genetically and clinically heterogeneous group of disorders characterized by degeneration and loss of anterior horn

cells of the spinal cord leading to muscle weakness and atrophy.^[84] Proximal SMA (types I-IV) accounts for 80-90% of all SMA cases and is primarily caused by recessive mutations in the survival motor neuron 1 (SMN1) gene located in the chromosome region

5q11.2-5q13.3, with homozygous absence of exon 7 in more than 95% of cases.^[48,59] Blake's pouch cyst, in contrast, is defined as a failure of regression of Blake's pouch (the rudimentary fourth ventricular tela choroidea) secondary to nonperforation of the foramen of Magendi resulting in a posterior ballooning into the cisterna magna.^[16,75] Failure of perforation of the foramen of Magendi results in enlargement of the fourth ventricle and the supratentorial ventricular system until the foramina of Luschka open and establish equilibrium of cerebrospinal fluid (CSF) outflow from the ventricles into the cisterns.^[16] Blake pouch cyst is one of the anomalies within the Dandy-Walker complex (DWC), which is a continuum of congenital anomalies comprising Dandy-Walker malformation (DWM), Dandy-Walker variant (DWW), mega cisterna magna (MCM) in addition to Blake's pouch cyst.^[20,78] To the best of our knowledge, the coexistence of SMA type 1 and Blake's pouch cyst (BPC) has not been previously reported in English literature.

CASE REPORT

A male neonate who is the first product of a nonconsanguineous marriage born at term with a body weight of 3.6 kg to a healthy young mother. Pregnancy was uneventful except for decreased fetal movements reported by the mother during the third trimester. Family history was negative for both parents.

Soon after birth, he was noticed to have paucity of movement of the four limbs with difficulty of breathing and poor feeding. He then developed respiratory distress with tachypnea, increased work of breathing, and oxygen desaturation that necessitated endotracheal intubation and mechanical ventilation. Clinically, his body weight, height and occipito-frontal circumference were all above 25th percentile; neurological examination revealed generalized hypotonia with decreased muscle power of all limbs, nonelicitable deep tendon jerks and occasional tongue fasciculations. No other clinical abnormalities were detected. Extensive metabolic workup and a TORCH (Toxoplasmosis, Rubella, Cytomegalovirus, Herpes simplex, HIV) screen revealed no abnormalities. Cranial and abdominal ultrasound examinations as well as cardiac echocardiogram were normal. Molecular genetic evaluation revealed a homozygous deletion of both exons 7 and 8 of the SMN1 gene, and exon 5 of the NAIP gene on the long arm of chromosome 5 consistent with Werdnig-Hoffmann disease (SMA type 1).

At the age of 5 months, a full anterior fontanelle and abnormal increase of the occipito-frontal circumference were noted. Computed tomographic (CT) scan and magnetic resonance imaging (MRI) of the brain revealed a tetraventricular hydrocephalus and features of BPC of

the fourth ventricle. Endoscopic third ventriculostomy or ventriculoperitoneal shunt insertion were both refused by the parents after detailed counseling. A follow up MRI done 3 months later showed progressive hydrocephalus [Figure 1].

The parents refused any surgical maneuver for CSF diversion including ventriculoperitoneal shunting or endoscopic third ventriculostomy. Now, for 11 months since admission to neonatal intensive care unit (NICU), many trials of extubation failed and he had to be re-intubated every time, due to increased work of breathing and desaturation. Over his NICU course, he developed frequent respiratory tract infections that were timely treated. Currently, the patient is kept on mechanical ventilation and is receiving only supportive care.

DISCUSSION

We report a case of proximal SMA type 1 (Werdnig-Hoffmann disease or severe infantile acute SMA) associated with a Blake's pouch cyst; a malformation that is currently classified within the spectrum of DWC. An exhaustive search of the Medline failed to retrieve any previously reported association of the two conditions in the English literature. The patient had a homozygous deletion of both exons 7 and 8 of the SMN1 gene, and exon 5 of the NAIP gene on the long arm of chromosome 5. In addition to the posterior fossa anomaly and hydrocephalus in our patient, both

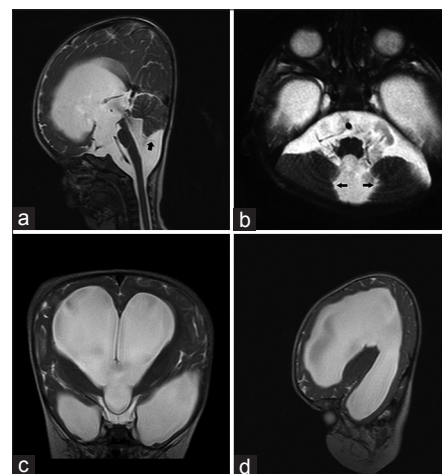


Figure 1: (a) Sagittal T2-weighted MR image demonstrating severe hydrocephalus with bulging third ventricular floor, open aqueduct and dilated fourth ventricle. Cerebellar vermis is compressed, relatively well-developed and is nonrotated. A thin line between dilated fourth ventricle and cisterna magna (Black arrow) indicates a Blake's pouch cyst. A high torcular Herophili with upward displacement of the tentorium is seen (b) Axial T2-weighted MR image with cystic dilatation of the fourth ventricle and compressed medial cerebellar hemispheres (Black arrows) (c) Coronal and (d) Sagittal T2-weighted MR images further demonstrate features of severe hydrocephalus

clinical and genetic findings are consistent with the diagnosis of proximal SMA type 1. In a seemingly similar case, Panas *et al.* reported a combination of distal SMA with DWC and anterior polar cataracts in two brothers aged 23 and 25 years.^[57] However, distal SMA and proximal SMAs represent completely different entities, making this case the first reported in the literature.

The spinal muscular atrophies

The SMAs are a genetically and clinically heterogeneous group of disorders characterized by degeneration and loss of anterior horn cells of the spinal cord leading to muscle weakness and atrophy.^[84] Proximal SMA (types I-IV) accounts for 80-90% of all SMA cases and is primarily caused by recessive mutations in the SMN1 gene located in the chromosome region 5q11.2- 5q13.3, with homozygous absence of exon 7 in more than 95% of cases.^[48,59] Alias *et al.* found homozygous absence of SMN1 exons 7 and 8 in 671 (90%) of 745 SMA patients. SMN gene is present in two highly homologous copies, SMN1 and SMN2, but only deletions of the SMN1 gene (exons 7 and 8 or exon 7) are responsible for clinical manifestations of SMA.^[5] Extended deletions that include the NAIP gene may correlate with the severity of SMA.^[48]

Depending on the age of onset, the maximum muscular activity achieved, and survivorship, proximal SMA types are classified as type I (Phenotype MIM number 253300), severe infantile acute SMA, or Werdnig-Hoffman disease; type II (Phenotype MIM number 253550), or infantile chronic SMA; type III (Phenotype MIM number 253400), juvenile SMA, or Wohlfart-Kugelberg-Welander disease; and type IV (Phenotype MIM number 271150), or adult-onset SMA.^[54]

Non-SMN1 SMAs include nonproximal SMA, bulbar palsy, spinobulbar muscular atrophy (SBMA), and infantile SMA variants also known as “SMA plus”.^[57,84] These variants are characterized by SMA with additional or atypical features. They include SMA with respiratory distress, which can be caused by recessive mutations in Immunoglobulin μ -binding protein 2 (IGHMBP2); infantile lethal X-linked SMA with arthrogryposis and congenital fractures (SMAX2), caused by mutations in ubiquitin-activating enzyme E1 (UBE1); SMA1 with arthrogryposis and bone fractures, and SMA with pontocerebellar hypoplasia (SMA-PCH), also known as PCH type 1.^[59]

Dandy-Walker complex and Blake’s pouch cyst

The posterior fossa anomaly and the associated hydrocephalus in the patient of this report represent a BPC that is currently classified within the spectrum of DWC. DWC is a continuum of congenital anomalies comprising DWM, DWV, Blake’s pouch cyst, and MCM.^[20,78] These anomalies are characterized by varying

degrees of malformation of the medullary vela, the cerebellar vermis and hemispheres, the fourth ventricle choroid plexus, the posterior fossa subarachnoid cisterns, and the enveloping meningeal structures.^[16] Persistent Blake’s pouch and MCM are thought to represent less severe abnormalities within the Dandy-Walker continuum.^[60]

The original description of DWM dates back to the year 1914 when Dandy and Blackfan described a huge cystic dilatation of the fourth ventricle with anterior displacement of the cerebellar vermis that was attributed to primary atresia of the foramina of the fourth ventricle.^[22] Over the following years many cases were reported, expanding the limits of the malformation to include findings of one particular case or another, and in the meanwhile creating a great deal of confusion about the definition and limits of the syndrome.^[42] Taggart and Walker in 1942 further defined the condition.^[70] Subsequently, Benda in 1954 introduced the now widely accepted name of DWM and was the first to introduce the currently held opinion that atresia of the cerebellar foramina is not an essential feature of the malformation.^[12]

Tortori-Donati *et al.* added persistent BPC as an independent entity within the DWC.^[75] BPC is thought to result from failure of regression of Blake’s pouch (the rudimentary fourth ventricular tela choroidea) secondary to nonperforation of the foramen of Magendi.^[75] Failure of perforation of the foramen of Magendi results in enlargement of the fourth ventricle and the supratentorial ventricular system until the foramina of Luschka open and establish equilibrium of CSF outflow from the ventricles into the cisterns.^[16] However, as the larger foramen of Magendi is permanently missing, the ventricles will stay enlarged.^[20] The cerebellar hemispheres and vermis would rather be compressed (to a certain degree) than underdeveloped and would therefore re-expand in case of ventricular shunting.^[9]

Typical radiological features of BPC are (i) tetraventricular hydrocephalus, (ii) infra- or retrocerebellar localization of the cyst, (iii) a relatively well-developed, nonrotated cerebellar vermis (as opposed to a DW), (iv) a cystic dilatation of the fourth ventricle without cisternal communication, and (v) some degree of compression on the medial cerebellar hemispheres. Ideally, one may see the fourth ventricular choroid plexus continuing in the roof of the cyst on sagittal MR images.^[20] These features were all noted in our patient’s MR images [Figure 1]. Classically, the choroid plexus of the fourth ventricle is displaced into the superior cyst wall in Blake’s pouch, absent in DWM, and normal in arachnoid cyst.^[52] As it is evident in our patient [Figure 1], BPC may push the developing tentorium into an abnormal, relatively high position.^[25] BPC is capable of producing a broad

spectrum of findings ranging from being asymptomatic to a full-blown hydrocephalus.^[20]

DWC has been associated with a long list of chromosomal and phenotypic abnormalities of both neural and mesenchymal elements [Table 1]. Heterozygous deletion of *ZIC1* and *ZIC4* on chromosome 3q24 was the first molecularly defined cause of classic DWM.^[31] A second DWM-linked locus on 6p25.3 was associated with deletions or duplications encompassing *FOXC1* causing cerebellar and posterior fossa malformations including cerebellar vermis hypoplasia (CVH), MCM and DWM. *Foxc1*-null mice have embryonic abnormalities of the rhombic lip due to loss of mesenchyme-secreted signaling molecules with subsequent loss of *Atoh1* expression in vermis. Specific loss of *FOXC1* and general defects in mesenchymal signaling may result in cerebellar malformations.^[3]

Spinal muscular atrophy with pontocerebellar hypoplasia

SMA-PCH (PCH-1) is an important differential diagnosis of the case reported herein, and can be excluded based on both genetic and radiological grounds; SMA-PCH is a non-SMN1 condition on contrary to our patient with homozygous deletion of both exons 7 and 8 of the SMN1 gene on chromosome 5. MRI of our patient reveals a normal appearance of the brainstem and ventral pons in addition to other findings consistent with BPC [Figure 1]. PCH-1 is an autosomal-recessive disease of prenatal or infantile onset characterized by PCH and ventral horn cell degeneration. Clinically, polyhydramnios is usually present during pregnancy, and affected individuals present with bulbar dysfunction that leads to neonatal respiratory insufficiency, feeding difficulty, and congenital contractures; death often occurs before 1 year of age.^[46] An extended clinical spectrum of PCH 1 with later onset of hypotonia, varying degrees of cerebellar or pontine hypoplasia and atrophy, peripheral nerve involvement, and longer survival has been reported.^[61] All PCH syndromes [types 1-6] include a small cerebellum and brainstem with progressive microcephaly being a common finding.^[59]

It is of relevance to this discussion to review the molecular genetic abnormality underlying PCH-1; namely the Vaccinia-related kinase 1 (VRK1) gene abnormality owing to its role in the pathogenesis of SMA and its probable contribution to the evolution of some cerebellar and posterior fossa congenital anomalies [Figure 2]. Renbaum *et al.* discovered a premature stop codon in the VRK1 gene that encodes a serine-threonine kinase and is located on chromosome 14q32 in affected siblings with PCH-1 in one family. VRK1 may be specifically important for spinal motor neuron survival or that it may also play a role in tRNA processing. In either case, identification of a VRK1 mutation as a cause of SMA-PCH points to new roles for this protein and suggests VRK2 [chromosome

Table 1: Clinical and chromosomal abnormalities associated with Dandy-Walker complex

	Ref.
Conditions associated with DWM	
Autosomal recessive osteopetrosis	13
Atrial septal defect	19
Beemer-Langer syndrome	44
Bifid hallux	65
Blepharophimosis/ptosis/epicanthus inversus syndrome	43
Cardiomyopathy (hypertrophic)	6
Cataracts	27
Collodion skin	27
Corpus callosum dysgenesis	13, 27
Crouzon syndrome	4
Cryptorchidism	27
Cerebral venous sinus thrombosis	33
Chondrodysplasia punctata with multiple anomalies	50
Ellis-van Creveld syndrome	82
Guschnann mesomelic campomelia polydactyly	32
Hypoparathyroidism	19
Jeune's asphyxiating thoracic dystrophy	66
Kallmann's syndrome	2
Keratitis-ichthyosis-deafness syndrome (kid)	72
Klippel-Feil syndrome	8
Meso-axial polydactyly	65
Microcephaly	18
Moerman lethal dysplasia	49
Neurocutaneous melanosis	47
Occipital encephalocele	15
Occipital meningoencephalocele	65
Parietal encephalocele	36
Phaces syndrome	45
Polymicrogyria	10
Renal agenesis	19
Rhombencephalosynapsis	64
Ritscher-Schinzel (cranio-cerebello-cardiac, 3c) syndrome with renal involvement	63
Syringomyelia	40
Turner syndrome	10
Ventricular septal defect	19
Chromosomal Abnormalities Associated with DWM	
Translocation (12;17;18) (q21.2;q22;q21.1)	1
Heterozygous deletions encompassing the <i>ZIC1</i> / <i>ZIC4</i> loci on 3q24	14,73
Partial trisomy 7p (7p15.3→pter), partial monosomy 13q (13q33.3→qter)	18
Mutations of the gene coding for emopamil binding protein (EBP)	27
Chromosome 2q36.1 abnormality	39
Conditions associated with DWV	
Atrial septal defect	56, 62
Autism	62
Cerebral palsy	62
Cerebro-fronto-facial syndrome	74

Table 1: Contd...

	Ref.
Cleft lip	62
Cleft palate	62
Coffin-Siris syndrome	38
Congenital diaphragmatic hernia	62
Cortical blindness	62
Ehlers-Danlos syndrome	53
Falot's tetralogy	56
Gastroesophageal reflux disease	62
Hypertelorism	62
Hypoplastic right heart	62
Hypothyroidism	56
Hypotonia	62
Intraventricular hemorrhage	62
Malrotation of the gut	62
Menkes syndrome (Kinky-hair disease)	11
Microcephaly	62
Neurocutaneous melanosis	41
Omphalocele	62
Patent ductus arteriosus	56, 62
Pierre Robin sequence	62
Progressive encephalopathy	62
Pulmonary artery stenosis	62
Ventricular septal defect	62
Seizure disorder	62
Senior-Loken syndrome	62
Smith-Lemli-Opitz syndrome	62
Spastic hereditary paraplegia	68
Tracheoesophageal fistula	62
Transposition of the great vessels	62
Chromosomal Abnormalities Associated with DWV	
Long-arm deletion of chromosome 3	17
Deletions on chromosome 8	23
Partial imbalances 6q and 11q	79
Partial trisomies of 9, 11, and 13	62
Chromosome 8 mosaicism	62

DWV: Dandy-Walker variant

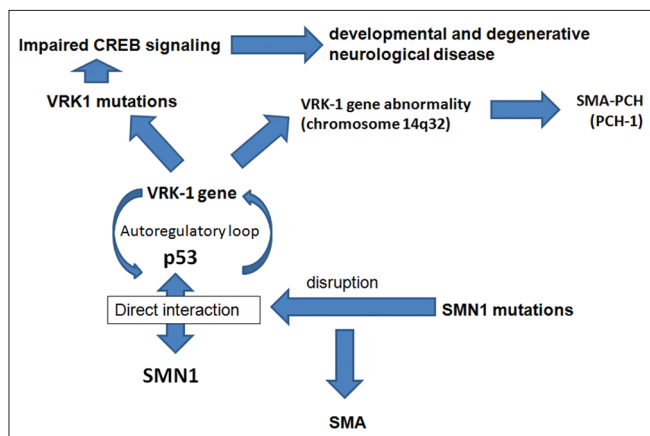


Figure 2: Schematic representation of the genetic events and interactions between VRK-1, SMA, and PCH-I

2p16] and VRK3 [chromosome 19q13] as candidate genes for related phenotypes, including other PCHs and other SMAs.^[59]

The existence of an autoregulatory loop between VRK1 and p53 may be of relevance to both development and maintenance of the nervous system. p53 regulates cell division and death during nervous system development and in response to neuronal insult or injury during life. Recessive mutations in Ataxia telangiectasia mutated (ATM), which phosphorylate p53 in response to DNA damage cause ataxia telangiectasia, in which loss of cerebellar neurons and ataxia are prominent features.^[59] Moreover, p53 interacts directly with SMN1, an association disrupted by SMN1 mutations associated with SMA,^[81] and might be of relevance to SMA pathogenesis.^[76] In addition, VRK1 may be involved in cell cycle regulation, organization of chromatin, and organization of the nuclear envelope.^[46] The role of VRK1 in cyclic AMP (cAMP) response element-binding (CREB) activation suggests that VRK1 mutations may lead to impaired CREB signaling, which can result in both developmental and degenerative neurological disease; Coffin-Lowry syndrome is caused by mutations in RSK2, another CREB kinase, Rubinstein-Taybi syndrome can be caused by mutations in CREBBP (a CREB binding protein). Interference with CREB-dependent transcription is a feature of polyglutamine stretches, common in spinocerebellar ataxias. CREB also binds to the SMN promoter and increases SMN expression, so its deficiency could promote an SMA phenotype.^[59]

As it is well known that mutations in multiple genes can cause various central nervous system malformations,^[46] we think that future reports and studies may reveal important molecular genetic links between DWV (specifically BPC) and Werdnig-Hoffmann disease.

CONCLUSION

This case represents a previously unreported association of BPC and SMA type I that further expands the current literature, and potentially directs future investigation of probable molecular genetic links between these conditions.

REFERENCES

1. Al-Achkar W, Wafa A, Jarjour R. A new case of de novo translocation (12;17)(q21.2;q22;q21.1) and cranio-cerebello-cardiac (3C) syndrome. *Am J Med Genet A* 2011;155A: 648-51.
2. Aluclu MU, Bahceci S, Bahceci M. A rare embryological malformation of brain-Dandy-Walker syndrome-and its association with Kallmann's syndrome. *Neuro Endocrinol Lett* 2007;28:255-8.
3. Aldinger KA, Lehmann OJ, Hudgins L, Chizhikov VV, Bassuk AG, Ades LC, et al. FOXC1 is required for normal cerebellar development and is a major contributor to chromosome 6p25.3 Dandy-Walker malformation. *Nat Genet* 2009;41:1037-42.

4. Alexiou GA, Prodromou N. Dandy-Walker malformation in Crouzon syndrome. *J Child Neurol* 2010;25:653.
5. Alias L, Bernal S, Fuentes-Prior P, Barcelo M, Also E, Martinez-Hernandez R, et al. Mutation update of spinal muscular atrophy in Spain: Molecular characterization of 745 unrelated patients and identification of four novel mutations in the SMN1 gene. *Hum Genet* 2009;125:29-39.
6. Al-Mendalawi MD. Dandy Walker malformation and hypertrophic cardiomyopathy. Unusual fatal association. *Neurosciences (Riyadh)* 2010;15:55.
7. Altman NR, Naidich TP, Braffman BH. Posterior fossa malformations. *AJNR Am J Neuroradiol* 1992;13:691-724.
8. Asai A, Hoffman HJ, Hendrick EB, Humphreys RP. Dandy-Walker syndrome: Experience at the Hospital for Sick Children, Toronto. *Pediatr Neurosci* 1989;15:66-73.
9. Barkovich AJ. Congenital malformations of the brain and skull. In Barkovich AJ editor, *Pediatric Neuroimaging*, 2nd ed. New York; Raven; 1994. p. 177-275.
10. Baxi LV, Walsh CA. Cerebral venous sinus thrombosis, Dandy-Walker malformation and polymicrogyria in Turner syndrome: An unreported association. *Prenat Diagn* 2009;29:899-900.
11. Bekiesińska-Figatowska M, Rokicki D, Walecki J, Gremida M. Menkes' disease with a Dandy-Walker variant: Case report. *Neuroradiology* 2001;43:948-50.
12. Benda CE. The Dandy-Walker syndrome of the so-called atresia of the foramen of Magendie. *J Neuropathol Exp Neurol* 1954;13:14-29.
13. Ben Hamouda H, Sfar MN, Braham R, Ben Salah M, Ayadi A, Soua H, et al. Association of severe autosomal recessive osteopetrosis and Dandy-Walker syndrome with agenesis of the corpus callosum. *Acta Orthop Belg* 2001;67:528-32.
14. Blank MC, Grinberg I, Aryee E, Laliberte C, Chizhikov VV, Henkelman RM, et al. Multiple developmental programs are altered by loss of Zic1 and Zic4 to cause Dandy-Walker malformation cerebellar pathogenesis. *Development* 2011;138:1207-16.
15. Cakmak A, Zeyrek D, Cekin A, Karazeybek H. Dandy-Walker syndrome together with occipital encephalocele. *Minerva Pediatr* 2008;60:465-8.
16. Calabrò F, Arcuri T, Jinkins JR. Blake's pouch cyst: An entity within the Dandy-Walker continuum. *Neuroradiology* 2000;42:290-5.
17. Chen CP, Tzen CY, Chang TY, Lin CJ, Wang W, Lee CC. Prenatal diagnosis of partial trisomy 3p and partial monosomy 11q in a fetus with a Dandy-Walker variant and trigonocephaly. *Prenat Diagn* 2002;22:1112-3.
18. Chen CP, Chen M, Su YN, Tsai FJ, Chern SR, Hsu CY, et al. Prenatal diagnosis and molecular cytogenetic characterization of de novo partial trisomy 7p (7p15.3 → pter) and partial monosomy 13q (13q33.3 → qter) associated with Dandy-Walker malformation, abnormal skull development and microcephaly. *Taiwan J Obstet Gynecol* 2010;49:320-6.
19. Coban D, Akin MA, Kurtoglu S, Oktem S, Yikilmaz A. Dandy-Walker malformation: A rare association with hypoparathyroidism. *Pediatr Neurol* 2010;43:439-41.
20. Cornips EM, Overvliet GM, Weber JW, Postma AA, Hoeberigs CM, Baldewijns MM, et al. The clinical spectrum of Blake's pouch cyst: Report of six illustrative cases. *Childs Nerv Syst* 2010;26:1057-64.
21. D'Agostino AN, Kernohan JW, Brown JR. Dandy-Walker syndrome. *J Neuropathol Exp Neurol* 1963;22:450-70.
22. Dandy WE, Blackfan KD. Internal hydrocephalus. *Am J Dis Child* 1914;8:406-82.
23. Donahue ML, Ryan RM. Interstitial deletion of 8q21→22 associated with minor anomalies, congenital heart defect, and Dandy-Walker variant. *Am J Med Genet* 1995;56:97-100.
24. Ecker JL, Shipp TD, Bromley B, Benacerraf B. The sonographic diagnosis of Dandy-Walker and Dandy-Walker variant: Associated findings and outcomes. *Prenat Diagn* 2000;20:328-32.
25. Epelman M, Daneman A, Blaser SI, Ortiz-Neira C, Konen O, Jarrin J, et al. Differential diagnosis of intracranial cystic lesions at head US: Correlation with CT and MR imaging. *Radiographics* 2006;26:173-96.
26. Estroff JA, Scott MR, Benacerraf BR. Dandy-Walker variant: Prenatal sonographic features and clinical outcome. *Radiology* 1992;185:755-8.
27. Furtado LV, Bayrak-Toydemir P, Hulinsky B, Damjanovich K, Carey JC, Rope AF. A novel X-linked multiple congenital anomaly syndrome associated with an EBP mutation. *Am J Med Genet A* 2010;152A:2838-44.
28. Gibson JB. Congenital hydrocephalus due to atresia of the foramen of Magendie. *J Neuropathol Exp Neurol* 1955;14:244-62.
29. Golden JA, Rorke LB, Bruce DA. Dandy-Walker syndrome and associated anomalies. *Pediatr Neurosci* 1987;13:38-44.
30. Gonsette R, Potvliege R, Andre-Galaisaux G, Stenuit J. La mega grande citerne: Etude clinique, radiologique et anatomopathologique. *Acta Neurol Psychiatr Belg* 1968;68:559-70.
31. Grinberg I, Northrup H, Ardinger H, Prasad C, Dobyns WB, Millen KJ. Heterozygous deletion of the linked genes ZIC1 and ZIC4 is involved in Dandy-Walker malformation. *Nat Genet* 2004;36:1053-5.
32. Guschmann M, Horn D, Entezami M, Urban M, Hälal S, Kunze J, et al. Mesomelic campomelia, polydactyly and Dandy-Walker cyst in sibs. *Prenat Diagn* 2001;21:378-82.
33. Gverić-Ahmetasević S, Colić A, Gverić T, Gasparović VE, Pavliša G, Ozretić D. Coexistence of cerebral sinovenous thrombosis and Dandy-Walker malformation in newborn. *Coll Antropol* 2011;35 Suppl 1:303-7.
34. Hart MN, Malamud N, Ellis WG. The Dandy-Walker syndrome: A clinicopathological study based on 28 cases. *Neurology* 1972;22:771-80.
35. Harwood-Nash DC, Fitz CR. *Neuroradiology in infants and children*. Vol. 3. St Louis: Mosby; 1976. p. 1014-9.
36. Hindryckx A, De Catte L, Van Esch H, Fryns JP, Moerman P, Devlieger R. First trimester prenatal diagnosis of 13q-syndrome presenting with increased nuchal translucency, Dandy-Walker malformation and small parietal encephalocele. *Prenat Diagn* 2008;28:445-6.
37. Hirsch JF, Pierre-Kahn A, Renier D, Sainte-Rose C, Hoppe-Hirsch E. The Dandy-Walker malformation. A review of 40 cases. *J Neurosurg* 1984;61:515-22.
38. Imai T, Hattori H, Miyazaki M, Higuchi Y, Adachi S, Nakahata T. Dandy-Walker variant in Coffin-Siris syndrome. *Am J Med Genet* 2001;100:152-5.
39. Jalali A, Aldinger KA, Chary A, McLone DG, Bowman RM, Le LC, et al. Linkage to chromosome 2q36.1 in autosomal dominant Dandy-Walker malformation with occipital cephalocele and evidence for genetic heterogeneity. *Hum Genet* 2008;123:237-45.
40. Kasliwal MK, Suri A, Sharma BS. Dandy Walker malformation associated with syringomyelia. *Clin Neurol Neurosurg* 2008;110:317-9.
41. Kim YJ, Won YD, Kim KT, Chang ED, Huh PW. Parenchymal neurocutaneous melanosis in association with intraventricular dermoid and Dandy-Walker variant: A case report. *Korean J Radiol* 2006;7:145-8.
42. Kollias SS, Ball WS Jr, Prenger EC. Cystic malformations of the posterior fossa: Differential diagnosis clarified through embryologic analysis. *Radiographics* 1993;13:1211-31.
43. Lim BC, Park WY, Seo EJ, Kim KJ, Hwang YS, Chae JH. De novo interstitial deletion of 3q22.3-q25.2 encompassing FOXL2, ATR, ZIC1, and ZIC4 in a patient with blepharophimosis/ptosis/epicanthus inversus syndrome, Dandy-Walker malformation, and global developmental delay. *J Child Neurol* 2011;26:615-8.
44. Lin AE, Doshi N, Flom L, Tenenholz B, Filkins KL. Beemer-Langer syndrome with manifestations of orofaciocaudal syndrome. *Am J Med Genet* 1991;39:247-51.
45. Lopez-Gutierrez JC. PHACES syndrome and ectopia cordis. *Interact Cardiovasc Thorac Surg* 2011;12:642-4.
46. Maricich SM, Aqeeb KA, Moayed Y, Mathes EL, Patel MS, Chitayat D, et al. Pontocerebellar hypoplasia: Review of classification and genetics, and exclusion of several genes known to be important for cerebellar development. *J Child Neurol* 2011;26:288-94.
47. Marnet D, Vinchon M, Mostofi K, Cateau B, Kerdraon O, Dhellemmes P. Neurocutaneous melanosis and the Dandy-Walker complex: An uncommon but not so insignificant association. *Childs Nerv Syst* 2009;25:1533-9.
48. Miskovic M, Lalic T, Radivojevic D, Cirkovic S, Vlahovic G, Zamurovic D, et al. Lower incidence of deletions in the survival of motor neuron gene and the neuronal apoptosis inhibitory protein gene in children with spinal muscular atrophy from Serbia. *Tohoku J Exp Med* 2011;225:153-9.
49. Moerman P, Vandenbergh K, Fryns JP, Haspeslagh M, Lauweryns JM. A new lethal chondrodysplasia with spondylocostal dysostosis, multiple internal anomalies and Dandy-Walker cyst. *Clin Genet* 1985;27:160-4.
50. Mortier GR, Messiaen L, Espeel M, Smets KJ, Vanzieleghe BD, Roels F, et al. Chondrodysplasia punctata with multiple congenital anomalies: A new syndrome? *Pediatr Radiol* 1998;28:790-3.
51. Namavar Y, Barth PG, Kasher PR, van Ruisven F, Brockmann K, Bernert G, et al. Clinical, neuroradiological and genetic findings in pontocerebellar hypoplasia. *Brain* 2011;134:143-56.
52. Nelson M, Maher K, Gilles FA. A different approach to cysts of the posterior fossa. *Pediatr Radiol* 2004;34:720-32.

53. Notaridis G, Ebbing K, Giannakopoulos P, Bouras C, Kovari E. Neuropathological analysis of an asymptomatic adult case with Dandy-Walker variant. *Neuropathol Appl Neurobiol* 2006;32:344-50.
54. Online Mendelian Inheritance in Man (OMIM®) [database online]. Bethesda: National Center for Biotechnology Information, U.S. National Library of Medicine. Available from: <http://omim.org/entry/253300>. [Last accessed on 2013 Nov 08].
55. Osenbach RK, Menezes AH. Diagnosis and management of the Dandy-Walker malformation: 30 years of experience. *Pediatr Neurosurg* 1992;18:179-89.
56. Ozdemir O, Polat A, Cinbis M, Kurt F, Kucuktasci K, Kiroglu Y. Dandy-Walker's variant and tetralogy of Fallot with atrial septal defect and patent ductus arteriosus and primary hypothyroidism—a new association. *Indian J Pediatr* 2009;76:433-5.
57. Panas M, Spengos K, Tsigoulis G, Kalfakis N, Sfagos C, Vassilopoulos D, et al. Spinal muscular atrophy, Dandy-Walker complex, and cataracts in two siblings: A new entity? *J Neurol Neurosurg Psychiatry* 2005;76:1183-4.
58. Raybaud C. Cystic malformations of the posterior fossa abnormalities associated with development of the roof of the fourth ventricle and adjacent meningeal structures. *J Neuroradiol* 1982;9:103-33.
59. Renbaum P, Kellerman E, Jaron R, Geiger D, Segel R, Lee M, et al. Spinal muscular atrophy with pontocerebellar hypoplasia is caused by a mutation in the *VRK1* gene. *Am J Hum Genet* 2009;85:281-9.
60. Robinson AJ, Goldstein R. The cisterna magna septa: Vestigial remnants of Blake's pouch and a potential new marker for normal development of the rhombencephalon. *J Ultrasound Med* 2007;26:83-95.
61. Rudnik-Schoneborn S, Sztrihai L, Aithala GR, Houge G, Laegreid LM, Seeger J, et al. Extended phenotype of pontocerebellar hypoplasia with infantile spinal muscular atrophy. *Am J Med Genet A* 2003;117A: 10-7.
62. Sasaki-Adams D, Elbabaa SK, Jewells V, Carter L, Campbell JW, Ritter AM. The Dandy-Walker variant: A case series of 24 pediatric patients and evaluation of associated anomalies, incidence of hydrocephalus, and developmental outcomes. *J Neurosurg Pediatr* 2008;2:194-9.
63. Seidahmed MZ, Alkuraya FS, Shaheed M, Al Zahrani M, Al Manea W, Mansour F, et al. Ritscher-Schinzel (cranio-cerebello-cardiac, 3C) syndrome report of four new cases with renal involvement. *Am J Med Genet A* 2011;155A: 1393-7.
64. Sener RN. Rhombencephalosynapsis associated with Dandy-Walker malformation. *J Neuroimaging* 2007;17:355-7.
65. Shenoy RD, Kamath N. Dandy-Walker malformation, occipital meningoencephalocele, meso-axial polydactyly and bifid hallux. *Clin Dysmorphol* 2010;19:166-8.
66. Silengo M, Gianino P, Longo P, Battistoni G, Defilippi C. Dandy-Walker complex in a child with Jeune's asphyxiating thoracic dystrophy. *Pediatr Radiol* 2000;30:430.
67. Stevens CA, Lachman RS. New lethal skeletal dysplasia with Dandy-Walker malformation, congenital heart defects, abnormal thumbs, hypoplastic genitalia, and distinctive facies. *Am J Med Genet A* 2010;152A: 1915-8.
68. Stoll C, Huber C, Alembik Y, Terrade E, Maitrot D. Dandy-Walker variant malformation, spastic paraplegia, and mental retardation in two sibs. *Am J Med Genet* 1990;37:124-7.
69. Sudha T, Dawson AJ, Prasad AN, Konkin D, de Groot GW, Prasad C. De novo interstitial long arm deletion of chromosome 3 with facial dysmorphism, Dandy-Walker variant malformation and hydrocephalus. *Clin Dysmorphol* 2001;10:193-6.
70. Taggart TK, Walker AE. Congenital atresia of the foramina of Luschka and Magendie. *Arch Neurol Psychiatry* 1942;48:583-612.
71. Talamonti G, Picano M, Debernardi A, Bolzon M, Teruzzi M, D'Aliberti G. Giant occipital meningocele in an 8-year-old child with Dandy-Walker malformation. *Childs Nerv Syst* 2011;27:167-74.
72. Todt I, Mazereeuw-Hautier J, Binder B, Willems PJ. Dandy-Walker malformation in patients with KID syndrome associated with a heterozygote mutation (p.Asp50Asn) in the *GJB2* gene encoding connexin 26. *Clin Genet* 2009;76:404-8.
73. Tohyama J, Kato M, Kawasaki S, Harada N, Kawara H, Matsui T, et al. Dandy-Walker malformation associated with heterozygous *ZIC1* and *ZIC4* deletion: Report of a new patient. *Am J Med Genet A* 2011;155A: 130-3.
74. Tonni G, Azzoni D, Ambrosetti F, de Felice C, Ventura A. Cerebro-fronto-facial syndrome (Dandy-Walker Variant and frontofacial dysmorphism): Report of the first case identified by increased nuchal translucency beyond 13(+6) weeks. *Congenit Anom (Kyoto)* 2007;47:68-71.
75. Tortori-Donati P, Fondelli MP, Rossi A, Carini S. Cystic malformations of the posterior cranial fossa originating from a defect of the posterior membranous area. Mega cisterna magna and persisting Blake's pouch: Two separate entities. *Childs Nerv Syst* 1996;12:303-8.
76. Tsai MS, Chiu YT, Wang SH, Hsieh-Li HM, Li H. Abolishing Trp53-dependent apoptosis does not benefit spinal muscular atrophy model mice. *Eur J Hum Genet* 2006;14:372-5.
77. Walbert T, Sloan AE, Cohen ML, Koubeissi MZ. Symptomatic neurocutaneous melanosis and Dandy-Walker malformation in an adult. *J Clin Oncol* 2009;27:2886-7.
78. Warf BC, Dewan M, Mugamba J. Management of Dandy-Walker complex-associated infant hydrocephalus by combined endoscopic third ventriculostomy and choroid plexus cauterization. *J Neurosurg Pediatr* 2011;8:377-83.
79. Weimer J, Cohen M, Wiedemann U, Heinrich U, Jonat W, Arnold N. Proof of partial imbalances 6q and 11q due to maternal complex balanced translocation analyzed by microdissection of multicolor labeled chromosomes (FISH-MD) in a patient with Dandy-Walker variant. *Cytogenet Genome Res* 2006;114:235-9.
80. Wilson ME, Lindsay DJ, Levi CS, Ackerman TE, Gordon WL. US case of the day. Dandy-Walker variant with agenesis of the corpus callosum. *Radiographics* 1994;14:678-81.
81. Young PJ, Day PM, Zhou J, Androphy EJ, Morris GE, Lorson CL. A direct interaction between the survival motor neuron protein and p53 and its relationship to spinal muscular atrophy. *J Biol Chem* 2002;277:2852-9.
82. Zangwill KM, Boal DK, Ladda RL. Dandy-Walker malformation in Ellis-van Creveld syndrome. *Am J Med Genet* 1988;31:123-9.
83. Zhang XB, Li CX. A case of keratitis ichthyosis deafness (KID) syndrome associated with Dandy-Walker. *J Eur Acad Dermatol Venereol* 2007;21:706-7.
84. Zerrres K, Rudnik-Schöneborn S. Spinal muscular atrophies. In: Rimoin DL, Connor JM, Pyeritz RE, Korf BR, editors. *Principles and Practice of Medical Genetics*. Vol. 3, 5th ed. New York: Churchill Livingstone; 2006. p. 3001-23.