

Rare EGFR Exon 20 S768I Mutation Predicts Resistance to Targeted Therapy: A Report of Two Cases

To the Editor:

The importance of submitting data of clinical response to *epidermal growth factor receptor*-tyrosine kinase inhibitors (EGFR-TKIs) in patients with uncommon EGFR mutations has been encouraged.¹ In view of this, we present two cases of a rare EGFR mutation that appears to confer resistance to TKIs.

Case 1, a 56-year-old Afro-Caribbean male presenting with hemoptysis, breathlessness, and weight loss. Performance status was 1, with no significant past medical history and 1 pack year smoking history. Imaging showed a right middle lobe mass, mediastinal lymphadenopathy, and liver metastases. Mediastinal biopsy confirmed poorly differentiated adenocarcinoma (TTF+, CK7+, and CK20-). EGFR mutation analysis of selected regions of exons 18 to 21, using real-time polymerase chain reaction, revealed missense mutation in exon 20 at nucleotide 2303 resulting in serine to isoleucine substitution at codon 768. After commencing gefitinib 250 mg daily, computed tomography scan after 6 weeks showed disease progression with new liver and bony metastases. Within 2 weeks of switching to 3-weekly pemetrexed (500 mg/m²) and cisplatin (70 mg/m²), his exercise tolerance improved and imaging after 4 cycles demonstrated a partial response. Unfortunately, he was admitted to hospital with pneumonia after his third cycle of maintenance pemetrexed (500 mg/m²) and died 4 days later.

Case 2, a 65-year-old Caucasian female presenting with acute onset

shortness of breath. Performance status was 0, with no significant past medical history and 20 pack year smoking history. Imaging showed a right lower lobe pulmonary embolism with incidental right upper lobe mass, right lung metastases, and extensive subcarinal, mediastinal, and retroperitoneal lymphadenopathy. Mediastinal biopsy confirmed poorly differentiated adenocarcinoma (TTF+, CK7+, and CK20-). EGFR mutation analysis reported the same exon 20 missense mutation described in case 1.

She had six cycles of pemetrexed (500 mg/m²) and cisplatin (70 mg/m²) chemotherapy with a good partial response. Within 2 months of commencing treatment with maintenance erlotinib (150 mg daily), imaging showed progression of all lesions. Despite early disease stabilization on switching to oral vinorelbine (60 mg/m²), computed tomography scan after 4 months revealed further progression. She was unfit for further treatment and died 2 months later.

A number of rare EGFR mutations exist to which response to targeted therapy is unclear. The exon 20 missense mutation S768I is one of these. In Asian populations, prevalence of this mutation is less than 5% although it is more commonly seen in combination with other mutations.² In our region, prevalence of this single mutation is 1.5% (unpublished data).

In vitro, cells expressing S768I mutation are less sensitive to EGFR-targeted treatment than wild-type cells.³ However, reports of clinical outcome in these patients are conflicting.^{4,5}

Our two cases add to the evidence that the S768I mutation causes insensitivity to TKI therapy. However, both cases did show response to platinum-based chemotherapy. Furthermore, these cases continue to highlight the importance of publishing treatment response data for cases of rare EGFR mutant lung cancers to guide clinical decision making.

Lalit Pallan

Department of Oncology
New Cross Hospital
Wolverhampton, United Kingdom

Phillip Tanriere

Department of Cellular Pathology

Queen Elizabeth Hospital Birmingham
Birmingham, United Kingdom

Pek Koh

Department of Oncology
New Cross Hospital
Wolverhampton, United Kingdom

REFERENCES

1. Yatabe Y, Pao W, Jett JR. Encouragement to submit data of clinical response to EGFR-TKIs in patients with uncommon EGFR mutations. *J Thorac Oncol* 2012;7:775–776.
2. Huang SF, Liu HP, Li LH, et al. High frequency of epidermal growth factor receptor mutations with complex patterns in non-small cell lung cancers related to gefitinib responsiveness in Taiwan. *Clin Cancer Res* 2004;10:8195–8203.
3. Chen YR, Fu YN, Lin CH, et al. Distinctive activation patterns in constitutively active and gefitinib-sensitive EGFR mutants. *Oncogene* 2006;25:1205–1215.
4. Masago K, Fujita S, Irisa K, et al. Good clinical response to gefitinib in a non-small cell lung cancer patient harboring a rare somatic epidermal growth factor gene point mutation; codon 768 AGC > ATC in exon 20 (S768I). *Jpn J Clin Oncol* 2010;40:1105–1109.
5. Weber B, Hager H, Sorensen BS, et al. EGFR mutation frequency and effectiveness of erlotinib: a prospective observational study in Danish patients with non-small cell lung cancer. *Lung Cancer* 2014;83:224–230.

OPEN

Elderly Former Smoker with HRAS Mutant Non-Small-Cell Lung Cancer

To the Editor:

While HRAS mutations have been identified in a few cases of non-small-cell

Address for correspondence: Ariel Lopez-Chavez, MD, MS, Oregon Health and Science University, Portland, OR 97239. E-mail: lopezcha@ohsu.edu

Copyright © 2014 by the International Association for the Study of Lung Cancer. This is an open-access article distributed under the terms of the Creative Commons Attribution-Non Commercial-No Derivatives 3.0 License, where it is permissible to download and share the work provided it is properly cited. The work cannot be changed in any way or used commercially.

ISSN: 1556-0864/14/0910-0e75

Address for correspondence: Lalit Pallan, School of Cancer Sciences, University of Birmingham, Edgbaston, Birmingham B15 2TT, United Kingdom. E-mail: lxp164@bham.ac.uk/lalitpallan@nhs.net

Copyright © 2014 by the International Association for the Study of Lung Cancer

ISSN: 1556-0864/14/0910-0e75

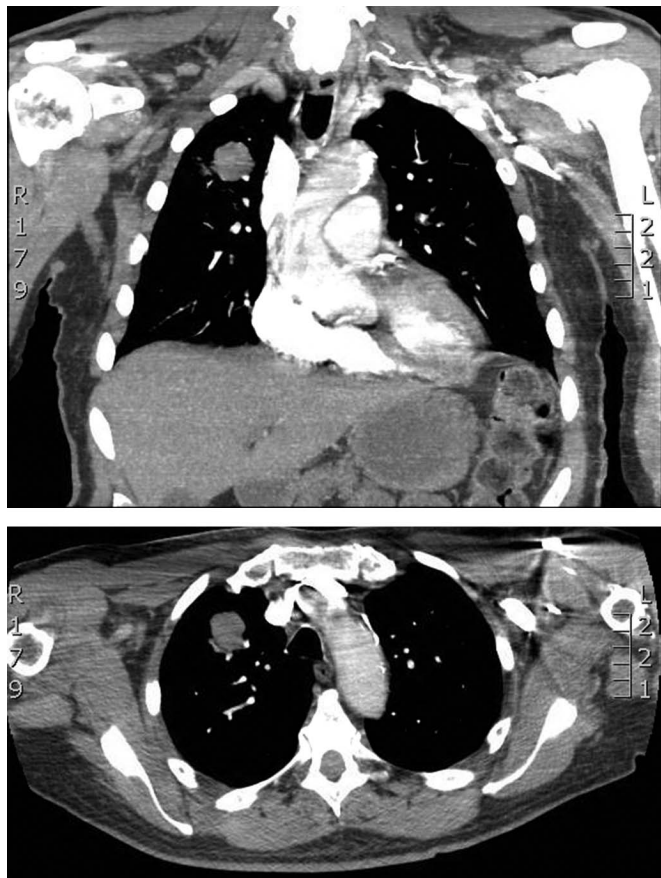


FIGURE 1. Computed tomography chest with 3-cm soft-tissue density in the anterior segment of the right upper lobe.

lung cancer (NSCLC), the clinical course of patients with NSCLC with HRAS mutations has not been described. The following case discusses a patient with an HRAS-positive adenocarcinoma of the lung who experienced rapid clinical decline.

CASE PRESENTATION

A 79-year-old male former smoker with a history of resected World Health Organisation (WHO) Grade I sphenoid meningioma presented to the emergency room, whereupon a computed tomography chest showed a 3-cm soft-tissue density in the anterior segment of the right upper lobes (Figs. 1 and 2). Moderately differentiated adenocarcinoma was confirmed by computed tomography-guided biopsy of the mass.

In September 2010, the patient underwent mediastinoscopy followed by right upper lobectomy. Final pathologic staging was T2aN0M0 (stage Ib) adenocarcinoma, large-cell subtype.

The patient was treated with four cycles of pemetrexed and carboplatin.

In July 2011, 10 months after completing the right upper lobectomy, the disease had metastasized to his brain. He underwent craniotomy for the left temporal lobe mass, followed by stereotactic radiosurgery of additional CNS lesions. Pathology of the temporal lobe lesion revealed poorly differentiated adenocarcinoma consistent with metastasis from a lung primary (Fig. 3). Multiplex polymerase chain reaction/mass spectroscopy (MassARRAY system) was performed, testing for 647 known gene mutations in solid tumors (among 53 genes), and revealed one mutation, HRAS Q61L (Table 1). The patient's previously resected meningioma was also tested for mutations using the same multiplex polymerase chain reaction/mass spectroscopy platform previously described, and no mutations were found in the meningioma, including no HRAS mutations.

Additional imaging revealed metastatic multiple bony lesions and innumerable liver lesions and bilateral adrenal lesions. The patient had an Eastern Cooperative Oncology Group performance status of three and was not a candidate for systemic palliative chemotherapy. The patient died in January 2012.

DISCUSSION

The case demonstrates a patient diagnosed with adenocarcinoma with HRAS mutation. The patient had a rapid progression from stage Ib disease to metastatic adenocarcinoma and death.

Ras mutations are detectable in approximately 20% of lung cancers, with KRAS mutations representing 90% of those mutations. KRAS mutations are associated with a poor overall prognosis¹ in NSCLC.

HRAS mutations have been documented in various cancer types (including cervical, salivary gland carcinoma, head and neck squamous cell carcinoma, melanoma, transitional cell carcinoma of the bladder, prostate adenocarcinoma, breast, and both soft-tissue and osteosarcomas).^{2,3} HRAS mutations have also been described in Costello syndrome, also known as faciocutaneouskeletal syndrome, a rare genetic disorder characterized by mental retardation, cardiac abnormalities, and distinct facial features.⁴

HRAS mutations represent 1% of all mutations in NSCLC.⁵ Although infrequent, the role of HRAS in the pathogenesis of NSCLC is uncertain. Our patient with HRAS mutation had rapid progression from early stage NSCLC and died from metastatic disease less than 18 months after diagnosis. Additional cases with HRAS mutation are needed to evaluate the clinical behavior and prognostic features of HRAS mutant NSCLC. For this patient, the possibility of HRAS mutant NSCLC causing rapid disease progression and death from metastatic NSCLC raises the likelihood that HRAS mutations in NSCLC tumors are aggressive and associated with poor overall prognosis, similar to KRAS mutant NSCLC. Further research and description of clinical cases are needed for improved understanding of this genetic mutation in NSCLC.

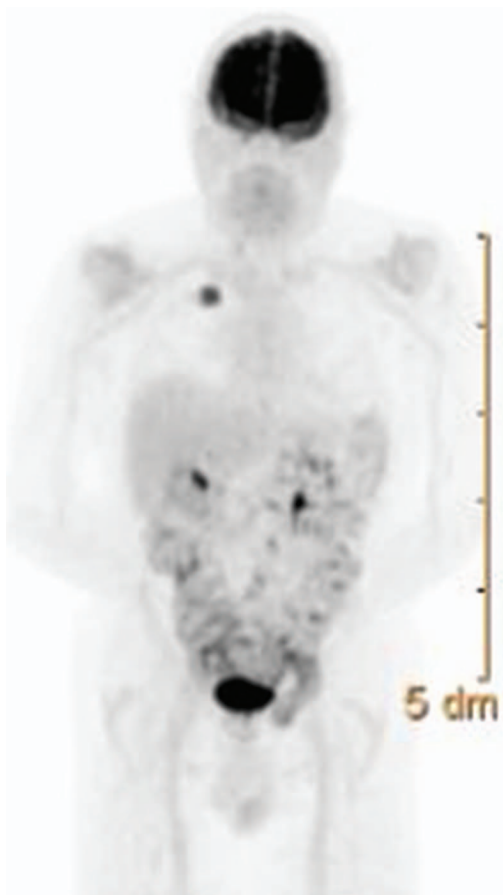


FIGURE 2. Positron emission tomography scan, notable for increased uptake (SUV 8) in the right upper lobe lesion only.

TABLE 1. Mutation Analysis Performed, Only Positive for HRAS Q61L Mutation

Mutation Analyzed	Result
HRAS, Q61L	POS
AKT1	Neg
CTNNB1	Neg
FGFR1	Neg
GNAS	Neg
KRAS	Neg
NRAS	Neg
PIK3R4	Neg
SOS1	Neg
AKT2	Neg
EGFR	Neg
FGFR2	Neg
MAP2K1	Neg
NTRK1	Neg
PIK3R5	Neg
STAT1	Neg
AKT3	Neg
ERBB2	Neg
FGFR3	Neg
IDH1	Neg
MAP2K2	Neg
NTRK2	Neg
PKHD1	Neg
TEC	Neg
ALK	Neg
ERCC6	Neg
FGFR4	Neg
IDH2	Neg
MAP2K7	Neg
NTRK3	Neg
PRKCB1	Neg
TP53	Neg
BRAF	Neg
FBX4	Neg
FOXL2	Neg
IGF1R	Neg
MET	Neg
PDGFRA	Neg
RAF1	Neg
CDK4	Neg
FBXW7	Neg
GNA11	Neg
KDR	Neg
MYC	Neg
PIK3CA	Neg
RET	Neg
CSF1R	Neg
FES	Neg
GNAQ	Neg
KIT	Neg
NEK9	Neg
PIK3R1	Neg
SMO	Neg

Elizabeth Cathcart-Rake, MD
Christopher Corless, MD, PhD
David Sauer, MD
Ariel Lopez-Chavez, MD, MS
 Oregon Health and Science University
 Portland, Oregon

REFERENCES

1. Huncharek M, Muscat J, Geschwind JF. K-ras oncogene mutation as a prognostic marker in non-small cell lung cancer: a combined analysis of 881 cases. *Carcinogenesis* 1999;20:1507-1510.
2. Da Silva L, Simpson PT, Smart CE, et al. HER3 and downstream pathways are

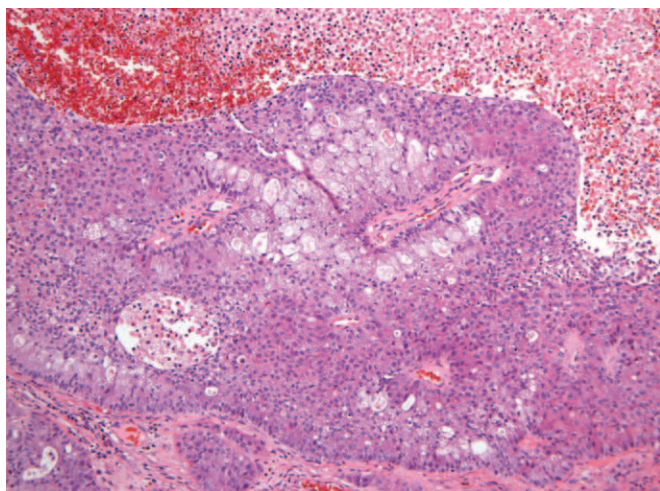


FIGURE 3. Histology of CNS metastases, adenocarcinoma of lung origin.

involved in colonization of brain metastases from breast cancer. *Breast Cancer Res* 2010;12:R46.

- Bamford S, Dawson E, Forbes S, et al. The COSMIC (Catalogue of Somatic Mutations in Cancer) database and website. *Br J Cancer* 2004;91:355–358.
- Aoki Y, Niihori T, Kawame H, et al. Germline mutations in HRAS proto-oncogene cause Costello syndrome. *Nat Genet* 2005;37:1038–1040.
- Lea IA, Jackson MA, Li X, et al. Genetic pathways and mutation profiles of human cancers: site- and exposure-specific patterns. *Carcinogenesis* 2007;28:1851–1858.

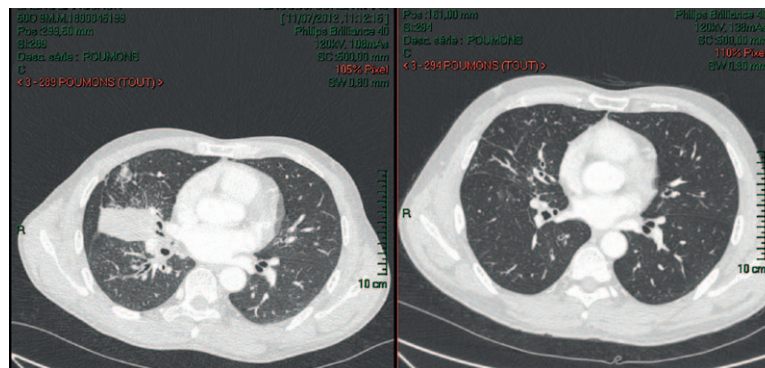


FIGURE 1. Computed tomography scan of chest of patient 1 (left) before treatment and (right) after 3 months of gefitinib treatment.

Two Cases of Non-Small-Cell Lung Cancer with Rare Complex Mutation of EGFR Exon 18 But Different Response to Targeted Therapy

To the Editor:

In non-small-cell lung cancer (NSCLC) besides the common exons 19 and 21 EGFR-activating mutations (>90%), exon 18-point mutations (mainly p.G719X) are rare (4%).¹ They are associated with a favorable response rate to EGFR tyrosine kinase inhibitors (EGFR-TKI),^{2,3} but are lower than common mutations.⁴ More than one mutation per sample represents complex mutations. Their clinical significance is uncertain, because they are rare (3.4–6.9%).^{2,3} Here, we present two cases of NSCLC with rare complex mutation that respond differently to EGFR-TKI.

Address for correspondence: Patricia de Cremoux, MD, PhD, Department of Biochemistry, Molecular Oncology Unit, Hôpital Saint Louis, 1, Avenue Claude Vellefaux, 75010 Paris, France. E-mail: patricia.de-cremoux@sls.aphp.fr

DOI: 10.1097/JTO.0000000000000328

Copyright © 2014 by the International Association for the Study of Lung Cancer

ISSN: 1556-0864/14/0910-0e78

CASES PRESENTATION

In July of 2012, an Asian, 52-year-old male smoker presented with a right cervical lymph node. A stage IV adenocarcinoma in the right lung; lymphangitis carcinomatosa; mediastinal, cervical, and subclavicular lymph nodes; and sacrum and hip bone osteoblastic metastases were diagnosed. Two-point mutations in exon 18 of the EGFR, p.I706T, and p.G719A were detected. Gefitinib treatment started in August of 2012. After 3 months, computed tomography scan showed a partial response (Fig. 1). The clinical response was maintained under gefitinib treatment with 22 months of follow up.

The second patient was a Caucasian, 58-year-old female smoker, referred in February of 2013. A stage IV lung adenocarcinoma, in the lower right lobe, with mediastinal lymph nodes as well as cerebral and right adrenal gland metastases was diagnosed. Two-point mutations in exon 18, p.E709K and p.G719A, were detected. Erlotinib treatment and whole brain radiotherapy began. After 2 months, the patient's performance status improved and computed tomography scan demonstrated a partial response on brain metastases and primary tumor. Then she presented with a progression of extracerebral metastases. Erlotinib was stopped. A chemotherapy combining cisplatin and pemetrexed was administered. In September of 2013, due to disease progression, carboplatin and paclitaxel were proposed. The patient presented a stable disease for 4 months and then

progressed. She died 11 months after diagnosis of metastatic disease.

DISCUSSION

The clinical significance of EGFR complex mutations differs whether complex mutations include the most frequent mutations or not. Hata et al⁵ showed that tumours with complex mutations, including deletion of exon 19 or L858R point mutation, had the same response rate to EGFR-TKI than those with the same mutations alone. Wu et al² showed that patients with rare and complex mutations, compared with patients with classic or rare mutation alone or classic mutation with rare mutations, had a worse response rate to EGFR-TKI (25% versus 74.8, 68.8, and 80%, respectively) and a poorer progression-free survival (1.4 versus 11.9, 8.1, and 8.0 months). Beau-Faller et al⁶ showed that EGFR-TKI efficacy was similar or slightly poorer in patients with complex mutations including p.G719X. Keam et al³ reported only two double mutations in exon 18, including the G719A + I706T, in a series of 306 patients. The overall survival of this patient, treated with erlotinib, was 53 months.³ This is the first description of the p.E709K + p.G719A mutation.

To date, the behavior of these NSCLCs with complex mutations are not completely understood. The report of these rare and complex mutations and their response to EGFR-TKI should be very useful for the constitution of well-annotated databases and to improve the knowledge of their specific response to EGFR-TKI.