

# The length of anterior vaginal wall exposed to external pressure on maximal straining MRI: relationship to urogenital hiatus diameter, and apical and bladder location

Aisha Yousuf · Luyun Chen · Kindra Larson ·  
James A. Ashton-Miller · John O. L. DeLancey

Received: 26 November 2013 / Accepted: 7 March 2014  
© The International Urogynecological Association 2014

## Abstract

**Introduction and hypothesis** In cystoceles, the distal anterior vaginal wall (AVW) bulges out through the introitus and is no longer in contact with the posterior vaginal wall or perineal body, exposing the pressure differential between intra-abdominal pressure and atmospheric pressure. The goal of this study is to quantify the length of the exposed vaginal wall length and to investigate its relationship with other factors associated with the AVW support, such as most dependent bladder location, apical location, and hiatus diameter, demonstrating its key role in cystocele formation.

**Methods** Fifty women were selected to represent a full spectrum of AVW support. Each underwent supine, dynamic MR imaging. Most dependent bladder location and apical location were measured relative to the average normal position on the mid-sagittal plane using the Pelvic Inclination Correction System. The length of the exposed AVW and the hiatus diameter were measured as well. The relationship between exposed AVW and most dependent bladder location, apical location, and hiatus diameter were examined.

**Results** A bilinear relationship has been observed between exposed vaginal wall length and most dependent bladder location ( $R^2=0.91$ ,  $P<0.001$ ). When the bladder descends up to the inflection point (about 4.4 cm away from its normal position), there is little change in the exposed AVW length. With further descent, the exposed vaginal wall length increases significantly, with a 2 cm increase in exposed AVW length for every additional 1 cm of drop bladder location. A similar but weaker bilinear relationship exists between exposed AVW and apical location. Exposed vaginal wall length is also highly correlated with hiatus diameter ( $R^2=0.85$ ,  $P<0.001$ ).

**Conclusion** A bilinear relationship exists between exposed vaginal wall length and most dependent bladder location and apical location. It is when the bladder descent is beyond the inflection point that exposed vaginal wall length increases significantly.

**Keywords** Anterior vaginal wall prolapse · Exposed vaginal wall · Most dependent bladder location · Apical location · Maximum Valsalva · Intra-abdominal pressure

The abstract received the Best Basic Science Poster award at the American Urogynecology Society 30th Annual Scientific Meeting in Hollywood, Florida (24–26 September 2009)

A. Yousuf · K. Larson · J. O. L. DeLancey  
Department of Obstetrics and Gynecology (Pelvic Floor Research Group), University of Michigan Hospital, Ann Arbor, MI 48109, USA

L. Chen · J. A. Ashton-Miller  
Department of Biomedical Engineering, University of Michigan, Ann Arbor, MI 48109, USA

L. Chen (✉)  
Biomechanics Research Lab, 3216 GG Brown Building, 2350  
Hayward Street, Ann Arbor, MI 48109, USA  
e-mail: luyunc@umich.edu

## Introduction

Pelvic organ prolapse is a common disease leading to over 200,000 operations annually [1]. Anterior vaginal wall (AVW) prolapse, or cystocele, is the most common form of prolapse [2]. Unfortunately, it is also the most frequent site of postoperative recurrence [3–9]. A better biomechanical understanding of anterior wall support mechanism is needed to improve our understanding of the operative success and failure.

Three factors are known to be associated with anterior vaginal wall prolapse: Apical descent [10, 11], levator ani muscle damage [12–15] and an enlarged levator hiatus [16] that is related to levator damage. What has been lacking is a

biomechanically plausible conceptual model of how these factors interact to cause prolapse. Based on experimental and clinical evidence, we have developed a biomechanical conceptual disease model that integrates these factors and is explained in Fig. 1 [17]. A key feature of this model concerns how pressure differential acting on exposed vaginal wall creates forces that drive the anterior vaginal wall downward.

Clinically, with cystocele, the anterior vaginal wall becomes visible through the enlarging levator hiatus. The externally visible portion of the anterior vaginal wall has lost contact with the posterior vaginal wall. This portion of the anterior wall becomes exposed to the pressure differential between abdominal pressure and atmosphere pressure. Biomechanically, the action of a pressure differential on a membrane structure (such as the anterior vaginal wall) generates a tension force in the membrane and its supporting attachments to counterbalance the pressure-generated force. The greater the area exposed to a specific pressure differential, the greater the force that is generated. The tension force in the vaginal wall due to AVW exposure to a pressure differential would be resisted by the ligaments and connective tissues that attach the vagina to the pelvic walls. Therefore, beginning to understand factors related to the amount of vaginal wall that is exposed to this pressure differential can help in advancing our understanding of the relationships among apical descent, levator ani muscle damage, and anterior vaginal wall prolapse and how eliminating the exposed vaginal wall surgically would improve the overall vaginal support.

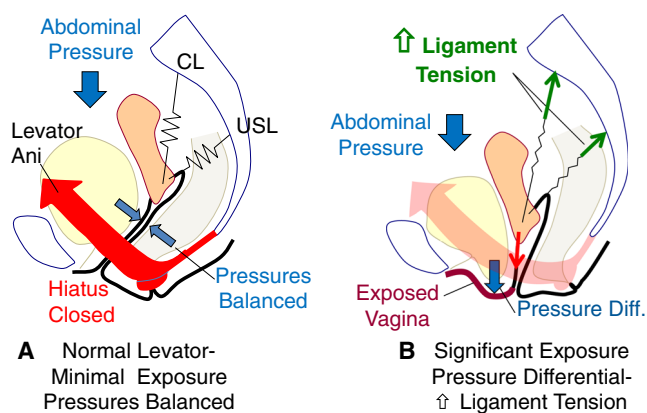
This study seeks to quantify the length of exposed anterior vaginal wall and explore its relationship with other factors such as cystocele size, apical descent, and hiatus diameter using dynamic MRIs of women with a spectrum of normal and abnormal anterior vaginal wall support. It is our

hypothesis that the exposed vaginal wall length is significantly associated with cystocele size, apical descent, and hiatus diameter.

## Materials and methods

This study is a secondary analysis of MR images from an ongoing University of Michigan, IRB-approved case-control study that focused on anterior vaginal wall prolapse (IRB # 1999-0395). To assemble a study set representing the full spectrum of normal and abnormal anterior vaginal wall support we used a stratified sampling strategy to select roughly equal numbers of women with normal support (anterior support points Aa, Ba and C above the hymenal ring) and prolapse (all support points below the hymenal ring). No women were included in whom a posterior vaginal prolapse was larger than the anterior vaginal prolapse. Study subjects were chosen sequentially starting from the most recent scans, moving backward until 25 subjects had been collected in each group. Since data do not exist on the amount of vaginal wall that is exposed in a cystocele, a formal sample size could not be estimated. We therefore planned a preliminary analysis at a sample size of approximately 50, and if important trends were not statistically significant, we would use these data for a formal power calculation and conduct a larger study. Women were excluded if they had undergone prior prolapse surgery, had neurological disease affecting the pelvic floor, or factors that would preclude MRI interpretation (e.g., a prosthetic hip). For this study, only subjects with a uterus in situ were included so that the location of the cervix could be marked. As part of the research protocol, all women underwent POP-Q examinations performed by an experienced urogynecologist (Dr DeLancey or Dr Larson) and the modified Duke Pelvic Floor Dysfunction Distress Inventory was used to access the symptoms. Before starting the examination, the patient was instructed how to properly perform straining maneuvers by relaxing their pelvic floor muscles and allowing maximal prolapse development starting from minimal to maximal straining.

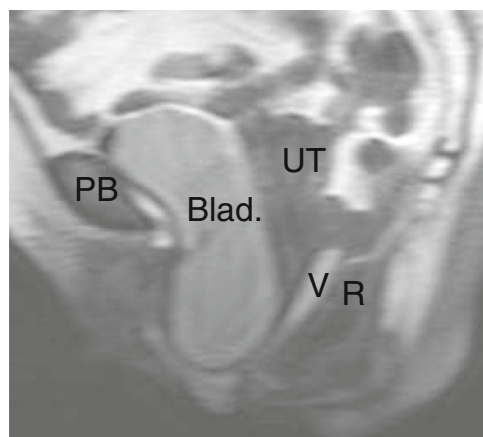
As described in our previous studies [18], MR imaging was performed on a 3-T system (Philips Medical Systems, Best, The Netherlands) using a six-channel torso phased array coil with the subject in the supine position. Ultrasound gel was placed in the vagina to outline its contour. For dynamic imaging, a multiphase, single-level image of the pelvis in the mid-sagittal plane was obtained approximately every 1.4 s over 30 s using a single-shot, turbo spin-echo sequence (TR, approximately 1,300 ms; TE, 105 ms; slice thickness, 6 mm; field of view 34 cm; matrix 256 × 90; and 1 number of signal average [NSA]). A set of 20 successive images were acquired during rest and graded straining effort as follows: after imaging during rest, the operator instructed the patient to strain



**Fig. 1** Schematic representation of pelvic organ prolapse theoretical disease model based on Chen et al. (2009). **a** With normal levator function, the hiatus is closed and anterior and posterior pressures are balanced. Levator damage results in a hiatal opening and **b** the vagina becomes exposed to a pressure differential that creates a tension force (red arrow) on the cardinal (CL) and uterosacral (USL) ligaments. (Modified from DeLancey© [26])

minimally, moderately, and maximally, then to breathe normally and relax before ending the acquisition. Women were instructed to relax their pelvic floor muscles to allow maximal prolapse development as during pelvic examination for prolapse. A research associate with the POP-Q data from each subject's clinical examination was present during MRI and visually evaluated the location of the anterior vaginal wall at maximal strain using the mid-pubic line as an estimate of the hymenal ring on MRI to ensure that the extent of the anterior vaginal wall prolapse was similar to what was seen on clinical examination.

The measurement strategy based on mid-sagittal MRI is presented in Fig. 2 using the Pelvic Inclination Correction System (PICS) based on the technique described by Summers et al. [11], Hsu et al. [18, 19], and Betschart et al. [20]. In brief, on each MR image, a local pelvic coordinate system was established with its origin in the mid-sagittal plane on the arcuate pubic ligament. The x-axis (PICS line) points posteriorly along the sacrococcygeal inferior pubic point (SCIPP) line, but is rotated 34° clockwise to compensate for the pelvic floor inclination, which is, on average, perpendicular to the body axis. The y-axis points cranially [20]. Overall, vaginal length and the portion below contact with the perineal body and posterior vaginal wall were assessed by tracing the contour of the vaginal wall from the external urethral meatus to the cervicovaginal junction. The point at which the anterior vaginal wall loses contact with the posterior wall in the region of the perineal body was marked as the transition point (black triangle in Fig. 2) to delimit the exposed vagina from the vagina in contact with other pelvic floor structures. The sagittal hiatus diameter was measured as the straight-line distance between pubic symphysis point and the transition point (Fig. 2). Sagittal diameters were measured as a proxy for area measurements that are not seen on these midline images based on the observation that 90 % of the variation in hiatal area is



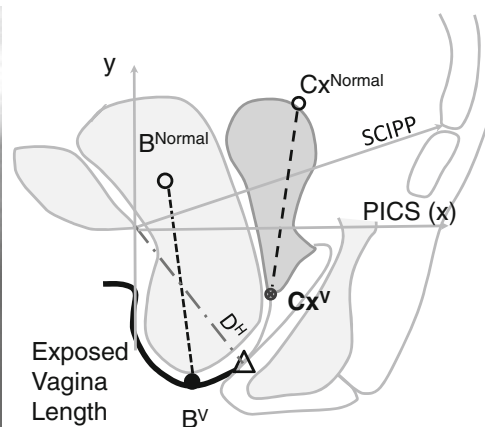
**Fig. 2** Mid-sagittal MRI at maximal straining and measurement scheme based with sacrococcygeal inferior pubic point (SCIPP) line-oriented axes; cervix location at maximal straining ( $Cx^V$ ); most independent bladder point at maximal straining ( $B^V$ ); normal cervix location ( $Cx^{Normal}$ )

attributable to the sagittal diameter [21]. Point placement was confirmed by two examiners (Dr Yousuf and Dr DeLancey) before measurements were completed.

As an assessment of cystocele size we identified the location of the most dependent point in the bladder (B) and assessed apical support by cervix location (Cx) 11. When there was no anterior compartment prolapse, the B was placed at the urethral-vesicle junction and in the case of prolapse it is placed at the lowest point on the bladder. The location of the most dependent part of the anterior cervix was marked at the cervicovaginal junction. The average normal resting dependent bladder point ( $B^{Normal}$ ) and the average normal cervix location ( $Cx^{Normal}$ ) have been previously determined in 20 nulliparous women [11] (black open circle, Fig. 2). Cystocele size was estimated by calculating the distance from the most dependent bladder point at maximal straining ( $B^V$ ) to the average nulliparous resting bladder point ( $B^{Normal}$ ). Similarly, the apical displacement was calculated as the distance between the subject's cervix location at maximal straining ( $Cx^V$ ) to the average normal cervix location at rest ( $Cx^{Normal}$ ). Distance from normal was assessed rather than the distance between the resting and straining because in some women with a large prolapse, the resting bladder can be quite low. When this is true, little movement occurs during straining, underestimating the size of the prolapse. Image J 1.4 l (NIH) software was used to measure the described reference lines and lengths.

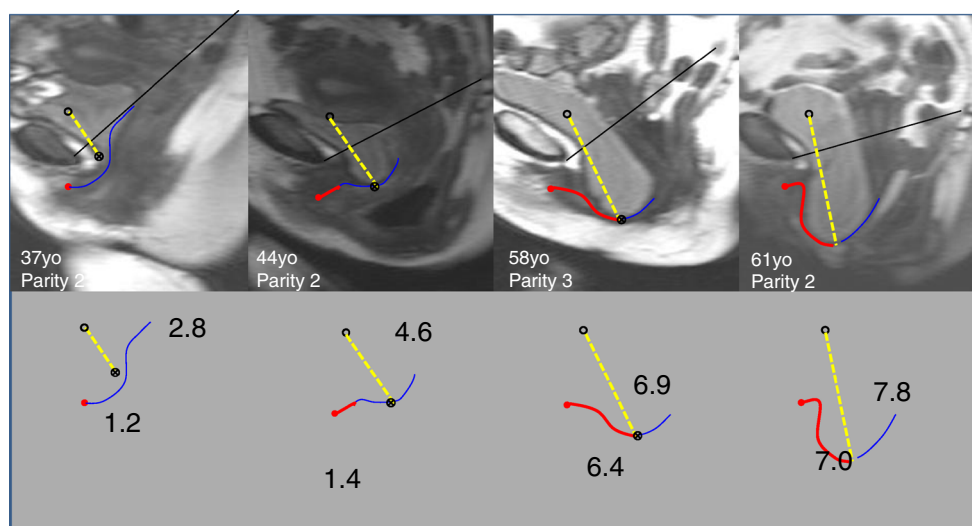
Several examples of different degrees of anterior vaginal wall support and the corresponding measurements of bladder location and exposed vaginal wall length are shown in Fig. 3.

Levator ani muscle were scored as major defect (more than 50 % muscle defect), minor defect (less than 50 % muscle defect) or normal muscle on the axial MRI images, as described in our previous studies [12].



and normal bladder rest location ( $B^{Normal}$ ) according to Summers et al. [11].  $\Delta$  transition point where the anterior vaginal wall (AVW) contacts the perineal body.  $D^H$ , R rectum, UT uterus, V vagina, PB pubic bone, PICS Pelvic Inclination Correction System

**Fig. 3** Examples of subjects' MRIs and measurements. *Open circle* normal rest bladder location, *filled circle* subject bladder location at maximal straining with *yellow dashed line* representing the distance the bladder is below its normal rest location (number shown in cm). The *red line* indicates the portion of the vagina that is exposed (length shown in cm) and the *blue line* the portion of the vagina that is in contact with the posterior vaginal wall. The *filled triangle* represents the transition point where the anterior vagina loses contact with the posterior vaginal wall



Although the original study included both cases and controls, our analysis concerned the relationship between exposed vaginal wall length and bladder location, apical location, hiatus diameter, and levator ani muscle defect, which did not depend on group status. The relationship between exposed vaginal wall length and most dependent bladder point, hiatus diameter, and apical location were examined using a scatter plot. Different curve fitting models, such as linear model, bilinear model, quadratic model, and exponential model, were used to explore the relationship among these parameters.

## Results

The subjects had a mean age of  $53.5 \pm 10.0$  years, a BMI of  $26.4 \pm 5.7$  kg/m<sup>2</sup> and  $2.4 \pm 1.3$  vaginal births. The POPQ results of the study group are shown in Table 1.

Figure 4 illustrates the relationship between exposed vaginal wall length and bladder position at maximal straining for the entire cohort. Linear, exponential, and bilinear models were evaluated for the regression analysis. A bilinear model chosen because it had the highest correlation coefficient ( $r^2 =$

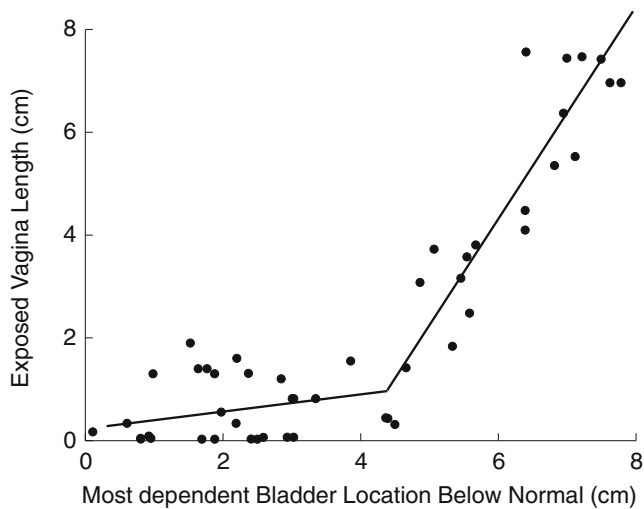
**Table 1** The Pelvic Organ Prolapsed Questionnaire (POPQ; cm) results of all subjects ( $n=50$ )

POPQ	Mean (cm)	SD (cm)	Minimum (cm)	Maximum (cm)
Aa	-0.3	1.7	-3	+3
Ba	+0.1	2.1	-3	+5
C	-4.9	1.7	-8	0
D	-7.5	1.6	-11	-4
Ap	-1	1.2	-3	+2
Bp	-1	1.2	-3	+2

0.91,  $P < 0.01$ ). The estimated bilinear curve illustrated that exposed vaginal wall length increases dramatically with bladder descent beyond 4.4 cm on the x-axis. When the bladder position is less than 4.4 cm from the normal resting position there is little change in the exposed vaginal wall length, the estimated slope is 0.12 with 95 % confidence interval (-0.17, 0.41). However, if the bladder was greater than 4.4 cm below the normal resting position, the slope increased dramatically to 2.0 with 95 % confidence interval (1.7, 2.3), which means that for every additional 1 cm drop of the most dependent bladder point, there is an average 2 cm increase in exposed vaginal wall length. In comparing women with a bladder location more than 4.4 cm below the normal resting position with those with less than 4.4 cm, 65 % vs 20.7 % ( $P=0.02$ ) of women reported experiencing pressure in the pelvic or genital area, 70 % vs 20.7 % ( $P=0.01$ ) of women reported having a sensation of a bulge, and 70 % vs 17.2 % ( $P < 0.001$ ) of women can see or feel a bulging or something falling out in the vaginal area on the modified Duke Pelvic Floor Dysfunction Distress Inventory.

Similarly, a bilinear model was used for the regression analysis to describe the relationship between the exposed vaginal wall length and apical location. The correlation of the model reveals an  $r^2$  of 0.78 ( $P < 0.01$ ; Fig. 5). The estimated transition point is at the apical descent at 5.0 cm below the normal position with a 95 % confidence interval 3.4 to 6.5 cm. When the apical descent is within 5 cm, there is little change in the length of the exposed vaginal wall, the estimated slope is 0.18 with a 95 % confidence interval -0.33 to 0.68). However, if the apical descent is greater than 5 cm, for every additional 1 cm drop of the apex, there is on average a 1.2 cm increase in the exposed vaginal wall length.

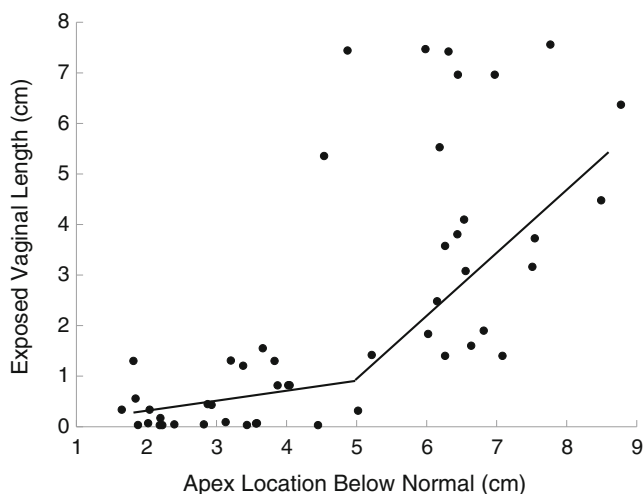
Figure 6 demonstrated the relationship between the exposed vaginal wall length and hiatus diameter. Exposed vaginal wall length is strongly associated with hiatus diameter



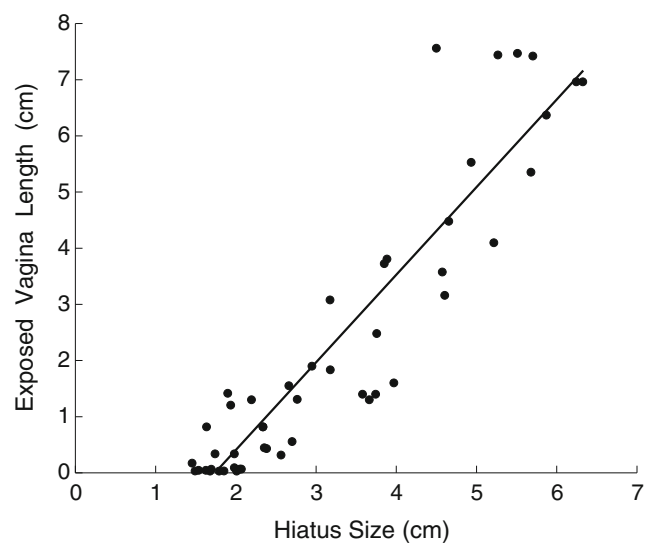
**Fig. 4** A bilinear relationship was used to describe the relationship between the position of the most dependent bladder point below normal and the length of exposed vagina. The correlation coefficient  $r^2=0.91$ . The estimated transition point is when the bladder location is 4.4 cm below the normal position with a 95 % confidence interval (3.9 cm, 4.9 cm)

( $r^2=0.73$ ). The scatter plot also shows the variation of exposed vaginal wall length, for example, with a similar hiatus diameter of 4.8 cm, the maximum exposed vaginal wall length is 7.56 cm in this sample, while the minimum exposed vaginal wall length is 3.16 cm. Increased exposed vaginal wall length was seen in women with a major defects average at 4.0 cm compared with 1.4 cm for women with a minor levator defect and 1.5 cm for women with a normal levator ani muscle ( $P<0.001$ ).

The relationships between our MRI measurements and clinical examination are as follows. The measured bladder location and apical location relative to the average normal



**Fig. 5** Bilinear relationship between exposed vaginal wall length and apex location. The correlation coefficient  $r^2=0.78$ . The estimated transition point is at the apical descent at 5.0 cm below the normal position with a 95 % confidence interval 3.4 to 6.5 cm



**Fig. 6** There is a strong linear relationship between hiatus diameter and exposed vaginal wall length with a correlation coefficient  $r^2=0.85$

locations on MRI correlate significantly with the clinical POPQ measurements. The correlation between the measured bladder location on MRI and the Ba point in a clinical examination is 0.737 ( $P<0.01$ ) and between the measured apical location on MRI and the C point is 0.535 ( $P<0.01$ ). The average exposed vaginal wall length increases in line with POPQ stages ( $P<0.001$ ). From stage 0 to stage 4 the average exposed vaginal wall lengths are 0.1 cm, 1.0 cm, 2.5 cm, 4.1 cm, and 6.2 cm respectively.

## Discussion

In this descriptive MRI study, we have examined the quantitative relationship between in vivo measurements of exposed vaginal wall length and bladder descent, apical descent and hiatal enlargement in a group of women with anterior vaginal wall support spanning the range from normal to significant prolapse at maximum straining. We discovered an interesting and novel bilinear relationship between exposed vaginal wall length and anterior compartment prolapse assessed as bladder descent. Based on our MR measurements, when bladder descent was less than 4.4 cm, very little of the vagina is exposed. In the descent that occurs up to this inflection point, the anterior vaginal wall is still in contact with the posterior vaginal wall and only a small portion is exposed to the pressure differential. With further bladder descent the exposed vaginal wall length starts to increase dramatically, as can be seen in Figs. 3 and 4. In this region of the graph, on average, there is a 2 cm increase in exposed vaginal wall length with each additional 1 cm of bladder descent. Similarly, a significant but weaker bilinear relationship was found between exposed vaginal wall length and apical location, the inflection point is at about 5 cm below the normal apex location. Both of

these observations suggest a threshold effect wherein some degree of descent is not associated with much exposure of the vaginal wall to a pressure differential, but after that threshold, progressively larger amounts of the anterior vaginal wall become exposed.

What do these findings mean to the practicing obstetrician/gynecologist? First, these findings explain why women are more likely to experience prolapse symptoms once the bladder and vaginal wall have descended a certain amount. The symptoms of bulging and pressure experienced by women with anterior vaginal wall prolapse become evident when the anterior vaginal wall descends to the level of the hymenal remnants [22]. Although the hymen is not visible on sagittal MRI, the urethra is normally 3.5 cm long [23] and so the normal BD point would be about 4 cm above the external urethral orifice that is at the level of the hymen. One can therefore estimate that descent of 4 cm would bring the bladder and adjacent vaginal wall just below the hymen. It is logical that women experience a pressure sensation when the bladder and vaginal wall have fallen to the point where they become exposed to the difference between abdominal and atmospheric pressure. Similarly, elevating the anterior vaginal wall above this point would eliminate the pressure differential, and therefore the pressure-related symptoms of prolapse. These observations provide a biomechanical explanation for why the hymen has emerged as an appropriate level both for defining symptomatic prolapse and for assessing surgical cure [24]. It is also consistent with the observation that women's dissatisfaction with surgical results increases once the vaginal wall is below the hymen, but not when it is at or above the hymen [25].

Second, these data may help to explain the somewhat paradoxical fact that three different surgical approaches to cystocele all have some success in eliminating cystocele: midline fascia plication defect repair, paravaginal repair and abdominal sacrocolpopexy [26]. In this line of reasoning an operation that eliminates the exposed vagina by repositioning the anterior vaginal wall to a location where it is in contact with the posterior vaginal wall is performed. This reduces the forces placed on the pelvic supportive tissues and can improve anterior vaginal wall support. The fact that the exposed vaginal wall is subjected to forces that in a normal position it is not exposed to may help to explain why the vaginal wall is somewhat wider and longer than normal [19, 27]. The degree to which this occurs may be related to variations that exist in the mechanical properties of the vaginal wall [28, 29]. It remains to be determined the degree to which cystocele is attributable to abnormal properties of the vaginal wall and apical ligaments, and how much these problems are due to the abnormal forces placed on them.

These findings also deepened our theoretical biomechanical understanding of the prolapse mechanism. The observations made in women with a full range of support, including a full spectrum from normal to prolapse, provide quantitative

support to help validate the conceptual disease model shown in Fig. 1. This model was based on our theoretical 2D and 3D biomechanical analysis [17, 30] that synthesizes the effects of interactions among cystocele size, apical descent, and levator ani muscle impairment. In this model, the portion of the anterior vaginal wall is exposed to the pressure differential between high intra-abdominal pressure and low atmosphere pressure. This pressure acting on the exposed vaginal wall when it falls below the levator hiatus generates tension in the vaginal wall, which acts as a downward force that drags the vaginal wall and apex downward. This, in turn, creates increased tension on the tissues that try to hold the vaginal wall in place. The longer the exposed vaginal wall length, the larger area exposed to the pressure differential, the greater the downward force drawing down the apex. On the other hand, the degree of apical descent would be also influenced by the stiffness of the apical support, which explains why there is only a weak correlation between apical descent and exposed vaginal wall length. Further study on the material property of apical support and how it interacts with downward forces should provide additional insights.

These observations also help to explain the relationship between the two different factors known to be associated with prolapse; namely, connective tissue supports (ligaments and fascia) and levator ani muscle damage. The integrity of the levator ani muscle is a contributing factor helping to determine hiatal size [31]. Therefore, levator ani muscle damage lessens the force resisting anterior vaginal wall movement and makes it easier for the anterior vaginal wall to descend enough to become exposed to the pressure differential. This thereby increases stress on the connective tissue supports and illustrates how these factors are inter-related; thus, no single factor explains all aspects of prolapse. It is easy to see that combinations of abnormalities can result in a "positive feedback" loop in engineering terms where, once the vagina descends beyond where other tissues can help with support, the stresses on the system increase and cause greater exposed vagina wall length.

There are some important considerations that need to be taken into account when interpreting our results. First, the exposed vaginal wall length was identified only on the mid-sagittal plane. Owing to the complex 3D nature of the cystocele, our measurement can underestimate the maximum exposed vaginal wall length. Second, we only evaluated the anteroposterior diameter of the hiatus. It is the area of the exposed vaginal wall that is relevant and it would be ideal to be able to determine the lateral dimension as well. However, 90 % of hiatal area variation is explained by changes in AP diameter; thus, changes in transverse diameter contribute only about 10 % [21]. Second, this study observed displacements seen in women who had a uterus in situ and in those who had not undergone prior pelvic floor surgery; therefore, our results are not generalizable to women with post-hysterectomy

prolapse. Third, we obtained our data from women performing straining in a supine position, which may eliminate some of the gravity factor in developing the cystocele. This is, however, the way in which gynecologists establish the size of prolapse during clinical examination and with care taken to make sure that the individual strains are hard enough, adequate development of the prolapse can be achieved. Finally, this paper reports the finding of a small pilot study, even though the two examiners agreed on point placement and tracing, inter-/intra-reliability data were not captured and analyzed. Also, this study is not a population-based study; thus, the spectrum evaluated is not representative of the population at large.

Our study on dynamic MRI at maximum straining found a strong correlation between prolapse severity and length of exposed vaginal wall. It provides in vivo evidence to support our previous modeling effort which shows that the exposed vagina wall length is the key to the development and progression of the cystocele.

**Acknowledgments** We gratefully acknowledge study support from the Office for Research on Women's Health SCOR on Sex and Gender Factors Affecting Women's Health P50 HD044406, BIRCWH K12 HD004438 and the National Institute of Child Health and Human Development Grants 2, R01 HD 038665. We also greatly appreciate Patricia Pacheco for her work on the early development of this project.

**Conflicts of interest** A. Yousuf, L. Chen, K. Larson have no conflicts of interest. J. A. Ashton-Miller receives research support from Boston Scientific and Proctor & Gamber and is consultant for Johnson & Johnson. J. O. L. DeLancey is consultant for Johnson & Johnson.

All authors perform protocol/project development, data analysis, and manuscript writing. A. Yousuf also performs data collection.

## References

- Boyles SH, Weber AM, Meyn L (2003) Procedures for pelvic organ prolapse in the United States, 1979–1997. *Am J Obstet Gynecol* 188: 108–115
- Hendrix SL, Clark A, Nygaard I, Aragaki A, Barnabei V, McTiernan A (2002) Pelvic organ prolapse in the Women's Health Initiative: gravity and gravidity. *Am J Obstet Gynecol* 186:1160–1166
- Benson JT, Lucente V, McClellan E (1996) Vaginal versus abdominal reconstructive surgery for the treatment of pelvic support defects: a prospective randomized study with long-term outcome evaluation. *Am J Obstet Gynecol* 175(6):1418–1421, discussion 1421–1422
- Nguyen JK (2001) Current concepts in the diagnosis and surgical repair of anterior vaginal prolapse due to paravaginal defects. *Obstet Gynecol Surv* 56(4):239–246
- Nguyen JN, Burchette RJ (2008) Outcome after anterior vaginal prolapse repair: a randomized controlled trial. *Obstet Gynecol* 111(4):891–898
- Maher CF, Murray CJ, Carey MP, Dwyer PL, Ugoni AM (2001) Iliococcygeus or sacrospinous fixation for vaginal vault prolapse. *Obstet Gynecol* 98(1):40–44
- Maher C, Baessler K (2006) Surgical management of anterior vaginal wall prolapse: An evidencebased literature review. *Int Urogynecol J Pelvic Floor Dysfunct* 17(2):195–201
- Shull BL, Bachofen C, Coates KW, Kuehl TJ (2000) A transvaginal approach to repair of apical and other associated sites of pelvic organ prolapse with uterosacral ligaments. *Am J Obstet Gynecol* 183(6): 1365–1373, discussion 1373–1374
- Fialkow MF, Newton KM, Weiss NS (2008) Incidence of recurrent pelvic organ prolapse 10 years following primary surgical management: a retrospective cohort study. *Int Urogynecol J Pelvic Floor Dysfunct* 19(11):1483–1487
- Rooney K, Kenton K, Mueller ER, FitzGerald MP, Brubaker L (2006) Advanced anterior vaginal wall prolapse is highly correlated with apical prolapse. *Am J Obstet Gynecol* 195(6):1837–1840
- Summers A, Winkel LA, Hussain HK, DeLancey JOL (2006) The relationship between anterior and apical compartment support. *Am J Obstet Gynecol* 194:1438–1443
- DeLancey JO, Morgan DM, Fenner DE, Kearney R, Guire K, Miller JM, Hussain H, Umek W, Hsu Y, Ashton-Miller JA (2007) Comparison of levator ani muscle defects and function in women with and without pelvic organ prolapse. *Obstet Gynecol* 109:295–302
- Dietz HP, Simpson JM (2008) Levator trauma is associated with pelvic organ prolapse. *BJOG* 115(8):979–984
- Dietz HP, Franco AV, Shek KL, Kirby A (2012) Avulsion injury and levator hiatal ballooning: two independent risk factors for prolapse? An observational study. *Acta Obstet Gynecol Scand* 91(2):211–214
- Weemhoff M, Shek KL, Dietz HP (2010) Effects of age on levator function and morphometry of the levator hiatus in women with pelvic floor disorders. *Int Urogynecol J* 21(9):1137–1142
- Andrew BP, Shek KL, Chantarasorn V, Dietz HP (2013) Enlargement of the levator hiatus in female pelvic organ prolapse: cause or effect? *Aust N Z J Obstet Gynaecol* 53(1):74–78. doi:10.1111/ajo.12026. Epub 2012 Dec 31
- Chen L, Ashton-Miller JA, DeLancey JO (2009) A 3D finite element model of anterior vaginal wall support to evaluate mechanisms underlying cystocele formation. *J Biomech* 42(10):1371–1377
- Hsu Y, Chen L, Julie T, Ashton-Miller JA, DeLancey JOL (2010) In vivo assessment of anterior compartment compliance and its relation to prolapse. *Int Urogynecol J* 21:1111–1115
- Hsu Y, Chen L, Summers A, Ashton-Miller JA, DeLancey JOL (2008) Anterior vaginal wall length and degree of anterior compartment prolapse seen on dynamic MRI. *Int Urogynecol J* 19:137–142
- Betschart C, Chen L, Ashton-Miller JA, DeLancey JO (2013) On pelvic reference lines and the MR evaluation of genital prolapse: a proposal for standardization using the Pelvic Inclination Correction System. *Int Urogynecol J* 24:1421–1428
- DeLancey JO, Hurd WW (1998) Size of the urogenital hiatus in the levator ani muscles in normal women and women with pelvic organ prolapse. *Obstet Gynecol* 91(3):364–368
- Swift SE, Tate SB, Nicholas J (2003) Correlation of symptoms with degree of pelvic organ support in a general population of women: what is pelvic organ prolapse. *Am J Obstet Gynecol* 189:372–379
- Rud T (1980) Urethral pressure profile in continent women from childhood to old age. *Acta Obstet Gynecol Scand* 59(4):331–335
- Barber MD, Brubaker L, Nygaard I, Wheeler TL 2nd, Schaffer J, Chen Z, Spino C; Pelvic Floor Disorders Network (2009) Defining success after surgery for pelvic organ prolapse. *Obstet Gynecol* 114(3):600–609
- Larson KA, Smith T, Berger MB, Abernethy M, Mead S, Fenner DE, Delancey JO, Morgan DM (2013) Long-term patient satisfaction with Michigan four-wall sacrospinous ligament suspension for prolapse. *Obstet Gynecol* 122(5):967–975
- DeLancey JOL (2012) Surgery for cystocele III: do all cystoceles involve apical descent? Observations on cause and effect. *Int Urogynecol J* 23:665–667
- Larson KA, Luo J, Guire KE, Chen L, Ashton-Miller JA, DeLancey JO (2012) 3D analysis of cystoceles using magnetic resonance imaging assessing midline, paravaginal, and apical defects. *Int Urogynecol J* 23(3):285–293

28. Cosson M, Lambaudie E, Boukerrou M, Lobry P, Crépin G, Ego A (2004) A biomechanical study of the strength of vaginal tissues. Results on 16 post-menopausal patients presenting with genital prolapse. *Eur J Obstet Gynecol Reprod Biol* 112(2):201–205
29. Cosson M, Boukerrou M, Lacaze S, Lambaudie E, Fasel J, Mesdagh H, Lobry P, Ego A (2007) A study of pelvic ligament strength. *Eur J Obstet Gynecol Reprod Biol* 109(1):80–87
30. Chen L, Ashton-Miller JA, Hsu Y, DeLancey JO (2006) Interaction among apical support, levator ani impairment, and anterior vaginal wall prolapse. *Obstet Gynecol* 108(2):324–332
31. Volloyhaug I, Wong V, Shek KL, Dietz HP (2013) Does levator avulsion cause distension of the genital hiatus and perineal body? *Int Urogynecol J* 24(7):1161–1165