

## Effect of Hydro-alcoholic Extract of Persian Oak (*Quercus brantii*) in Experimentally Gastric Ulcer

Shahrzad Azizi<sup>a\*</sup>, Abdollah Ghasemi Pirbalouti<sup>b,c</sup> and Mahdi Amirmohammadi<sup>d</sup>

<sup>a</sup>Department of Pathobiology, Veterinary Medicine Faculty, Shahid Bahonar University of Kerman, Kermn, Iran. <sup>b</sup>Department of Medicinal Plants, Shahrekord Branch, Islamic Azad University, Shahrekord, Iran. <sup>c</sup>Medicinal Plants Program, Collage of Natural Science, University of Massachusetts, Amherst, MA, 1003, USA. <sup>d</sup>Young Research Club, Islamic Azad University, Jiroft Branch, Kerman, Iran.

### Abstract

Persian oak (*Quercus brantii* Lindl.) belongs the family Fagaceae, is a medicinal plant which seed flour is used to treat inflammatory and gastric ulcers by the tribes in south western Iran. The current study was done to evaluate the effect of hydro-alcoholic extract of *Q. brantii* seed flour for treatment of gastric ulcers induced by ethanol in Wistar rats. The hydro-alcoholic extract of *Q. brantii* was tested orally at doses of 250, 500, and 1000 mg/Kg, control group and standard drug (omeprazole) on experimentally gastric ulceration. At the 3, 6, 9, and 14<sup>th</sup> days, ulcer index in mm<sup>2</sup> and histopathological findings were evaluated. Results indicated the size of ulcers significantly reduced at 9, and 14 days after of *Q. brantii* extract treatment. Curative effect in the hydro-alcoholic induced gastric damage was 100% at 1000 mg/Kg and omeprazole, 99.8 % at 500 mg/Kg, and 95.4% at 250 mg/Kg after 14 days. Results of histopathological investigation showed the thickness of ulcerated mucosa was similar to the normal mucosa with 1000 mg/Kg of *Q. brantii* hydro-alcoholic extract after 14 days but in the groups treated by 250, and 500 mg/Kg, superficial erosions were visible in the central portion of the healed ulcers. In conclusion, the hydro-alcoholic extract of *Q. brantii* had active components (tannin = 8.2%) that accelerates ulcer healing and thus supported its traditional use.

**Keywords:** *Quercus brantii* Lindl; Histopathology; Gastric ulcer; Rat.

### Introduction

Gastric ulcer is a common disorder of digestive system that a considerable number of people in the world are affects. Current chemical drugs using for treatment of gastric ulcer are associated with many side effects. Recently, developing of new drugs with herbal origin is considered for decline of chemical drugs side effects (1). In folk knowledge, medicinal plants

are used for treatment of various disorders with little information of their pharmacological uses (2).

*Quercus* is the most frequent genus of the Fagaceae family in forests of Iran (3). Several species of oaks grow abundantly in Zagros, Arasbaran and Hyrcanian forests exhibiting remarkable morphological variation. The main species of Chaharmahal va Bakhtiari forests is *Q. brantii*, which is widely distributed all over the area, particularly between 700 and 2400 m of altitude above sea level. *Q. brantii* popularly known as Persian oak in English and

\* Corresponding author:  
E-mail: azizi@uk.ac.ir

“Balout Irani” in Persian used for treatments gastric disorders by traditional people in Zagros region (Chaharmahal va Bakhtiari, Ilam and Kohghiluyeh va Boyer Ahmad provinces), southwestern Iran (4, 5, 6). The seed hulls of the Persian oak have been used as an anti-diarrheic remedy in traditional medicine. The tannins extracted from *Q. brantii* have contractive and disinfectant effects (7). The extracts isolated from *Q. brantii* seed and seed hulls have been shown to have biological and pharmacological activities such as anti-bacterial (8, 9, 10), wound healing effect (11).

To our knowledge, no documented reports on the hydro-alcoholic extract of *Q. brantii* seed on gastric ulcers are available. Therefore, the aim of this study was to evaluate the effect of hydro-alcoholic extract of *Q. brantii* seed flour for treatment of gastric ulcers induced by ethanol in Wistar rats.

## Experimental

### *Collection and identification of plant material*

Fruits of Persian oak (*Quercus brantii* Lindl., the Fagaceae family) were collected in September 2011 from Ardal region in central Zagros mountains (latitude. 31° 50', longitude. 51° 23', altitude. 2120 m above sea level), Chaharmahal va Bakhtiari province, Iran. Plant identities were confirmed by Dr. H.A. Shirmardi, and a representative voucher specimen (IAUSHK-351) was been placed in the Herbarium of Research Center of Medicinal Plants and Ethno-veterinary, I.A.U, Iran.

### *Plant extract preparation*

Seeds of Persian oak were dried inside for one week at room temperature (30 ± 5 °C), and the ground to fine a powder using Moulinex food processor. The hydro-alcoholic extract was obtained by maceration of the crude plant powder with ethanol/water (70/30) for four days in a chamber temperature (35 ± 5 °C) in the dark. The extract was filtered using a sterile cloth sheet. The filtrate was evaporated under reduced pressure at temperature below 45 °C with a rotary evaporator and a dark green hydro-alcohol extract (yield: 14.1%) was obtained. Phytochemical screening of the extract revealed

the presence of tannins. The extract samples were stored in universal bottles and kept at 4 °C prior to use.

### *Ethanol induced ulcer*

Male Wistar rats (200-250 g) of three months were used. The animals were housed in standard environmental conditions of temperature (22 ± 3 °C), humidity (60 ± 5%) and a 12 h light/dark cycle. During experimental time rats were given standard pellet diet (Pastor Institute, Iran) and water *ad libitum*. The rats were used for the experiment after one week of acclimatization period. All the procedures were approved by the Medical Ethics Committee of Shahrekord University of Medical Sciences. The rats fasted for 48 h and supplied with sucrose 8% during the fasting period. Each animal received 1 mL of absolute ethanol (99.6%) orally (12, 13). The animal divided in groups including *Q. brantii* extracts (250, 500, and 1000 mg/Kg), omeprazole (20 mg/Kg), and distilled water (control negative). Treatment was performed orally after 1 h of ulcer induction until 14 days.

### *Determination of ulcer index*

On 3, 6, 9, and 14 days after induced ulcer, experimental rats were euthanized and then necropsied. After excision of the abdomen, the stomach was opened along the greater curvature and washed by normal saline. Ulcer areas on the glandular and non-glandular of gastric mucosa were examined macroscopically. Graded transparency sheet with square millimeter paper was put on stomachs surface and investigated under a dissecting microscope. The ulcerous areas were drawn on sheet. The sum of the ulcerous areas was expressed in mm<sup>2</sup> as the ulcer score. Curative effects of the *Q. brantii* extracts were evaluated with the following formula and compared with the results obtained from control and omeprazole groups (14).

$$\text{Curative ratio} = \frac{(\text{Control ulcer index}) - (\text{Test ulcer index})}{(\text{Control ulcer index})} \times 100$$

### *Pathologic investigation*

At the 3, 6, 9 and 14<sup>th</sup> days, experiment was

**Table 1.** Effect of *Quercus brantii* extract on ethanolic gastric ulcer in rats.

<i>p</i>	Curative Ratio (%)	Ulcer index (mm <sup>2</sup> )	Dose (mg/Kg)	Test Samples	No of Animals	Treatment duration
	-	321.66 ± 17.90 <sup>b*</sup>	-	Ethanol + D.W	3	
	53.3	150.00 ± 33.20 <sup>ab</sup>	20	Ethanol + Om	3	
0.05<	60.1	128.33 ± 9.27 <sup>a</sup>	250	Ethanol + QB	3	3 days
	72.2	90.00 ± 12.16 <sup>a</sup>	500	Ethanol + QB	3	
	41.9	186.66 ± 43.71 <sup>ab</sup>	1000	Ethanol + QB	3	
	-	251.0 ± 26.83 <sup>b</sup>	-	Ethanol + D.W	3	
	79.6	51.00 ± 11.84 <sup>a</sup>	20	Ethanol + Om	3	
0.01<	68.4	79.33 ± 24.67 <sup>a</sup>	250	Ethanol + QB	3	6 days
	74.2	64.66 ± 7.42 <sup>a</sup>	500	Ethanol + QB	3	
	70.9	73.00 ± 18.00 <sup>a</sup>	1000	Ethanol + QB	3	
	-	285.66 ± 7.85 <sup>c</sup>	-	Ethanol + D.W	3	
	93.1	19.66 ± 8.19 <sup>a</sup>	20	Ethanol +Om	3	
0.01 <	79.2	59.33 ± 8.29 <sup>b</sup>	250	Ethanol + QB	3	9 days
	93.9	17.33 ± 6.35 <sup>a</sup>	500	Ethanol + QB	3	
	96.3	10.33 ± 4.91 <sup>a</sup>	1000	Ethanol + QB	3	
	-	314.66 ± 17.75 <sup>b</sup>	-	Ethanol + D.W	3	
	100	0 <sup>a</sup>	20	Ethanol + Om	3	
0.01<	99.8	14.33 ± 2.96 <sup>a</sup>	250	Ethanol + QB	3	14 days
	95.4	0.33±0.33 <sup>a</sup>	500	Ethanol + QB	3	
	100	0 <sup>a</sup>	1000	Ethanol + QB	3	

Note: results are mean±SD.

\*Similar letters show no significant difference between groups.

terminated, and the ulcer area was removed from the surviving animals for histological examination. Tissue samples from each suspected lung and regional lymph node (1 × 1 x 0.5 cm<sup>3</sup>) were fixed in 10% neutral buffered formalin for histopathological examination. The samples were then dehydrated in graded ethanol and embedded in paraffin. Sections of 5 µm in thickness were stained with hematoxylin and eosin and examined by an ordinary light microscope (Olympus BX51).

#### Statistical analysis

The results were expressed as mean ± SD. The differences between ulcer indexes of experimental groups were tested by using ANOVA. Means of ulcer index were compared by Tukey-test at  $p \leq 0.05$  level. All data processing was performed with SPSS software

(version 11.5).

## Results

#### Ulcer index

The analysis variance indicated significant differences ( $p \leq 0.01$ ) among different experimental and control groups for ulcer index on 3, 6, 9 and 14 days after ulcer induction (Table 1). At 3<sup>th</sup> day, ulcer index score decreased significantly from  $321.7 \pm 17.9$  mm<sup>2</sup> in negative control to  $128.3 \pm 9.27$ ,  $90.0 \pm 12.16$ ,  $186.66 \pm 43.71$ , and  $150.00 \pm 33.20$  mm<sup>2</sup> in animals treated with the hydro-alcoholic extracts of *Q. brantii* at 250, 500, and 1000 mg/Kg and standard drug (omeprazole). At 6<sup>th</sup> day, ulcer index score decreased significantly from  $251+26.8$  mm<sup>2</sup> in negative control to  $79.33 \pm 24.67$ ,  $64.66 \pm 7.42$ ,  $73.00 \pm 18.00$ , and  $51.00 \pm 11.84$  mm<sup>2</sup> in animals treated with the

hydro-alcoholic extracts of *Q. brantii* at 250, 500 and 1000 mg/Kg and standard drug. At 9<sup>th</sup> day, ulcer index score decreased significantly from  $285.66 \pm 7.85$  mm<sup>2</sup> in negative control to  $59.33 \pm 8.29$ ,  $17.33 \pm 6.35$ ,  $10.33 \pm 4.91$ , and  $19.66 \pm 8.19$  mm<sup>2</sup> in animals treated with the hydro-alcoholic extracts of *Q. brantii* at 250, 500, and 1000 mg/Kg and standard drug. At 14<sup>th</sup> day, ulcer index score decreased significantly from  $314 \pm 17.75$  mm<sup>2</sup> in negative control to  $14.33 \pm 2.96$ ,  $0.33 \pm 0.33$ , 0.00, and 0.00 mm in animals treated with the hydro-alcoholic extracts of *Q. brantii* at 250, 500, and 1000 mg/Kg and standard drugs. Generally, the results indicated that omeprazole, the hydro-alcoholic extracts of *Q. brantii* at 1000, 500, and 250 mg/Kg had 100%, 100%, 99.8%, and 95.4% healing effect after 14 days induced ulcer, respectively.

#### *Evaluation of histopathologic findings*

At 3<sup>th</sup> day of treatment, all experimental and control groups indicated severe mucosal ulceration, necrosis and hemorrhage grossly. Ulcers in different forms and sizes were observed principally in glandular and lesser in non-glandular part of stomach. The mucosal stomach showed hyperemia. The margins ulcers were swollen due to edematous. Hyperemia was more evident in the control groups than in the others. Histopathologically, gastric mucosa was sloughed due to necrosis, and erosions and ulcers in different degrees were occurred. Lamina propria showed hyperemia and hemorrhage. Around the marginal ulcers, inflammatory cells especially neutrophils and a few eosinophils infiltrated. Submucosa layer was edematous and thickened by aggregation a lot of fibrinohemorrhagic exudates.

At 6<sup>th</sup> day, the hyperemia and hemorrhage were decreased in all treated groups especially the group treated by omeprazole. A fibrinonecrotic layer was covered various sizes of ulcers and erosions superficially. The control group showed severe hemorrhage and hyperemia with severe ulcers. At the base of ulcerated areas, granulation tissue developed. Lamina propria and submucosa layer were moderately hyperemic and inflammatory cells were present in these layers.

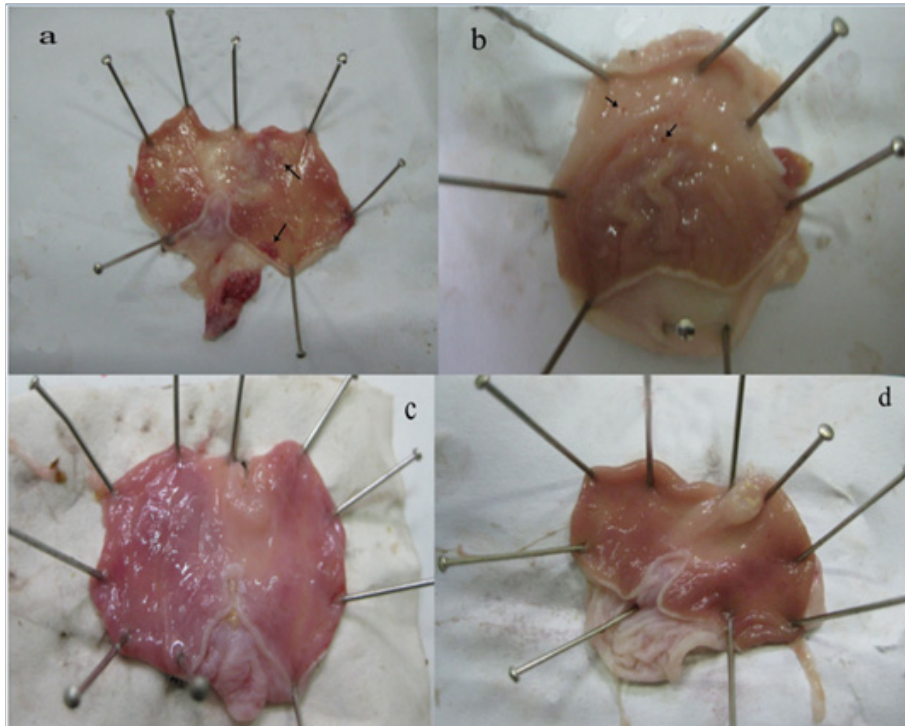
At 9<sup>th</sup> day, mucosal hemorrhage and

hyperemia were decreased remarkable in the hydro-alcoholic extracts of *Q. brantii* at 500, and 1000 mg/Kg and omeprazole group in comparison to control group. The ulcerated lesions were repaired but small erosions were remained yet. The treated group by 250 mg/Kg extract of *Q. brantii*, indicated more hemorrhage and hyperemia, and presence of some ulcers were noticeable. Thickness of gastric mucosa was variable in different areas. Microscopic study indicated proper regeneration of epithelium, especially in the edges of ulcers. New formed gastric glands had simple columnar epithelium with dilated lumens. In the central portion of the healed ulcers superficial erosions were visible. A dense connective tissue scar was observed at the base of healed ulcer. In the submucosa layer, a great number of newly formed vessels were considerable in the extracts treated groups, especially at the higher doses.

At 14<sup>th</sup> day, no gastric erosions or ulcers were found in the rats which received the extract of *Q. brantii* at 1000 mg/Kg, and omeprazole but very small erosions were visible yet at dose 250 and 500 mg/Kg of extracts (Figure 1). Control group showed severe hemorrhage and mucosal lesions (Figure 2). We observed a thicker regenerative mucosa in the treated animals with 1000 mg/Kg and omeprazole in comparing to the groups treated with 250 and 500 mg/Kg for 14 days. Very small superficial erosions were observable yet in the central portion of the healed ulcers (Figure 3). In all groups, there were infiltration of a few lymphocytes and eosinophils in the submucosa layer and the base of repaired areas.

#### **Discussion**

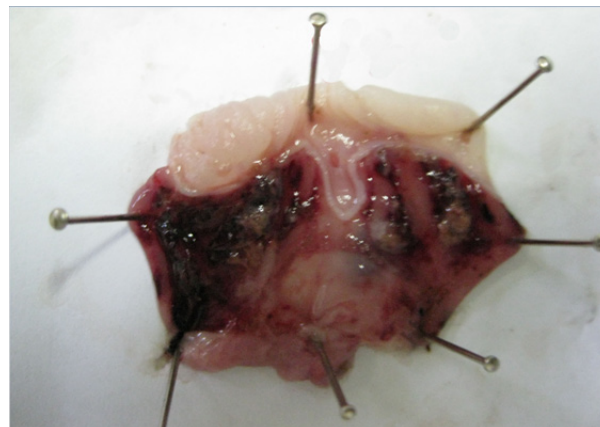In ethno-pharmacology knowledge, study on natural herbal products is aimed for improvement of new drugs because chemical drugs are expensive and have several disadvantages. Attention is focused on components with less price and toxicity that may be more effective. Medical plants are a candidate for substitution with current drugs (15). In folk medicine, some *Quercus* species is a medical plant with various therapeutic properties specially treatment of gastritis (16-18). The current study investigated the healing effect of *Q. brantii* on gastric ulcers



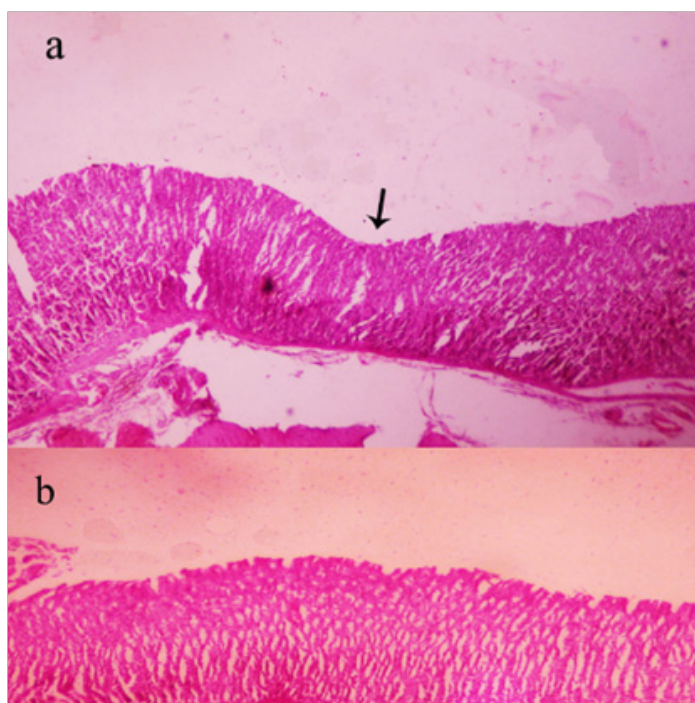
**Figure 1.** Ethanol-induced ulcers in rat's stomach 14 days after treatment; a-d) rat treated with *Quercus brantii* extract 250, 500, 1000 mg/Kg and omeprazole (20 mg/Kg) respectively. Macroscopic small erosions and ulcers are visible in treated rat with 250 and 500 mg/Kg extract (arrows).

induced by ethanol in rats. In experimental studies, intra-gastrically ethanol uses as the most common ulcerogenic agent that lead to severe erosions and ulcers in the stomach (19). The pathogenesis of ethanol-induced gastric ulcers is multifactorial. It causes mucus content of gastric wall is depleted (20). Ethanol disrupts the mucosal barrier of gastric wall with induction of damage to microvessels (21, 22). In addition,

some agents such as indomethacin, alcohol, and aspirin produce oxygen free radicals and enhance lipid peroxidation (23). A powerful relationship has been observed between lipid peroxidation and ulcer formation in the stomach (24). Ethanol induces gastric damages through the oxidative stress and producing of reactive oxygen species (25). Results of our study indicated the hydro-alcoholic extract of *Q. brantii* extract decreased



**Figure 2.** Severe gastric erosions, ulcers and hemorrhage induced by ethanol in rat after 14 days (negative control group treated by saline).



**Figure 3.** Histopathologic features of stomach in rat treated with *Quercus brantii* extract (250 and 500 mg/Kg) show remained superficial erosion in the central part of healed ulcer (arrow) in comparing with dose 1000 mg/Kg of extract (Figure b) ( $\times 100$ , H-E).

index ulcers significantly at all doses (250, 500, and 1000 mg/kg). The macroscopic measures of ulcers showed that the *Q. brantii* extract repaired ethanol induced gastric lesions dose dependently. These results indicate a relationship between extract dosages and time. Microscopically, the thickness of ulcerated mucosa was similar to the normal mucosa with 1000 mg/Kg of *Q. brantii* extract after 14 days but in 250, and 500 mg/Kg dose of extract very small superficial erosions were observed in the gastric wall after 14 days of treatment. Several studies (26, 27, 28, 29, 30) on the gastro-protective effect of crude drugs extracts and herbal mixtures suggest that most studies can be undertaken with doses in the range 100–800 mg/Kg of both crude drug extracts and herbal mixtures. Even at those doses the extract amount administered is a multiple of the traditional doses. In agreement with our study, review literature shows different species of *Quercus* have therapeutic effects on gastric ulcer. Ebrahimi *et al.* (2012) investigated the antibacterial and wound healing effects of methanolic extract of *Q. persica* fruits in three concentrations (25, 50, and 75

mg/mL) in rats. Their results showed that all concentrations were effective on the inhibition of *Staphylococcus aureus*, *S. epidermidis*, and *Escherichia coli* but the effect of 50 and 75 mg/mL extracts was significant for bacteria. In addition, the treated wounds with extract indicated better epithelialization, and wound contraction in comparison to control wounds. They suggested *Q. persica* possesses compounds with antibacterial and wound healing properties (11). Khouzami *et al.* (2009) investigated gastro-protective effect of *Q. infectoria* extract bark for two days. They reported (56–67%) protection against induced gastric lesions by ethanol (16). Gastro-protective and curative effects of *Quercus* spp. against ethanol-induced gastric damage were also attributed to other species of *Quercus* including extract from *Quercus ilex* root bark (31, 32), *Q. coccifera* and, *Q. aegilops* fruits (17). Khennouf *et al.* (2010) studied the anti-lipoperoxidant activity of some phenolic acids, flavonoids and purified tannins from *Quercus* spp. They described the phenolic acids, flavonoids and purified tannins exhibit gastro-protective properties by acting

as inhibitors of lipid peroxidation process (33). These materials showed anti-lipoperoxidant activity. This antioxidant property is believed to be responsible for the gastro-protective effects of *Quercus* tannins and phenolic compounds. In addition, reported the polyphenols such as tannic acid, quercetin and ellagic acid in *Q. infectoria* bark, are able to inhibit the proton pump present in parietal cells and resulting in decreasing of gastric acid secretion (18, 31, 32). Khennouf *et al.* (2003) used extracted tannins from leaves of *Q. suber* and *Q. coccifera* orally in mice and observed this component prevented the gastric lesions induced by ethanol (18). In current study, the presence of tannin 8.2% based dry weight in seed flour of *Q. brantii* may be responsible for the curative action of the hydro-alcoholic extract of *Q. brantii* seed. The animals treated with the fruit extract at a higher dose of 1000 mg/Kg did not manifest any significant abnormal signs and changes in behaviors. They had no mortality and decreasing of weight during the course of the experiment. Further studies are needed for detection of different components of *Q. brantii* extract and demonstration of their therapeutic effects of each purified substance.

In conclusion, we can suggest the hydro-alcoholic extract of *Q. brantii* seed is effective in experimentally healing rat ulcers. The hydro-alcoholic extract of *Q. brantii* seed at 250, and 500 mg/Kg produced a significant gastric ulcer when compared with the negative control. We suggest the extract of *Q. brantii* seed and more appropriately the active compounds should be assessed for action mechanisms to elucidate their mode of action. Furthermore, new action mechanisms may be discovered. Hence, the results of current study support the traditional uses of *Q. brantii* to treat gastric ulcer.

### References

- (1) Arun M and Asha VV. Gastroprotective effect of *Dodonaea viscosa* on various experimental ulcer models. *J. Ethnopharmacol.* (2008) 118: 460-465.
- (2) Veiga Junior VF, Pinto AC and Maciel MAM. Plantas medicinais: cura segura? *Quim. Nova.* (2005) 28: 519-528.
- (3) Panahi P, Jamzad Z, Pourmajidian MR, Fallah A, Pourhashemi M and Sohrabi H. Taxonomic revision of the *Quercus brantii* complex (Fagaceae) in Iran with emphasis on leaf and pollen micromorphology. *Acta Bot. Hung.* (2012) 54: 355-375.
- (4) Ghasemi Pirbalouti A. Medicinal plants used in Chaharmahal and Bakhtyari districts, Iran. *Herba. Pol.* (2009) 55: 69-75.
- (5) Mosaddegh M, Naghibi F, Moazzeni H, Pirani A and Esmaeili S. Ethnobotanical survey of herbal remedies traditionally used in Kohghiluyeh va Boyer Ahmad province of Iran. *J. Ethnopharmacol.* (2012) 141: 80-95.
- (6) Ghasemi Pirbalouti A, Momeni M and Bahmani M. Ethnobotanical study of medicinal plants used by Kurd tribe in Dehloran and Abdanan districts, Ilam province, Iran. *Afr. J. Tradit. Complement. Altern. Med.* (2013) 10: 368-385.
- (7) Amin GH. *Traditional Pharmaceutical Plants of Iran.* Iranian Ministry of Health and Medical Education Publications, Tehran (1991) 8-10.
- (8) Khosravi AD and Behzadi A. Evaluation of the antibacterial activity of the seed hull of *quercus brantii* on some Gram negative bacteria. *Pak. J. Med. Sci.* (2006) 22: 429-432.
- (9) Safary A, Motamedi H, Maleki S and Seyyednejad SM. A preliminary study on the antibacterial activity of *Quercus brantii* against bacterial pathogens, particularly enteric pathogens. *Int. J. Botany.* (2009) 5: 176-180.
- (10) Ghasemi Pirbalouti A, Broujeni NV, Momeni M, Poor MF and Hamedi B. Antibacterial activity of Iranian medicinal plants against *Streptococcus iniae* isolated from rainbow trout (*Oncorhynchus mykiss*). *Arch. Biol. Sci.* (2011) 63: 59-66.
- (11) Ebrahimi A, Khayami M and Nejati V. Evaluation of the antibacterial and wound healing activity of *Quercus persica*. *J. Basic Appl. Sci.* (2012) 8: 118-123.
- (12) Gürbüz I and Yesilada E. Evaluation of the anti-ulcerogenic effect of sesquiterpene lactones from *Centaurea solstitialis* L. ssp. *solstitialis* by using various *in-vivo* and biochemical techniques. *J. Ethnopharmacol.* (2007) 112: 284-291.
- (13) Nwidi LL and Nwafor PA. Gastroprotective effects of leaf extracts of *Carpolobia lutea* (polygalaceae) G. Don. in rats. *Afr. J. Biotech.* (2009) 8: 12-19.
- (14) Suleyman H, Cadirci E, Albayrak A, Polat B, Halici Z, Koc F, Hacimuftuoglu A and Bayir Y. Comparative study on the gastroprotective potential of some antidepressants in indomethacin-induced ulcer in rats. *Chem-Biol. Interact.* (2009) 180: 318-324.
- (15) Borelli F and Izzo AA. The plant kingdom as a source of antiulcer Remedies. *Phytother. Res.* (2000) 14: 581-591.
- (16) Khouzami L, Mroueh M, Costantine and Daher F. The role of methanolic extract of *Quercus infectoria* bark in lipemia, glycemia, gastric ulcer and bacterial growth. *J. Med. Plant Res.* (2009) 2: 224-230.
- (17) Alkofahi A and Atta AH. Pharmacological screening of the antiulcerogenic effects of some Jordanian medicinal plants in rats. *J. Ethnopharmacol.* (1999) 67: 341-345.
- (18) Khennouf S, Benabdallah H, Gharzouli K, Amira S,

- Ito H, Kim TK, Yoshida T and Gharzouli A. Effect of tannins from *Quercus suber* and *Quercus coccifera* leaves on ethanol-induced gastric lesions in mice. *J. Agr. Food Chem.* (2003) 51: 1469-1473.
- (19) Shetty R, Kumar KV, Naidu MUR and Ratnakar KS. Effect of *Gingko biloba* extract on ethanol-induced gastric mucosa lesions in rats. *Int. J. Pharmacol.* (2000) 32: 313-317.
- (20) Martin MJ, Marhuenda ME, Perez-Guerrero C and Franco JM. Antiulcer effect of naringin on gastric lesions induced by ethanol in rats. *Pharmacol.* (1994) 49: 144-150.
- (21) Glavin GB and Szabo S. Experimental gastric mucosal injury: laboratory models reveal mechanisms of pathogenesis and new therapeutic strategies. *FASEB J.* (1992) 6: 825-831.
- (22) Ko JKS, Cho CH and Ogle CW. The vagus nerve and its non-cholinergic mechanism in the modulation of ethanol induced gastric mucosal damage in rats. *J. Pharm. Pharmacol.* (1994) 46: 29-33.
- (23) Takeuchi K, Ueki S and Okabe S. Importance of gastric motility in the pathogenesis of indomethacin-induced gastric lesions in rats. *Digest. Dis. Sci.* (1986) 31: 1114-1121.
- (24) Yoshikawa T, Naito Y, Nakumura S, Nishimura S, Kaneko T, Iinuma S, Takahashi S, Kondo M and Yamasaki K. Effects of rebamipide on lipid peroxidation and gastric mucosal injury induced by indomethacin in rats. *Arzneimittel-Forsch* (1993) 34: 1327-1330.
- (25) Marotta F, Tajiri H, Safran P, Fesce E and Ideo G. Ethanol related gastric mucosal damage: evidence of a free radical-mediated mechanism and beneficial effect of oral supplementation with bionormalizer, a novel natural antioxidant. *Digest.* (1999) 60: 538-543.
- (26) Sairam K, Priyambada S, Aryya NC and Goel RK. Gastroduodenal ulcer protective activity of *Asparagus racemosus*: an experimental, biochemical and histological study. *J. Ethnopharmacol.* (2003) 86: 1-10.
- (27) Yusuf S, Agunu A and Diana M. The effect of *Aloe vera* A. Berger (Liliaceae) on gastric acid secretion and acute gastric mucosal injury in rats. *J. Ethnopharmacol.* (2004) 93: 33-37.
- (28) Antonio JM, Gracioso JS, Toma W, Lopez LC, Oliveira F and Souza-Brito ARM. Antiulcerogenic activity of ethanol extract of *Solanum variabile* (false "jurubeba"). *J. Ethnopharmacol.* (2004) 93: 83-88.
- (29) Metowogo, K, Eklou-Gadegbeku K, Agbonon A, Aklikokou, AK and Gbeassor M. Gastroprotective effect of hydroalcoholic extract of *Aloe buettneri*. *Iran. J. Pharm. Res.* (2011) 10: 69-74.
- (30) Behravan E, Heidari R, Heidari M, Fatemi G, Etemad L, Taghipour G and Abbasifard M. Comparison of gastric ulcerogenicity of percolated extract of *Anacardium occidentale* (Cashew Nut) with indomethacin in rats. *Pak. J. Pharm. Sci.* (2012) 25: 111-115.
- (31) Gharzouli K, Khennouf S, Amira S and Gharzouli A. Effects of aqueous extracts of *Quercus ilex* (L.) root bark, *Punica granatum* (L.) fruit peel and *Artemisia-alba* Asso leaves on ethanol-induced gastric damage in rats. *Phytother. Res.* (1999) 13: 42-45.
- (32) Khennouf S, Gharzouli K, Amira S and Gharzouli A. Effects of *Quercus ilex* (L.) and *Punica granatum* (L.) polyphenols against ethanol-induced gastric damage in rats. *Pharmazie.* (1999) 54: 75-76.
- (33) Khennouf S, Amira S, Arrar L and Baghiani A. Effect of some phenolic compounds and *Quercus* tannins on lipid peroxidation. *World Appl. Sci. J.* (2010) 8: 1144-1149.