

# Primary myelolipoma in posterior mediastinum

Yan Xiong<sup>1,2</sup>, Yong Wang<sup>1,3</sup>, Yidan Lin<sup>1</sup>

<sup>1</sup>Thoracic Surgery Department, <sup>2</sup>Department of Orthopaedics, <sup>3</sup>General Surgery Department, West China Hospital, Sichuan University, Chengdu 610000, China

Correspondence to: Yidan Lin, MD. Thoracic Surgery Department, West China Hospital, Sichuan University, No 37 Guo Xue Lane, Chengdu 610041, China. Email: luyibingli2@163.com.

**Abstract:** Myelolipoma in posterior mediastinum is indeed rare. As a benign tumor, it consists of mature fat with scattered foci of haematopoietic elements resembling bone marrow. The computed tomography (CT) and magnetic resonance imaging (MRI) are effective methods to detect them, while the definite diagnosis still depends on pathological diagnosis. Up to now, there is no standard treatment for this disease. Surgery is thought to be the best choice in some literatures reports. In this paper, two patients with primary posterior mediastinal tumor are reported, both of whom were underwent Video-assisted thoracoscopic surgery (VATS). Postoperative pathological diagnosis was myelolipoma.

**Keywords:** Mediastinum; myelolipoma; extra-adrenal; video-assisted thoracic surgery (VATS)

Submitted Mar 16, 2014. Accepted for publication Jul 08, 2014.

doi: 10.3978/j.issn.2072-1439.2014.07.34

View this article at: <http://dx.doi.org/10.3978/j.issn.2072-1439.2014.07.34>

## Introduction

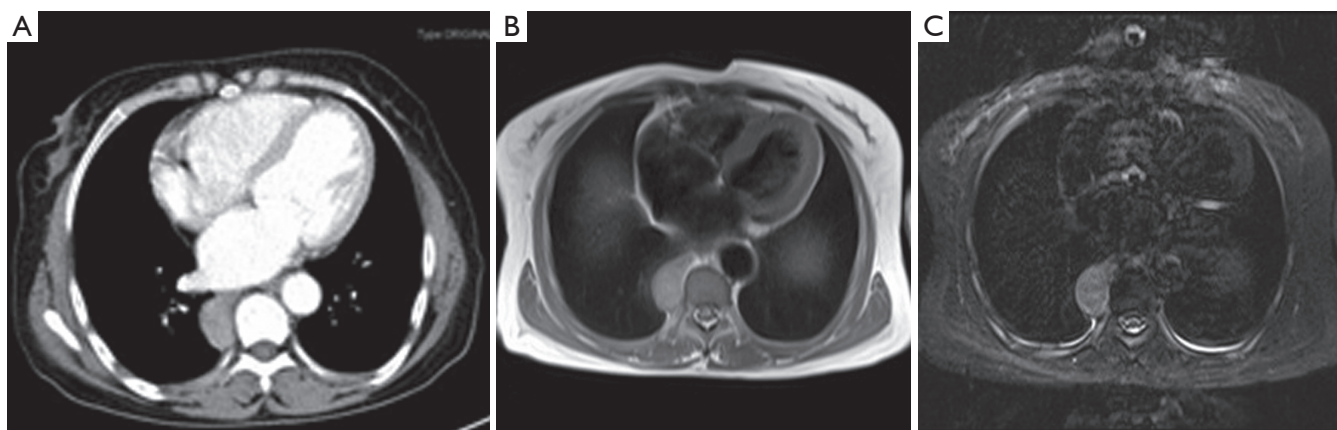
Myelolipoma was first described in 1905, and named 'myelolipoma' in 1929 (1). It is an unusual benign neoplasm composed of mature adipocytes and hematopoietic tissue (2). It is commonly found in adrenal gland. Myelolipomas can also occur in extra-adrenal location. The occurrence in extra-adrenal site is quite rare with an incidence of 0.08-0.2% at autopsy (3). Atypical sites of origin include the presacral region, retroperitoneum, liver, spleen, stomach, greater omentum, leptomeninges, and mediastinum, where myelolipoma is discovered accidentally (4-10). Until now only 28 cases of mediastinal myelolipoma (1-3) including our cases have been reported (11-32). Some of the patients were asymptomatic, while others suffered from a wide variety of symptoms, such as endocrine disorder, anemia, hypertension, splenomegaly, etc. (20-32). Here we represent two cases of posterior mediastinal myelolipoma, whose clinical features and treatments after using minimally invasive thoracic surgery are discussed.

## Case report

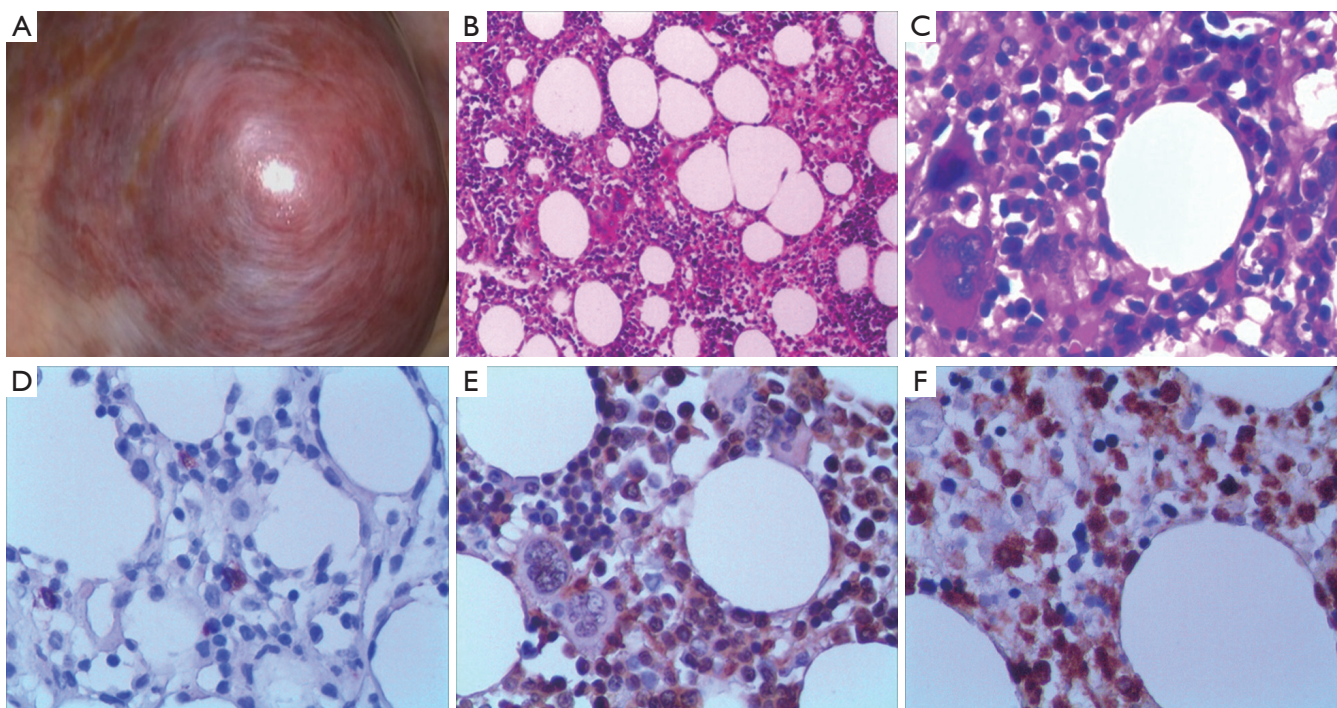
### Case one

A 60-year-old woman presented to our department

with a right lower posterior mediastinal mass which was incidentally revealed by chest computed tomography (CT) scan. Repeated coughing and expectoration for one month made her seek medical assistance. Her past medical history was significant for thalassemia and splenomegaly for 10 years. Enhanced CT scan revealed a partial enhanced mass located in the right lower posterior mediastinum. It was 3.7 cm in diameter beside the vertebral column (*Figure 1*). There was no evidence of bony erosion in nearby rib or vertebra, pleural effusion or surrounding tissue infiltration. Magnetic resonance imaging (MRI) demonstrated that the mass extended from the paravertebral region and moderately intensified signal showed in T1-weighted images (*Figure 1*). Complete blood cell count revealed her red blood cells of  $3.65 \times 10^{12}/L$ , hemoglobin of 65 g/L, white blood cells of  $3.54 \times 10^9/L$  and platelets of  $75 \times 10^9/L$ . It was considered as a neurogenic tumor initially and video-assisted thoracic surgery (VATS) was performed for tumor resection. Grossly, the surgical specimen was approximately 3.7 cm × 3.5 cm × 3 cm as a round-shaped, well-encapsulated, soft and purple mass (*Figure 2*). A microscopic examination revealed a predominant mature adipose and hematopoietic tissue with intermingled. Immunohistochemical stains showed positivity for CD3, CD15, CD20, CD68, CD138 and MPO antibodies



**Figure 1** (A) An enhanced chest CT scan revealed a posterior mediastinal mass, which could be partially enhanced; (B,C) MRI demonstrated that the mass extended from the paravertebral region and was moderately intensified in T1-weighted image. CT, computed tomography; MRI, magnetic resonance imaging.

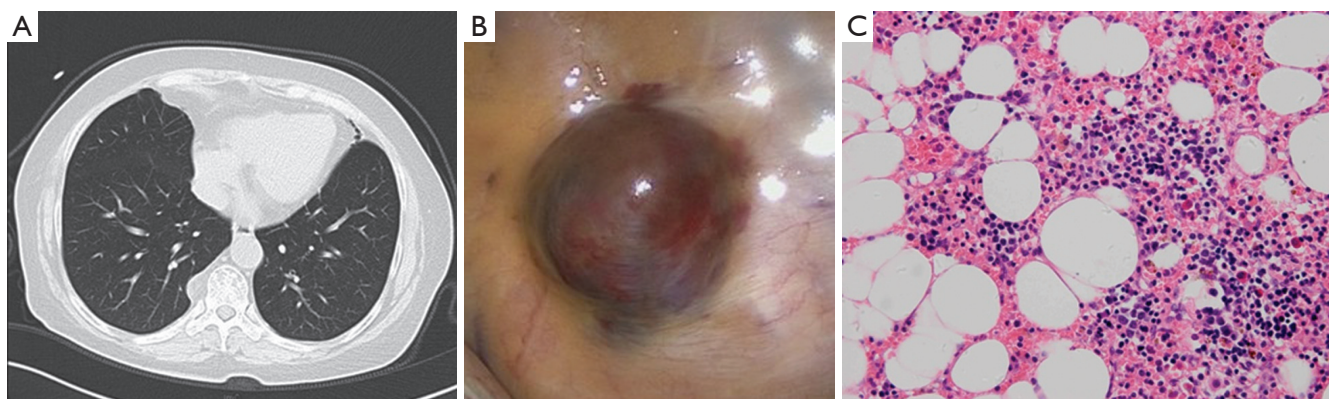


**Figure 2** Macro and microscopical findings of this myelolipoma: (A) a round-shaped, well-encapsued, soft and purple mass was identified in the posterior mediastinum; (B,C) a microscopic examination revealed predominant mature adipose tissue with hematopoietic tissue. There was a variable blend of adipocytes, myeloid, erythroid precursors and mature cells and even megakaryocytes and lymphoid cells resembling all together bone marrow. (Hematoxylin and eosin, B:  $\times 200$ , C:  $\times 400$ ); (D-F) immunohistochemical stains showed positivity for CD20, CD68 and MPO antibodies ( $\times 400$ ).

(Figure 2). Cytokeratin, neuron specific enolase (NSE) and S100 antibodies were negative. Based on these findings, the myelolipoma was confirmed. The patient discharged in the third postoperative day and has remained disease free at 6-month follow-up.

#### Case two

A 68-year-old man was admitted to our hospital and underwent chest CT scan because of palpitation, chest tightness, and shortness of breath. He was diagnosed with



**Figure 3** (A) Chest CT scan revealed one posterior mediastinal mass; (B) grossly, a round-shaped, well-encapsulated purple mass was identified in the posterior mediastinum; (C) the pathology demonstrated predominant adipose tissue interspersed with mature bone marrow elements (Hematoxylin and eosin,  $\times 200$ ). CT, computed tomography.

a right lower posterior mediastinal tumor. He had been through paroxysmal hypertension (the highest value was 200/100 mmHg) for 1 year and it hard to be controlled by medicine. The patient also had a history of type 2 diabetes for 15 years. Noradrenaline and epinephrine of blood and urine were relatively normal. We suspected that it was pheochromocytoma initially. CT revealed there was a mass shadow, which was 2.1 cm in diameter and located in the right lower posterior mediastinum. Its boundary was clear. Enhanced chest CT revealed the mass was partially enhanced (*Figure 3*). We considered it as a pheochromocytoma and VATS was performed for tumor resection. During the operation, a round-shaped, well-encapsulated purple mass was identified in posterior mediastinum in diameter of 1.5 cm. A pathological examination was the same as above-mentioned in the case one postoperatively (*Figure 3*). Thus mediastinal myelolipoma was confirmed, and no signs of malignancy were observed. Paroxysmal increased blood pressure was disappeared and the blood pressure was easy to control by medicine after surgery. After more than 6-month follow-up, he remained clinically well and a CT scan showed no residual tumor.

## Discussion

Myelolipoma is a familiar adrenal tumor with an incidence of 3-5%. However, extra-adrenal myelolipoma is rare with the morbidity of 0.08-0.2% (3). Since the first mediastinum myelolipoma reported in 1925, only 28 cases including our cases have been reported so far in English literatures (*Table 1*). Based on the literature reviews (*Table 2*),

most of them arose from the posterior mediastinum (93%). There were 12 females and 16 males, at a mean age of 64 years. The mass diameter ranged from 1.5 to 25 cm with mean diameter of 5.9 cm. About 25% patients were asymptomatic, while 75% of them were symptomatic. Mainly complaints were cough, chest pain and dyspnea. Almost all the tumors were benign and non-invasive, so did our cases. The prognosis was well after tumor resection.

The etiology of myelolipoma is unclear at present. About four hypotheses were proposed to explain the pathogenesis: (I) most theories indicated that the development and differentiation of either ectopic adrenal or hematopoietic stem cell received triggering stimulus by obesity, hypertension, chronic inflammation, carcinoma, previous trauma or endocrinic disorders, which had been studied in some reported cases. Maybe our second case supports this opinion (23,29,30); (II) some studies suggested that myelolipoma evolved from metaplastic change of embryonic primitive mesenchymal cells or embolism of bone marrow cells via the blood stream (14,17,29); (III) Chang *et al.* reported chromosomal translocations (3,21)(q25;P11) in one case of adrenal myelolipoma without other adrenal lesions (33). This clonal chromosome abnormality was commonly reported to be found in acute myelogenous leukemia and myelodysplastic syndrome. Therefore, this finding suggested that the myelolipoma might be a neoplastic phenomenon as the result of a particular chromosomal mutation. Some cases which were related to anemic condition such as hereditary spherocytosis and thalassemia, might support this hypothesis, so did our first case; (IV) another theory raised the hypothesis that majority of tumors were attached to vertebral bodies, haematopoietic

Table 1 Reported cases of mediastinal myelolipoma\*

Main author	Age/sex	Tumor location	Size (cm)	Clinical feature	Treatment or management	Outcome
Saleeby, 1925 (1)	81/F	Posterior mediastinum	2.5	/	Autopsy	Death
Foster, 1958 (11)	80/M	Posterior mediastinum	4.0	/	Autopsy	Death
Litwer, 1960 (12)	63/M	Posterior mediastinum	9.0	Chronic anemia	Autopsy	Death
	62/M	Posterior mediastinum	7.0	Chronic anemia	Thoracotomy	Not stated
Krag, 1972 (13)	71/F	Anterior mediastinum	5.0	/	Autopsy	Death
Schön, 1984 (14)	50/M	Posterior mediastinum	Not stated	Anemia	Not stated	Not stated
Kim, 1984 (2)	55/M	Posterior mediastinum	7.0	Coronary heart disease, hypertension	Thoracotomy	Not stated
Bastion, 1990 (15)	72/F	Posterior mediastinum.	10.0	Hereditary spherocytosis	Thoracotomy	Not stated
Pulsoni, 1992 (16)	60/M	Bilateral paravertebral area	Right: 4.0; left: 4.4	Hereditary spherocytosis	Thoracotomy	Not stated
De Montpréville, 1993 (17)	65/M	Posterior mediastinum	8.0	Anemia	Thoracotomy	Not stated
Strimlan, 1993 (18)	65/F	Posterior mediastinum	5.0	Chronic obstructive lung disease, chronic respiratory failure	Thoracotomy	No recurrence
Wyttenbach, 1994 (19)	53/M	Anterior mediastinum	8.0	/	Thoracotomy	Not stated
Minamiya, 1997 (20)	59/M	Posterior mediastinum	6.5	/	Thoracotomy	No recurrence
Koizumi, 1999 (21)	55/M	Posterior mediastinum	4.0	Chest pain	VATS	No recurrence at 8 months
Fonte, 1999 (3)	74/F	Posterior mediastinum	2.0	Back pain	Not stated	Not stated
Kawanami, 2000 (22)	72/M	Bilateral paravertebral area	Not stated	Diabetes mellitus	CT-guided needle biopsy	Not stated
Gao, 2002 (23)	59/M	Posterior mediastinum	2.5	Hypertension, bronchitis	Thoracotomy	Not stated
Franiel, 2004 (24)	65/F	Bilateral posterior mediastinum	Left: 4.5; right: 6.5	Hypertension, chronic obstructive bronchitis	Thoracotomy	No recurrence at 12 months
Mohan, 2006 (25)	46/M	Paratracheal mediastinum	4.5	Chest pain	Not stated	Not stated
Rossi, 2007 (26)	73/F	Posterior mediastinum	7.0	/	Fine-needle aspiration, thoracotomy	Not stated
Vaziri, 2008 (27)	56/M	Posterior mediastinum	25.0	Cough, dyspnea	Thoracotomy	No recurrence
Geng, 2013 (28)	68/F	Bilateral posterior mediastinum	Right: 10.0; left: 9.0	Back pain, cough, anemia, type 2 diabetes	Thoracotomy	No recurrence at 3 years

Table 1 (continued)

Table 1 (continued)

Main author	Age/sex	Tumor location	Size (cm)	Clinical feature	Treatment or management	Outcome
Ema, 2013 (29)	68/M	Posterior mediastinum	3.0	/	VATS	No recurrence at 10 months
Fonda, 2013 (30)	64/F	Posterior mediastinum	3.0	Type 2 diabetes, leukocytosis	VATS	No recurrence
Migliore, 2014 (31)	56/F	Posterior mediastinum	3.5	Obese, chest pain	VATS	No recurrence at 11 months
Nakagawa, 2014 (32)	79/M	Bilateral paravertebral area	Th-8:1.9; Th-10:4; Th-9~10:7.5	Hypertension, nephrosclerosis, alcoholic liver hepatitis	VATS	No recurrence at 4 years
Our case	60/F	Posterior mediastinum	3.7	Cough, thalassemia, splenomegaly	VATS	No recurrence
	68/F	Posterior mediastinum	2.1	palpitation, chest tightness, Hypertension, type 2 diabetes	VATS	No recurrence

F, female; M, male; VATS, video-assisted thoracoscopic surgery; /, the clinical feature has nothing to do with the tumor; \*, the report cases from references (1-3) and (11-32).

**Table 2** The summary characteristics of reported patients with mediastinal myelolipoma\*

Characteristics	Number
Age [mean] (year)	46-81 [64]
Male:female	16:12
Symptoms [%] <sup>†</sup>	
Endocrine disorder	6.0 [21]
Hematopoietic systemic abnormality	9.0 [32]
CVD	5.0 [18]
Symptoms of respiratory system	10.0 [36]
Another	6.0
Tumor size [mean] (cm)	1.5-25 [5.9]
Tumor location [%]	
Posterior mediastinum	26.0 [93]
Anterior mediastinum	2.0 [7]
Treatment	
VATS	7.0
Thoracotomy	13.0
Another	8.0

\*, values are number of patients unless specified otherwise;

<sup>†</sup>, some patients had multiple symptoms; symptoms (%), number of patients with this symptom/total number of patients (%); tumor location (%), number of patients in this location/total number of patients (%); VATS, video-assisted thoracoscopic surgery; CVD, cardiovascular disease. Data from references (1-3) and (11-32).

tissue might project from vertebral microfractures to paravertebral space. Ectopic haematopoietic tissue may include stem cells that would be the origin of myelolipoma formation (30).

The mediastinum myelolipoma does not have any pathognomonic signs or symptoms. Thus it is difficult to definitively diagnose without histopathologic evaluations. Ultrasonography, CT scan and MRI have become more common as useful diagnostic tools and given some clues to the correct diagnosis (19,22,26). Although CT and MRI were effective in diagnosing myelolipoma, a confident conclusion was made difficultly before surgery. Some authors reported that Fine-needle aspiration under the guidance of CT scan or ultrasonography—combined with pathological examination—could be used to confirm the diagnosis (22,23,26). However, due to myelolipoma mostly occurring in posterior mediastinum (93%), especially for

small mass, it is too difficult to biopsy accurately by Fine-needle aspiration from anterior chest wall, which can be associated with a risk simultaneously, such as hemorrhage, pneumothorax etc. The spine blocks the Fine-needle aspiration if entering from posterior chest wall. Therefore, Fine-needle aspiration with posterior mediastinum is not be advocated in our opinion.

At present, there is no standard treatment for mediastinal myelolipoma. According to treatment with mediastinal tumor (34), once a neoplasm is discovered in the mediastinum, especially unconfirmed behavior of the tumor, surgical resection may be an optimal treatment for patient. Particularly, VATS is a satisfactory choice (30-32). As we can see in *Table 1*, the tumor size ranges from 1.5 to 25 cm, which reveals that the myelolipoma has potential of continuous growth. With the tumor growing constantly, the patients have to receive thoracotomy eventually, which would cause more trauma and risks, particularly to seniors. Therefore, once the mediastinal myelolipoma is found, surgery is a preferred treatment for patient in our opinion, especially with VATS.

## Conclusions

Myelolipoma in posterior mediastinum is a rare tumor, without exact etiology. It primarily occurs in seniors with concealed onset. The patients usually resort to medical attention for symptoms by chest discomfort, anemia, hypertension, endocrinic disorders. In our reports, they might be closely related to ectopic hematopoiesis and endocrine disorder. Maybe we should spend more time and energy on investigating the cause of myelolipoma. Radiological investigations are the diagnostic modality of choice. Surgery is an optimal treatment for patient, especially VATS. The long-term prognosis is very good.

## Acknowledgements

*Disclosure:* The authors declare no conflict of interest.

## References

1. Saleeby ER. Heterotopia of the Bone Marrow without Apparent Cause. *Am J Pathol* 1925;1:69-76.3.
2. Kim K, Koo BC, Davis JT, et al. Primary myelolipoma of mediastinum. *J Comput Tomogr* 1984;8:119-23.
3. Fonte JM, Varma JD, Kuligowska E, et al. Thoracic case of the day. Kartagener's syndrome. *AJR Am J Roentgenol*

- 1999;173:822, 826-7.
4. Fowler MR, Williams RB, Alba JM, et al. Extra-adrenal myelolipomas compared with extramedullary hematopoietic tumors: a case of presacral myelolipoma. *Am J Surg Pathol* 1982;6:363-74.
  5. Vaziri M, Sadeghipour A, Pazooki A, et al. Primary mediastinal myelolipoma. *Ann Thorac Surg* 2008;85:1805-6.
  6. Prahlow JA, Loggie BW, Cappellari JO, et al. Extra-adrenal myelolipoma: report of two cases. *South Med J* 1995;88:639-43.
  7. Radhi J. Hepatic myelolipoma. *J Gastrointest Liver Dis* 2010;19:106-7.
  8. Cina SJ, Gordon BM, Curry NS. Ectopic adrenal myelolipoma presenting as a splenic mass. *Arch Pathol Lab Med* 1995;119:561-3.
  9. Le Bodic MF, Mussini-Montpellier J, Magois JY, et al. Myelolipoma of the stomach. *Arch Anat Pathol (Paris)* 1974;22:119-22.
  10. Karam AR, Nugent W, Falardeau J, et al. Multifocal extra-adrenal myelolipoma arising in the greater omentum. *J Radiol Case Rep* 2009;3:20-3.
  11. Foster JB. Primary thoracic myelolipoma: case report. *AMA Arch Pathol* 1958;65:295-7.
  12. Litwer H. Myelolipoma of the mediastinum. *Radiology* 1960;74:471-3.
  13. Krag D, Reich SB. Heterotopic bone marrow (myelolipoma) of the mediastinum. *Chest* 1972;61:514-5.
  14. Schön HR, Emmerich B, Arnold H, et al. Hemolytic anemia with pyruvate kinase deficiency presenting as paravertebral myelolipoma. *Klin Wochenschr* 1984;62:133-7.
  15. Bastion Y, Coiffier B, Felman P, et al. Massive mediastinal extramedullary hematopoiesis in hereditary spherocytosis: a case report. *Am J Hematol* 1990;35:263-5.
  16. Pulsoni A, Ferrazza G, Malagnino F, et al. Mediastinal extramedullary hematopoiesis as first manifestation of hereditary spherocytosis. *Ann Hematol* 1992;65:196-8.
  17. De Montpréville VT, Dulmet EM, Chapelier AR, et al. Extramedullary hematopoietic tumors of the posterior mediastinum related to asymptomatic refractory anemia. *Chest* 1993;104:1623-4.
  18. Strimlan CV, Khasnabis S. Primary mediastinal myelolipoma. *Cleve Clin J Med* 1993;60:69-71.
  19. Wyttenbach R, Fankhauser G, Mazzucchelli L, et al. Primary mediastinal myelolipoma: a case report. *European Radiology*. 1994;4:492-5.
  20. Minamiya Y, Abo S, Kitamura M, et al. Mediastinal extraadrenal myelolipoma: report of a case. *Surg Today* 1997;27:971-2.
  21. Koizumi J, Harada H, Yamamoto N, et al. A case of mediastinal myelolipoma. *Kyobu Geka* 1999;52:869-71.
  22. Kawanami S, Watanabe H, Aoki T, et al. Mediastinal myelolipoma: CT and MRI appearances. *Eur Radiol* 2000;10:691-3.
  23. Gao B, Sugimura H, Sugimura S, et al. Mediastinal myelolipoma. *Asian Cardiovasc Thorac Ann* 2002;10:189-90.
  24. Franiel T, Fleischer B, Raab BW, et al. Bilateral thoracic extraadrenal myelolipoma. *Eur J Cardiothorac Surg* 2004;26:1220-2.
  25. Mohan K, Gosney JR, Holemans JA. Symptomatic mediastinal myelolipoma. *Respiration* 2006;73:552.
  26. Rossi M, Ravizza D, Fiori G, et al. Thoracic myelolipoma diagnosed by endoscopic ultrasonography and fine-needle aspiration cytology. *Endoscopy* 2007;39 Suppl 1:E114-5.
  27. Vaziri M, Sadeghipour A, Pazooki A, et al. Primary mediastinal myelolipoma. *Ann Thorac Surg* 2008;85:1805-6.
  28. Geng C, Liu N, Yang G, et al. Primary mediastinal myelolipoma: A case report and review of the literature. *Oncol Lett* 2013;5:862-864.
  29. Ema T, Kawano R. Myelolipoma of the posterior mediastinum: report of a case. *Gen Thorac Cardiovasc Surg* 2013. [Epub ahead of print].
  30. Fonda P, de Santiago E, Guijarro M, et al. Mediastinal myelolipoma with leukocytosis. *BMJ Case Rep* 2013;2013. pii: bcr2013010349.
  31. Migliore M, Calvo D, Criscione A, et al. An unusual symptomatic case of mediastinal myelolipoma treated by VATS approach. *Ann Ital Chir* 2014;85:85-7.
  32. Nakagawa M, Kohno T, Mun M, et al. Bilateral video-assisted thoracoscopic surgery resection for multiple mediastinal myelolipoma: report of a case. *Korean J Thorac Cardiovasc Surg* 2014;47:189-92.
  33. Chang KC, Chen PI, Huang ZH, et al. Adrenal myelolipoma with translocation (3;21)(q25;p11). *Cancer Genet Cytogenet* 2002;134:77-80.
  34. Duwe BV, Sterman DH, Musani AI. Tumors of the mediastinum. *Chest* 2005;128:2893-909.

**Cite this article as:** Xiong Y, Wang Y, Lin Y. Primary myelolipoma in posterior mediastinum. *J Thorac Dis* 2014;6(9):E181-E187. doi: 10.3978/j.issn.2072-1439.2014.07.34