

Survey of Japanese ophthalmic surgeons regarding perioperative disinfection and antibiotic prophylaxis in cataract surgery

Kazuki Matsuura¹
Takafumi Mori²
Takeshi Miyamoto³
Chikako Suto⁴
Yusuke Saeki⁵
Shigeto Tanaka⁶
Hajime Kawamura⁷
Shinji Ohkubo⁸
Masaki Tanito^{9,10}
Yoshitsugu Inoue¹¹

¹Nojima Hospital, Kurayoshi,

²Department of Ophthalmology, School of Medicine, Fukushima Medical University, Fukushima,

³Department of Ophthalmology, Wakayama Medical University, Wakayama,

⁴Department of Ophthalmology, Tokyo Women's Medical University, Tokyo,

⁵Department of Ophthalmology, School of Medicine, Fukuoka University, Fukuoka,

⁶Tonosho Central Hospital, Kagawa, ⁷Shiga University of Medical Science, Otsu,

⁸Department of Ophthalmology and Visual Science, Kanazawa University Graduate School of Medical Science, Kanazawa, ⁹Department of Ophthalmology, Shimane University Faculty of Medicine, Izumo, ¹⁰Division of Ophthalmology, Matsue Red Cross Hospital, Matsue, ¹¹Division of Ophthalmology and Visual Science, Faculty of Medicine, Tottori University, Yonago, Japan

Correspondence: Kazuki Matsuura
Nojima Hospital, 2714-1, Sesaki-machi,
Kurayoshi-city, Tottori, 682-0863, Japan
Email i-mnys2001@za.ztv.ne.jp

Purpose: To elucidate Japanese trends for perioperative disinfection and antibiotic selection during cataract surgeries.

Methods: Perioperative iodine use and antibiotic prophylaxis for cataract surgery were surveyed in eight regions in Japan by mail or through interviews from February 1 to March 1, 2014.

Results: We surveyed 572 surgeons, of whom 386 (67%) responded. Most of the surgeons (94%) used iodine compounds before surgery for periocular skin disinfection (povidone-iodine [PI]: 79%; polyvinyl alcohol-iodine [PAI]: 15%) or conjunctival disinfection (85%; PI: 36%; PAI: 49%). Preoperative conjunctival iodine was primarily used as an eye wash (irrigation: 95%) and less often as an eye drop (5%). It was determined that 31% of surgeons waited 30 seconds or more between periocular disinfection and conjunctival disinfection. During surgery, 14% of surgeons used iodine several times, including immediately before intraocular lens insertion, and 7% used the Shimada technique (repeated iodine irrigation). Preoperative antibiotic eye drops were used by 99% of surgeons, and antibiotics were added to the irrigation bottle by 22%. The surgeons reported use of subconjunctival antibiotic injections (23%), antibiotic ointments (79%), and intracameral antibiotics (7%: 22 moxifloxacin; 6 levofloxacin). All surgeons prescribed postoperative eye drops, with 10% initiating the drops on the day of surgery.

Conclusion: Iodine compounds are commonly used preoperatively, but few institutions use iodine compounds intraoperatively, particularly with repeated application. The selection of antibiotic administration and disinfection technique has to be at the surgeon's discretion. However, intracameral antibiotic and intraoperative iodine compound use are techniques that should be widely recognized.

Keywords: intracameral antibiotic, intraoperative iodine, antibiotic prophylaxis, cataract surgery, endophthalmitis

Introduction

Endophthalmitis has become a rare surgical complication. However, it remains the most important concern for surgeons, because it can have devastating consequences on vision. Bacteria exist in the anterior chamber of the eye in 8%–22% of patients by the end of surgery.^{1,2} Investigation of the bacteria that cause endophthalmitis after cataract surgery has revealed that bacterial flora from the patient's conjunctiva and eyelid are the primary sources of infection.³ Therefore, it is generally believed that a preoperative decrease in bacterial contamination in the conjunctival sac may decrease the risk of postoperative endophthalmitis.

According to Ciulla et al⁴ only preoperative povidone-iodine (PI) has received clinical recommendations. However, there is limited evidence on the efficacy of prophylactic antibiotic administration, including preoperative topical antibiotics, subconjunctival antibiotic injections, and antibiotic irrigation.

Typically, 5% or 10% PI has been used worldwide to disinfect the periocular area and surgical field before surgery. Although preoperative topical antibiotics can decrease the bacteria in the conjunctival flora, a complete elimination of bacteria is unlikely. However, PI is advantageous because of its low cost, broad-spectrum activity, rapid bactericidal rate, and the lack of resistance to its bactericidal effects.⁵ PI and preoperative topical antibiotics are effective and well-tolerated. However, 20%–40% of surgical field cultures are positive, even after PI and antibiotic application.^{6–8} Despite the use of sterile draping, bacteria from the eyelashes or eyelids may contaminate the conjunctival surface during surgery. To address these problems, Shimada et al⁹ reported that intraoperative irrigation of the surgical field with PI resulted in extremely low contamination rates in the anterior chamber at the end of surgery.

The Endophthalmitis Surgery Group and the European Society of Cataract and Refractive Surgeons conducted a multicenter clinical trial that identified a five-fold decrease in infection rates with the postoperative intracameral administration of cefuroxime.¹⁰ According to a 6-year Swedish national study, intracameral cefuroxime was responsible for a nationwide decrease in the incidence of postoperative endophthalmitis.¹¹ Other reports have documented the effectiveness and safety of intracameral moxifloxacin.^{12–15}

Although there is an abundance of information on prophylaxis, there is little definitive evidence proving a decrease in the postoperative endophthalmitis rate. Therefore, many surgeons have been ambivalent toward prophylactic strategies for postoperative endophthalmitis. In a previous study from 2012, we surveyed ophthalmic surgeons from six regions in Japan and evaluated their use of prophylactic antibiotics for patients undergoing cataract surgery. In the current study, we evaluated the use of perioperative iodine compounds and prophylactic antibiotics, by surveying surgeons from eight regions in Japan, to clarify the national trends of disinfection and antibiotic choice.

Materials and methods

The survey included a questionnaire that was administered either by mail or through personal interviews from February 1 to March 1, 2014. We selected the following eight regions to avoid an uneven sampling distribution: Fukushima, Ishikawa, Saitama, Wakayama, San'in, Fukuoka, Shiga, and Kagawa (Figure 1). In 2012, we conducted a similar survey¹⁶ in six of the eight regions, not including Shiga and Kagawa. For comparison, the participants in Shiga and Kagawa were

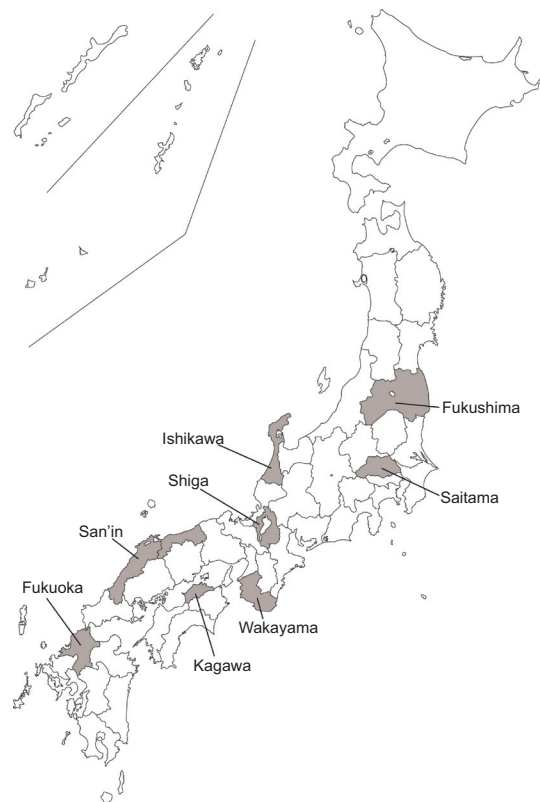


Figure 1 Survey regions.

Note: Eight regions (9 prefectures) were involved in the study, avoiding an uneven sampling distribution.

requested to fulfill the surveys from both 2012 and 2014. The surgeons involved in this study were selected using an official ophthalmologist list. As a result, our survey targeted a broad range of ophthalmologists, regardless of their academic orientation. This may better reflect the awareness of ophthalmologists in general, including cataract specialists and cataract surgeons.

Results

A total of 572 surgeons were contacted, of whom 386 (67%) responded. Our survey consisted of both low- and high-volume surgeons (Table 1). According to unofficial figures, there are an estimated 5,000 cataract surgeons in Japan. Therefore, this survey sampled approximately 8% of all cataract surgeons in Japan.

Table 1 Distribution of respondents by annual cataract volume

Volume (cases)	Respondents (n)
<100	75
100–300	160
300–500	69
>500	82

Table 2 Perioperative disinfection method

	2014	2012
Preoperative		
Periocular iodine compounds	94%	ND
Conjunctival iodine compounds	87%	ND
Ozonated solution	3%	ND
Intraoperative		
Iodine compounds: several times	14%	ND
Iodine compounds: repeated application	7%	ND

Abbreviation: ND, no data.

Polyvinyl alcohol–iodine (PAI) and PI are iodine compounds used in Japan. Before surgery, 94% (PI: 79%; PAI: 15%) and 85% (PI: 36%; PAI: 49%) of surgeons performed periocular skin disinfection and conjunctival irrigation with iodine compounds, respectively (Table 2). Preoperative conjunctival iodine was primarily used as an eye wash (irrigation: 95%) and less often as eye drops (5%).

Periocular disinfection was performed primarily using 10% or 5% PI. For conjunctival disinfection after periocular disinfection, 2.5%–0.625% diluted PI or diluted PAI, equivalent to 0.5%–0.25% PI, was used (Table 3). We determined that 31% of surgeons waited for 30 seconds or more between periocular disinfection and conjunctival disinfection.

Among the surgeons who did not use preoperative iodine compounds, 5% and 1% used chlorhexidine gluconate and benzethonium chloride, respectively. Chlorhexidine gluconate, ozonated solution, benzethonium chloride, and balanced salt solution were used for conjunctival irrigation by 9%, 3%, 2%, and 2% of surgeons, respectively.

During surgery, 14% of surgeons used iodine several times, including immediately before intraocular lens insertion, whereas 7% used the Shimada technique (repeated iodine irrigation) (Table 2). Fifty-six percent of surgeons who did not use iodine compounds during surgery did not acknowledge the necessity of intraoperative disinfection. In addition, 42% and 28% of surgeons reported concerns about toxicity and the lack of information, respectively.

Preoperative antibiotic eye drops were used by 99% (382/386) of surgeons (Table 4). Preoperative topical antibiotic was mostly initiated 2–5 days before surgery (Table 5).

Table 3 Concentration of preoperative iodine compounds

Periocular skin PI (231)	Eye wash with PI (115)	Eye wash with PAI* (151)
10% or 5%: 83% (191)	10% or 5%: 3% (4)	0.25% to 0.5%: 78% (118)
0.625% to 2.5%: 17% (40)	0.625% to 2.5%: 74% (85)	<0.25%: 22% (33)
	<0.625%: 23% (26)	

Note: *4-fold diluted PAI is equivalent to 0.5% PI.

Abbreviations: PI, povidone–iodine; PAI, polyvinyl alcohol–iodine.

Table 4 Perioperative and postoperative use of antibiotic prophylaxis

	2014 (386)	2012 (368)
Preoperative topical antibiotics	99% (382)	99% (365)
Perioperative topical antibiotics	35% (137)	42% (155)
Postoperative topical antibiotics	100% (386)	100% (368)
Irrigation bottle	22% (85)	20% (72)
Intracameral injection	7% (28)	1% (4)
Subconjunctival injection	23% (89)	22% (82)
Antibiotic ointment	79% (304)	86% (318)

Note: 2012 includes the data from both present study and previous study (n=16).

Of these, 356 used a fluoroquinolone (combined use with cephem: 27 surgeons) and 12 used only cephem (Table 6). Preoperative antibiotic eye drops were initiated upon arrival or 1 day before surgery (7%; 26 surgeons), 2–5 days before surgery (83%; 317 surgeons), or 1 week before surgery (10%; 37 surgeons) (Table 5).

Immediately after surgery, 35% (137/386) of surgeons used antibiotic eye drops (Table 4), mainly a fluoroquinolone. Subconjunctival antibiotic injections were used by 23% (89/386) of surgeons (Table 4). Of these, 63 used gentamycin, 17 used cephem, and 6 used a fluoroquinolone (Table 6). Antibiotics were added to the irrigation bottle by 22% (85/386) of surgeons, with 37 using cephem, 35 using imipenem, and 2 using vancomycin (Tables 4 and 6). Ophthalmic antibiotic ointments were used by 79% (304/386) of surgeons, and most of these ointments contained ofloxacin (Tables 4 and 6); 25 surgeons used erythromycin. Some surgeons reported the use of intracameral antibiotics (7%; 28/386); 22 used moxifloxacin, and 6 used levofloxacin (Tables 4 and 6). All surgeons prescribed postoperative eye drops (Table 4); 10% (39/386) initiated the drops on the day of surgery. Fluoroquinolones were the most commonly used antibiotics. Postoperative eye drops were continued for more than 1 month by 63% (244/386) of surgeons (Table 7).

Discussion

Most of the surgeons surveyed in the present study used iodine compounds for preoperative periocular and conjunctival

Table 5 Initiation of preoperative topical antibiotics

	2014 (380)	2012 (361)
Upon arrival or 1 day before surgery	7% (26)	12% (43)
2–5 days before surgery	83% (317)	81% (292)
1 week before surgery	10% (37)	7% (26)

Note: 2012 includes the data from both present study and previous study (n=16).

disinfection. According to Berkelman et al the time required until bactericidal properties are exhibited by iodine is approximately 15 seconds, for concentrations of 0.1%–1.0% iodine, but this increases to 30–120 seconds for 2.5%–10% iodine.¹⁷ This indicates that water is essential for the bactericidal properties of iodine. The dilution of PI results in weakening of the iodine linkage to the carrier polymer, polyvinylpyrrolidone, with a concomitant increase in the amount of free iodine solution. The present study found that 10% or 5% iodine was used for skin disinfection in most patients. However, only 31% of surgeons waited for 30 seconds or more before subsequent conjunctival irrigation with diluted iodine.

In the United States, highly concentrated iodine eye drops are generally used for conjunctival disinfection, but in Japan, diluted iodine compounds are generally used for irrigation. Miño de Kasper et al reported that irrigation with 10 mL of iodine before cataract surgery led to lower culture-positive rates, compared with irrigation with two drops of iodine eye drops.⁷

Considering that all bacteria in the surgical field cannot be eliminated, even with the use of preoperative eye drops and iodine disinfection, the idea of intraoperative iodine compound use seems reasonable and appropriate. However, only a few surgeons used iodine compounds during surgery, particularly with repeated applications. Some surgeons did not use this technique, for fear of corneal damage or because of lack of information (Table 2).

Table 6 Choice of antibiotics

	Preoperative topical antibiotics	Subconjunctival injection	Intracameral injection	Irrigation bottle	Antibiotic ointment
Fluoroquinolone	356	6	28 22 moxifloxacin, 6 levofloxacin		271 (ofloxacin)
Cephem	12+27*	17		37	
Aminoglycoside	1	63		6	2
Imipenem		1		35	
Erythromycin	1				25
Penicillin		1		3	
Others		1		2 (vancomycin)	
Used but not identified	12			2	6
Total	382	89	28	85	304

Note: *27 surgeons used cephem combined with fluoroquinolone.

Table 7 Duration of postoperative topical antibiotic use

	2014 (386)	2012 (368)
<2 wk	6% (25)	5% (18)
2–4 wk	30% (117)	28% (102)
1–2 mth	41% (160)	41% (152)
>2 mth	22% (84)	26% (96)

Note: 2012 includes the data from both present study and previous study (16).

Abbreviations: wk, week; mth, month.

Currently, there is no consensus among surgeons regarding the methods and theory of perioperative iodine use. In the present study, there were no drastic changes in the trends of perioperative antibiotic use, including intracameral antibiotic use. Considering that postoperative endophthalmitis is mostly caused by infection with bacteria brought into the eye from the surgical field,^{3,9} we believe that it is best to administer antibacterial agents soon after surgery or during surgery.

Fluoroquinolones were the most commonly used perioperative (preoperative, postoperative, and completion of surgery) eye drops. Although moxifloxacin, a representative fluoroquinolone, penetrates well into the anterior chamber, its concentration after use as an eye drop (1.8 µg/mL)¹⁸ and after subconjunctival injection (3.1 µg/mL)¹⁹ does not exceed the minimum inhibitory concentration required to inhibit a growth of 90% (MIC₉₀) for resistant pathogens such as *Pseudomonas aeruginosa* and methicillin-resistant *Staphylococcus aureus* (MRSA) (Table 8).

The antibiotic concentration in the anterior chamber 1 hour after ophthalmic ointment administration is only 219 ng/mL,²⁰ which is less than the MIC₉₀ for most pathogens. Therefore, the effects of antibacterial agents administered via commonly-used methods are limited. In contrast, there is no antibiotic resistance to iodine, which appears to be effective against pathogenic bacteria. On the other hand, intracameral

Table 8 Bacteria which cause endophthalmitis in Japan

Bacteria (moxifloxacin: MIC ₉₀ : µg/mL)	Onset:	Onset:
	0–29 days (cases)	after 1 month (cases)
<i>P. acnes</i> (0.25)	0	13
<i>S. epidermidis</i> (CNS >4)	28	4
<i>S. aureus</i> (MRSA >4)	18	0
<i>E. faecalis</i> (0.5)	22	0
<i>Streptococcus</i> sp. (0.5)	6	1
<i>P. aeruginosa</i> (>4)	4	0
Others	26	12
Total	104	30

Notes: The numbers shown in parenthesis are MIC₉₀ in each bacteria to moxifloxacin. *S. epidermidis* involves some cases of CNS. *S. aureus* contains 16 cases of MRSA. Copyright © 2003. Translated and adapted from Medical-Aoi Publications, Inc. Hara J. Relation between causative organism and inflammation in pseudophakic endophthalmitis following cataract surgery. *Journal of the Eye*. 2003;(20):657–660.²¹

Abbreviations: MIC₉₀, minimum inhibitory concentration, 90%; CNS, coagulase negative *Staphylococcus*; MRSA, methicillin-resistant *Staphylococcus aureus*.

antibiotics have the advantage of providing a sufficient antibiotic concentration during surgery, by themselves. Although intracameral antibiotics are gaining in popularity, as indicated by a comparison with 2012 data (1%; Table 4), they were used by only 7% of surgeons. Ophthalmologists in Japan still face several barriers, including the lack of commercially-available intracameral cefuroxime. Therefore, surgeons in Japan opt for off-label, broad-spectrum fluoroquinolones (Table 6), instead of cefuroxime, which is popular in Europe.

Fluoroquinolones are suitable choices as an intracameral agent because they are concentration-dependent drugs, as compared against time-dependent cefuroxime, and because the anterior chamber is characterized by rapid drug turnover.

Our study revealed that periocular and conjunctival iodine use at the initiation of surgery was common, whereas intraoperative iodine use, particularly with repeated applications, was used only at a few institutions. Although the early administration of prophylactic antibiotics has been recommended, they are typically initiated the day after surgery. Ointments and eye drops (and subconjunctival injection) are also common, but their penetration into the anterior chamber may be insufficient. Intracameral antibiotic use is increasing, although only a few surgeons are currently using this technique. The choice of antibiotic administration and disinfection has to be at the surgeon's discretion. However, we believe that the use of intracameral antibiotics and intraoperative iodine compounds should be widely recognized.

Disclosure

The authors report no conflicts of interest in this work.

References

- Koç F, Akçam Z, Kuruoğlu S, Oge I, Günaydin M. Does surgical technique influence cataract surgery contamination? *Eur J Ophthalmol*. 2001;11(1):31–36.
- Tervo T, Ljungberg P, Kautiainen T, et al. Prospective evaluation of external ocular microbial growth and aqueous humor contamination during cataract surgery. *J Cataract Refract Surg*. 1999;25(1):65–71.
- Speaker MG, Milch FA, Shah MK, Eisner W, Kreiswirth BN. Role of external bacterial flora in the pathogenesis of acute postoperative endophthalmitis. *Ophthalmology*. 1991;98(5):639–649; discussion 650.
- Ciulla TA, Starr MB, Masket S. Bacterial endophthalmitis prophylaxis for cataract surgery: an evidence-based update. *Ophthalmology*. 2002;109(1):13–24.
- Zamora JL. Chemical and microbiologic characteristics and toxicity of povidone-iodine solutions. *Am J Surg*. 1986;151(3):400–406.
- Inoue Y, Usui M, Ohashi Y, Shiota H, Yamazaki T; Preoperative Disinfection Study Group. Preoperative disinfection of the conjunctival sac with antibiotics and iodine compounds: a prospective randomized multicenter study. *Jpn J Ophthalmol*. 2008;52(3):151–161.
- Miño de Kaspar H, Chang RT, Singh K, Egbert PR, Blumenkranz MS, Ta CN. Prospective randomized comparison of 2 different methods of 5% povidone-iodine applications for anterior segment intraocular surgery. *Arch Ophthalmol*. 2005;123(2):161–165.
- Nentwich MM, Rajab M, Ta CN, et al. Application of 10% povidone iodine reduces conjunctival bacterial contamination rate in patients undergoing cataract surgery. *Eur J Ophthalmol*. 2012;22(4):541–546.
- Shimada H, Arai S, Nakashizuka H, Hattori T, Yuzawa M. Reduction of anterior chamber contamination rate after cataract surgery by intraoperative surface irrigation with 0.25% povidone-iodine. *Am J Ophthalmol*. 2011;151(1):11–17.e1.
- Endophthalmitis Study Group, European Society of Cataract and Refractive Surgeons. Prophylaxis of postoperative endophthalmitis following cataract surgery: results of the ESCRS multicenter study and identification of risk factors. *J Cataract Refract Surg*. 2007;33(6):978–988.
- Friling E, Lundström M, Stenevi U, Montan P. Six-year incidence of endophthalmitis after cataract surgery: Swedish national study. *J Cataract Refract Surg*. 2013;39(1):15–21.
- Kim SY, Park YH, Lee YC. Comparison of the effect of intracameral moxifloxacin, levofloxacin and cefazolin on rabbit corneal endothelial cells. *Clin Experiment Ophthalmol*. 2008;36(4):367–370.
- Espiritu CR, Caparas VL, Bolinao JG. Safety of prophylactic intracameral moxifloxacin 0.5% ophthalmic solution in cataract surgery patients. *J Cataract Refract Surg*. 2007;33(1):63–68.
- Lane SS, Osher RH, Masket S, Belani S. Evaluation of the safety of prophylactic intracameral moxifloxacin in cataract surgery. *J Cataract Refract Surg*. 2008;34(9):1451–1549.
- O'Brien TP, Arshinoff SA, Mah FS. Perspectives on antibiotics for postoperative endophthalmitis prophylaxis: potential role of moxifloxacin. *J Cataract Refract Surg*. 2007;33(10):1790–1800.
- Matsuura K, Suto C, Inoue Y, et al. A Japanese survey of perioperative antibiotic prophylaxis in cataract surgery. *Asia Pac J Ophthalmol*. 2012;1(5):283–286.
- Berkelman RL, Holland BW, Anderson RL. Increased bactericidal activity of dilute preparations of povidone-iodine solutions. *J Clin Microbiol*. 1982;15(4):635–639.
- Hariprasad SM, Blinder KJ, Shah GK, et al. Penetration pharmacokinetics of topically administered 0.5% moxifloxacin ophthalmic solution in human aqueous and vitreous. *Arch Ophthalmol*. 2005;123(1):39–44.
- Matsuura K. Pharmacokinetics of subconjunctival injection of moxifloxacin in humans. *Graefes Arch Clin Exp Ophthalmol*. 2013;251(3):1019–1020.
- Wada T, Kozai S, Tajika T, Sakaki H, Suzuki T, Ohashi Y. Prophylactic efficacy of ophthalmic quinolones in experimental endophthalmitis in rabbits. *J Ocul Pharmacol Ther*. 2008;24(3):278–289.
- Hara J. Relation between causative organism and inflammation in pseudophakic endophthalmitis following cataract surgery. *Journal of the Eye*. 2003;(20):657–660.

Clinical Ophthalmology

Dovepress

Publish your work in this journal

Clinical Ophthalmology is an international, peer-reviewed journal covering all subspecialties within ophthalmology. Key topics include: Optometry; Visual science; Pharmacology and drug therapy in eye diseases; Basic Sciences; Primary and Secondary eye care; Patient Safety and Quality of Care Improvements. This journal is indexed on

Submit your manuscript here: <http://www.dovepress.com/clinical-ophthalmology-journal>

PubMed Central and CAS, and is the official journal of The Society of Clinical Ophthalmology (SCO). The manuscript management system is completely online and includes a very quick and fair peer-review system, which is all easy to use. Visit <http://www.dovepress.com/testimonials.php> to read real quotes from published authors.