

# Twisting Lipoma Presenting as Appendicitis-A Rare Presentation

BASAVAPATNA RAMAKRISHNAIAH SATHYAKRISHNA<sup>1</sup>, SURYANARAYAN GIRIDHAR BOGGARAM<sup>2</sup>, NAGAMALLESWARA RAO JANNU<sup>3</sup>

## ABSTRACT

Right iliac fossa (RIF) pain is the most common presenting complaint in the general surgical ward. Though there are several causes for the RIF pain, acute appendicitis is the first and common diagnosis. Here we present one of the rare differential diagnoses of RIF pain in a young female patient with one month history of intermittent right lower abdominal pain. Patient's symptoms and clinical findings indicated acute appendicitis, though ultrasonography didn't show any significant abnormality. Through diagnostic laparoscopy we found that there was torsion of anterior abdominal wall parietal peritoneal pedunculated lipoma located in RIF region. The clinical presentation, examination, investigation, laparoscopic findings and further management is presented in this case report.

**Keywords:** Diagnostic laparoscopy, Pedunculated lipoma, Right iliac fossa (RIF) pain, Torsion

## CASE REPORT

A 21-year-old female presented to us with one month history of intermittent right lower abdominal pain, which intensified since a day prior to visiting the clinic; pain was not aggravated by movements or on coughing. The patient did not have vomiting, fever, anorexia, or bowel and bladder disturbances. Her menstrual, medical & surgical histories were not significant. On examination, she had tachycardia, and was normotensive and afebrile with BMI of 21.5. She had right iliac fossa tenderness with rebound tenderness. The rest of the examination was unremarkable. Routine investigations showed a normal white cell count, Urine analysis was normal, USG abdomen and pelvis showed no abnormality. With the differential diagnoses of appendicitis, ovarian pathology, or renal colic, she was commenced on conservative management. She did not respond to conservative treatment hence was taken up for diagnostic laparoscopy. Upon entering the peritoneal cavity, we observed that the appendix, uterus, fallopian tubes, and ovaries were macroscopically normal. On further examination, in the right lower quadrant of the anterior abdominal wall, a tormented pedunculated lipoma [Table/Fig-1a] with congestion [Table/Fig-1b] was seen, located in the area corresponding to McBurney's point on the outside. Lipoma was resected laparoscopically. The patient was discharged postoperative day-one. Histopathological examination of the lipoma revealed an infarcted lipoma. Post-surgery, there were no further episodes of abdominal pain.

## DISCUSSION

Acute abdominal pain is the most common presenting complaint in the general surgical ward [1]. It can represent a spectrum of conditions

from benign and self-limited disease to surgical emergencies. Right iliac fossa (RIF) pain is a classical sign of acute appendicitis which constitutes about 30% of the cases. Routine parameters observed during collecting history and physical examination could strongly suggest bowel obstruction. But we need to bear in mind the other differential diagnosis of RIF pain which include mesenteric adenitis, diverticulitis, ureteric colic, Meckel's diverticulitis, Crohn's disease, leaking duodenal ulcer, biliary disease, and epiploic appendicitis. In women, endometriosis, pelvic inflammatory disease, salpingitis, ectopic pregnancy and ovarian pathology also need to be ruled-out [2,3]. There is one case reported where the torsion of the anterior abdominal-wall lipoma was the cause of the RIF pain that mimicked appendicitis [2]. Lipoma is a benign neoplasm of mesenchymal origin commonly occurring in subcutaneous tissue. They are found mostly on the trunk but may appear anywhere in the body and are asymptomatic [2]. Intra-abdominal lipomas can occur in gastrointestinal tract, omentum, mesentery and appendices epiploicae. Lipomas arising from the parietal peritoneum are rare, and generally an incidental finding during laparoscopic surgeries [4,5]. Anterior abdominal wall parietal peritoneal lipomas presenting as abdominal pain is a rare entity, only two such cases were reported till date in literature [2,4] of which one case mimicked acute appendicitis reported by John Bunker et al.

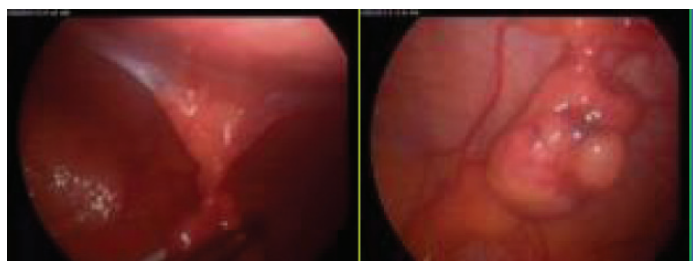
The reason for pain is the torsion of lipoma around its pedicle. On ultrasound they appear as iso- to hyper echoic texture (when compared to the adjacent muscles), surrounded by a thin, echogenic capsule [6]. Microscopically lipoma is a lobulated tumor containing normal fat cells. Simple excision is the treatment of choice [2].

## CONCLUSION

In conclusion, as observed in this patient, the torsion of anterior abdominal wall parietal peritoneal lipoma need also to be considered as one of the rare differential diagnosis for RIF pain and acute appendicitis.

## ACKNOWLEDGEMENTS

The authors acknowledge the expert advice provided by Dr. Maneesh Paul-Satyaseela, Chief Scientific Officer, St. Martha's Hospital, in developing the manuscript.



**[Table/Fig-1]:** Intra-operative image of the anterior abdominal wall pedunculated lipoma showing the twisted pedicle of the lipoma (1a) and tormented lipoma with congestion (1b)

## REFERENCES

- [1] Rennie AT, Tytherleigh MG, Theodoropolou K, Farouk R. A Prospective Audit of 300 Consecutive Young Women with an Acute Presentation of Right Iliac Fossa Pain. *Ann R Coll Surg Engl.* 2006;88(2):140-43.
- [2] Bunker DL, Ilie VG, Halder TK. Torsion of an Abdominal-Wall Pedunculated Lipoma: A Rare Differential Diagnosis for Right Iliac Fossa Pain. *Case Rep Surg.* 2013;2013:587380.3 doi: 10.1155/2013/587380.
- [3] Birnbaum BA, Wilson SR. Appendicitis at the millennium. *Radiology.* 2000;215(2):337-48.
- [4] Barut I, Tarhan OR, Cerci C, Ciris M, Tasliyar E. Lipoma of the parietal peritoneum: an unusual cause of abdominal pain. *Ann Saudi Med.* 2006;26(5):388-90.
- [5] Weiss W and Goldblum JR. *Soft Tissue Tumours. 5th. Ed.* Mosby 2007.
- [6] Truong S, Pflingsten FP, Dreuw B, Schumpelick V. Value of sonography in diagnosis of uncertain lesions of the abdominal wall and inguinal region. *Chirurg.* 1993;64(6):468-75.

### PARTICULARS OF CONTRIBUTORS:

1. Senior Consultant & Unit Chief, Department of Surgery, St Martha's Hospital, Bangalore, India.
2. Senior Consultant & HOD, Department of Surgery, St Martha's Hospital, Bangalore, India.
3. Resident, Department of General Surgery, Department of Surgery, St Martha's Hospital, Bangalore, India.

### NAME, ADDRESS, E-MAIL ID OF THE CORRESPONDING AUTHOR:

Dr. Basavapatna Ramakrishnaiah Sathyakrishan,  
St. Martha's Hospital, Surgery, No. 5, Nrupatunga Road, Bangalore – 560 001, Karnataka, India.  
Phone : 09845006775, E-mail : cso@stmarthashospital.org, dr.brsk@gmail.com

Date of Submission: **Apr 16, 2014**

Date of Peer Review: **Jun 12, 2014**

Date of Acceptance: **Jul 16, 2014**

Date of Publishing: **Aug 20, 2014**

**FINANCIAL OR OTHER COMPETING INTERESTS:** None.