

Bilateral hemiballism-hemichorea presenting in a diabetes Taiwanese woman

Chih Ming Lin,¹ Chi-Kuang Liu²

¹Department of Neurology, Stroke Center,
²Department of Neuro-imaging,
Chunghua Christian Hospital Chunghua,
Taiwan

Abstract

Hemiballism-hemichorea (HB-HC) is a hyperkinetic disorder characterized by continuous involuntary movements of the extremities. It could be associated with non-insulin dependent diabetes mellitus. A very few cases of bilateral HB-HC have been reported until today. We describe here the case of a Taiwanese woman (85 years old) presenting with bilateral HB-HC and diabetes mellitus.

Introduction

Hemiballism-hemichorea (HB-HC) is characterized by the continuous and involuntary movements of both the distal and proximal part of the extremities.^{1,2} Most of cases are associated with diabetes mellitus with poor control and presented in the elderly women.^{2,5} Typical brain magnetic resonance imaging (MRI) presentation shows unilateral hyper-intensity signal over the striatum region, contra-lateral to the symptom side. Nonetheless, bilateral HB-HC is seldom reported. Here, we report a case of bilateral HB-HC associated with diabetes mellitus. Brain MRI are also carefully evaluated.

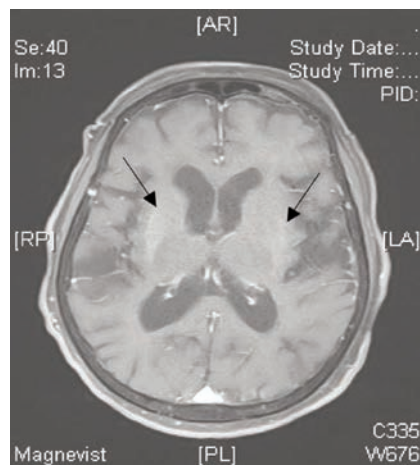


Figure 1. Gadolinium-enhanced brain magnetic resonance imaging shows hyperintensity signal over bilateral putamen regions in T1 weighted imaging.

Case Report

A 85-year-old Taiwanese woman with poor controlled non-insulin dependent diabetes mellitus (NIDDM) noted four limbs involuntary movements one week prior to medical attention. She was consciousness, clear and oriented to person, place and time. A neurological consultation was made and it revealed she had bilateral HB-HC (first with left sided extremities, which was then ensued with right sided extremities). After admission, contrasted cerebral MRI was performed; it showed the evidence of T1 weighted imaging with hyperintensity signal in bilateral putamen regions (Figure 1). The routine laboratory work-up showed that her fasting blood sugar was up to 500 mg/dL and hemoglobin A_{1C} was 16.2%. During the two-week hospitalization, hyperglycemia was corrected with aggressive insulin therapy. In addition, she was treated with haloperidol 1 mg twice a day. Her bilateral HB-HC was greatly subsided. After she discharged from the ward, her bilateral HB-HC remained silent. The second MRI was taken four months after her initial involuntary episode and showed complete resolution of the previously-reported brain lesions.

Discussion and Conclusions

We report the case of a patient with initial HB-HC over the left side extremities. The right sided extremities ensued the same phenomena three days later. The symmetrical focal abnormalities over bilateral striatum of her brain MRI taken during the hospitalization correspond to her clinical manifestations.

The clinical symptom could be alleviated with intensive correction of hyperglycemia state and administration of low doses of haloperidol.^{1,4} The follow-up brain MRI, which showed intact cerebral parenchyma, also echoes the satisfactory treatment. On literature review, the likely etiologies of HB-HC cases vary. However, most of reported cases are associated with poor controlled type 2 diabetes mellitus in either hypoglycemic or hyperglycemic state as the initial manifestation.^{6,7} The other etiologies are ischemic change contra-lateral to the lesion side, infection,^{1,4,5} or tumor metastasis.³ It is speculated by some scholars inflammation process plays a pivotal role in this malady owing to increased level of IgG in cerebrospinal fluid examination.² However, the definite cause of HB-HC is still uncertain and required advanced studies.

In addition, most of the involuntary movement occurs unilaterally. Few cases have been documented with bilateral HB-HC, and whose efficacy of treatment and neuro-imaging studies are compatible with one another.

Correspondence: Chih Ming Lin, Department of Neurology, Stroke Center, Changhua Christian Hospital, No. 135, Nanhsiao Street, 500 Changhua, Taiwan.
Tel. +88.647.238.595.4131.
E-mail: 166110@cch.org.tw

Key words: hemiballism-hemichorea, diabetes mellitus, Taiwan.

Contributions: the authors contributed equally.

Conflict of interests: the authors declare no potential conflict of interests.

Received for publication: 16 June 2014.

Revision received: 30 June 2014.

Accepted for publication: 7 July 2014.

This work is licensed under a Creative Commons Attribution NonCommercial 3.0 License (CC BY-NC 3.0).

©Copyright C.M. Lin and C.-K. Liu, 2014
Licensee PAGEPress, Italy
Neurology International 2014; 6:5519
doi:10.4081/ni.2014.5519

References

- Mugundhan K, Maski A, Elanchezian JA, et al. Mixed movement disorder as the presenting manifestation of non-ketotic hyperglycemia. *J Assoc Physicians India* 2010;58:387-8.
- Wang JH, Wu T, Deng BQ, et al. Hemichorea-hemiballismus associated with nonketotic hyperglycemia: a possible role of inflammation. *J Neurol Sci* 2009;284:198-202.
- Moore FG. Bilateral hemichorea-hemiballism caused by metastatic lung cancer. *Mov Disord* 2009;24:1405-6.
- Ohmori H, Hirashima K, Ishihara D, et al. Two cases of hemiballism-hemichorea with T1-weighted MR image hyperintensities. *Intern Med* 2005;44:1280-5.
- Oh SH, Lee KY, Im JH, Lee MS. Chorea associated with non-ketotic hyperglycemia and hyperintensity basal ganglia lesion on T1-weighted brain MRI study: a meta-analysis of 53 cases including four present cases. *J Neurol Sci* 2002;200:57-62.
- Guerrero WR, Okun MS, McFarland NR. Encephalopathy, hypoglycemia, and flailing extremities: a case of bilateral chorea-ballism associated with diabetic ketoacidosis. *Tremor Other Hyperkinet Mov (NY)* 2012;2:pii:tre-02-58-235-1.
- Ogawa K, Suzuki Y, Kamei S, Mizutani T. Choreic involuntary movement that occurred during therapy for diabetes mellitus. *Nihon Ronen Igakkai Zasshi* 2008;45:225-30. [Article in Japanese].