



CASE REPORT

# Case Report: Group B *Streptococcus* meningitis in an adolescent [v1; ref status: indexed, <http://f1000r.es/3u4>]

Roselle Vittorino<sup>1</sup>, Joyce Hui-Yuen<sup>2</sup>, Adam J. Ratner<sup>3</sup>, Amy Starr<sup>2</sup>, Teresa McCann<sup>1</sup>

<sup>1</sup>Division of Child and Adolescent Health, Department of Pediatrics, Columbia University Medical Center, New York, NY, 10032, USA

<sup>2</sup>Division of Pediatric Rheumatology, Department of Pediatrics, Columbia University Medical Center, New York, NY, 10032, USA

<sup>3</sup>Division of Pediatric Infectious Diseases, Department of Pediatrics, Columbia University Medical Center, New York, NY, 10032, USA

**v1** First published: 22 Jul 2014, 3:167 (doi: [10.12688/f1000research.4651.1](https://doi.org/10.12688/f1000research.4651.1))  
 Latest published: 22 Jul 2014, 3:167 (doi: [10.12688/f1000research.4651.1](https://doi.org/10.12688/f1000research.4651.1))

**Abstract**

*Streptococcus agalactiae* (group B *Streptococcus*, GBS) usually colonizes the gastrointestinal and lower genital tracts of asymptomatic hosts, yet the incidence of invasive disease is on the rise. We describe a case of an 18 year old woman, recently diagnosed with lupus, who reported a spontaneous abortion six weeks prior to her hospitalization. She presented with fever, altered mental status, and meningeal signs, paired with a positive blood culture for GBS. Magnetic resonance imaging of her brain demonstrated an extra-axial fluid collection, and she was diagnosed with meningitis. She received prolonged intravenous antibiotic therapy and aggressive treatment for lupus, leading to clinical recovery. This case illustrates the importance of recognizing GBS as a potential pathogen in all patients presenting with CNS infection.

**Open Peer Review**

Referee Status:

	Invited Referees	
	1	2
<b>version 1</b> published 22 Jul 2014	 report	 report
<b>1</b>	Theresa Lu, Weill Cornell Medical Center USA	
<b>2</b>	Rebecca Madan, Yeshiva University USA	

**Discuss this article**

Comments (0)

**Corresponding author:** Teresa McCann ([tm501@cumc.columbia.edu](mailto:tm501@cumc.columbia.edu))

**How to cite this article:** Vittorino R, Hui-Yuen J, Ratner AJ *et al.* Case Report: Group B *Streptococcus* meningitis in an adolescent [v1; ref status: indexed, <http://f1000r.es/3u4>] *F1000Research* 2014, 3:167 (doi: [10.12688/f1000research.4651.1](https://doi.org/10.12688/f1000research.4651.1))

**Copyright:** © 2014 Vittorino R *et al.* This is an open access article distributed under the terms of the [Creative Commons Attribution Licence](#), which permits unrestricted use, distribution, and reproduction in any medium, provided the original work is properly cited. Data associated with the article are available under the terms of the [Creative Commons Zero "No rights reserved" data waiver](#) (CC0 1.0 Public domain dedication).

**Grant information:** The author(s) declared that no grants were involved in supporting this work.

**Competing interests:** No competing interests were disclosed.

**First published:** 22 Jul 2014, 3:167 (doi: [10.12688/f1000research.4651.1](https://doi.org/10.12688/f1000research.4651.1))

**First indexed:** 10 Oct 2014, 3:167 (doi: [10.12688/f1000research.4651.1](https://doi.org/10.12688/f1000research.4651.1))

## Introduction

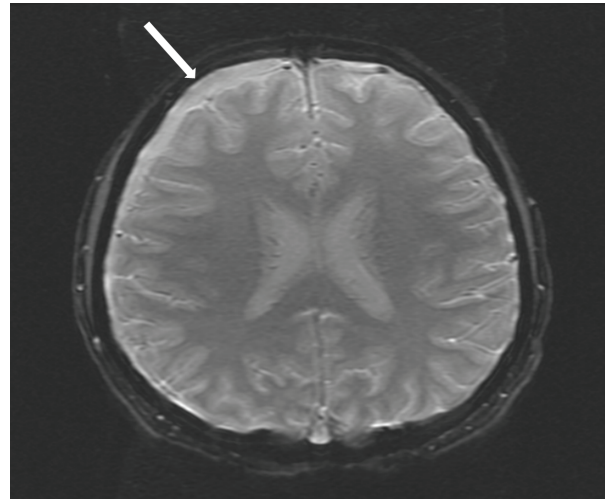
In this case report we describe an interesting and unique patient with group B Streptococcus (GBS) meningitis following a spontaneous abortion without instrumentation. Although our patient was recently diagnosed with systemic lupus erythematosus (SLE), this chronic disease has not been shown to increase the chances of developing invasive GBS infection<sup>1</sup>. Although GBS can cause severe infections outside of the neonatal period, it rarely manifests as meningitis, accounting for less than 2% of all cases of invasive GBS in the United States and Spain<sup>2,3</sup>. There have been only two reported cases of GBS meningitis following elective termination with cervical dilatation and uterine evacuation, both presenting to a hospital in Detroit, Michigan<sup>4,5</sup> and none to date following spontaneous abortion.

## Case report

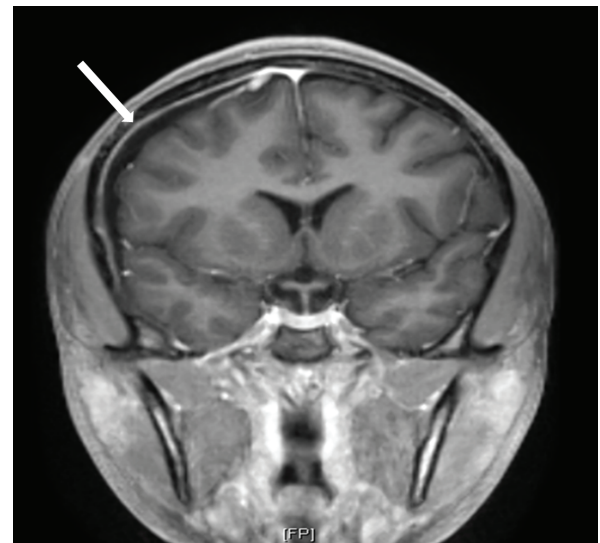
In October, 2013, an 18-year-old African American young woman diagnosed in August of that year with SLE presented to a community hospital complaining of headache, neck and back pain for five days, and vomiting with non-bloody diarrhea for one day. Additionally, she reported right-sided weakness. Six weeks prior to this presentation, she met the criteria for a diagnosis of SLE with arthritis, a photosensitive malar rash, and serum serology positivity for anti-nuclear antibodies (1:5120) as well as anti-double stranded DNA and anti-ribonuclear protein antibodies. A regimen of oral prednisone (10 mg twice daily) and hydroxychloroquine (200 mg twice daily) was begun. In the weeks subsequent to the diagnosis and treatment of SLE, and prior to her hospitalization, the patient had a positive home pregnancy test, which was followed by an unusually heavy menstrual cycle and presumed spontaneous abortion. The patient did not seek medical attention, and therefore no uterine manipulation or evacuation was performed. The patient's family history is significant for a maternal aunt and paternal cousin with SLE, and a maternal great-uncle who died from Libman-Sacks endocarditis.

At the time of the acute presentation, she was febrile to 38.9°C, oriented to self only, and had positive Kernig and Brudzinski signs. A computed tomography scan of the head revealed an extra-axial fluid collection in the right frontotemporal region, with a mild local mass effect, but no midline shift and normal ventricles. Intravenous vancomycin and ceftriaxone were initiated and the patient was transferred to our institution.

On arrival to our pediatric intensive care unit, the patient's temperature was 38.8°C, blood pressure was 145/76 mmHg, heart rate was 70 beats per minute, respiratory rate was 22 breaths per minute, and oxygen saturation was 100% on room air. She was drowsy and irritable when aroused, complaining of continued severe headache and neck pain. Neurological exam was significant for photophobia and meningismus. The remainder of the neurological exam and the ocular exam were normal. Analysis of the cerebrospinal fluid (CSF) revealed 1525 white blood cells/ $\mu$ L (91% neutrophils), 65 red blood cells/ $\mu$ L, 252 mg/dL protein, and 56 mg/dL glucose. An MRI of the brain with and without contrast revealed a moderately sized extra-axial effusion with secondary inflammatory response (Figure 1 and Figure 2) and punctate diffusion abnormalities within the dependent



**Figure 1.** Axial susceptibility weighted image of MRI brain with an arrow indicating the extra-axial collection in right frontotemporal region.



**Figure 2.** Coronal view of MRI brain post-contrast showing extra-axial collection with the arrow indicating dural enhancement.

portion of the lateral ventricles, consistent with pus or debris. The CSF culture was negative for bacteria, likely secondary to receipt of antibiotics prior to sampling, but the blood culture prior to antibiotic receipt grew GBS. Antibiotic susceptibility testing was not performed. CSF studies for other pathogens, including cryptococcal antigen, detection of herpes simplex and varicella viruses by PCR, and specific cultures for acid-fast bacilli and fungi, were negative. Upon identification of GBS, vancomycin and ceftriaxone were discontinued, and treatment was continued with intravenous penicillin G (4,000,000 units every 4 hours) for two weeks. The patient showed rapid improvement on antibiotic therapy and had

resolution of all neurologic symptoms within one week of admission. She was discharged to receive intravenous ceftriaxone for one additional week at home.

Notably, the patient's SLE was severely active during the course of this acute illness. Initial laboratory results at our institution demonstrated anti-Smith, anti-Ro and anti-La antibodies. She also had severe hypocomplementemia, doubling of serum creatinine, and nephrotic range proteinuria as assessed by 24-hour urine collection. Subsequent kidney biopsy demonstrated class V lupus nephritis. Induction therapy with intravenous methylprednisolone was started, which was then changed to oral prednisone (30 mg twice daily), mycophenolate mofetil (1000 mg twice daily), and hydroxychloroquine (400 mg once daily). Her serologically active SLE began to improve after her course of methylprednisolone, but was still active at the time of discharge.

## Discussion

GBS is an encapsulated bacterium that produces a narrow zone of hemolysis on sheep blood agar. Strains are classified into one of 10 serotypes determined by the organism's polysaccharide capsule. GBS colonizes the gastrointestinal tract, vagina, and urethra of asymptomatic hosts, but can cause invasive disease in infants, pregnant or post-partum women, individuals with underlying medical conditions and the elderly<sup>6-9</sup>.

GBS emerged as the leading cause of neonatal sepsis in the 1970s in the US<sup>10</sup>. While the rates of early-onset invasive GBS infection among neonates have declined due to widespread use of intrapartum antibiotic prophylaxis in the United States, GBS continues to affect an estimated 1200 infants per year<sup>9</sup>. Pregnancy and the post-partum state are characterized by an altered immune response that allows GBS to cause invasive disease<sup>11</sup>. A 6-year epidemiologic study done in the US found that half of all invasive GBS infections seen in pregnant women were associated with infection of the upper genital tract, placenta, and amniotic sac, leading to fetal demise<sup>12</sup>. Other commonly reported manifestations included bacteremia (31%) and endometritis without fetal death (8%). Deutscher *et al.* reported that a greater proportion of cases of invasive GBS disease occurred in the post-partum period (14% vs. 10% in pregnant women), and pregnant women had a 2-fold increase incidence of GBS disease compared to non-pregnant women<sup>11</sup>.

As the rate of neonatal GBS infection has declined, the majority of cases now occur in the adult population, manifesting as skin or soft tissue infection, bacteremia, pneumonia, osteomyelitis and septic arthritis<sup>2,3,6,7,12</sup>. Several studies have shown increasing rates of invasive GBS infection in all adult age groups, but particularly vulnerable populations are those with medical co-morbidities and the elderly. Of those with underlying medical conditions, 41% have diabetes mellitus, 36% cardiovascular disease, and 17% malignancy<sup>12</sup>. Interestingly, immunosuppressed individuals comprise less than 10% of all at risk groups<sup>2,3</sup>.

GBS meningitis is a rare occurrence, accounting for <2% of all cases of invasive GBS infection in the US and Spain<sup>2,3</sup>. In fact, one of the largest initial reviews of GBS meningitis in the adult population identified only 12 cases over a 15 year period, and found

72 cases in the literature overall. The majority of those cases were associated with underlying medical conditions and the risk of contracting GBS meningitis was greater with increasing age, with 58% of cases found in individuals >50 years old<sup>13</sup>. Although pregnant women have a 2-fold increased incidence of GBS disease compared to non-pregnant women, meningitis caused by GBS remains rare in this population<sup>14-18</sup>.

Infection of the central nervous system (CNS) is uncommon among patients with SLE, and relevant symptoms may resemble neuropsychiatric lupus flare, making diagnosis difficult<sup>1</sup>. There does not appear to be a temporal association between contraction of CNS infection and diagnosis of SLE<sup>19</sup>, but CNS infection does account for a significant amount of mortality in patients with SLE<sup>20</sup>. To date, the largest cohort of SLE patients with CNS infections is a group of 38 patients, none of whom had GBS, collected over a 10-year period<sup>19</sup>. In a large retrospective review of Korean patients with SLE, only 1.4% had meningitis, with the leading causative organism being *Cryptococcus neoformans*<sup>21</sup>. A recent study characterizing the major infections seen in juvenile onset SLE found meningitis to be a rare entity. Only one case was identified out of 101 major infections, with the causative agent being *Streptococcus pneumoniae*<sup>22</sup>. Only three other cases of GBS meningitis in patients with SLE have been reported<sup>3,23</sup>.

To our knowledge, this patient represents the only reported case of GBS meningitis following a spontaneous abortion without instrumentation of the uterus. The two previously reported cases of GBS meningitis followed elective abortion with cervical dilatation and uterine evacuation<sup>4,5</sup>. Although these women became symptomatic within two weeks of their procedure, a recent study of expectant versus surgical management of first-trimester miscarriage showed that 18.6% of women in the expectant management group had evidence of retained products of conception after four weeks<sup>24</sup>. Therefore it is possible that our patient remained at risk for invasive infection longer than would otherwise be expected.

This case illustrates the importance of recognizing GBS as a potential pathogen in all patients presenting with CNS infection. It also highlights the value of obtaining a thorough obstetrical history in all reproductive-aged females, even in the setting of acute illness.

## Consent

Written informed consent for publication of the patient's clinical details and images was obtained from the patient.

## Author contributions

RV, JH, and TM equally contributed to the writing and editing of this manuscript. Additional editing and expert content was provided by AS and AR.

## Competing interests

No competing interests were disclosed.

## Grant information

The author(s) declared that no grants were involved in supporting this work.

## References

1. Yang CD, Wang XD, Ye S, *et al.*: **Clinical features, prognostic and risk factors of central nervous system infections in patients with systemic lupus erythematosus.** *Clin Rheumatol.* 2007; **26**(6): 895–901.  
[PubMed Abstract](#) | [Publisher Full Text](#)
2. Blancas D, Santin M, Olmo M, *et al.*: **Group B streptococcal disease in nonpregnant adults: incidence, clinical characteristics, and outcome.** *Eur J Clin Microbiol Infect Dis.* 2004; **23**(3): 168–173.  
[PubMed Abstract](#) | [Publisher Full Text](#)
3. Skoff TH, Farley MM, Petit S, *et al.*: **Increasing burden of invasive group B streptococcal disease in nonpregnant adults, 1990–2007.** *Clin Infect Dis.* 2009; **49**(1): 85–92.  
[PubMed Abstract](#) | [Publisher Full Text](#)
4. Deziel PJ, McGuire N, Brown PD: **Group B streptococcal meningitis complicating elective abortion: report of 2 cases.** *Clin Infect Dis.* 2000; **31**(5): E23–E25.  
[PubMed Abstract](#) | [Publisher Full Text](#)
5. Walker MA, McNeeley SG: **Group B streptococcus meningitis following elective termination of pregnancy: two case reports.** *Infect Dis Obstet Gynecol.* 1995; **2**(6): 275–278.  
[PubMed Abstract](#) | [Publisher Full Text](#) | [Free Full Text](#)
6. Farley MM: **Group B streptococcal disease in nonpregnant adults.** *Clin Infect Dis.* 2001; **33**(4): 556–561.  
[PubMed Abstract](#) | [Publisher Full Text](#)
7. Le Doare K, Heath PT: **An overview of global GBS epidemiology.** *Vaccine.* 2013; **31**(Suppl 4): D7–D12.  
[PubMed Abstract](#) | [Publisher Full Text](#)
8. Ohlsson A, Shah VS: **Intrapartum antibiotics for known maternal group B streptococcal colonization.** *Cochrane Database Syst Rev.* 2013; **1**: CD007467; 1–38.  
[PubMed Abstract](#) | [Publisher Full Text](#)
9. Verani JR, McGee L, Schrag SJ: **Prevention of perinatal group B streptococcal disease—revised guidelines from CDC, 2010.** *MMWR Recomm Rep.* 2010; **59**(RR-10): 1–36.  
[PubMed Abstract](#)
10. Franciosi RA, Knostman JD, Zimmerman RA: **Group B streptococcal neonatal and infant infections.** *J Pediatr.* 1973; **82**(4): 707–18.  
[PubMed Abstract](#) | [Publisher Full Text](#)
11. Deutscher M, Lewis M, Zell ER, *et al.*: **Incidence and severity of invasive *Streptococcus pneumoniae*, group A *Streptococcus*, and group B *Streptococcus* infections among pregnant and postpartum women.** *Clin Infect Dis.* 2011; **53**(2): 114–123.  
[PubMed Abstract](#) | [Publisher Full Text](#)
12. Phares CR, Lynfield R, Farley MM, *et al.*: **Epidemiology of invasive group B streptococcal disease in the United States, 1999–2005.** *JAMA.* 2008; **299**(17): 2056–2065.  
[PubMed Abstract](#) | [Publisher Full Text](#)
13. Domingo P, Barquet N, Alvarez M, *et al.*: **Group B streptococcal meningitis in adults: report of twelve cases and review.** *Clin Infect Dis.* 1997; **25**(5): 1180–1187.  
[PubMed Abstract](#) | [Publisher Full Text](#)
14. Ghani NA, Jaafar R, Ishak S, *et al.*: **Mother with post-partum group B *Streptococcus* meningitis and cerebellar abscess.** *J Obstet Gynaecol Res.* 2007; **33**(2): 195–198.  
[PubMed Abstract](#) | [Publisher Full Text](#)
15. Grossman J, Tompkins RL: **Group B beta-hemolytic streptococcal meningitis in mother and infant.** *N Engl J Med.* 1974; **290**(7): 387–388.  
[PubMed Abstract](#) | [Publisher Full Text](#)
16. Guerin JM, Leibinger F, Mofredi A, *et al.*: **Streptococcus B meningitis in post-partum.** *J Infect.* 1997; **34**(2): 151–153.  
[PubMed Abstract](#) | [Publisher Full Text](#)
17. Ravindranth NT, O'Driscoll J: **Maternal group B streptococcal meningitis in the postpartum period.** *J Obstet Gynaecol.* 2003; **23**(1): 79.  
[PubMed Abstract](#)
18. Wolfe RR Jr, Norwick ML, Bofill JA: **Fatal maternal beta-hemolytic group B streptococcal meningitis: a case report.** *Am J Perinatol.* 1998; **15**(11): 597–600.  
[PubMed Abstract](#) | [Publisher Full Text](#)
19. Benseler SM, Silverman ED: **Neuropsychiatric involvement in pediatric systemic lupus erythematosus.** *Lupus.* 2007; **16**(8): 564–71.  
[PubMed Abstract](#) | [Publisher Full Text](#)
20. Zonana-Nacach A, Yañez P, Jiménez-Balderas FJ, *et al.*: **Disease activity, damage and survival in Mexican patients with acute severe systemic lupus erythematosus.** *Lupus.* 2007; **16**(12): 997–1000.  
[PubMed Abstract](#) | [Publisher Full Text](#)
21. Kim JM, Kim KJ, Yoon HS, *et al.*: **Meningitis in Korean patients with systemic lupus erythematosus: analysis of demographics, clinical features and outcomes; experience from affiliated hospitals of the Catholic University of Korea.** *Lupus.* 2011; **20**(5): 531–536.  
[PubMed Abstract](#) | [Publisher Full Text](#)
22. Costa-Reis P, Nativ S, Isgro J, *et al.*: **Major infections in a cohort of 120 patients with juvenile-onset systemic lupus erythematosus.** *Clin Immunol.* 2013; **149**(3): 442–449.  
[PubMed Abstract](#) | [Publisher Full Text](#)
23. Kim BS, Kim SH, Kim SJ, *et al.*: **An unusual complication of systemic lupus erythematosus: bacterial meningitis caused by *Streptococcus agalactiae*.** *J Eur Acad Dermatol Venereol.* 2007; **21**(9): 1274–1275.  
[PubMed Abstract](#) | [Publisher Full Text](#)
24. Al-Ma'ani W, Solomayer EF, Hammadeh M: **Expectant versus surgical management of first-trimester miscarriage: a randomised controlled study.** *Arch Gynecol Obstet.* 2014; **289**(5): 1011–1015.  
[PubMed Abstract](#) | [Publisher Full Text](#)

# Open Peer Review

Current Referee Status:



Version 1

Referee Report 10 October 2014

doi:10.5256/f1000research.4972.r5871



**Rebecca Madan**

Department of Pediatrics, Yeshiva University, Bronx, USA

This case report reviews an unusual and thought-provoking case of Group B Streptococcus meningitis in a young woman who had a recent history of both spontaneous abortion and newly diagnosed SLE. Of note, she received relatively low-dose immunosuppression prior to developing meningitis, and the authors indicate that SLE participants are typically not thought to be at higher risk for bacterial meningitis. This case report is highly relevant in that it illustrates the imperative to 1) exclude infection in the setting of altered mental status in SLE patients and 2) to investigate for potential sources of infection (recent pregnancy) in a patient with an invasive bacterial infection that is not typical of their age group.

The authors imply in their Discussion that this case of GBS meningitis was more likely to be related to the patient's recent history of spontaneous abortion and was less likely related to her recently diagnosed SLE. They cite a significant prevalence of endometritis (8%) in women who develop invasive GBS with pregnancy. Did the patient have evidence of endometritis on exam or imaging? Did she undergo pelvic imaging to assess for retained products of conception (or undisclosed foreign body) that could provide an ongoing source of infection?

The most interesting aspect of this case is this patient's significant SLE flare in the setting of GBS meningitis. The authors report that she had serologic evidence of SLE flare, hypocomplementemia, and a new diagnosis of class V lupus nephritis concomitant with her GBS diagnosis. This presents an interesting finding to expand upon in the Discussion. Although bacterial meningitis is unusual in the setting of SLE, is it possible that this young woman developed a severe flare prior to meningitis, and that the subsequent immune dysfunction predisposed her to invasive GBS? Or do the authors postulate that immune dysfunction in the setting of bacterial sepsis resulted in the SLE flare? What are the possible mechanisms that could underly a relationship between these two conditions? A brief discussion of the patient's SLE flare would contribute significantly to this manuscript.

**I have read this submission. I believe that I have an appropriate level of expertise to confirm that it is of an acceptable scientific standard.**

**Competing Interests:** No competing interests were disclosed.

Referee Report 04 August 2014

doi:10.5256/f1000research.4972.r5546

**Theresa Lu**

Department of Microbiology and Immunology, Weill Cornell Medical Center, New York, NY, USA

This is a well-written case report about a newly diagnosed lupus patient who develops GBS meningitis after a spontaneous abortion. Most of the salient details are included and there is an informative review of the literature on GBS infections, autoimmune disease, and spontaneous abortions. This is a useful documentation of an unusual case that can be helpful when considering the differential diagnosis of meningitis in a patient with lupus, other autoimmune disorders, or spontaneous abortion.

One presumes that the patient was in her first trimester, but confirmation of that in the description of the patient would be helpful to be complete.

**I have read this submission. I believe that I have an appropriate level of expertise to confirm that it is of an acceptable scientific standard.**

***Competing Interests:*** No competing interests were disclosed.

---