

- 3 Awad H, Santilli S, Ohr M, Roth A, Yan W, Fernandez S *et al.* The effects of steep trendelenburg positioning on intraocular pressure during robotic radical prostatectomy. *Anesth Analg* 2009; **109**(2): 473–478.
- 4 Molloy BL. Implications for postoperative visual loss: steep trendelenburg position and effects on intraocular pressure. *AANA J* 2011; **79**(2): 115–121.
- 5 Martin JT. The Trendelenburg position: a review of current slants about head down tilt. *AANA J* 1995; **63**(1): 29–36.

AR Afshar¹, P Pongsachareonnont¹, SW Siegner²
and JM Stewart¹

¹Department of Ophthalmology, University of California, San Francisco, San Francisco, CA, USA

²Department of Ophthalmology, Permanente Medical Group, Santa Rosa, CA, USA
E-mail: StewartJ@vision.ucsf.edu

Eye (2014) **28**, 1261–1263; doi:10.1038/eye.2014.171;
published online 18 July 2014

Sir, Intra-orbital gas following sutureless small-gauge (23-gauge) vitrectomy masquerading as orbital cellulitis

Small-gauge sutureless vitrectomy using 23-gauge, 25-gauge or 27-gauge valved self-sealing sclerostomies is now routinely performed for numerous vitreo-retinal surgical procedures. We describe a case where the gas used for postoperative tamponade escaped from the globe through the sutureless 23-gauge valve sclerostomy ports into the subconjunctival and intra-orbital spaces, causing signs and symptoms suggestive of an orbital cellulitis.

Case report

A 43-year-old myopic (−3DS) female presented with 6/6 vision and a right macula-on rhegmatogenous retinal detachment associated with posterior vitreous detachment and a supero-temporal horse-shoe retinal tear. Emergency surgery was scheduled under

sub-tenons anaesthesia on the same day. Following a 5-ml sub-tenon block (a 50 : 50 mixture of 2% lignocaine and 0.5% bupivacaine with 150 units of hyaluronidase) the anaesthetist noted a tense globe and surgery was postponed due to a suspected retro-bulbar haemorrhage. The eye settled spontaneously within the next few hours and there was no evidence of a retro-bulbar haemorrhage. Surgery for the retinal detachment was scheduled the next day under general anaesthesia. She underwent 23-gauge micro-incision sutureless vitrectomy using valved self-sealing sclerostomies (Constellation Vision System, Alcon Laboratories, Inc, Fort Worth, TX, USA) with cryo retinopexy and 16% C2F6 gas tamponade (perfluoroethane). There were no intra-operative complications. Postoperatively on day 1, intra-ocular pressure (IOP) was 16 mm Hg and a 90% gas fill was noted with a flat retina. On postoperative day 3 the patient returned to the emergency department with headache, nausea, and redness and swelling of the right eye. Visual acuity was hand movements and the right eye was chemosed and congested with an IOP of 46 mm Hg. Mild anterior chamber inflammation (cells 1+) was

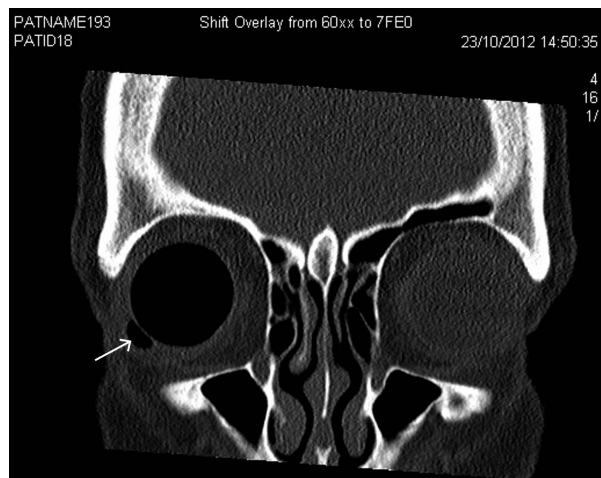

Figure 2 CT scan imaging of the orbits demonstrating extra-scleral loculated lesions (marked with an open white arrow) with the same radio-density as the intra-ocular gas. There are no signs of an orbital or sub-periosteal collection and no signs of orbital inflammation.

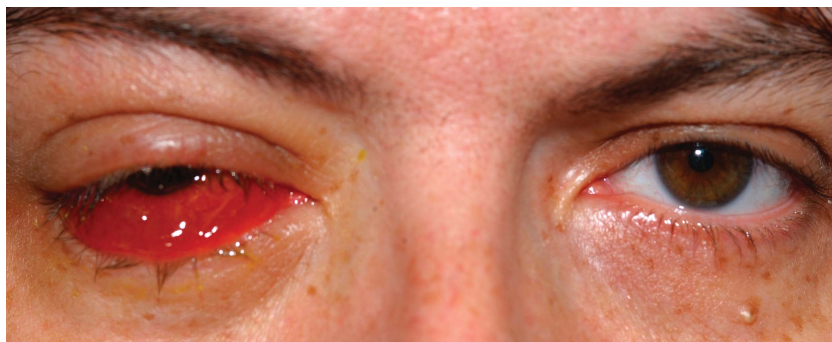

Figure 1 Colour photograph of the face demonstrating congestion, chemosis, and proptosis of the right eye with soft-tissue swelling of the upper and lower lid.

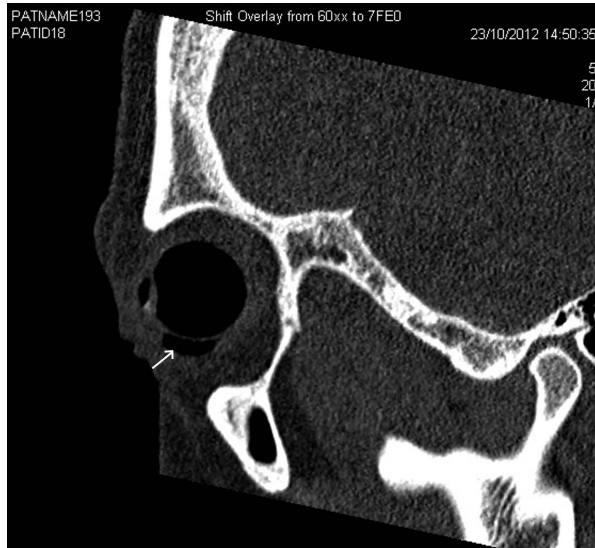


Figure 3 CT scan image of the orbit demonstrating extra-scleral loculated spaces (marked with an open white arrow) with the same radio-density as the intra-ocular gas.

noted; however, there was no hypopyon or pupil block and the anterior chamber was deep (Figure 1). Despite treatment with maximal topical antihypertensives and intravenous acetazolamide, IOP remained 44 mm Hg. The patient was admitted for management of the pain and the raised IOP. In the next 24 h she developed a 2 mm right-sided proptosis, a subtle relative afferent pupillary defect, mild limitation of right eye ocular movements, increasing pain, and a spike in temperature (38 °C). Based on the clinical findings of chemosis, congestion, a developing proptosis, limited ocular motility, a spike in temperature, and a subtle relevant afferent pupillary defect, an orbital cellulitis was suspected. An urgent CT scan of the orbits showed no signs of orbital haemorrhage, infection, or inflammation, but there were extra-scleral and subconjunctival loculated spaces with an appearance similar to that of the gas in the vitreous cavity (Figures 2 and 3). The CT scan raised suspicion of extra-ocular gas. Owing to the progressive proptosis and uncontrolled IOP despite maximum medical therapy, we decided to release and exchange the gas tamponade. The patient underwent 23-gauge vitrectomy with gas to fluid and then fluid to 1000 centistoke silicone oil exchange. Postoperatively the chemosis, congestion, and proptosis resolved completely and the patient was asymptomatic with a flat retina and a normal IOP. One month postoperatively, the retina is flat under oil; however, visual acuity is limited to hand movements owing to optic atrophy presumed to be secondary to the raised IOP and compression of the nerve from the intra-orbital gas.

Comment

Pure C2F6 is expansible to 3.3 times its original volume and is isovolumetric at 16%. We believe this clinical picture was caused due to an error in dilution of C2F6

resulting in an expansile intra-ocular concentration being used. The resultant increase in IOP exceeded the limit of the self-sealing sclerostomies, with gas escaping into the subconjunctival and orbital space. This gas that had escaped into the orbit continued to expand, resulting in proptosis, limitation of movements, and compression of the optic nerve. Removal of the gas resulted in resolution of the proptosis, chemosis, and IOP.

To the best of our awareness there are no reports of gas escaping from small-gauge self-sealing sclerostomies causing a clinical picture that resembles orbital cellulitis.^{1–5}

Conflict of interest

The authors declare no conflict of interest.

References

- 1 Lincoff A, Haft D, Liggett P, Reifer C. Intravitreal expansion of perfluorocarbon bubbles. *Arch Ophthalmol* 1980; **98**(9): 1646.
- 2 Chang S, Lincoff HA, Coleman DJ, Fuchs W, Farber ME. Perfluorocarbon gases in vitreous surgery. *Ophthalmology* 1985; **92**: 651–656.
- 3 Lincoff H, Mardirossian J, Lincoff A, Liggett P, Iwamoto T, Jakobiec F. Intravitreal longevity of three perfluorocarbon gases. *Arch Ophthalmol* 1980; **98**: 1610–1611.
- 4 Joutei Hassani RT, El Sanharawi M, Adam R, Monin C, Dupont-Monod S, Baudouin C. Influence of sutureless 23-gauge sclerotomy architecture on postoperative intraocular pressure decrease: results of a multivariate analysis. *Graefes Arch Clin Exp Ophthalmol* 2012; **251**(5): 1285–1292.
- 5 Ahn SJ, Woo SJ, Ahn J, Park KH. Comparison of postoperative intraocular pressure changes between 23-gauge transconjunctival sutureless vitrectomy and conventional 20-gauge vitrectomy. *Eye* 2012; **26**: 796–802.

N Kumar¹, P Tsangaris² and RJ Haynes²

¹Moorfields Eye Hospital, London, UK

²Bristol Eye Hospital, Bristol, UK

E-mail: richardjhaynes@me.com

Eye (2014) **28**, 1263–1264; doi:10.1038/eye.2014.151;

published online 25 July 2014

Sir, IgG4-related orbital inflammation presenting as bilateral proptosis in a child

IgG4-related orbital disease is an immune-mediated fibro-inflammatory disease with systemic associations^{1,2} and predominantly affects middle-aged and elderly patients,² presentation of IgG4-related orbital disease in children is very rare.^{3,4}