

Intestinal ascariasis at pediatric emergency room in a developed country

Shuichiro Umetsu, Tsuyoshi Sogo, Kentaro Iwasawa, Takeo Kondo, Tomoyuki Tsunoda, Manari Oikawa-Kawamoto, Haruki Komatsu, Ayano Inui, Tomoo Fujisawa

Shuichiro Umetsu, Tsuyoshi Sogo, Kentaro Iwasawa, Takeo Kondo, Tomoyuki Tsunoda, Manari Oikawa-Kawamoto, Ayano Inui, Tomoo Fujisawa, Department of Pediatric Hepatology and Gastroenterology, Saiseikai Yokohama City Tobu Hospital, Kanagawa 230-0012, Japan

Haruki Komatsu, Department of Pediatrics, Toho University Medical Center, Sakura Hospital, Chiba 285-8741, Japan

Author contributions: Umetsu S and Sogo T were both attending doctors and drafted the manuscript and they made equal contributions to this case report; Iwasawa K, Kondo T, Tsunoda T, and Oikawa-Kawamoto M participated in radiological and endoscopic examinations, and discussion on diagnosis and treatment; Inui A, Komatsu H and Fujisawa T supervised diagnosis and treatment; all authors read and approved the final manuscript.

Correspondence to: Tsuyoshi Sogo, MD, Department of Pediatric Hepatology and Gastroenterology, Saiseikai Yokohama City Tobu Hospital, Shimosueyoshi 3-6-1, Tsurumi Ward, Yokohama City, Kanagawa 230-0012,

Japan. so5244ibukick@kdp.biglobe.ne.jp

Telephone: +81-45-5763000 Fax: +81-45-5763525

Received: April 13, 2014 Revised: May 27, 2014

Accepted: June 25, 2014

Published online: October 14, 2014

Abstract

Ascaris lumbricoides infection is rare among children in developed countries. Although large numbers of adult *Ascaris* in the small intestine can cause various abdominal symptoms, this infection remains asymptomatic until the number of worms in the intestine considerably increases in most cases. *Ascaris* causing bilious vomiting suggesting ileus is rare, especially in developed countries. A 6-year-old boy who lived in Japan, presented with abdominal colic, bilious vomiting at the pediatric emergency room. He appeared pale, and had no abdominal distention, tenderness, palpable abdominal mass, or findings of dehydration. He experienced bilious vomiting again during a physical examination.

Laboratory tests showed mild elevation of white blood cells and C-reactive protein levels. Antigens of adenovirus, rotavirus, and norovirus were not detected from his stool, and stool culture showed normal flora. Ultrasonography showed multiple, round-shaped structures within the small intestine, and a tubular structure in a longitudinal scan of the small intestine. Capsule endoscopy showed a moving worm of *Ascaris* in the jejunum. Intestinal ascariasis should be considered as a cause of bilious vomiting in children, even at the emergency room in industrial countries. Ultrasound examination and capsule endoscopy are useful for diagnosis of pediatric intestinal ascariasis.

© 2014 Baishideng Publishing Group Inc. All rights reserved.

Key words: *Ascaris lumbricoides*; Paralytic ileus; Capsule endoscopy; Ultrasound; Bilious vomiting

Core tip: Intestinal ascariasis usually remains asymptomatic until the number of worms in the intestine considerably increases. A single worm of *Ascaris* can enter the ampulla of Vater and result in biliary colic. Ileus caused by a single worm is rare. Moreover, the diagnosis of intestinal ascariasis might not be considered as a cause of symptoms suggesting ileus because ascariasis is rare in developed countries. This is the report of a child who presented with bilious vomiting caused by a single worm of *Ascaris lumbricoides*. Pediatricians in developed country need to be aware that *Ascaris* infection can cause bilious vomiting.

Umetsu S, Sogo T, Iwasawa K, Kondo T, Tsunoda T, Oikawa-Kawamoto M, Komatsu H, Inui A, Fujisawa T. Intestinal ascariasis at pediatric emergency room in a developed country. *World J Gastroenterol* 2014; 20(38): 14058-14062 Available from: URL: <http://www.wjgnet.com/1007-9327/full/v20/i38/14058.htm> DOI: <http://dx.doi.org/10.3748/wjg.v20.i38.14058>

INTRODUCTION

Ascaris lumbricoides (*A. lumbricoides*) is the most common intestinal helminth parasite, and it is estimated that the infected population is 0.8-1.2 billion worldwide^[1]. The highest prevalence of ascariasis occurs in tropical and semitropical countries where sanitation is poor. However, there has been a dramatic decrease in the prevalence of ascariasis in several Asian and Latin American countries with economic development^[2]. In developed countries, *Ascaris* infection is rare, especially among children.

Although large numbers of adult *Ascaris* in the small intestine can cause abdominal distension, abdominal pain, obstructive ileus, malnutrition, and growth failure, this infection remains asymptomatic until the number of worms in the intestine considerably increases in most cases^[1]. A single worm of *A. lumbricoides* can enter the ampulla of Vater and result in biliary colic, obstructive jaundice, ascending cholangitis, acalculous cholecystitis, or acute pancreatitis^[1,3,4]. Because of the low prevalence of ascariasis among children living in developed countries, pediatricians rarely encounter ascariasis as a cause of obstructive ileus in the pediatric emergency room.

We describe a 6-year-old boy who presented with symptoms suggesting ileus caused by a single worm of *A. lumbricoides* at the pediatric emergency room in a developed country.

CASE REPORT

A 6-year-old boy, who lived in Yokohama, Japan, presented with abdominal colic, bilious vomiting, and a fever of 38.0 °C at the pediatric emergency room in Saiseikai Yokohama City Tobu Hospital. He had no history of digestive diseases, except for infectious gastroenteritis, and no growth failure, anemia, or metabolic diseases before this episode. He had a history of traveling to the Philippines annually. The last visit to the Philippines was 5 mo ago. His height was 113 cm (-0.3 standard deviation) and body weight was 18.1 kg (-0.8 standard deviation). On physical examination, he appeared pale, and had no abdominal distention, tenderness, palpable abdominal mass, or findings of dehydration. He experienced bilious vomiting repeatedly during a physical examination. Therefore, he received an abdominal ultrasound examination with suspicion of ileus.

Ultrasonography showed multiple, round-shaped structures with a target-like appearance within the small intestine. We also observed a tubular structure with two parallel, outer high echogenic lines in a longitudinal scan of the small intestine (Figure 1). There was no dilation of the small intestine with fluid retention, suggesting ileus. There was also no thickened wall of the gut, indicating gastrointestinal inflammation or edema. Color Doppler ultrasound did not detect blood flow in the tubular structure within the small intestine. The biliary system and pancreas were normal. Abdominal computed tomography following an ultrasound examination also showed a tubular structure within the small intestine without dila-

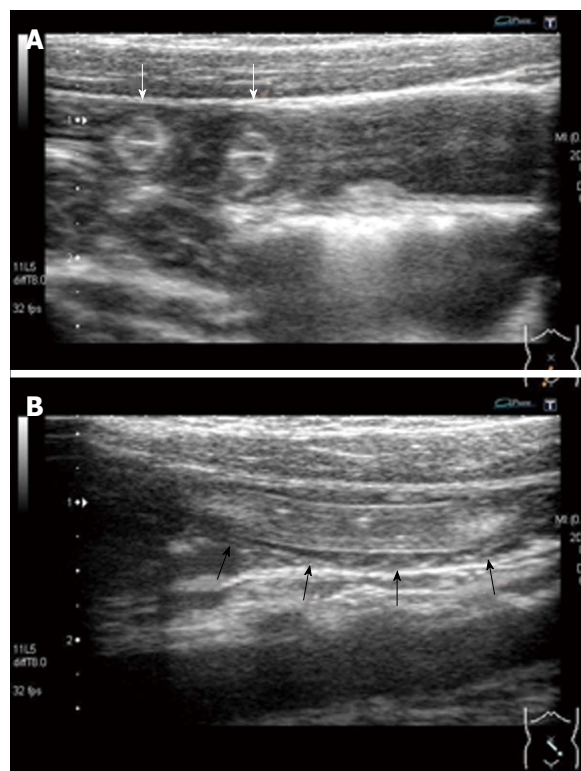


Figure 1 Abdominal ultrasound examination at the pediatric emergency room. A: Ultrasonography shows multiple, round-shaped structures with a target-like appearance within the small intestine (white arrows); B: In a longitudinal scan of the small intestine, ultrasound shows a tubular structure with two parallel, outer high echogenic lines (black arrows). Space between the intestinal wall and the tubular structure was not observed.

tion. He was admitted for further examinations. Laboratory tests at admission were as follows: white blood cells, 14400/ μ L; eosinophils, 100/ μ L; hemoglobin level, 13.1 mg/dL; platelets, 328000/ μ L; and C-reactive protein level, 1.29 mg/dL. All other results, including electrolytes and urinalysis, were within normal limits. Antigens of adenovirus, rotavirus, and norovirus were not detected from his stool by immunochromatography, and stool culture showed normal flora.

The day after admission, his clinical symptoms disappeared, but the tubular structure in his small intestine remained, as shown by an ultrasound examination (Figure 2). Capsule endoscopy was performed 3 d after admission, and showed a moving roundworm, with an estimated length of at least 10 cm, in the jejunum (Figure 3). No worms were observed in other sites.

He was treated with pyrantel pamoate 4 d after admission, and defecated a single roundworm 5 d after admission (Figure 4). The diagnosis of a single roundworm infection (*A. lumbricoides*) was determined.

DISCUSSION

A. lumbricoides has a worldwide distribution, but it occurs most frequently in developing countries where the sanitation is poor, and is rare in industrialized countries^[1,2,5]. While the majority of *A. lumbricoides* infections are as-

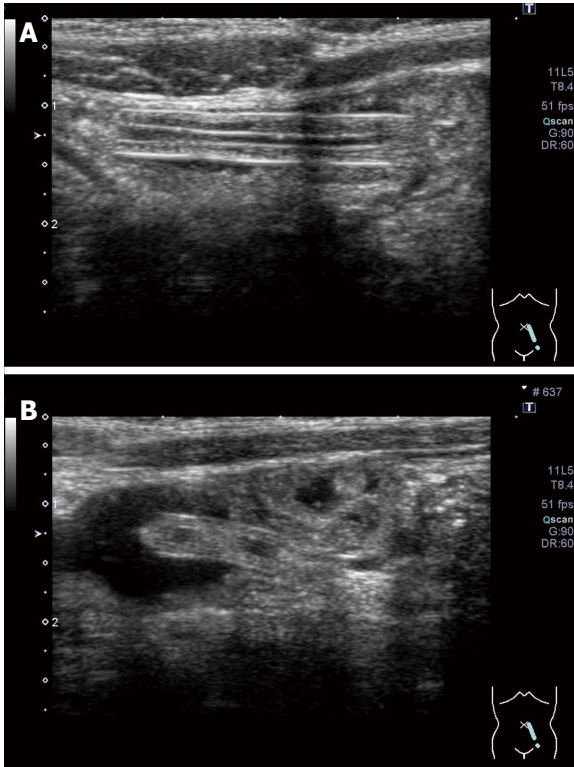


Figure 2 Abdominal ultrasound examination on the day after admission. The tubular structure in the patient's small intestine was still observed. An ultrasound examination shows a space between the intestinal wall and the tubular structure, and fluid could pass through this space.

ymptomatic, an estimated 8%-15% of those infected are associated with morbidity^[6]. Severity of this infection increases with worm burden, and those who harbor light infections tend to be asymptomatic^[6]. When adult worms in the duodenum enter and block the ampullary orifice of the common bile duct or main pancreatic duct, they cause biliary colic, cholecystitis, cholangitis, pancreatitis, and hepatic abscesses^[1,3,4]. Large numbers of adult worms can cause obstructive ileus, especially in children whose intestinal lumen is small^[1,6-10]. Obstruction by *Ascaris* is the most common etiology in developing countries, whereas adhesion obstruction is the most common in developed countries^[7-9]. Obstruction owing to ascariasis commonly occurs at the terminal ileum, although large numbers of worms are found in the jejunum. Surgical removal of worms is often required^[7-10]. Other causes of obstruction from *Ascaris* are the result of associated volvulus or intussusception caused by the bolus of worms^[7-10]. In these cases, large numbers of worms cause ileus, although a single worm rarely causes ileus or ileus-like symptoms. Riggin *et al*^[11] reported a case of paralytic ileus caused by intestinal ascariasis. In addition, *Ascaris* may excrete neurotoxins that make the small bowel contract (spasticity), resulting in obstruction^[8]. We encountered a child presenting with symptoms suggesting ileus, such as bilious vomiting and abdominal colic caused by a single worm of *A. lumbricoides* at the pediatric emergency room in a developed country. Diagnosis of intestinal ascariasis was

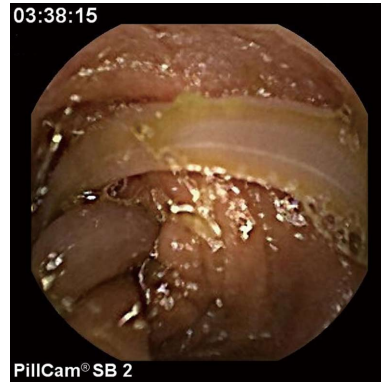

Figure 3 Capsule endoscopy. Capsule endoscopy shows a single roundworm moving in the jejunum. There appears to be more than one worm body. However, movement of each part of a body able to be visualized was coordinated. A single worm of *Ascaris* infection was diagnosed.



Figure 4 Excreted *Ascaris lumbricoides* after treatment. A single worm of *Ascaris lumbricoides* was excreted the day after treatment of pyrantel pamoate. The worm length was approximately 20 cm.

made by ultrasound examination and capsule endoscopy.

There have been reports on sonographic diagnosis of intestinal ascariasis^[12-17]. Characteristic sonographic findings of intestinal ascariasis are as follows: a “winding highway” or “parallel lines,” a “railway track” or “3-line” or “4-line” signs on longitudinal scans, a “target” or “bull’s eye” appearance on transverse scans, and a “zig-zag sign”, which indicates that the live worm shows characteristic slow, pendular, non-directional movements. Ultrasonography of the abdomen is a quick, safe, easily available, non-invasive, and useful modality for intestinal ascariasis^[12-14,17]. An ultrasound examination should initially be performed if intestinal ascariasis is suspected. *A. lumbricoides* in the biliary system and pancreatic duct is relatively easy to detect by ultrasound examination because these organs are fixed in the abdomen. Occasionally, it is difficult to recognize *Ascaris* in the small intestine with an ultrasound examination when worms are mixed with feces, when intestinal gas interferes with observation, or when patients cannot keep still in childhood. In addition, another factor that interferes with observation is mobility of the small bowel. Moreover, in developed countries where ascariasis is rare, the diagnosis of intestinal ascariasis might not be consid-

ered. Therefore, pediatricians need to be aware that *Ascaris* infection can be a cause of bilious vomiting, indicating ileus. In our case, we should have suspected parasitosis as a cause of the symptoms suggesting ileus because the patient had a history of traveling to the Philippines. We might have been able to avoid further examinations, including computed tomography (CT) and capsule endoscopy, if we had been familiar to ascariasis and suspected ascariasis as a cause of bilious vomiting. There were several reasons why we could not reach a diagnosis with ultrasonography as follows: we did not consider intestinal ascariasis as a cause of bilious vomiting and abdominal pain, we could not observe mobile worms despite repeated ultrasound examinations, and symptoms suggesting ileus were not assumed to be caused by a single worm infection. We reached a diagnosis of intestinal ascariasis by capsule endoscopy following an ultrasound examination.

Capsule endoscopy is a prevailing technology mainly used in developed countries, which are not endemic areas of *Ascaris*, and it is not widely used in endemic areas. In previous reports on diagnosis of intestinal ascariasis using capsule endoscopy, most of the patients were adults^[18-23]. To the best of our knowledge, only one report described this technique in a pediatric case^[23]. In our case, we placed a capsule endoscope into the duodenum endoscopically, and identified a tubular object that was detected by ultrasound in his small intestine. Detecting specific ultrasound findings of intestinal ascariasis is easy, and treatment can be initiated in cases where a large number of adult worms cause symptoms. Capsule endoscopy is useful in cases where a small number of worms or a single worm causes symptoms. In addition, capsule endoscopy can clarify the type and be used to estimate the number of infected parasites. In our case, capsule endoscopy revealed a single worm of *Ascaris* infection in the small intestine.

Aggregation of adult worms usually leads to obstructive ileus caused by ascariasis. In some cases, obstruction from *Ascaris* is the result of associated volvulus or intussusception caused by a bolus of worms^[7-10]. In our case, there were no findings of volvulus or intussusceptions, and no intestinal dilatation of the oral side of an infected worm. However, the patient presented with colicky abdominal pain and recurrent bilious vomiting, suggesting ileus. Bilious vomiting at any age is an ominous sign that mandates immediate evaluation, and a sign of intestinal obstruction until proven otherwise^[24]. He also presented with a fever and elevation of serum C-reactive protein levels. No pathogens of acute gastroenteritis were detected. An ultrasound examination showed no space between the worm and intestinal wall at the emergency room, but a space between the worm and intestinal wall appeared after clinical symptoms disappeared. *Ascaris* may excrete neurotoxins, which make the small bowel contract (spasticity), resulting in obstruction^[8]. Findings in our case support this putative pathogenesis.

In conclusion, intestinal ascariasis should be considered as a cause of bilious vomiting, suggesting ileus in children, even at the emergency room in industrial

countries, especially in children with a history of traveling to endemic areas. Ultrasound examinations and capsule endoscopy are useful for diagnosis of pediatric intestinal ascariasis.

ACKNOWLEDGMENTS

We thank Dr. Ellen Knapp who provided medical writing services on behalf of Edanz Group Japan KK.

COMMENTS

Background

Ascaris lumbricoides (*A. lumbricoides*) is the most common intestinal helminth parasite, the highest prevalence of ascariasis occurs in tropical and semitropical countries where sanitation is poor. However, *Ascaris* infection is rare in developed countries, especially among children. Large numbers of adult *Ascaris* infection can cause intestinal obstruction, but a single worm of *Ascaris* infection usually asymptomatic.

Research frontiers

Capsule endoscopy is a recently developed modality for the evaluation of small bowel diseases, first developed in adults, and thereafter applied to children. For children who cannot swallow a capsule endoscope, the capsule is placed into the duodenum endoscopically. In previous reports on diagnosis of intestinal ascariasis using capsule endoscopy, most of the patients were adults. In this report, authors detected a tubular structure in small intestine, and confirmed a single worm infection of *Ascaris* using capsule endoscopy.

Innovations and breakthroughs

In this case, the authors placed a capsule endoscope into the duodenum endoscopically in a pediatric case, and identified a tubular object that was detected by ultrasound in his small intestine. Moreover, capsule endoscopy revealed a single worm of *Ascaris* infection in the small intestine as a cause of bilious vomiting.

Applications

Intestinal ascariasis should be considered as a cause of bilious vomiting in children, even at the emergency room in industrial countries, especially in children with a history of traveling to endemic areas. Ultrasound examinations and capsule endoscopy should be applied to a diagnosis of pediatric intestinal ascariasis.

Terminology

A. lumbricoides, the human roundworm, is one of the most common soil transmitted parasites in the world, infecting about 1.2 billion people globally.

Peer review

This case report presents a patient with symptomatic ascariasis diagnosed in an area in which this infection is infrequent. The images and comments may be interesting for the readers because the paper includes some characteristic ultrasonographic images facilitating easy diagnosis.

REFERENCES

- 1 **Bethony J**, Brooker S, Albonico M, Geiger SM, Loukas A, Diemert D, Hotez PJ. Soil-transmitted helminth infections: ascariasis, trichuriasis, and hookworm. *Lancet* 2006; **367**: 1521-1532 [PMID: 16679166 DOI: 10.1016/s0140-6736(06)68653-4]
- 2 **de Silva NR**, Brooker S, Hotez PJ, Montresor A, Engels D, Savioli L. Soil-transmitted helminth infections: updating the global picture. *Trends Parasitol* 2003; **19**: 547-551 [PMID: 14642761 DOI: 10.1016/j.pt.2003.10.002]
- 3 **Sharma M**. Echogenic shadow in the common bile duct. Diagnosis: Biliary ascariasis. *Gastroenterology* 2011; **141**: e14-e15 [PMID: 21640114 DOI: 10.1053/j.gastro.2010.05.093]
- 4 **Lee TH**, Park SH, Lee CK, Lee SH, Chung IK, Kim SJ. *Ascaris lumbricoides*-induced acute pancreatitis. *Gastrointest Endosc* 2012; **75**: 192-193; discussion 193 [PMID: 22196821 DOI: 10.1016/j.gie.2011.08.052]

- 5 **Masucci L**, Graffeo R, Bani S, Bugli F, Boccia S, Nicolotti N, Fiori B, Fadda G, Spanu T. Intestinal parasites isolated in a large teaching hospital, Italy, 1 May 2006 to 31 December 2008. *Euro Surveill* 2011; **16**: [PMID: 21699767]
- 6 **Dold C**, Holland CV. Ascaris and ascariasis. *Microbes Infect* 2011; **13**: 632-637 [PMID: 20934531 DOI: 10.1016/j.micinf.2010.09.012]
- 7 **Shiekh KA**, Baba AA, Ahmad SM, Shera AH, Patnaik R, Sherwani AY. Mechanical small bowel obstruction in children at a tertiary care centre in Kashmir. *Afr J Paediatr Surg* 2010; **7**: 81-85 [PMID: 20431216 DOI: 10.4103/0189-6725.62852]
- 8 **Villamizar E**, Méndez M, Bonilla E, Varon H, de Onatra S. Ascaris lumbricoides infestation as a cause of intestinal obstruction in children: experience with 87 cases. *J Pediatr Surg* 1996; **31**: 201-24; discussion 201-24; [PMID: 8632280 DOI: 10.1016/s0022-3468(96)90348-6]
- 9 **Baba AA**, Ahmad SM, Sheikh KA. Intestinal ascariasis: the commonest cause of bowel obstruction in children at a tertiary care center in Kashmir. *Pediatr Surg Int* 2009; **25**: 1099-1102 [PMID: 19760197 DOI: 10.1007/s00383-009-2486-8]
- 10 **Wani I**, Rather M, Naikoo G, Amin A, Mushtaq S, Nazir M. Intestinal ascariasis in children. *World J Surg* 2010; **34**: 963-968 [PMID: 20143068 DOI: 10.1007/s00268-010-0450-3]
- 11 **Riggin AJ**, Brewer MB, Turner PL, Singh DP. Paralytic ileus secondary to intestinal ascariasis. *Am Surg* 2012; **78**: E481-E483 [PMID: 23089427]
- 12 **Mehta V**, Goyal S, Pandit S, Mittal A, Aggarwal A. Sonographic diagnosis of Ascaris lumbricoides infestation as a cause of intestinal obstruction. *Indian J Pediatr* 2010; **77**: 827 [PMID: 20589467 DOI: 10.1007/s12098-010-0114-1]
- 13 **Coşkun A**, Özcan N, Durak AC, Tolu I, Güleç M, Turan C. Intestinal ascariasis as a cause of bowel obstruction in two patients: sonographic diagnosis. *J Clin Ultrasound* 1996; **24**: 326-328 [PMID: 8792275]
- 14 **Aydin R**, Bekci T, Bilgici MC, Polat AV. Sonographic diagnosis of ascariasis causing small bowel obstruction. *J Clin Ultrasound* 2014; **42**: 227-229 [PMID: 24132881 DOI: 10.1002/jcu.22100]
- 15 **Mahmood T**, Mansoor N, Quraishy S, Ilyas M, Hussain S. Ultrasonographic appearance of Ascaris lumbricoides in the small bowel. *J Ultrasound Med* 2001; **20**: 269-274 [PMID: 11270532]
- 16 **Sharma UK**, Rauniyar RK, Bhatta N. Roundworm infestation presenting as acute abdomen in four cases--sonographic diagnosis. *Kathmandu Univ Med J (KUMJ)* 2005; **3**: 87-90 [PMID: 16401953]
- 17 **Mahmood SA**, Lee EY. Intestinal Ascaris lumbricoides. *Pediatr Radiol* 2010; **40**: 1452 [PMID: 19902200 DOI: 10.1007/s00247-009-1449-5]
- 18 **Wickramasinghe DP**, Samarasekera DN. Intestinal helminths detected in capsule endoscopy. *Dig Endosc* 2012; **24**: 388 [PMID: 22925304 DOI: 10.1111/j.1443-1661.2012.01297.x]
- 19 **Soares J**, Lopes L, Villas-Boas G, Pinho C. Ascariasis observed by wireless-capsule endoscopy. *Endoscopy* 2003; **35**: 194 [PMID: 12561020 DOI: 10.1055/s-2003-37008]
- 20 **Balachandran P**, Prasad VG. Intestinal parasites seen on capsule endoscopy. *Gastrointest Endosc* 2006; **64**: 651 [PMID: 16996366 DOI: 10.1016/j.gie.2006.03.009]
- 21 **Flóro L**, Pák G, Sréter L, Tulassay Z. Wireless capsule endoscopy in the diagnosis of helminthiasis. *Gastrointest Endosc* 2007; **65**: 1078; discussion 1079 [PMID: 17451709 DOI: 10.1016/j.gie.2006.09.023]
- 22 **Yamashita ET**, Takahashi W, Kuwashima DY, Langoni TR, Costa-Genzini A. Diagnosis of Ascaris lumbricoides infection using capsule endoscopy. *World J Gastrointest Endosc* 2013; **5**: 189-190 [PMID: 23596544 DOI: 10.4253/wjge.v5.i4.189]
- 23 **Fritscher-Ravens A**, Scherbakov P, Bufler P, Torroni F, Ruska T, Nuutinen H, Thomson M, Tabbers M, Milla P. The feasibility of wireless capsule endoscopy in detecting small intestinal pathology in children under the age of 8 years: a multicentre European study. *Gut* 2009; **58**: 1467-1472 [PMID: 19625281 DOI: 10.1136/gut.2009.177774]
- 24 **Parashette KR**, Croffie J. Vomiting. *Pediatr Rev* 2013; **34**: 307-19; quiz 320-1 [PMID: 23818085 DOI: 10.1542/pir.34-7-307]

P- Reviewer: Bordas JM, Perakath B, Zhao HT
S- Editor: Ding Y L- Editor: A E- Editor: Ma S





Published by **Baishideng Publishing Group Inc**

8226 Regency Drive, Pleasanton, CA 94588, USA

Telephone: +1-925-223-8242

Fax: +1-925-223-8243

E-mail: bpgoffice@wjgnet.com

Help Desk: <http://www.wjgnet.com/esps/helpdesk.aspx>

<http://www.wjgnet.com>



ISSN 1007-9327



9 771007 932045