

Nicolas Mélé, MD
Vincent Guiraud, MD
Pierre Labauge, MD, PhD
Catherine Oppenheim,
MD, PhD
Jean Louis Mas, MD,
PhD
Guillaume Taieb, MD

*Neurol Neuroimmunol
Neuroinflammation*
2014;1:e6; doi: 10.1212/
NXI.0000000000000006

EFFECTIVE ANTITUBERCULOUS THERAPY IN A PATIENT WITH CLIPPERS: NEW INSIGHTS INTO CLIPPERS PATHOGENESIS

OPEN

Chronic lymphocytic inflammation with pontine perivascular enhancement responsive to steroids (CLIPPERS) is a brainstem relapsing-remitting inflammatory disease. To date, no treatment besides corticosteroids has been shown to be effective to treat relapses. We report a patient with CLIPPERS initially misdiagnosed with CNS tuberculosis who presented with brainstem attacks responsive to antituberculous therapy.

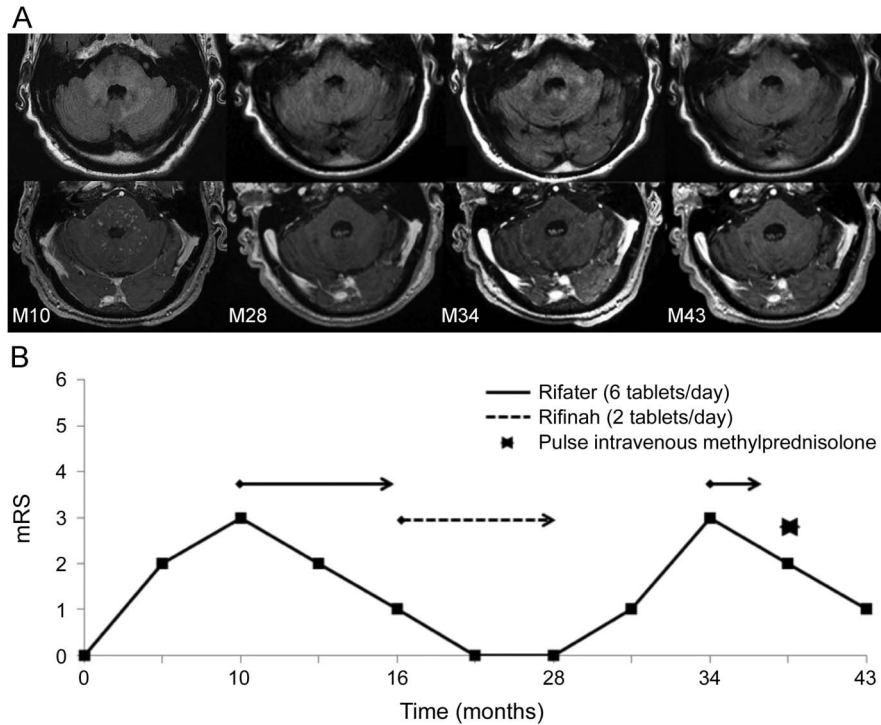
Case report. A 64-year-old man with a history of surgical resection of left thigh fibrosarcoma 5 years ago progressively developed dysarthria, intermittent horizontal diplopia, dizziness, and unsteady gait together with asthenia and anorexia. Ten months after symptom onset (M10), clinical examination showed horizontal bidirectional nystagmus, left facial peripheral nerve palsy, dysarthria, left cerebellar limb ataxia, and ataxic gait. Brain MRI revealed punctate and curvilinear enhancements on gadolinium-injected T1-weighted images involving brainstem, middle cerebellar peduncles, cerebellum, left-sided internal capsule, and corona radiata. Fluid-attenuated inversion recovery (FLAIR) sequences showed hyperintensities in the corresponding areas (figure 1, M10). Spinal MRI disclosed punctate gadolinium-enhancing lesions and patchy T2-weighted hyperintensities in the cervical and upper thoracic cord (figure 2). CSF analysis displayed mild pleocytosis (5/mm³, normal range 0–4/mm³, 95% lymphocytes) and elevated protein level (0.68 g/L, normal range 0.15–0.45 g/L). Oligoclonal bands were absent. CSF cytology, bacterial cultures, and *Tropheryma whipplei* PCR were negative. QuantiFERON-TB Gold test was positive (AgTB-TN >10 UI/mL, positivity threshold >0.35 UI/mL). *Mycobacterium tuberculosis* cultures from gastric washings, bronchoalveolar lavage, CSF, and urine were negative. The other extensive laboratory investigations for infectious, inflammatory, and autoimmune (including antiganglioside and onconeural antibodies) diseases were negative. Labial salivary gland biopsy and whole-body fluorodeoxyglucose PET scan showed no evidence of systemic diseases known to involve the CNS. The patient refused brain biopsy. Based on QuantiFERON-TB Gold

results, a combination of 3 antituberculosis drugs (rifampicin, isoniazid, and pyrazinamide) (Rifater, Sanofi-Aventis, France) was started without corticosteroids. After 2 months, examination showed only mild left limb ataxia. Brain and spinal MRI (figure 2) showed resolution of enhancing lesions and significant decrease of T2-weighted hyperintensities. Four months later, pyrazinamide was stopped and rifampicin plus isoniazid was continued (Rifinah, Sanofi-Aventis, France). At the end of the 18-month treatment period, the patient was asymptomatic, and brain MRI only showed some hyperintensities on FLAIR images without enhancing lesions (figure 1, M28). Six months later, the patient experienced clinical and radiologic relapse (figure 1, M34). Rifampicin/isoniazid/pyrazinamide was restarted, leading to progressive clinical improvement. Based on clinical and radiologic features of CLIPPERS together with the absence of tuberculosis, antituberculous therapy was stopped. IV bolus of methylprednisolone (1 g daily for 3 days) was started, with marked clinical and radiologic improvement (figure 1, M43).

Discussion. In our patient, clinical, MRI, and CSF findings, together with relapse after adequate antituberculous therapy, made the diagnosis of CNS tuberculosis very unlikely. Moreover, *M tuberculosis* was never found on bacterial analysis. Positive QuantiFERON-TB results only indicate the presence of memory T lymphocytes (directed against tuberculosis antigens), but not necessarily active tuberculosis. In this case, after excluding the differential diagnoses, the occurrence of brainstem attacks with characteristic punctate and curvilinear enhancing lesions involving the pons responsive to steroids made the diagnosis of CLIPPERS.¹

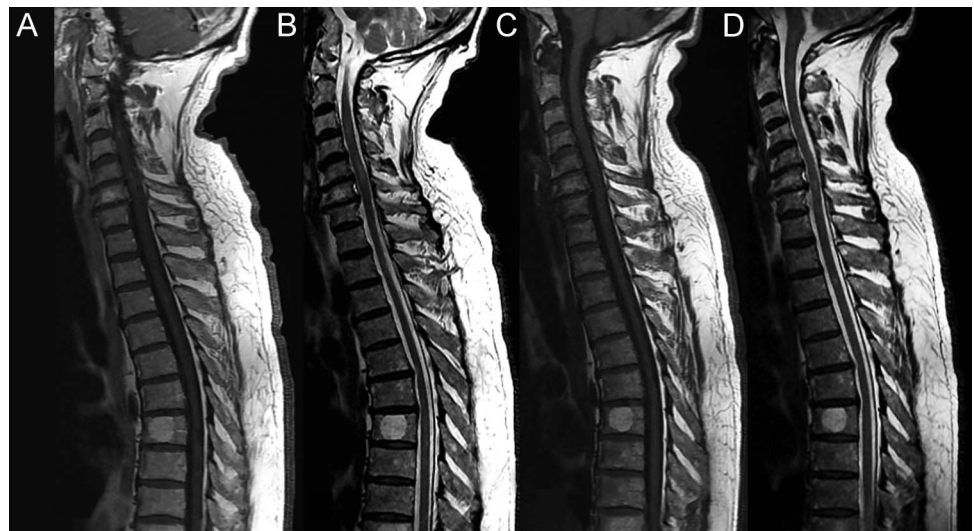
Ataxia and diplopia, commonly seen during CLIPPERS attacks, were associated with peripheral facial nerve palsy in our patient. Considering that CLIPPERS predominantly concerns white (as opposed to gray) matter on pathologic findings, the mechanism of the facial nerve palsy is probably due to a lesion concerning its fascicle within the brainstem. However, a lesion involving the nucleus of the facial nerve or the facial nerve in the subarachnoid space (related to the meningeal involvement) cannot be excluded in our patient.

Figure 1 Clinical and brain MRI course in a patient with CLIPPERS treated with antituberculous therapy



(A) Axial brain MRI of the pons and cerebellum using fluid-attenuated inversion recovery (FLAIR) (top) and gadolinium-injected T1-weighted sequences (bottom). M10: punctate confluent lesions involving the pons, middle cerebellar peduncles, and cerebellum were seen on FLAIR sequences with associated punctate enhanced lesions in the corresponding areas. M28: marked decrease of FLAIR hyperintensities and resolution of the enhanced lesions, associated with brainstem volume reduction. M34: recurrence of FLAIR hyperintensities with few enhanced lesions. M43: decrease of FLAIR hyperintensities and disappearance of enhanced lesions. (B) MRI findings were correlated with the graphical representation of disability, as assessed by the modified Rankin Scale (mRS), ranging from no symptoms (0) to death (6). During the course of the disease the patient experienced symptoms with no disability (1), slight disability (2), or moderate disability (3). Treatments are also indicated.

Figure 2 Spinal MRI in a patient with CLIPPERS treated with antituberculous therapy



Gadolinium-enhancing lesions (A) and fluid-attenuated inversion recovery (FLAIR) hyperintensities (B) involving the cervical and upper thoracic cord are seen on the initial spinal MRI. After 2 months of antituberculous therapy, enhancing lesions disappeared (C) and FLAIR hyperintensities decreased (D).

The repeated clinical and radiologic response to rifampicin/isoniazid/pyrazinamide and the relapse after its withdrawal in our case suggest that antituberculous therapy might be a treatment for CLIPPERS. In contrast to isoniazid and pyrazinamide, rifampicin is an anti-inflammatory agent inhibiting the nuclear factor kappa-light-chain-enhancer of activated B cells (NF- κ B) pathway.² NF- κ B is a transcription factor that activates proinflammatory genes in immune cells and promotes Th17 differentiation and function.³ As Th1, Th2, and Foxp3 regulatory T cells, Th17 is a subset of T4 cells. It is interesting that rifampicin also seems to be beneficial in rheumatoid arthritis, Crohn disease, and psoriasis, known to be Th17-related autoimmune diseases.^{2,4} CLIPPERS histology is characterized by perivascular and parenchymal lymphohistiocytic infiltrates with a predominance of T4 cells.⁵ To date, T4 cell subsets in CLIPPERS are undetermined. As CLIPPERS is considered an autoimmune disease, the clinical and radiologic response to antituberculous therapy suggests that CLIPPERS may be a Th17-related autoimmune disease.

Two previously reported patients with initial features of CLIPPERS progressed within a few months to CNS B-cell lymphoma.^{6,7} Perivascular infiltrates of T cells (without B-cell lymphoma), seen on the first brain biopsy, have been considered host immunity fighting against the lymphoma. In animal models, the T-cell cytokine profiles in CNS B-cell lymphoma microenvironment (i.e., antitumor response) are Th1/Th17.⁸ In inhibiting the Th17 pathway, rifampicin should in theory accelerate the emergence of B-cell lymphoma. Therefore, in contrast to steroid therapy (effective in lymphoma and CLIPPERS), rifampicin might be useful to distinguish these 2 entities. Further studies are needed to confirm the beneficial effect of rifampicin and to better determine the underlying pathophysiology of CLIPPERS.

From the Department of Neurology (N.M., V.G., J.L.M.) and Department of Neuroradiology (C.O.), Université Paris-Descartes, Sorbonne Paris Cité, INSERM UMR 894, Centre Hospitalier Sainte-Anne, Paris, France; Department of Neurology (P.L.), CHU Montpellier, Hôpital Gui de Chauliac, Montpellier, France; and Department of Neurology (G.T.), CHU Nîmes, Hôpital Caremeau, Nîmes, France.

Author contributions: Nicolas Mélé: drafting/ revising the manuscript, study concept or design, analysis or interpretation of data.

Vincent Guiraud: drafting/ revising the manuscript, study concept or design, analysis or interpretation of data. Pierre Labauge: drafting/ revising the manuscript, analysis or interpretation of data. Catherine Oppenheim: drafting/ revising the manuscript, analysis or interpretation of data. Jean Louis Mas: drafting/ revising the manuscript, analysis or interpretation of data. Guillaume Taieb: drafting/ revising the manuscript, study concept or design, analysis or interpretation of data.

Study funding: No targeted funding reported.

Disclosure: The authors report no disclosures relevant to the manuscript. Go to Neurology.org/n for full disclosures. The Article Processing Charge was paid by the authors.

This is an open access article distributed under the terms of the Creative Commons Attribution-Noncommercial No Derivative 3.0 License, which permits downloading and sharing the work provided it is properly cited. The work cannot be changed in any way or used commercially.

Received January 16, 2014. Accepted in final form March 19, 2014.

Correspondence to Dr. Taieb: taiebguillaume@gmail.com

1. Pittock SJ, Debruyne J, Krecke KN, et al. Chronic lymphocytic inflammation with pontine perivascular enhancement responsive to steroids (CLIPPERS). *Brain* 2010;133:2626–2634.
2. Cheng J, Shah YM, Ma X, et al. Therapeutic role of rifaximin in inflammatory bowel disease: clinical implication of human pregnane X receptor activation. *J Pharmacol Exp Ther* 2010;335:32–41.
3. Chen G, Hardy K, Pagler E, et al. The NF- κ B transcription factor c-Rel is required for Th17 effector cell development in experimental autoimmune encephalomyelitis. *J Immunol* 2011;187:4483–4491.
4. Tsankov N, Grozdev I. Rifampicin—a mild immunosuppressive agent for psoriasis. *J Dermatolog Treat* 2011;22:62–64.
5. Simon NG, Parratt JD, Barnett MH, et al. Expanding the clinical, radiological and neuropathological phenotype of chronic lymphocytic inflammation with pontine perivascular enhancement responsive to steroids (CLIPPERS). *J Neurol Neurosurg Psychiatry* 2012;83:15–22.
6. Limousin N, Praline J, Motica O, et al. Brain biopsy is required in steroid-resistant patients with chronic lymphocytic inflammation with pontine perivascular enhancement responsive to steroids (CLIPPERS). *J Neurooncol* 2012;107:223–224.
7. De Graaff HJ, Wattjes MP, Rozemuller-Kwakkel AJ, Petzold A, Killestein J. Fatal B-cell lymphoma following chronic lymphocytic inflammation with pontine perivascular enhancement responsive to steroids. *JAMA Neurol* 2013;70:915–918.
8. Donnou S, Galand C, Daussy C, et al. Immune adaptive microenvironment profiles in intracerebral and intrasplenic lymphomas share common characteristics. *Clin Exp Immunol* 2011;165:329–337.