

Treatment of pig serum-induced rat liver fibrosis with *Boschniakia rossica*, oxymatrine and interferon- α

Chun-Song Wu, Xi-Xu Piao, Dong-Ming Piao, Yong-Ri Jin, Cheng-Hao Li

Chun-Song Wu, Xi-Xu Piao, Yong-Ri Jin, Cheng-Hao Li, Department of Gastroenterology, the Affiliated Hospital, Medical College, Yanbian University, Yanji 133000, Jilin Province, China

Dong-Ming Piao, Department of Pathology, the Affiliated Hospital, Medical College, Yanbian University, Yanji 133000, Jilin Province, China
Supported by the Medical Scientific Research Fund of Health Department of Jilin Province, No. 114

Correspondence to: Xi-Xu Piao, Department of Gastroenterology, the Affiliated Hospital, Medical College, Yanbian University, 119 Juzi Street, Yanji 133000, Jilin Province, China. piaoxixu1951@yahoo.com
Telephone: +86-433-2660061 **Fax:** +86-433-2513610

Received: 2003-05-11 **Accepted:** 2003-06-12

Abstract

AIM: To investigate the effect of *Boschniakia rossica* (BR), oxymatrine (OM) and interferon-alpha (IFN- α) 1b on the therapy of rat liver fibrosis and its mechanism.

METHODS: By establishing a rat model of pig serum-induced liver fibrosis, liver/weight index and serum alanine transaminase (ALT) were observed to investigate the therapeutic effect of BR, OM and IFN- α . Radioimmunoassay was utilized to measure procollagen type III (PCIII) and collagen type IV (CIV). RT-PCR was used to assay the expression of liver transforming growth factor- β 1 (TGF- β 1) mRNA. Immunohistochemistry of alpha-smooth muscle actin (α -SMA) and pathologic changes of liver tissues were also under investigation.

RESULTS: Serum PCIII and CIV in BR, OM and IFN- α groups were significantly declined compared with those in model group, and their RT-PCR revealed that TGF- β 1 mRNA expression was also reduced more than that in model group. Immunohistochemistry demonstrated that α -SMA also declined more than that in model group. Serum ALT in IFN- α , control and model groups was within normal level. Serum ALT in BR group had no significant difference from those of IFN- α , control and model groups. Serum ALT in OM group was significantly higher than those in BR, IFN- α , model, and control groups.

CONCLUSION: BR, OM and IFN- α can prevent pig serum-induced liver rat fibrosis by inhibiting the activation of hepatic stellate cells and synthesizing collagen. OM has hepatotoxicity to rat liver fibrosis induced by pig serum.

© 2005 The WJG Press and Elsevier Inc. All rights reserved.

Key words: Liver fibrosis; *Boschniakia rossica*; Oxymatrine; Interferon-alpha

Wu CS, Piao XX, Piao DM, Jin YR, Li CH. Treatment of pig serum-induced rat liver fibrosis with *Boschniakia rossica*, oxymatrine and interferon-alpha. *World J Gastroenterol* 2005; 11(1): 122-126

<http://www.wjgnet.com/1007-9327/11/122.asp>

INTRODUCTION

Liver fibrosis results from chronic hepatitis, ethanol abuse or other conditions. It is a very common disease in China and severely affects people's health. All countries in the world including China have not approved any drug on liver fibrosis therapy^[1]. Herbal medicine has been used to treat liver fibrosis in China for thousands of years. It is found that Chinese herbal medicine has the direct function of preventing liver fibrosis besides the effect of protecting hepatocytes^[2]. Many ingredients of Chinese herbs have been proved in previous studies on liver fibrosis. *Boschniakia rossica* (BR) Fedtsch Et Flerov is a parasitic plant growing on the root of *Alnus* plant^[3]. Dried BR is used to nourish the kidney, strengthen Yang, loose the bowel, arrest bleeding, and prolong life^[4-6]. BR is called "anti-senility herb" (bu lao cao) among civilians. Oxymatrine (OM) is a preparation of alkaloid aqueous solution extracted from herbal medicine matrine. It has biological functions of anti-inflammation, antibacteria, antiviral, anti-tumor and immunosuppression. There are many reports about the prophylactic effect of OM on liver fibrosis and its function to suppress activation of hepatic stellate cells^[7-11]. In the present study, a rat liver fibrosis model was established with pig serum and the therapeutic effect and mechanism of BR, OM and IFN- α on liver fibrosis were investigated.

MATERIALS AND METHODS

Drugs and animals

BR was accredited and extracted by a medicative botanist, Professor Yong-Zhen Liu from Medical College, Yanbian University. OM injection concentration was 200 mg/2 mL (Ningxia Pharmaceutical Factory). Interferon -alpha 1b was purchased from Shenzhen Kexing Bioproducts Co., LTD.

Male Wistar rats, 7 wk old and weighing 150-180 g, were obtained from Animal Facility of Yanbian University Medical College. After a week acclimation period on a basal diet, the rats were divided randomly into experimental groups.

Experimental protocol

The experiment was started on Monday (d 1), and the total study period was 10 wk. Five experimental groups were designed: control group ($n = 8$), model group ($n = 10$), BR group ($n = 10$), OM group ($n = 10$) and IFN- α group ($n = 10$). Each group except for control group received 0.5 mL pig serum twice a week for 10 wk via intraperitoneal injection. At the beginning of the 6th wk (Day 36), BR group received 500 mg/kg of BR by oral administration. OM group received 60 mg/kg of OM, and IFN- α group received 50 000u IFN- α via muscle injection. At the same time, control group received 0.5 mL of saline injection twice a week for 10 wk. All the rats were killed under ether anesthesia, blood was obtained from the right ventricle, and the livers were excised for TGF- β 1 mRNA assay and pathological examination.

Serum markers

At end of the experiment, serum ALT was assayed by a HITACHI 7600-010 autobiochemical analyser, while serum PCIII and CIV by radioimmunoassay.

Histological examination and immunohistochemical staining

Three μm thick sections from right lobes of all rat livers were processed routinely for hematoxylin and eosin and Sirius-red staining. α -SMA for detection of activated hepatic stellate cells was assessed immunohistochemically by the avidin-biotin-peroxidase complex method. Anti- α -SMA monoclonal antibody (Zhongshan Bio-tech Company) was also used.

Morphological examination of liver tissue

The results of sirius-red staining were examined under optical microscope. The level of liver fibrosis was divided into five grades^[12]: grade 0: no fibrosis; grade 1: fibrosis located within portal area with a tendency to become worse; grade 2: fibrosis involving 2/3 liver lobule; grade 3: fibrosis reaching the surroundings of central vein; grade 4: the total liver lobule had permeant fibrosis, with false lobule formation and changes in grade 3.

TGF- β 1 mRNA assay

RT-PCR was used to examine TGF- β 1 mRNA in liver tissue. Total RNA was extracted with Trizol (Invitrogen Chemical Co.). The sense primer sequence was 5' GCC TCC GCA TCC CAC CTT TG 3' and the sequence of antisense primer was 5'GCG GGT GAC TTC TTT GGC GT 3' (synthesized by Sino-American Biotechnology Company). RT-PCR was performed with Access Quick™ RT-PCR system (Promega), and the procedures were as follows. First, reverse transcription was incubated for 45 min at 48 °C and initial denaturation for 2 min at 95 °C. Each PCR cycle was at 95 °C for 45 s, at 60 °C for 45 s and at 70 °C for 45 s, the number of cycles was 25 and the final extension was carried out at 70 °C for 5 min. RT-PCR products were resolved on 1.0% agarose gel and then visualized with ultraviolet assay and photography. The results were determined with computerized image analysis (CMIAS).

Statistical analysis

Results were presented as mean \pm SD, differences of ordinal

data were analyzed using Kroskal-Wallis test and measurement data were analyzed using one-way analysis of variance (ANOVA). The results were analyzed by SPSS 10.0 software.

RESULTS

General condition

The condition did not change in control group, but the activity was reduced, urine became yellow and most rats had diarrhea in model group. General conditions in BR, OM and IFN- α groups were much better than those in model group.

Liver/weight index

Liver/weight index in model group was slightly higher than that in other groups, but the difference had no statistical significance ($P=0.169$).

Serum markers

Serum ALT was not increased after administration of pig serum for 10 wk in model group. IFN- α at doses up to 50 000u also had no effect on serum ALT level, but serum ALT in OM group was excessively increased and significantly higher than that in model and IFN- α groups ($P<0.009$). Serum ALT in BR group had no considerable changes compared with model group, but was significantly lower than that in OM group ($P=0.021$). The serum ALT level was significantly higher in BR group than in IFN- α group ($P=0.043$). Only serum IV collagen in model group was significantly higher than that in other groups ($P<0.048$). The PCIII level in model group was also significantly higher than that in BR, OM and IFN-alpha groups ($P<0.001$), and the PCIII level in IFN- α group had almost no change compared with that in control group ($P=0.341$), but serum PCIII in OM group was significantly higher than that in control group ($P=0.028$, Table 1).

Histological findings

In model group, the rat liver stained with Sirius-red and HE showed an extensive accumulation of collagens (Figures 1: C, D),

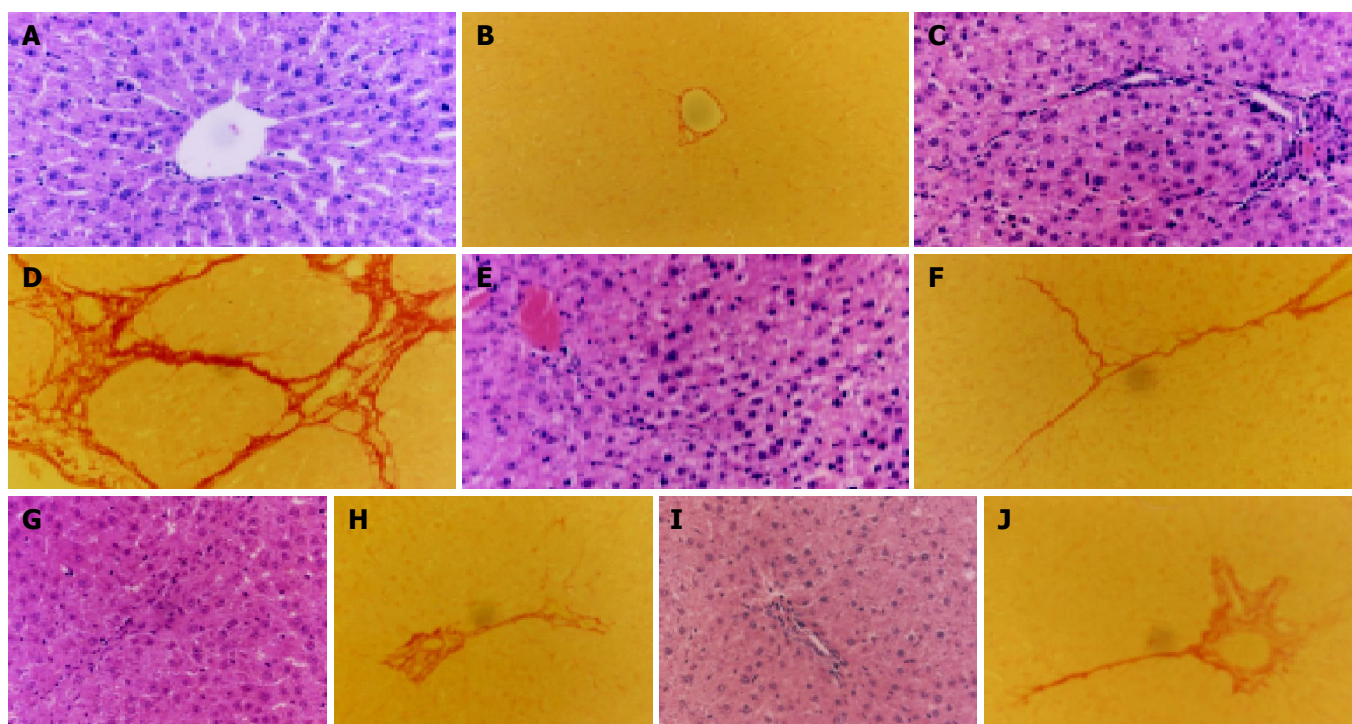


Figure 1 Histological findings in model group. Livers stained with Sirius-red (D) and HE (C) showed an extensive accumulation of collagens. The accumulation of collagens was higher in model group than in BR group as shown in Figures 1 A, 1B, 1E, 1F, 1H, 1I and 1J.

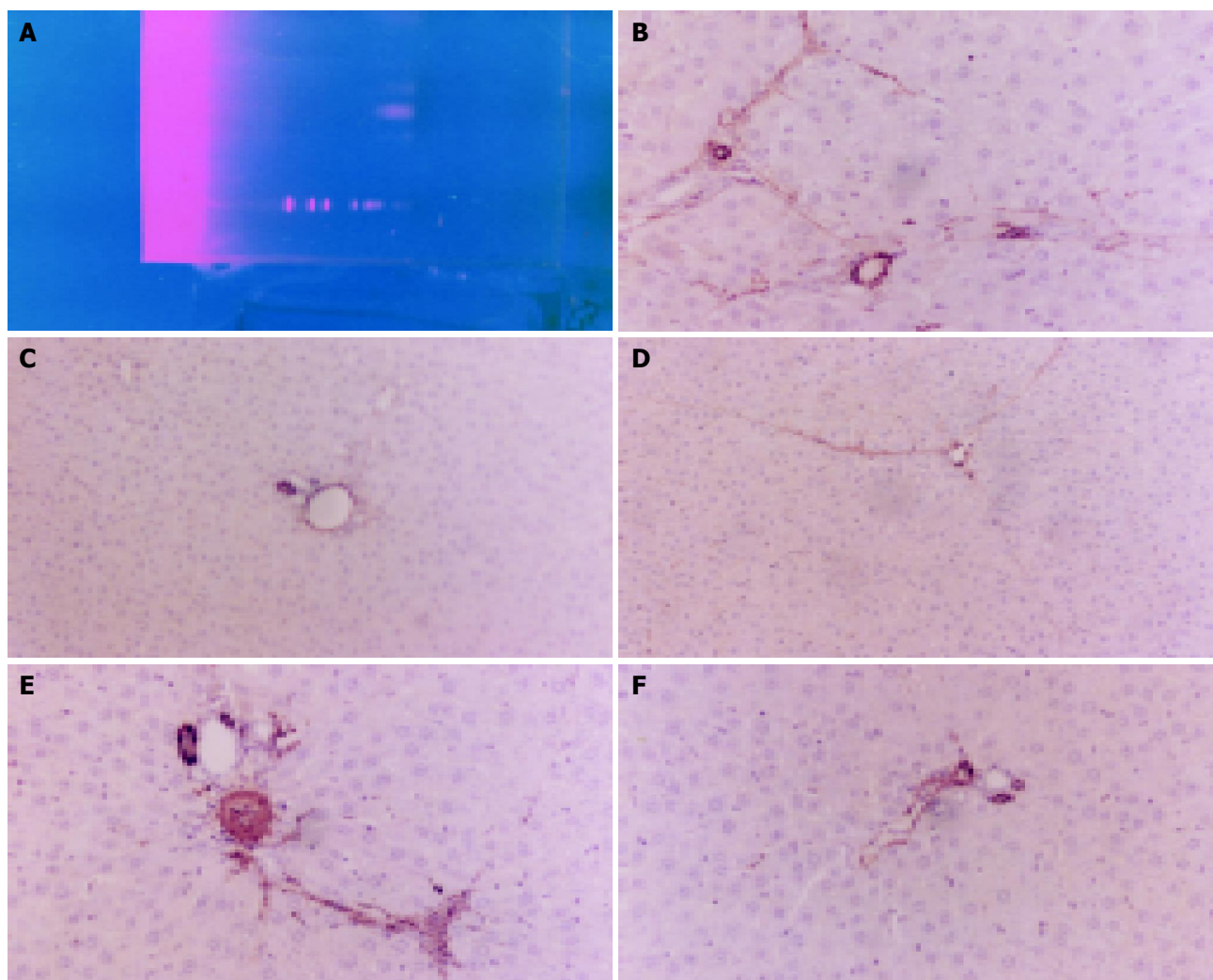


Figure 2 Expression of TGF- β 1 in liver tissue. A: RT-PCR products of TGF- β 1 mRNA in liver tissue resolved on 1.0% agarose gel (M: markers; 1: Control; 2: Model; 3: BR; 4: OM; 5: IFN- α); B: Results of model group rat liver specimens stained with IHC. Lots of α -SMA positive cells, hepatic cord lined up in disorder and fibrosis septum could be seen; C-F: Liver cells stained with IHC ($\times 200$) in control, BR, OM and IFN- α groups respectively.

fibrotic septum increased and was found between port to port and port to central vein in some parts of lobules, in some serious units false lobules presented. But no hepatocyte necrosis was found. The accumulation of collagens in BR ($P = 0.003$), OM ($P = 0.009$) and IFN- α ($P = 0.0237$) groups was obviously lower than that in model group (Figure 1 A, B, E-J). The grades of liver fibrosis are shown in Table 2.

Table 1 Serum markers of ALT (U/L), PCIII (μ g/L) and CIV (μ g/L, mean \pm SD)

	Control <i>n</i> = 8	Model <i>n</i> = 10	OM <i>n</i> = 10	IFN <i>n</i> = 9	BR <i>n</i> = 10
ALT	48.00 \pm 3.0	51.33 \pm 6.5	67.70 \pm 3.3 ¹	41.33 \pm 1.8	53.80 \pm 5.2
PCIII	5.83 \pm 0.4	9.91 \pm 3.1	7.46 \pm 0.7 ^{1,2}	6.68 \pm 0.3 ¹	6.56 \pm 0.4 ¹
CIV	0.93 \pm 0.7 ¹	4.13 \pm 1.4	0.97 \pm 0.9 ¹	0.90 \pm 0.6 ¹	0.40 \pm 0.4 ¹

¹Significantly different compared with model group, ²significantly different compared with control group.

Expression of TGF- β 1 mRNA in liver tissue

The RT-PCR products of TGF- β 1 mRNA were electrophoresed with 1.0% agarose gel (Figure 2 A). The TGF- β 1 mRNA expression in control group was not significant, but was significant in model group and the expression of TGF- β 1 mRNA in BR, OM

and IFN- α groups was significantly lower than that in model group ($P < 0.05$).

Table 2 Comparison of liver fibrosis grades in different groups

Group	<i>n</i>	0	I	II	III	IV
Control	8	8	0	0	0	0
Model	10	0	5	1	1	3
OM	10	2	7	0	1	0
IFN	9	2	6	1	0	0
BR	10	4	5	0	1	0

Immunohistochemical assay

Activated hepatic stellate cells, characterized by expression of α -SMA and called myofibroblast-like cells, were markedly increased in the liver of rats that received pig serum for 10 wk (Figure 2 B). In BR, OM and IFN- α groups, the number of α -SMA positive cells in liver was much lower than that in model group ($P < 0.05$, Figures 2C-F), and the distribution of α -SMA positive cells was similar to that of collagen in the liver.

DISCUSSION

Fibrosis is a dynamic process associated with the continuous deposition and resorption of connective tissues and collagens.

Therapeutic strategies have shown that this dynamic process can be modulated. Many results in previous studies suggest that BR could markedly enhance the immune reactivation of Kupffer cells. Kupffer cells are the necessary cells when the body responds to TD antigen immune reaction^[13]. BR could significantly restore superoxide dismutase (SOD) activation reduced by CCL₄ intoxication and CCL₄-induced lipid peroxidation products^[14,15]. Researches also show that BR could inhibit swelling of carageen gel-induced rat podium, PGE release from swollen podium and permeability of rat celiac capillaries^[4,16]. Song *et al*^[8] found that OM could inhibit fibroblastic proliferation and expression of type III collagen mRNA *in vivo*. Chen *et al*^[9] compared the effects of OM and IFN- α on cultured rat hepatic stellate cells, and found that OM had the similar inhibitory effect as IFN- α on rat stellate cells *in vitro*, indicating that OM has prophylactic effects on D-galactosamine-induced rat liver fibrosis, since it can protect hepatocytes and suppress activation of hepatic stellate cells through anti-lipoperoxidation *in vivo*^[7,10]. It was reported that IFN- α could inhibit hepatic stellate cell activation and lipid peroxidation in liver mitochondria, and enhance biological defense activities against oxidative stress and function as a potent fibrosuppressant by protecting hepatocytes and hepatic stellate cells from lipid peroxidation *in vivo*^[17]. It could inhibit the proliferation and collagen synthesis of stellate cells, down-regulate the expression of procollagen types I and III mRNA and reduce the deposition of collagen types I and III in fibrotic liver^[18]. IFN- α could improve the function and composition of liver cells and erythrocyte membrane^[19]. Early and long-term administration of IFN- α could prevent the development of liver fibrosis and porto-collateral circulation in the CCL₄ model^[20]. Clinical researches on IFN- α have shown that IFN- α elevates MMP-1/TIMP-1 ratio and decreases the extent of liver fibrosis^[21], reduces the number of α -SMA- positive cells and decorin expression^[22], and improves liver inflammation and fibrosis in patients with chronic hepatitis C^[23]. IFN- α could also reduce liver fibrosis independent of its antiviral activity^[24,25]. In the present study, an immune liver fibrosis model was established by intraperitoneal injection of pig serum, and the model was designed according to the fact that many kinds of fibrosis are related to type III immune reaction^[26]. The present study showed that serum ALT was not increased and there was no obvious hepatocyte necrosis except for liver fibrosis in model group. In IFN- α group serum ALT had no change, and this result is similar to that treated with IFN- γ ^[27]. The obvious increase of serum ALT in OM group indicated that OM has hepatotoxicity to rat liver fibrosis induced by pig serum. Radioimmunoassay showed that serum PCIII and CIV were significantly decreased, indicating that BR, OM and IFN- α inhibit synthesis of collagens, and that serum PCIII is higher than CIV, which is in line with the result that PCIII was the main collagen accumulated in primeval fibrosis^[26]. TGF β -1 activates hepatic stellate cells and increases α -SMA expression^[28,29]. On the other hand, the activated hepatic stellate cells release a lot of TGF- β 1^[30]. The present study showed that BR, OM and IFN- α could inhibit the activation of hepatic stellate cells and the release of TGF- β 1. Pathological results further indicate BR, OM and IFN- α have anti-fibrosis actions. This study compared the anti-fibrosis action of BR, OM and IFN- α , and found that BR had no effect on liver serum ALT, and is thus being very convenient for use. BR is an effective herb with a promising prospect of application.

In conclusion, the results in the present study indicate that BR, OM and IFN- α can prevent pig serum-induced liver fibrosis by inhibiting the activation of stellate cells and synthesis of collagens. OM has hepatotoxicity to liver fibrosis induced by pig serum.

REFERENCES

- 1 Cai WM. Medicinal therapy of anti-fibrosis. *Zhonghua Ganzhangbing Zazhi* 2001; **4**: 120-121
- 2 Wang BE. Treatment of chronic liver diseases with traditional Chinese medicine. *J Gastroenterol Hepatol* 2000; **15** Suppl: E67-E70
- 3 Yin ZZ, Kim HS, Kim YH, Lee JJ. Iridoid compounds from Boschniakia rossica. *Arch Pharm Res* 1999; **22**: 78-80
- 4 Yu QH, Gao DY, Piao GC, Shun QS, Yang HJ, Niu YF, Liu YJ. The experimental pharmacology study of Boschniakia rossica. *Zhongyaocai* 1993; **16**: 32-34
- 5 Tusaha T, Liu YZ, Sugaya A, Katoh K, Hori K, Tanaka S, Nomura M, Sugaya E. Reinforcement effects of Boschniakia rossica on discrimination learning in cholinergic lesions of rats. *J Ethnopharmacol* 1994; **44**: 67-71
- 6 Tsuda T, Sugaya A, Liu YZ, Katoh K, Tanaka H, Kawazura H, Sugaya E, Kusai M, Kohno M. Radical scavenger effect of Boschniakia rossica. *J Ethnopharmacol* 1994; **41**: 85-90
- 7 Yang WZ, Zeng MD, Lu LG, Mao YM, Fan ZP, Song YL, Jia YT, Chen CW, Pen YS, Zhu HY. An experimental study of prophylactic effect of Oxymatrine on D-galactosamine-induced rat liver fibrosis. *Ganzang* 2002; **7**: 2-4
- 8 Song J, Zhang XR, Zhu L, Zhang ZB, Zhang XK. Effects of Oxymatrine on the proliferation and procollagen III mRNA expression. *Dier Junyi Daxue Xuebao* 1999; **20**: 356-358
- 9 Chen C, Liu B, Gu YH, Ge SM. Inhibition of oxymatrine, a Chinese herbal medicine, and Chinese made interferon-alpha1b and alpha2b on proliferation and collagen synthesis of rat hepatic stellate cells. *Weichangbingxue He Ganbingxue Zazhi* 2002; **3**: 32-35
- 10 Yang W, Zeng M, Fan Z, Mao Y, Song Y, Jia Y, Lu L, Chen CW, Peng YS, Zhu HY. Prophylactic and therapeutic effect of oxymatrine on D-galactosamine-induced rat liver fibrosis. *Zhonghua Ganzhangbing Zazhi* 2002; **10**: 193-196
- 11 Yu YY, Wang QH, Zhu LM, Zhang QB, Xu DZ, Guo YB, Wang CQ, Guo SH, Zhou XQ, Zhang LX. A clinical research on oxymatrine for the treatment of chronic hepatitis B. *Zhonghua Ganzhangbing Zazhi* 2002; **10**: 280-281
- 12 Zhai WR, Wang TL, Zhou XJ, Zhang TH. The diagnosis, grading and staging of chronic hepatitis. *Zhonghua Xiaohua Zazhi* 1996; **16**: 277-280
- 13 Piao YR, Jiang YS, Li YX, Jin MS, Jiang YN. Effects of Boschniakia rossica on the immune reactivation of hepatic kuffle cells. *Zhongcaoyao* 1994; **25**: 200-202
- 14 Yang XW, Lou ZC, Yan ZK. Anti-lipid peroxidative effects of ethanolic extract of Boschniakia rossica on the liver tissue of mice *in vivo*. *Zhongguo Yaoxue Zazhi* 1995; **30**: 84-86
- 15 Shen M, Yin Z. Effect of Boschniakia rossica extract on antioxidative activities in rat hepatic preneoplasia induced by diethylnitrosamine. *Zhongguo Zhongyao Zazhi* 1999; **24**: 746-748,765
- 16 Yin ZZ, Jin HL, Yin XZ, Li TZ, Quan JS, Jin ZN. Effect of Boschniakia rossica on expression of GST-P, p53 and p21^{ras} proteins in early stage of chemical hepatocarcinogenesis and its anti-inflammatory activities in rats. *World J Gastroenterol* 2000; **6**: 812-818
- 17 Lu G, Shimizu I, Cui X, Itonaga M, Tamaki K, Fukuno H, Inoue H, Honda H, Ito S. Interferon-alpha enhances biological defense activities against oxidative stress in cultured rat hepatocytes and hepatic stellate cells. *J Med Invest* 2002; **49**: 172-181
- 18 Zhang Q, Wang J, Hu M. Effects of interferon-alpha on the mRNA expression of procollagen type I and III of hepatic stellate cells and on the deposition of collagen type I and III in fibrotic liver of rats. *Zhonghua Yixue Zazhi* 1999; **79**: 695-698
- 19 Muriel P, Bolanos J, Barral JM, Torres G. Effect of alpha-interferon on erythrocyte and hepatocyte plasma membranes derived from cirrhotic rats. *Pharmacology* 1994; **48**: 63-68
- 20 Fort J, Pilette C, Veal N, Oberti F, Gallois Y, Douay O, Rosenbaum J, Cales P. Effects of long-term administration of interferon alpha in two models of liver fibrosis in rats. *J Hepatol* 1998; **29**: 263-270
- 21 Ninomiya T, Yoon S, Nagano H, Kumon Y, Seo Y, Kasuga M,

- Yano Y, Nakaji M, Hayashi Y. Significance of serum matrix metalloproteinases and their inhibitors on the antifibrogenetic effect of interferon-alfa in chronic hepatitis C patients. *Intervirology* 2001; **44**: 227-231
- 22 **Jarmay K**, Gallai M, Karacsony G, Ozsvar Z, Schaff Z, Lonovics J, Kovalszky I. Decorin and actin expression and distribution in patients with chronic hepatitis C following interferon- alfa-2b treatment. *J Hepatol* 2000; **32**: 993-1002
- 23 **Serejo F**, Costa A, Oliveira AG, Ramalho F, Batista A, De Moura MC. Alpha-interferon improves liver fibrosis in chronic hepatitis C: clinical significance of the serum N-terminal propeptide of procollagen type III. *Dig Dis Sci* 2001; **46**: 1684-1689
- 24 **Vendemiale G**, Grattagliano I, Caruso ML, Serviddio G, Valentini AM, Pirrelli M, Altomare E. Increased oxidative stress in dimethylnitrosamine- induced liver fibrosis in the rat: effect of N-acetylcysteine and interferon-alpha. *Toxicol Appl Pharmacol* 2001; **175**: 130-139
- 25 **Mazzoran L**, Tamaro G, Mangiarotti MA, Marchi P, Baracetti S, Gerini U, Fanni-Cannelles M, Zorat F, Pozzato G. Effects of interferon therapy on fibrosis serum markers in HCV-positive chronic liver disease. *Eur J Gastroenterol Hepatol* 1998; **10**: 125-131
- 26 **Cheng ML**. The basically study and clinic of liver fibrosis. Beijing: *people's Medical Publishinghouse of China* 1996: 17-50
- 27 **Sakaida I**, Uchida K, Matsumura Y, Okita K. Interferon gamma treatment prevents procollagen gene expression without affecting transforming growth factor-beta₁ expression in pig serum-induced rat liver fibrosis *in vivo*. *J Hepatol* 1998; **28**: 471-479
- 28 **Zhan YT**, Wei HS. The effect and sence of transferring growth factor-β in liver fibrosis. *Guowai Yixue Mianyixue Fence* 2000; **24**: 230-233
- 29 **Kanzler S**, Lohse AW, Keil A, Henninger J, Dienes HP, Schirmacher P, Rose-John S, zum Buschenfelde KH, Blessing M. TGF-beta1 in liver fibrosis: an inducible transgenic mouse model to study liver fibrogenesis. *Am J Physiol* 1999; **276**: G1059-G1068
- 30 **Wang BE**. Hepatic stellate cell and liver fibrosis. *Zhonghua Ganzhangbing Zazhi* 2000; **8**: 197-199

Edited by Wang XL and Zhang JZ Proofread by Ma JY