

Cutaneous Granulomatous Response to BCG Cell Walls with Reference to Cancer Immunotherapy

D. L. GRANGER,¹ W. BREHMER,² K. YAMAMOTO,³ AND E. RIBI*

National Institute of Allergy and Infectious Diseases, Rocky Mountain Laboratory, Hamilton, Montana 59840

Received for publication 9 October 1975

A chronic inflammatory response produced by cell walls of *Mycobacterium bovis* strain BCG associated with microscopic oil droplets (BCG CW-O) was studied with reference to the tumor-regressing ability of this preparation. When BCG CW-O was injected intradermally in the footpads of guinea pigs, intense inflammation developed at the site of injection and in the draining popliteal lymph node. This was characterized histologically as granulomatous inflammation. The intensity of the response was related to the dose of BCG CW-O. Cell walls without oil produced the same type of inflammation but much less in degree. Data are presented that demonstrate the immunological nature of this response and classify it as a cell-mediated immune reaction. Ramifications of this chronic inflammatory reaction occurring at the site of a tumor are discussed.

Previous studies from this laboratory showed that cell walls of *Mycobacterium bovis* strain BCG (BCG CW) suspended in saline and injected into the skin of rabbits produced a chronic inflammatory lesion at the site of injection (7, 12). This was attended by the development of delayed hypersensitivity (DH) to tuberculin. More recently it was shown that BCG CW associated with oil droplets (BCG CW-O) produced this same effect after intradermal (i.d.) injection in guinea pigs, and histological studies of the injection site showed granulomatous inflammation (8). The demonstration that BCG CW-O effectively regressed cutaneous tumor transplants after intralesional treatment in guinea pigs (18) provided impetus for further examination of the response to this preparation in epithelial tissue. Moreover, since evidence suggested that activated histocytes responding to intratumor infection with viable BCG may kill tumor cells nonspecifically, as "innocent bystanders" (10), it would follow that with a more complete understanding of the mechanism by which this response occurs in the skin, more effective regimens and immunotherapeutic agents could be developed.

A second important feature of the host response to BCG CW-O is that which occurs in the lymph node draining the injection site. It is

known that in guinea pigs with 7-day-old cutaneous hepatoma transplants, microscopic metastases have developed within the first draining node (5). Again, it is possible that these metastases may be eliminated as a result of a regional lymphadenitis which develops after intratumor treatment with viable BCG (5) or BCG CW-O.

In this report the inflammatory reaction in guinea pigs to i.d. injection of BCG CW-O was studied. As with viable BCG, the nonliving cell wall preparation produced a chronic inflammatory lesion at the site of injection, which was associated with gross regional lymphadenopathy. Microscopically, this was shown to be a chronic granulomatous reaction at these sites. Methods for determining the course and intensity of the inflammatory reaction are presented. That this phenomenon is mediated by immune cells is strongly suggested by the findings in this study.

MATERIALS AND METHODS

Animals. Hartley strain random-bred guinea pigs were obtained from the Rocky Mountain Laboratory colony. Animals within any experiment were all of the same sex and weighed approximately 400 g. For cell transfer experiments inbred strain 2 guinea pigs from the same source and meeting the same requirements as listed above were used. Guinea pigs were housed in groups on soft bedding.

Mycobacterial cell walls. Preparation of BCG CW has been described in detail (11). Cell walls of *Mycobacterium ulcerans* were prepared similarly. The cell walls were stored lyophilized in a desiccator containing CaCl₂.

¹ Present address: Department of Medicine, Strong Memorial Hospital, Rochester, N. Y. 14620.

² Present address: Robert Koch Institute, Berlin, Germany.

³ Present address: Institute of Immunological Science, Hokkaido University, Sapporo, Japan.

Emulsions. Preparation of cell walls associated with mineral oil droplets (e.g., BCG CW-O) has been described previously (1). Briefly, a weighed amount of lyophilized cell walls was mixed with 2 drops (approximately 80 μ l) of a light mineral oil, Drakeol 6 VR (Pennsylvania Refining Co., Butler, Pa.), by grinding in a 15-ml tissue homogenizer equipped with a Teflon pestle. A volume of sterile saline containing 0.2% Tween 80 (TS) to give the desired concentration of cell walls was added and grinding was continued until a well-dispersed oil-in-water emulsion was obtained. The emulsion was then heated at 65 C for 30 min in a water bath. Emulsion containing mineral oil droplets without cell walls (TS-O) was prepared in the same manner as BCG CW-O except that no cell walls were added to the mixture. The emulsion consisted of microscopic oil droplet spheres which appeared granulated when prepared with cell walls and translucent when no cell walls were added.

BCG cell walls in TS. Suspensions of BCG cell walls in TS were prepared exactly like BCG CW-O except that 2 drops of TS was added in place of the mineral oil.

Q fever rickettsia vaccine. Vaccine containing formalinized Q fever rickettsia, California strain, was kindly supplied by Robert Philip of the Rocky Mountain Laboratory. This was concentrated by removal of water by dialysis against dry Sephadex G-50. The resulting preparation contained 240 μ g of Q fever organisms per 0.1 ml.

Hind footpad injections. Emulsions and suspensions were injected i.d. into the footpad (FP) located just distal to the hock. This was done by passing the needle proximally through the skin of the plantar FP and then engaging the needle point into the dermis of the FP area mentioned. The dermis of the FP in this area is relatively thick; consequently reliable i.d. injections can be made. A 0.1-ml volume was injected in all cases. If done correctly, marked blanching and swelling of the FP occurred as the preparation was injected. Plastic tuberculin syringes equipped with 25-gauge needles were used. The FP was thoroughly cleansed with 70% ethanol before injection. Both right and left FP were injected in all cases.

Measurement of FP. FP thickness was measured with a Schnell-Taster (Systems Kröplin, Schlüchtern, Germany) at various intervals after injection. Base-line measurements before injection (day 0) were always made to assure uniformity of groups. The standard error of the mean was determined for the number of animals per group by taking the average of the right and left FP measurements for each animal.

Measurement of lymph node weight. Popliteal lymph nodes draining injected FP were removed, dissected free of adipose tissue, and immersed in saline. Before weighing, nodes were blotted on saline-dampened gauze to remove excess moisture.

Assessment of DH. Guinea pigs were skin tested on shaven flanks by i.d. injection of purified protein derivative (PPD) (National Institutes of Health research material, 30,000 tuberculin units [TU] per mg). Skin test sites were always observed at 2 to 3 h

for immediate reactions and at 24 h for DH. Positive reactions were recorded as diameter in millimeters of induration.

Assessment of serum antibodies. Sera from guinea pigs were assayed for antituberculo-protein and antituberculo-polysaccharide antibodies by passive hemagglutination using methods previously described (14).

Passive immunization. Peritoneal exudate (PE) cells, induced by intraperitoneal injection of 20 ml of sterile light mineral oil 1 week previously, were removed aseptically, pooled, and washed three times in Hanks balanced salt solution. Viable cells, as determined by trypan blue exclusion, were counted in a hemocytometer, and the original cell suspension was adjusted to contain 1.3×10^8 cells per ml. One milliliter of cell suspension was transfused into recipient animals by intracardiac injection with a 23-gauge needle. Care was taken to place the needle in the left ventricle so as to avoid pulmonary embolization.

A pool of sera from donor guinea pigs was used for passive transfer. Each recipient received 3 ml of undiluted serum by intracardiac injection.

RESULTS

Inflammatory response at the site of injection and draining lymph node. It had been observed that BCG CW-O produced a chronic inflammatory reaction at the site of injection in guinea pig skin (8). This was associated with regional lymphadenopathy. To study the course of development and intensity of this response, the FP dermis was used as the site of injection since increasing thickness from inflammation could readily be measured. Moreover, the lymphatic drainage is first, to a single lymph node, the popliteal node, and this structure could serve as a convenient source to observe the regional inflammatory response.

A group of eight guinea pigs received i.d. injections of BCG CW-O, 150 μ g, in each hind FP. A comparable control group was treated in the same manner with TS-O, the oil concentration being the same as in the BCG CW-O preparation (1.5%). FP thickness was measured at frequent intervals in these two groups. In Fig. 1 these measurements are plotted against time. The initial points on day 0 are measurements before injection.

During the first 4 days after injection the FP thickness increased and then subsided. This was seen in both BCG CW-O and TS-O groups and is a result of the acute inflammation caused by trauma of injection, oil, and BCG CW. On day 6 a striking increase in FP thickness took place in the BCG CW-O-injected group. Grossly, the FP were erythematous and febrile. The increased FP thickness on day 6 is highly significant ($P < 0.001$ comparing BCG CW-O group to the TS-O group by Student's t

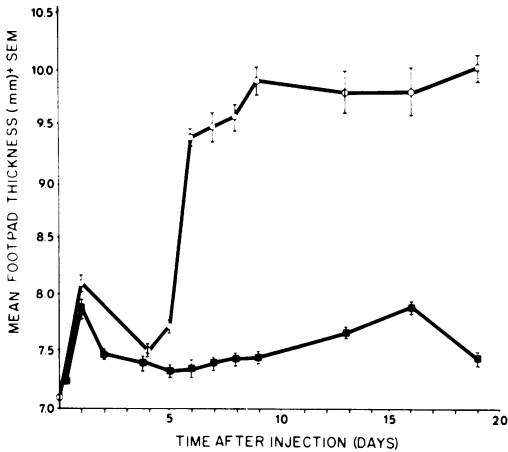


FIG. 1. Inflammatory response following injection of BCG CW-O. Two groups of eight guinea pigs received either BCG CW-O, 150 µg (○), or TS-O (■) i.d. in each hind FP. Each point represents measurements of the same eight pigs on the days shown. Day 0 points were determined before injection.

test). By day 10 the inflammatory response reached a plateau, which was maintained through day 19.

All animals in both groups were skin tested on day 19 with PPD, 300 TU. The BCG CW-O-treated group showed typical DH reactions to tuberculin. There were no immediate (2 to 3 h) skin reactions seen, and none of the animals in the TS-O group showed skin reactivity.

The BCG CW-O-induced inflammatory response was shown to be dose dependent (Fig. 2). Varying amounts of BCG CW-O were injected i.d. in groups of six guinea pigs by making dilutions from an initial emulsion containing 450 µg/0.1 ml. TS was used as diluent. The temporal sequence of the onset and development of the chronic inflammatory response was the same for doses ranging from 50 to 450 µg per hind FP. However, the intensity as measured by the degree of increased FP thickness was clearly dose related. The lowest dose (17 µg) produced a weak and late developing reaction. By day 14 FP necrosis was grossly evident in guinea pigs injected with 450 and 150 µg of BCG CW-O. This did not occur in animals given lower doses.

Four groups of nine guinea pigs were given FP injections of varying amounts of BCG CW-O. One group of nine animals receiving TS-O served as controls. At 2, 7, and 14 days after injection three animals in each group were sacrificed and their popliteal lymph nodes were removed and weighed. The results as seen in Fig. 3 showed again a dose-dependent reaction that was absent at 2 days but was well devel-

oped by 7 days after injection. Unlike the FP reaction, which persisted unabated for at least 3 weeks, the lymphadenopathy declined by 2 weeks after injection.

Histopathology of inflammatory response in FP and regional lymph nodes. A group of guinea pigs was injected with BCG CW-O, 150 µg, in each hind FP. At various times after injection animals were sacrificed and tissue samples of the FP and popliteal lymph nodes

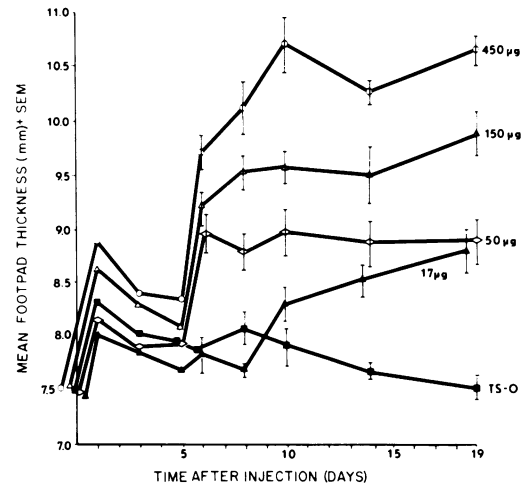


FIG. 2. Inflammatory response after injection of BCG CW-O: effect of graded doses. Groups of six guinea pigs received varying doses of BCG CW-O i.d. in each hind FP. The doses were prepared by making threefold dilutions from an original emulsion containing BCG CW-O, 450 µg/0.1 ml, using TS as diluent.

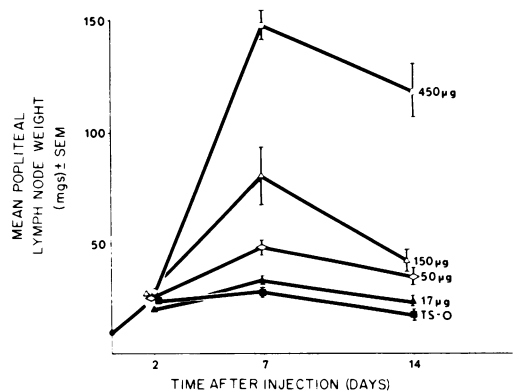


FIG. 3. Inflammatory response in draining lymph nodes after injection of BCG CW-O. Groups of nine guinea pigs received varying doses of BCG CW-O i.d. in each hind FP. On the days shown three animals in each group were sacrificed and lymph node weights were determined. Day 0 point represents a group of three uninjected guinea pigs.

were processed for histological examination. A group of control animals injected with TS-O served for base-line comparison.

At 3 days after injection there was a moderate acute inflammatory process in the FP dermis. This was composed mainly of polymorphonuclear leukocytes and lesser numbers of macrophages and lymphocytes. At this time the popliteal lymph node showed evidence of a lymphoproliferative response primarily in the paracortical areas.

Seven and 14 days after injection the FP dermis was grossly thickened. As shown microscopically in Fig. 4, this was due to a dense infiltrate of macrophages with large vesicular nuclei and indistinct cytoplasmic borders. These cells are so numerous as to form a monotonous pattern throughout the dermis. In addition, scattered lymphocytes and some polymorphonuclear leukocytes are seen. By 14 days after injection necrosis had occurred in the FP dermis. There was breakdown of the overlying epidermis and drainage of some of the necrotic material outward.

This same accumulation of macrophages occurred in popliteal lymph nodes at 7 and 14 days after injection where extensive infiltration of these cells was seen in the medulla and cortex (Fig. 5). This was associated with mitotic activity of reticuloendothelial cells lining the lymph node sinuses. Necrosis did not occur in the regional lymph node with this dose of BCG CW-O (150 μ g). However, in other experiments using higher doses of BCG CW-O (1 mg), necrosis occurred.

These findings are essentially the same as those reported for viable BCG infection of guinea pig (13) and rabbit (3) skin, as well as for infection of established intracutaneous tumors in guinea pigs (5). This is a granulomatous inflammatory response characteristic of mycobacterial infections of various tissues in the host.

Correlation of FP granulomatous reaction and DH. There is strong evidence that allergic granulomas occur as a result of DH (6, 15, 16). This being so, one would expect an association between the time course of development of DH to BCG CW antigens and development of the FP granulomatous reaction. As shown in Fig. 6, this was indeed the case. When separate groups of animals injected with BCG CW-O in the FP were skin tested with PPD at time intervals thereafter, it was seen that significant tuberculin DH (bar graphs) was first observed on day 5, the day during which the greatest FP swelling occurred. Thus, just as the DH reaction to tuberculin developed over a 24-h period and reached maximum intensity in 24 to

48 h, so did the FP response, and at the same time after injection required for the animal to develop systemic DH. No immediate hypersensitivity skin reactions to PPD were observed.

There was no correlation between the development of the FP granulomatous response and antibody production to tuberculoprotein or tuberculopolysaccharide CW antigens. Sera from separate groups of three guinea pigs were collected 10, 20, and 28 days after i.d. immunization with BCG CW-O, 150 μ g, in each hind FP. Listed in Table 1 is the range of antibody titers obtained using passive hemagglutination. No tuberculoprotein antibodies were detected and antibodies against tuberculopolysaccharide appeared in the serum (day 28) long after the development of the local inflammatory reaction (day 6). However, this does not rule out much earlier local antibody production or a humoral response to CW antigens not tested for here.

Response to BDG CW without mineral oil. It was of interest to examine the local tissue response to BCG CW without mineral oil since it had been shown that, in the absence of oil, BCG CW had no antitumor effect when injected with tumor cells intracutaneously in guinea pigs (18). A TS suspension of BCG CW was injected i.d. in each hind FP (150 μ g/FP) of six guinea pigs. A comparable group received the same dose of BCG CW-O. As shown in Fig. 7, BCG CW in TS provoked an inflammatory reaction at the site of injection as measured by increasing FP thickness. The time course of this response was similar to that produced by BCG CW-O, and in addition tissue sections from similarly treated animals revealed a histological picture identical to that described for BCG CW-O. It is apparent from Fig. 7 that without mineral oil the granulomatous response is less intense as gauged by absolute FP thickness and, in addition, begins to recede at a time when the response to BCG CW-O remains strong. This was also the case for the response in the draining lymph node (not shown). The development of lymphadenopathy as a result of granulomatous adenitis induced by BCG CW in TS followed the same time sequence as shown in Fig. 3; however, the popliteal node weights were significantly less than with the same dose of BCG CW-O.

Table 2 shows that guinea pigs immunized with BCG CW in TS developed DH to PPD similar to BCG CW-O-immunized animals, although in general skin reaction diameters were smaller. The presence of mineral oil had an effect on the humoral immune response to tuberculopolysaccharide antigens in that without oil antibody titers were lower (Table 1 versus Table 2).

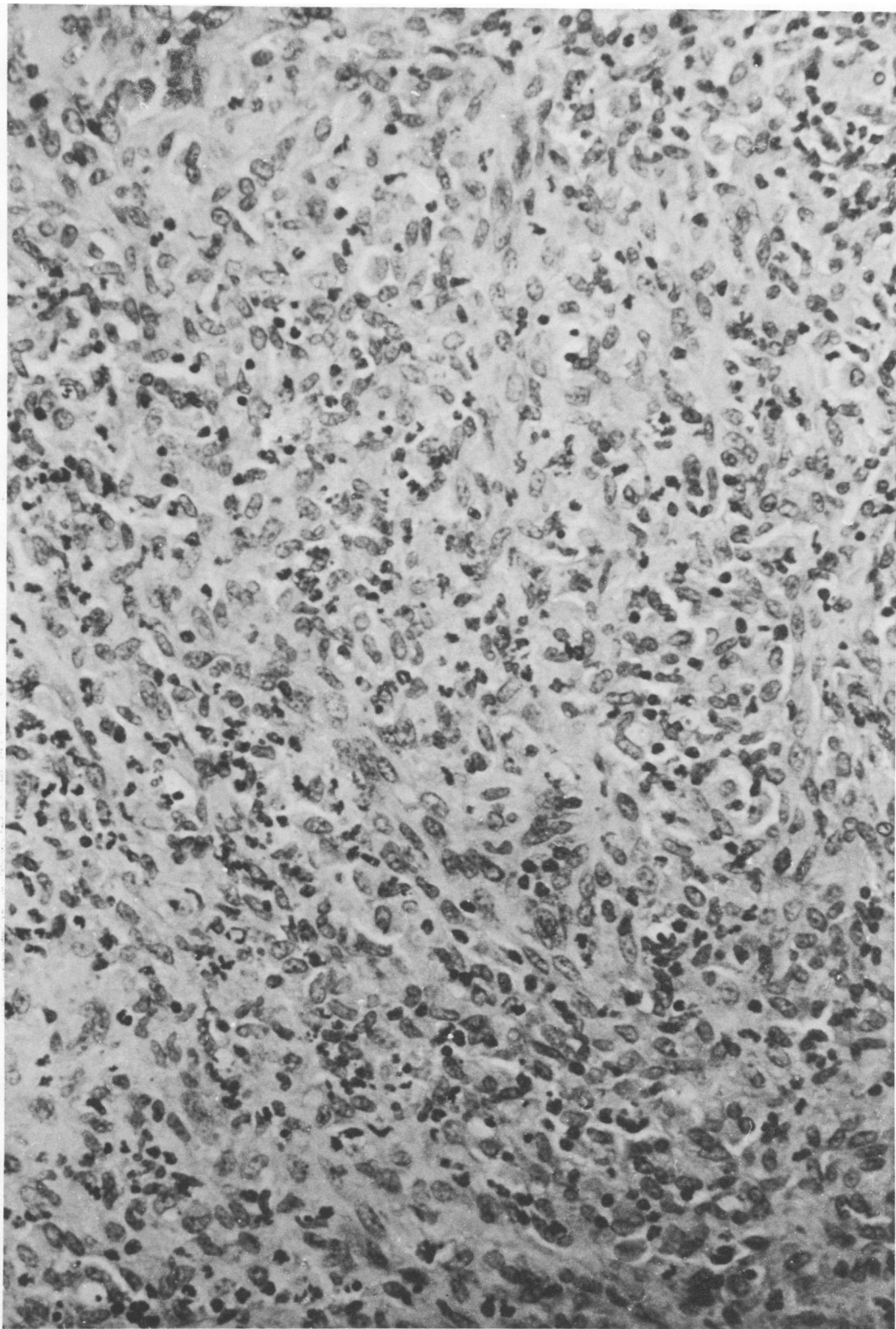


FIG. 4. Granulomatous response in FP after injection of BCG CW-O, 150 μg , i.d. in each hind FP. An extensive macrophage infiltrate with scattered lymphocytes and polymorphonuclear leukocytes is seen 14 days after injection. Hematoxylin and eosin stain, $\times 240$.

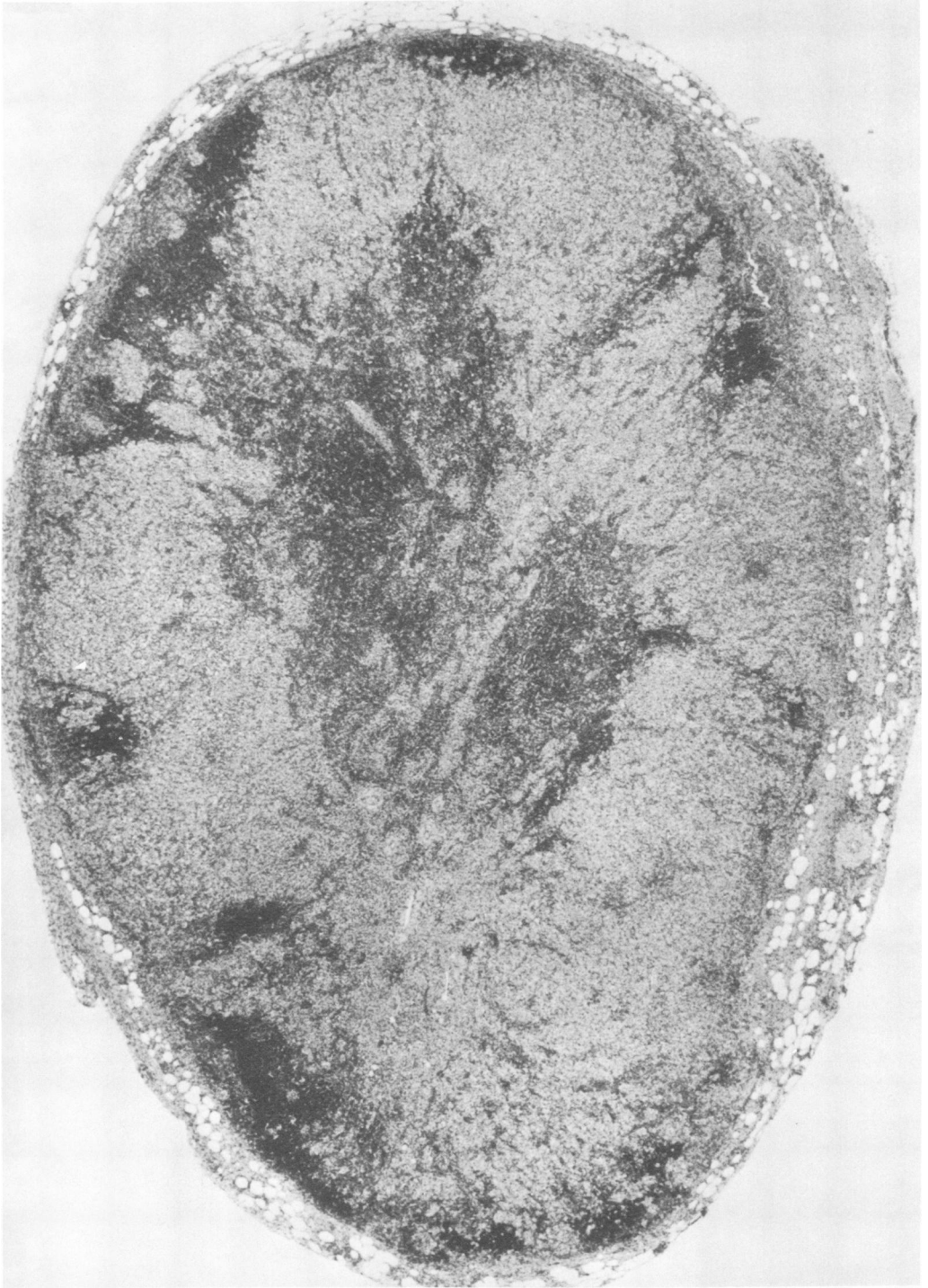

FIG. 5. Granulomatous response in popliteal lymph node after injection of BCG CW-O, 150 μ g, i.d. in each hind FP. Much of the node has been replaced with a pale staining macrophage infiltrate. Hematoxylin and eosin stain, $\times 30$.

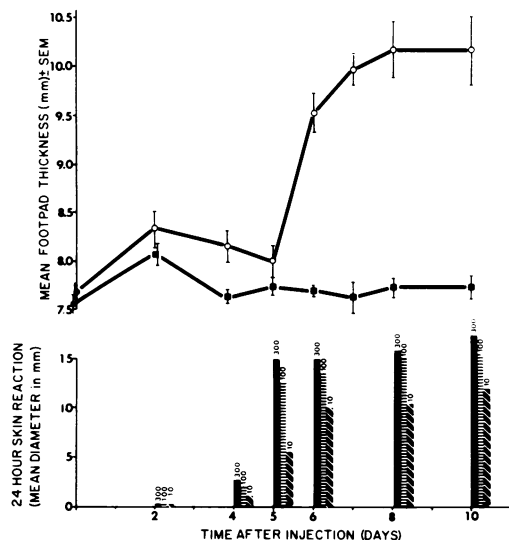


FIG. 6. Correlation between FP granulomatous response and development of DH to PPD. Two groups of six guinea pigs received either BCG CW-O, 150 μ g (\circ), or TS-O (\blacksquare) i.d. in each hind FP. Bar graphs show DH to PPD in additional separate groups of four guinea pigs skin tested on the days shown after injection of BCG CW-O, 150 μ g, i.d. in each hind FP. Each animal was skin tested with 300, 100, and 10 TU. Six guinea pigs injected with TS-O and skin tested with PPD on day 10 gave negative reactions. There were no immediate hypersensitivity reactions.

TABLE 1. Passive hemagglutination antibody titers to cell wall antigens after immunization of guinea pigs with BCG CW-O^a

Days after immunization	Range of antibody titers to: ^b	
	Tuberculoproteins	Tuberculopolysaccharides
10	0	0
20	0	0
28	0	0-512

^a BCG CW-O, 150 μ g, was injected i.d. in each hind FP of nine guinea pigs. Three animals were sacrificed on the days shown and serum from each animal was tested against both antigens.

^b Reciprocal of highest dilution giving positive passive hemagglutination. Positive control consisted of a known rabbit anti-BCG CW serum tested against each antigen. Negative controls consisted of normal guinea pig serum tested against each antigen and unsensitized sheep erythrocytes tested with the lowest dilution of each serum sample.

FP granulomatous reaction in previously immunized animals. Presumably the interval between the injection of BCG CW-O and the onset of the local granulomatous response (5 days) is the time required for the guinea pig to become sensitive to CW antigens. Were the

animals previously sensitized to BCG CW-O, then the FP response should occur promptly without a latent period.

A group of 10 guinea pigs was injected with BCG CW-O, 150 μ g, i.d. on each flank. Seven

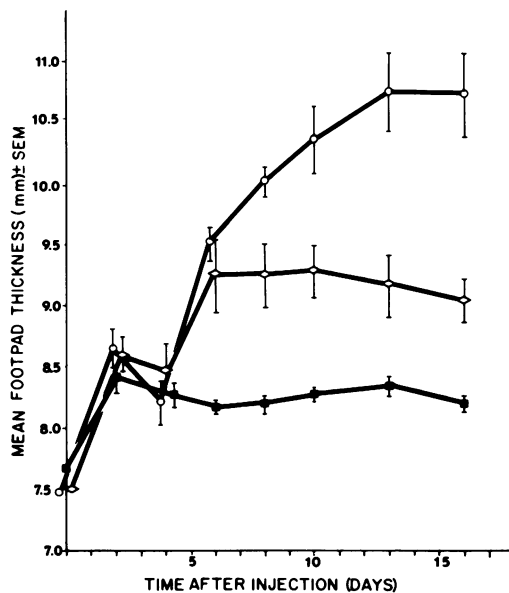


FIG. 7. FP granulomatous response after injection of BCG CW without mineral oil. Groups of six guinea pigs received BCG CW suspended in TS, 150 μ g (\diamond); BCG CW-O, 150 μ g (\circ); or TS-O (\blacksquare) i.d. in each hind FP.

TABLE 2. Delayed hypersensitivity to PPD and passive hemagglutination antibody titers to cell wall antigens after immunization of guinea pigs with a TS suspension of BCG CW^a

Days after immunization	24-h skin reaction (mean diameter in mm) ^b	Range of antibody titers to: ^c	
		Tuberculoproteins	Tuberculopolysaccharides
2	0	ND ^d	ND
6	6.0	ND	ND
8	10.8	ND	ND
10	9.5	0	0
20	13.8	0	0
28	12.5	0	0-8

^a A 0.1-ml TS suspension of BCG CW, 150 μ g/0.1 ml, was injected i.d. into each hind FP of 18 guinea pigs. Serum samples for passive hemagglutination were obtained from separate groups of three animals on the days shown before applying skin tests.

^b Three guinea pigs were skin tested with PPD, 300 TU, on days shown. No immediate hypersensitivity reactions were observed.

^c See footnote b, Table 1.

^d ND, Not done.

days later half of these animals received BCG CW-O, 75 μg , i.d. in each hind FP, and the other half received TS-O in the same manner. Five guinea pigs injected i.d. on each flank with TS-O 7 days previously were given BCG CW-O, 75 μg , i.d. in each hind FP. The lower dose of BCG CW-O was used because it produced less of an acute inflammatory response in the few days after injection. The FP response to BCG CW-O in previously immunized guinea pigs was evident at 24 h after injection (Fig. 8) and persisted through the period of observation. The early course did not resemble the acute inflammatory reaction seen in unimmunized animals in that there was no defervescence and FP thickness was maintained at a significantly higher level. This accelerated inflammatory reaction was unlike tuberculin-type DH because it was long lived and a focal chronic lesion was produced (Koch phenomenon).

As seen previously, the FP response to BCG CW-O in unimmunized guinea pigs did not begin until after day 5 (Fig. 8). The effect pro-

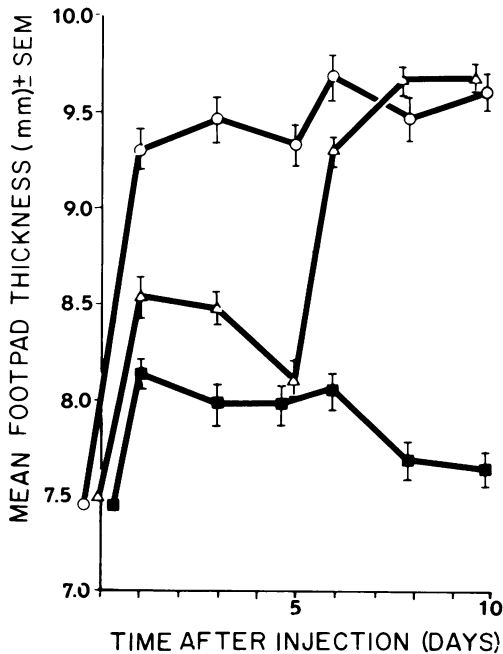


FIG. 8. FP granulomatous response in previously immunized animals. Symbols: (○) BCG CW-O, 150 μg , i.d. in each flank 7 days before injection of BCG CW-O, 75 μg , i.d. in each hind FP; (△) TS-O i.d. in each flank 7 days before injection of BCG CW-O, 75 μg , i.d. in each hind FP; (■) BCG CW-O, 150 μg , i.d. in each flank 7 days before injection of TS-O i.d. in each hind FP. The curves begin on the day of FP injections, the first measurements being taken before the injections.

duced by preimmunization did not depend on previous exposure to mineral oil droplets since animals injected i.d. with TS-O 7 days before FP injection with BCG CW-O developed the local response in the same fashion as animals treated for the first time with BCG CW-O (Fig. 8).

Specificity of accelerated granulomatous reaction. The effect of previous immunization was shown to be specific. A heterologous granulomagenic preparation (Q fever rickettsia vaccine) was used. Two groups of five guinea pigs were immunized with either BCG CW-O, 150 μg , or Q fever vaccine, 240 μg , i.d. in each flank. After 2 weeks these animals plus five unimmunized guinea pigs received i.d. injections of BCG CW-O, 75 μg , in each hind FP. As shown in Fig. 9, the accelerated FP response was produced only in animals previously immunized with the homologous preparation (BCG CW-O). The reverse experiment (not presented here) showed that guinea pigs immunized with Q fever vaccine and injected with this material in the FP 14 days later developed an accelerated response. This was not the case for animals previously immunized with BCG CW-O and injected with Q fever vaccine in the FP.

This same protocol was used to examine the accelerated response in guinea pigs previously immunized with CW from a different mycobacterial species (*M. ulcerans*). Interestingly, although there was definite cross-reactivity (Fig. 10), the accelerated response in animals immunized with *M. ulcerans* waned after 2 days only to resurge on day 6, as seen in animals not previously immunized.

Accelerated granulomatous reaction in guinea pigs passively immunized with cells. As we have seen, the FP granulomatous response to BCG CW-O correlated with the development of DH to PPD. The accelerated response in animals previously injected with BCG CW-O suggested that this inflammatory response is immunologically mediated rather than nonallergic foreign body-type granulomatous reaction. To directly examine the type of immunity involved in this reaction, passive immunization was used. Inbred strain 2 guinea pigs were given either BCG CW-O, 150 μg , or TS-O i.d. in four weekly injections. The inoculation sites were shifted from bilateral flanks to both hind FP, to both front FP, and repeated on both flanks. One week after the last immunization 20 ml of sterile light mineral oil was injected intraperitoneally in each animal and into a group of unimmunized strain 2 guinea pigs. One week after oil injection PE cells and sera

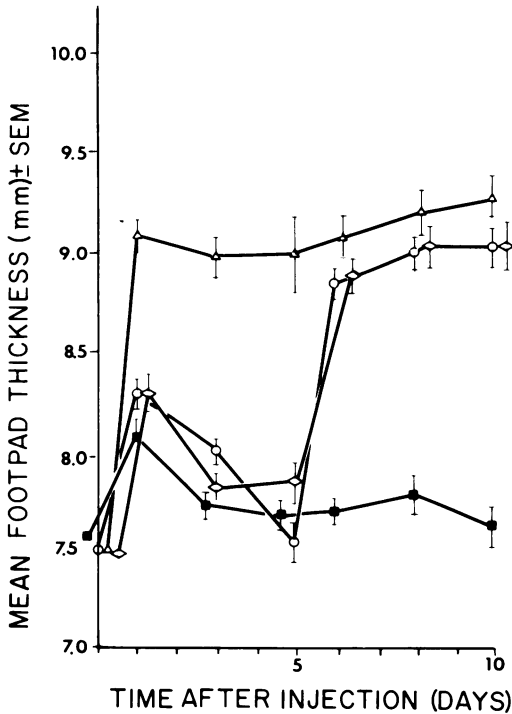


FIG. 9. Specificity of accelerated granulomatous response. Symbols: (Δ) BCG CW-O, 150 μ g, i.d. in each flank 14 days before injection of BCG CW-O, 75 μ g, i.d. in each hind FP; (\diamond) Q fever vaccine, 240 μ g, i.d. in each flank 14 days before injection of BCG CW-O, 75 μ g, i.d. in each hind FP; (\circ) BCG CW-O, 75 μ g, i.d. in each hind FP; (\blacksquare) TS-O i.d. in each hind FP. All FP injections were made on the same day.

were recovered and transfused into normal syngeneic recipients. One day after transfusion, the recipient animals were inoculated with BCG CW-O, 75 μ g, or TS-O as described in Fig. 11. Animals transfused with PE cells from hyperimmunized donors made an accelerated FP granulomatous response. Recipients transfused with normal PE cells or hyperimmune serum developed the now familiar day-6 reaction characteristic of unimmunized animals. Oil droplets had no effect either in stimulating the response in FP of animals which had received immune cells (Fig. 11) or in immunizing guinea pigs as a source of donor cells (not shown). In two other experiments we were unable to passively immunize with comparable numbers of PE cells from donors which had received just one i.d. immunization of BCG CW-O. Since passively immunized animals developed accelerated granulomas just 2 days after transfusion, it is unlikely that immunogen (BCG CW-O), which

could possibly have been transferred with cells, provided the immunizing stimulus.

DISCUSSION

In this study the inflammatory response to i.d. injection of BCG CW-O was studied. When the site of injection was the FP, the resulting inflammatory response at that focus was followed by repeated measurements of FP thickness. This method distinguished different intensities of FP inflammation depending on the amount of BCG CW-O injected. The use of FP thickness measurements was most helpful, however, in following the time course of the inflammatory response. This was characterized by two phases. First, an acute inflammatory reaction occurred in the first few days after injection. This was followed by an intense chronic process which began abruptly during the 24-h period between days 5 and 6 and persisted for weeks. This chronic inflammation was characterized histologically as a granulomatous response, the paramount feature of which was the accumulation of numerous macrophages at the site of injection.

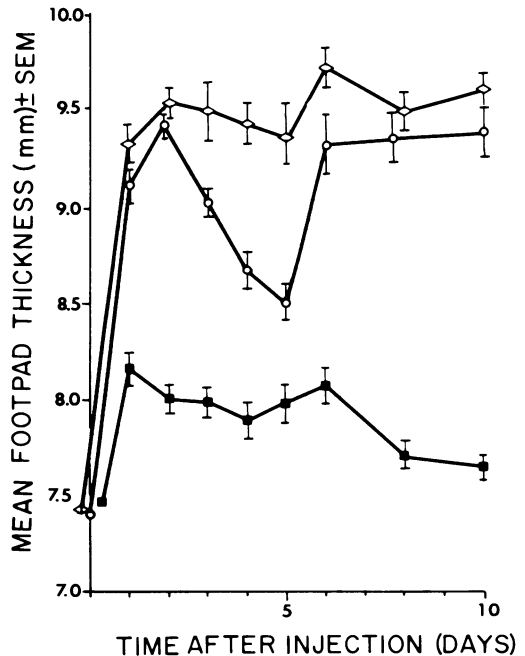


FIG. 10. Cross-reactivity between BCG CW and *M. ulcerans* CW. Symbols: (\diamond) BCG CW-O, 150 μ g, i.d. in each flank 14 days before injection of BCG CW-O, 75 μ g, i.d. in each hind FP; (\circ) *M. ulcerans* CW-O, 150 μ g, i.d. in each flank 14 days before injection of BCG CW-O, 75 μ g, i.d. in each hind FP; (\blacksquare) TS-O i.d. in each hind FP.

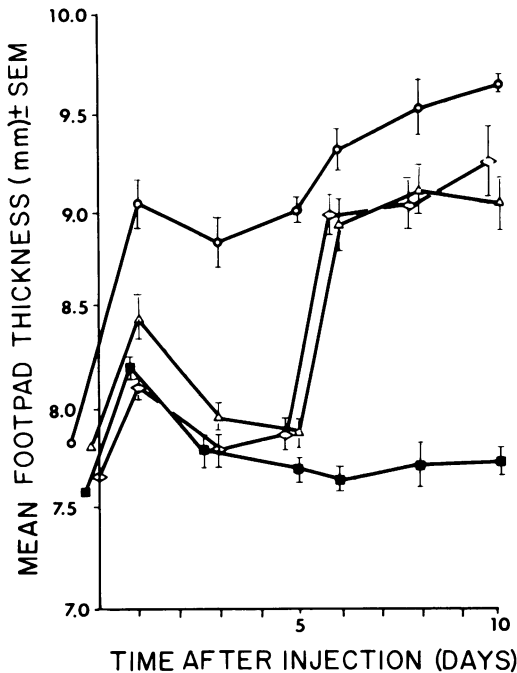


FIG. 11. Accelerated granulomatous response following passive immunization. Symbols: (O) transfused with PE cells from BCG CW-O-immunized guinea pigs 24 h before injection of BCG CW-O, 75 μ g, i.d. in each hind FP; (◇) transfused with serum from BCG CW-O-immunized guinea pigs 24 h before injection of BCG CW-O, 75 μ g, i.d. in each hind FP; (△) transfused with PE cells from normal guinea pigs 24 h before injection of BCG CW-O, 75 μ g, i.d. in each hind FP; (■) transfused with PE cells from BCG CW-O-immunized guinea pigs 24 h before injection of TS-O i.d. in each hind FP.

The granulomatous response also occurred in the lymph node draining the injection site and was present 7 days after injection. Lymph node weight proved to be a satisfactory measure of the regional response. The degree of lymphadenopathy was dose dependent and showed a time course similar to the FP response except that the granulomatous response in the popliteal node began to wane at a time (day 14) when FP inflammation remained intense. Also necrosis occurred in the FP but not the popliteal node in animals given a dose of 150 μ g of BCG CW-O per FP.

These findings are similar to those reported for intracutaneous injection of viable BCG in guinea pigs (13).

An important component of the cell wall immunogen was mineral oil. In this system an oil-in-water emulsion was used. This consisted of microscopic oil droplets containing fragments of BCG CW. Without mineral oil, BCG CW had little or no granulomagenic effect in mice (1)

and no antitumor effect in guinea pigs (17). In this study BCG CW in TS induced a weak but definite granulomatous response in the guinea pig FP and draining lymph node. This was associated with the development of DH to PPD. Thus, essentially the same type of response occurred to BCG CW with and without oil. The main difference appeared to be quantitative. That is, a more intense and longer lasting inflammatory reaction was seen when BCG CW were associated with mineral oil droplets. One important effect of mineral oil may be to maintain BCG CW at the site of injection and in the regional lymph nodes (2). This would result in a continuing stimulus at these local sites, leading to chronic inflammation. The nonmetabolizable nature of mineral oil in part may account for the persistence of dead mycobacteria in host tissues (4).

The results presented here indicate that the granulomatous response to BCG CW-O in the guinea pig FP is a hypersensitive rather than foreign body granuloma. Guinea pigs previously exposed to BCG CW-O, upon reinjection, developed an accelerated response in their footpads. This is similar to the findings of Myrvik et al., who studied the same reaction to whole killed mycobacteria in rabbit lung (9). Our results showed that the accelerated response was specific for the sensitizing preparation when a phylogenetically unrelated microorganism (*Q* fever rickettsia) was used for comparison (Fig. 9). In animals immunized with cell walls from another mycobacterium (*M. ulcerans*), cross-reaction occurred upon FP injection of BCG CW-O. This response, however, was evanescent and was more like a tuberculin DH reaction. Perhaps the cross-reacting antigens in *M. ulcerans* CW did not persist in the FP dermis and hence the local antigenic stimulus was lost. We observed a similar phenomenon when cross-reacting protein-containing lipopolysaccharides from gram-negative bacteria were injected i.d. into hypersensitive guinea pigs (K. Yamamoto, unpublished data).

Granuloma formation in the lung has been effectively studied in experimental systems using trematode eggs (16) and inert particles (Sephacrose and polyacrylamide beads) coated with protein antigens (6, 15). Results from these studies present the convincing thesis that hypersensitivity granulomas are a histopathological expression of a fundamental immunological process, namely DH. Results presented here are in agreement. The onset of the FP granulomatous response to BCG CW-O correlated exactly with the acquisition of DH to tuberculo proteins (Fig. 6), and, during the course of this chronic inflammation, guinea pigs main-

tained DH at a high level. The accelerated response occurred in guinea pigs passively immunized with PE cells from BCG CW-O-sensitized donors but not with serum from these same donors. Thus, an important criterion for a cell-mediated immune response was fulfilled.

Two characteristics of the granulomatous response induced by BCG CW-O would appear to be particularly relevant with regard to antitumor effects after direct injection into a neoplasm. First is the relatively short time between injection and onset of the response coupled with the rapidity with which maximum intensity is obtained. If the granulomatous reaction was late to occur and developed slowly, tumor growth might advance beyond a stage of susceptibility to tumoricidal mechanisms. Second is the chronicity of the granulomatous reaction produced by BCG CW-O. This would allow for a continued flux of activated macrophages to the tumor site over a period of weeks. This may be germane for therapy of an established vascularized tumor where, because of the sizable tumor burden, complete elimination requires considerable time. It remains to be seen if this type of evaluation will be predictive for determining whether microbial preparations or fractions have immunotherapeutic value.

ACKNOWLEDGMENTS

We thank James Kyle for excellent technical assistance. BCG cell walls were kindly supplied by Reno Parker, Hamilton Biochemical Research Laboratory, Hamilton, Mont., under contract number N01-CP-45609 from the National Cancer Institute.

LITERATURE CITED

1. Barclay, W. R., R. Anacker, W. Brehmer, and E. Ribi. 1967. Effects of oil-treated mycobacterial cell walls on the organs of mice. *J. Bacteriol.* 94:1736-1745.
2. Champlin, R., and R. L. Hunter. 1975. Studies on the composition of adjuvants which selectively enhance delayed-type hypersensitivity to lipid conjugated protein antigens. *J. Immunol.* 114:76-80.
3. Dannenberg, A. M., Jr., O. T. Meyer, J. R. Esterly, and K. Takeshi. 1968. The local nature of immunity in tuberculosis, illustrated histochemically in dermal BCG lesions. *J. Immunol.* 100:931-941.
4. Freund, J. 1956. The mode of action of immunologic adjuvants. *Adv. Tuberc. Res.* 7:130-148.
5. Hanna, M. G., Jr., B. Zbar, and H. J. Rapp. 1972. Histopathology of tumor regression after intraleisional injection of *Mycobacterium bovis*. I. Tumor growth and metastases. *J. Natl. Cancer Inst.* 48:1441-1455.
6. Kasdon, E. J., and S. F. Schlossman. 1973. An experimental model of pulmonary arterial granulomatous inflammation. *Am. J. Pathol.* 71:365-374.
7. Larson, C. L., E. Ribi, W. Wicht, and R. List. 1961. Skin reactions produced in rabbits by cell walls and protoplasm of *Mycobacterium tuberculosis* and *M. butyricum*. *Am. Rev. Respir. Dis.* 83:184-193.
8. Meyer, T. J., E. Ribi, and I. Azuma. 1975. Biologically active components from mycobacterial cell walls. V. Granuloma formation in mouse lungs and guinea pig skin. *Cell. Immunol.* 16:11-24.
9. Myrvik, Q. M., E. S. Leake, and S. Oshima. 1962. A study of macrophages and epithelioid-like cells from granulomatous (BCG-induced) lungs of rabbits. *J. Immunol.* 89:745-751.
10. Rapp, H. J. 1973. A guinea pig model for tumor immunology: a summary. *Isr. J. Med. Sci.* 9:366-374.
11. Ribi, E., R. L. Anacker, W. Brehmer, G. Goode, C. L. Larson, R. List, K. C. Milner, and W. C. Wicht. 1966. Factors influencing protection against experimental tuberculosis in mice by heat-stable cell wall vaccines. *J. Bacteriol.* 92:869-879.
12. Ribi, E., C. L. Larson, R. List, and W. Wicht. 1958. Immunologic significance of the cell wall of mycobacteria. *Proc. Soc. Exp. Biol. Med.* 98:263-265.
13. Rosenthal, S. R. 1937. Studies with BCG. IV. The focal and general tissue response and the humoral response; the intradermal route. *Am. J. Dis. Child.* 54:296-321.
14. Takahashi, Y., T. Onodera, and K. Yamamoto. 1961. The behavior of three different kinds of antibodies in tuberculosis: antiprotein, antipolysaccharide and antiphosphatide. I. Experimental tuberculosis. *J. Exp. Med.* 114:555-567.
15. Unanue, E. R., and B. Benacerraf. 1973. Immunologic events in experimental hypersensitivity granulomas. *Am. J. Pathol.* 71:349-364.
16. Warren, K. S., E. O. Domingo, and R. B. T. Cowan. 1967. Granuloma formation around schistosome eggs as a manifestation of delayed hypersensitivity. *Am. J. Pathol.* 51:735-756.
17. Zbar, B., H. J. Rapp, and E. E. Ribi. 1972. Tumor suppression by cell walls of *Mycobacterium bovis* attached to oil droplets. *J. Natl. Cancer Inst.* 48:831-835.
18. Zbar, B., E. Ribi, and H. J. Rapp. 1973. An experimental model for immunotherapy of cancer. *Natl. Cancer Inst. Monogr.* 39:3-6.