

## Electron Microscope Study of Experimental Enteric Adenovirus Infection in Mice

AKIO TAKEUCHI\* AND KAZUO HASHIMOTO

*Department of Experimental Pathology, Walter Reed Army Institute of Research, Washington, D.C. 20012,\*  
and Department of Microbiology, Tokai University School of Medicine, Kanagawa, Japan*

Received for publication 30 September 1975

Using fluorescent antibody techniques (FA) and light microscopy (LM) and electron microscopy (EM), this paper describes the morphological features of the ileum in the DK1 mouse orally challenged with adenovirus K87. At the peak of infection, virus is easily identified by FA in the epithelium of the villi and crypts of the ileum. LM shows that fluorescent cells have large, bizarre, uniformly basophilic nuclei containing deoxyribonucleic acid, as indicated by histochemical tests. EM further identifies these nuclei as belonging to columnar, goblet, or Paneth cells, all epithelial cells facing the lumen with a microvillus border. The basophilic material in the nuclei consists of virus particles 75 nm in diameter arranged in crystalline arrays. When found in the cell cytoplasm, the virions do not form arrays but are scattered or form irregular aggregates, which may or may not be enclosed by single membranes. Infected columnar cells show mild cytopathic effects with no cell degeneration and necrosis, whereas the goblet and Paneth cells appear normal and maintain synthetic and secretory functions. All infected cells, however, share an abnormally accelerated extrusion rate, with columnar and goblet cells often being shed from the side rather than from the tip of the villi. The Paneth cells, which do not migrate out of the crypts, show a higher than normal rate of extrusion in the crypt lumen.

The physicochemical, pathogenic, and oncogenic aspects of adenovirus-host cell interaction have been well studied in *in vitro* systems. Yet little is known about adenovirus-host cell interactions *in vivo* (15). In particular, we lack information concerning virus tissue tropisms and the histopathological aspects of adenovirus infections in the digestive tract.

Adenovirus strain K87 (8-10), originally isolated and identified by Hashimoto and his colleagues from the feces of a healthy inbred mouse, strain DK1 (28), grows well in mouse kidney tissue culture (9). Either oral or parenteral administration of K87 to mice results in replication of the viral antigens exclusively in the bowel but produces no symptoms in the infected animals (19). When DK1 mice are orally infected with suspension of K87 grown in mouse kidney culture cells, viral antigens start to increase at 3 days and reach a maximum between 7 and 14 days after infection (10). At the height of the viral replication in the gut, numbers of virally infected cells are found in the epithelial lining of the distal small intestine; this has made feasible electron microscope observations on the adenovirus-host cell interaction *in vivo*.

The present paper describes morphological features of an experimental enteric infection of the DK1 mouse, inoculated orally with mouse adenovirus strain K87, as observed by the fluorescent antibody (FA) technique and by light microscopy (LM) and electron microscopy (EM). In particular, it establishes the small intestinal epithelial cells as the site of replication of the structural antigen of K87 adenovirus.

### MATERIALS AND METHODS

**Mice.** Fifty-eight mice used in this experiment were 4-week-old, inbred strain DK1, white mice (28), caged individually and allowed access to food and water *ad libitum*. Of these, 46 animals were experimentally infected and the remaining 12 were used as noninfected controls.

**Virus.** Mouse adenovirus strain K87, isolated by Hashimoto (9), was used. The virus suspensions were prepared from freeze-thawed mouse kidney tissue cultures infected with the virus after five to nine passages through mouse kidney tissue cultures, as described in detail elsewhere (19).

**Viral challenge.** The inoculum, 0.4 ml containing  $4 \times 10^5$  50% tissue culture infective doses, was administered orally to each mouse under ether anesthesia through a metal tube inserted into the stomach. The control inoculum was 0.4 ml of physiological saline (10).

**Tissue preparation.** At 5, 7, and 14 days after oral inoculation, groups of infected and control mice were anesthetized by ether, sacrificed by cervical dislocation, and necropsied in a conventional manner. A segment of the ileum was removed, divided into four portions, and processed as follows.

(i) **Viral isolation and titration.** For virus isolation, a 10% suspension of feces and a 5% suspension of the homogenized first portion of the ileum were made and titrated by procedures described in detail elsewhere (10).

(ii) **Direct FA.** A second portion of the ileum was opened longitudinally, rolled, and placed on a strip of paper in a test tube, which was held for 10 min in a mixture of ethanol and dry ice to freeze the tissue at  $-73^{\circ}\text{C}$ . The frozen tissues were sectioned in a cryostat, fixed, and treated with fluorescein-labeled mouse K87 virus antiserum. Preparations of the antiserum and the method of conjugation with fluorescein isothiocyanate have been described previously (10). Sections were examined under a Nikon fluorescence microscope, type SUR-F. The specificity of the FA staining was established by treating in the same fashion sections from uninoculated mice or by blocking the reaction in inoculated mice with a gamma globulin solution prepared from K87 immune serum. In both cases no fluorescence was seen.

(iii) **LM.** A third portion of the ileum was fixed in chilled 10% buffered neutral formalin and routinely processed for histological study. Paraffin sections were stained with one of the following stains: hematoxylin and eosin, periodic acid-Schiff, Giemsa, alcyon blue, or Feulgen. Thick 1- to 2- $\mu\text{m}$  sections of Epon-embedded material were stained with azure II-methylene blue.

(iv) **EM.** A fourth portion of ileum was minced, fixed in 2% glutaraldehyde in phosphate buffer for 2 h, and washed with phosphate buffer. The tissues were further fixed with 3.3% osmium tetroxide in S-collidine buffer. The details of the preparation of intestinal tissues for EM have been previously described (21, 22, 25). Ultrathin sections were examined by Hitachi 11C or RCA EM 3-G electron microscopes.

## RESULTS

**FA microscopy.** Observations on frozen sections of the ileum from infected mice, stained by FA techniques with serum immunized with K87 adenovirus, were essentially the same as those reported previously (10). Cells containing viral antigen were localized in the intestinal epithelium and absent in the lamina propria (Fig. 1). They appeared singly and were randomly distributed in both villi and crypts (Fig. 1 and 2). The viral antigen was seen as a round, or sometimes as an angular or crescent-shaped, mass, usually located at the base but occasionally close to the luminal surface of the epithelial lining. In many instances, the fluorescence appeared to be confined to the nucleus of epithelial cells.

**LM.** The ileum of control noninfected DK1

mice was essentially the same as that of mice of other strains. The ileal mucosa of infected DK1 mice examined at 5 and 7 days after oral challenge was indistinguishable from its counterpart in the control mice. In contrast, the ileum at 14 days postinfection showed significant changes, which included a decreased villus-crypt ratio and a moderately increased cellularity in the lamina propria (Fig. 3). However, there was no acute inflammation in the mucosa. The crypts were slightly distended and contained cellular debris (Fig. 4).

Paraffin sections stained with hematoxylin and eosin and carefully examined at magnifications of more than 300 revealed large, bizarre-shaped, homogeneously basophilic nuclei, which were sparsely distributed in the epithelial lining of both villi and crypts (Fig. 4). Some were oval or round; others were angular. Under oil immersion ( $\times 1,200$ ) they often showed several smaller, dense inclusions surrounded by less dense nucleoplasm. These inclusions were consistently Feulgen positive but periodic acid-Schiff negative, indicating the presence of deoxyribonucleic acid.

The enlarged nuclei in the infected ileal tissues were identified by LM more easily on Epon preparations than on paraffin sections; moreover, Epon sections revealed better structural details. The nuclei were round or oval or had an irregular perimeter (Fig. 5). The most common shape was oval, outlined by a distinct nuclear membrane with a lightly stained nucleoplasm, containing small dense granules often concentrated at the periphery (Fig. 5). The distribution of these granules, however, varied from one enlarged nucleus to another, and they could be also evenly distributed throughout the nucleoplasm.

Some enlarged nuclei were clearly located in columnar cells of the villus epithelium. It was not possible, however, at the LM level to recognize with certainty all the cell types in which these enlarged nuclei were located, especially in the crypt epithelium, which is closely populated by different types of cells.

**EM.** Ultrastructural studies confirmed the LM observations and provided further details. The fine structure of the small intestine of mice was similar to that of other mammals and has been described in detail (24). On the basis of their ultrastructural characteristics, intestinal epithelial cells could be divided into four types (27): columnar, goblet, Paneth, and argentaffin cells. Between the epithelial cells of both villi and crypts were thelial lymphocytes (23). The villi were covered predominantly by columnar cells between which mucus-secreting goblet cells were sparsely located, whereas the crypt

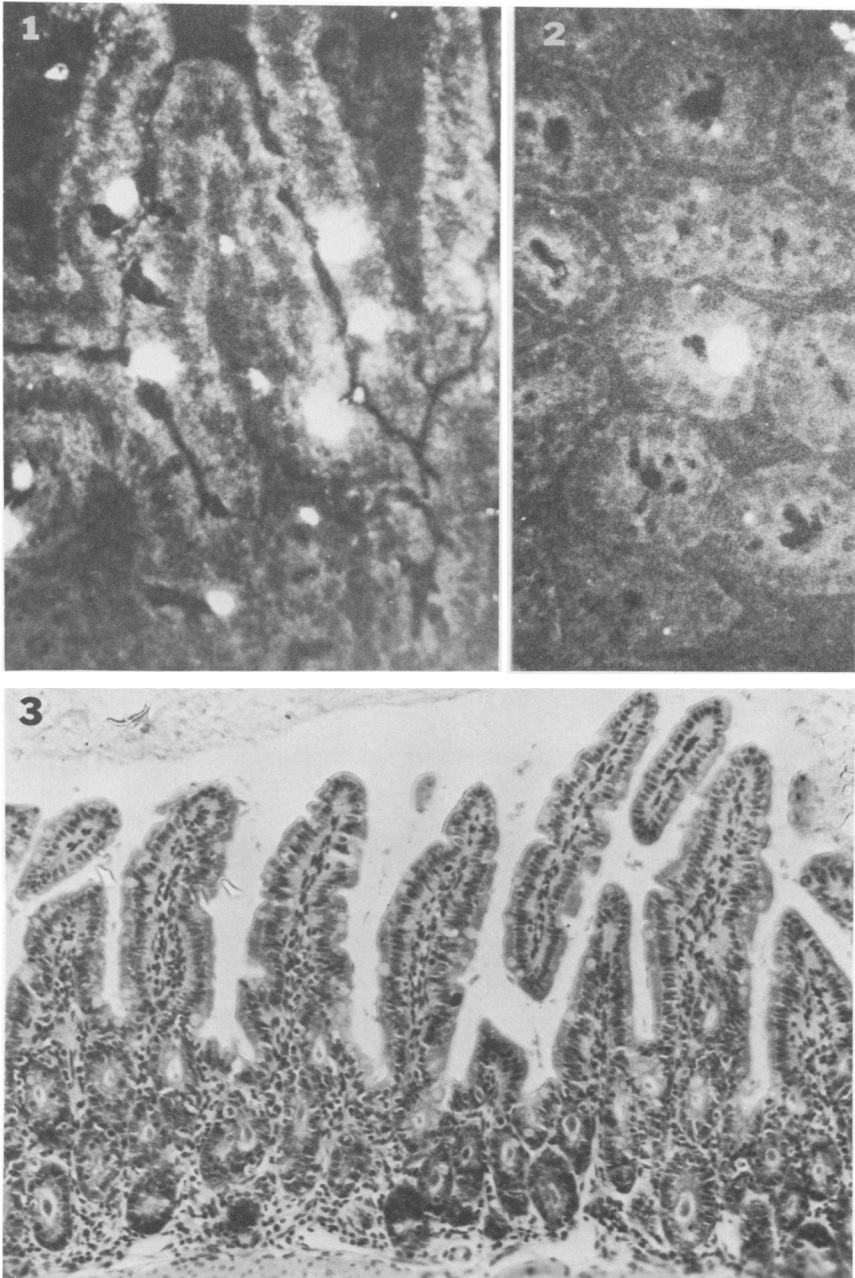


FIG. 1 AND 2. Frozen sections of infected mouse ileum. These and all other photomicrographs were taken from tissues 14 days postinfection with adenovirus K87. Fluorescent structures are seen in the epithelium of both villi (Fig. 1) and crypt (Fig. 2). The viral titer is high in the stool and ileal tissue of this animal. FA technique.  $\times 320$ .

FIG. 3. Ileal mucosa of infected mouse. Although the epithelial covering of the villi appears normal, the cellularity of the lamina propria is slightly higher than normal and the crypts are dilated. Paraffin section, hematoxylin and eosin.  $\times 120$ .

epithelium consisted of immature columnar cells, Paneth cells, goblet cells, and argentaffine cells. Cellular elements in the ileal lamina

propria were similar to those previously described in guinea pigs (23).

In general, the ileal mucosa of infected ani-

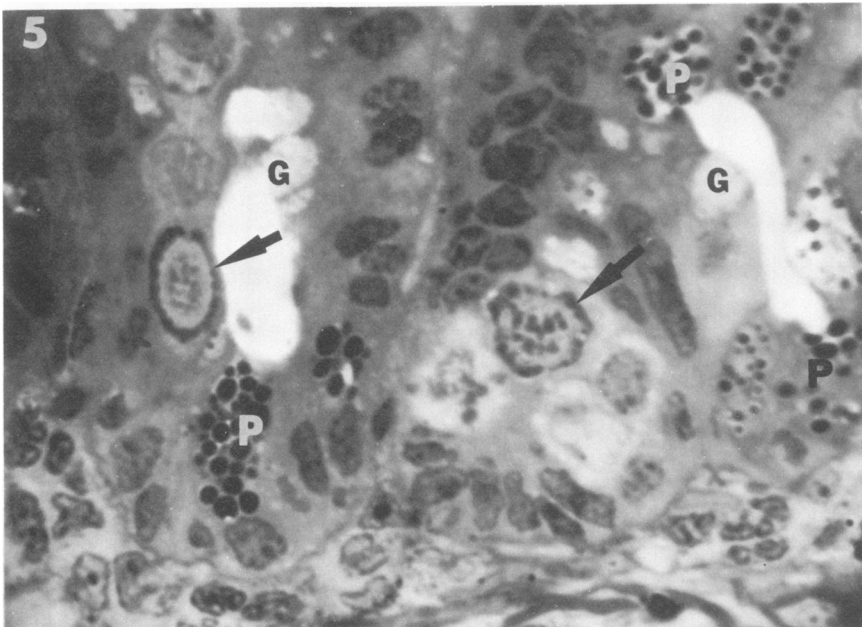
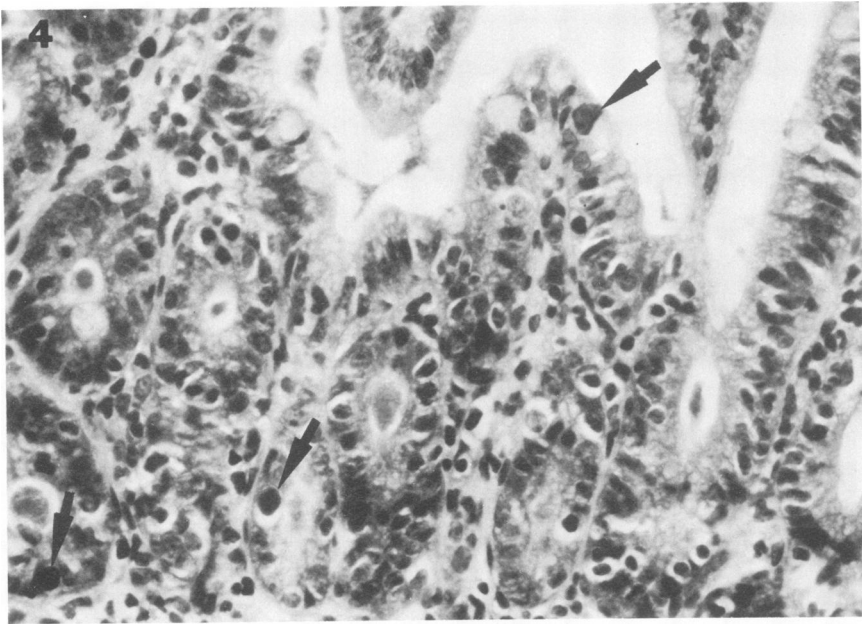


FIG. 4. Ileal mucosa of infected mouse. Oval or irregular nuclei (arrows) with densely basophilic inclusions are easily distinguishable from normal nuclei of epithelial cells and are localized within the epithelium of villi and crypt. Paraffin section, hematoxylin and eosin.  $\times 560$ .

FIG. 5. Crypt epithelium of infected ileum. This 1- to 2- $\mu$ m section from Epon-embedded tissue shows details of the enlarged nuclei with intraepithelial inclusions (arrows); their shape is oval at left and irregular at right. Inclusions consist of dense granular masses concentrated at the periphery and distributed throughout the light matrix. Note the prominent granules of Paneth cells (P) and the goblet cells (G). Methylene blue-azure II.  $\times 1,200$ .

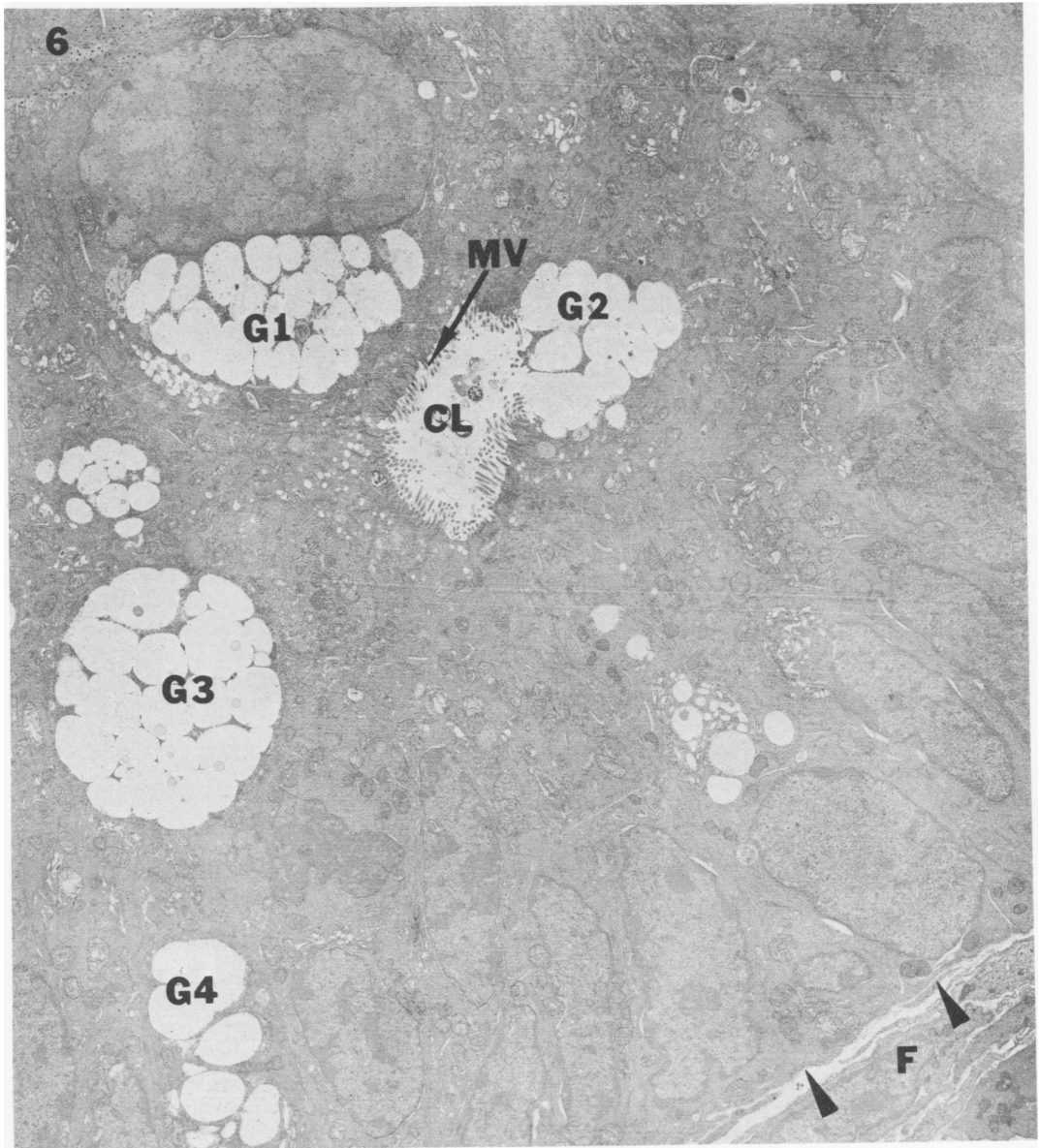
mals at 5 and 7 days after oral challenge was similar to that of control animals. Enlarged nuclei were occasionally identified in cells within the epithelium, but their presence was

extremely rare and appeared to have no effect upon the surrounding cellular organelles and on the other components of the gut mucosa; therefore, the following ultrastructural obser-

vations were mostly made on ileal tissues obtained 14 days after oral infection. Enlarged nuclei were then easily identified in both crypt and villus epithelium at low magnification and corresponded to those observed by FA and LM. They were confined to three types of epithelial cells, columnar, goblet, and Paneth (Fig. 6, 7, and 8). Nuclei containing large viral masses belonged to columnar and goblet cells on the

villi, whereas in the crypts they were found preferentially in the Paneth cells and more rarely in goblet cells.

At high magnification, fully formed virions were identified in the infected nuclei (Fig. 7). They were strikingly uniform in size, being  $75 \pm 5$  nm in diameter, and appeared hexagonal (Fig. 7). In favorable sections, two types of virions were identified, some with dense central



**FIG. 6.** Cross section of infected ileal crypt epithelium. A goblet cell (G1) faces the crypt lumen (CL) with its microvilli (MV) and shows an enlarged nucleus and mucus granules. The nucleus contains crystalline arrays of virions, not clearly discernible at this magnification, and dense bodies. Other goblet cells (G2, G3, and G4) show round prominent mucus granules; G2 is in the process of discharging mucus into the crypt lumen. Note the basal lamina of crypt epithelium (arrowheads) and fibroblast (F) in lamina propria.  $\times 4,200$ .

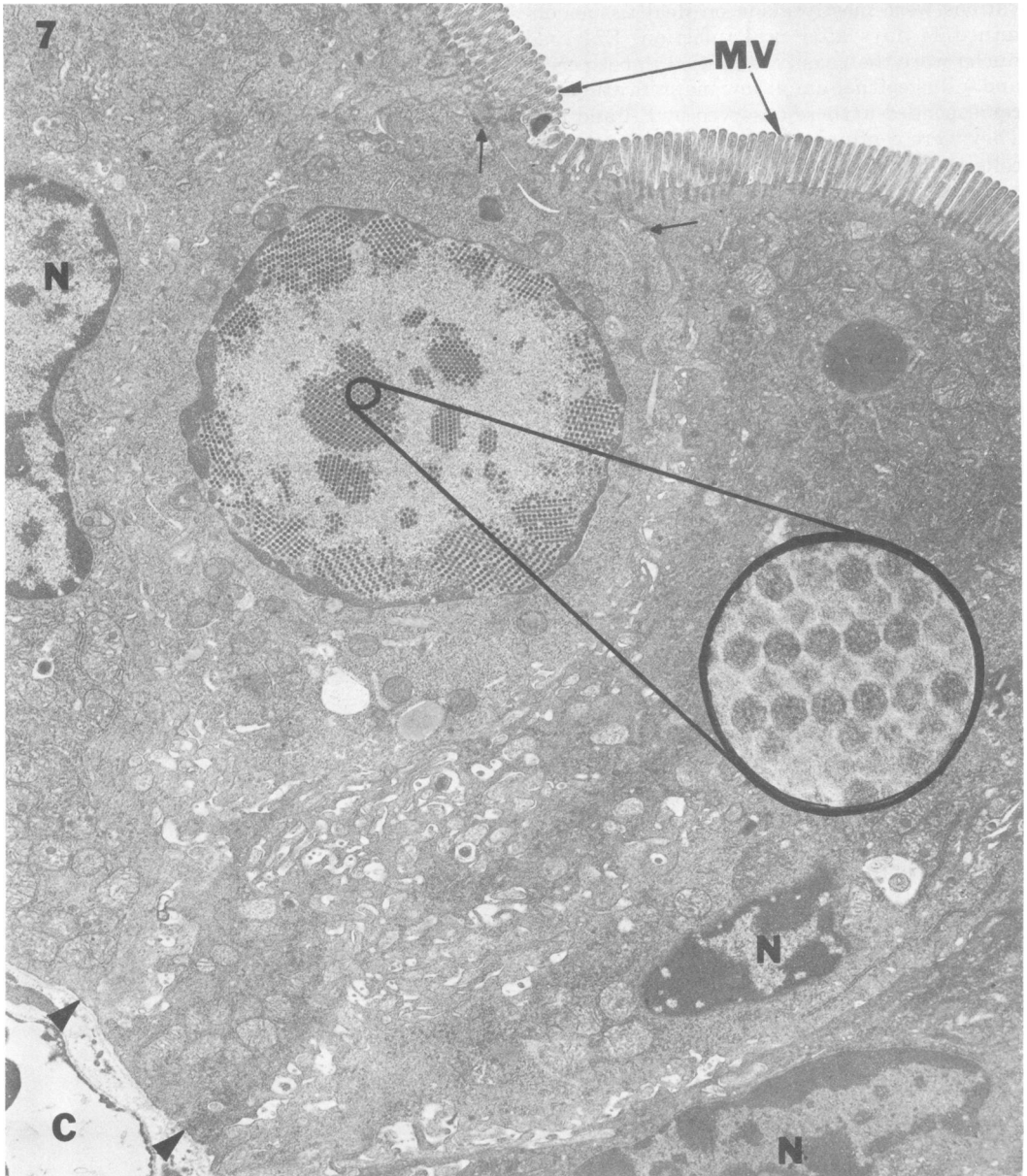
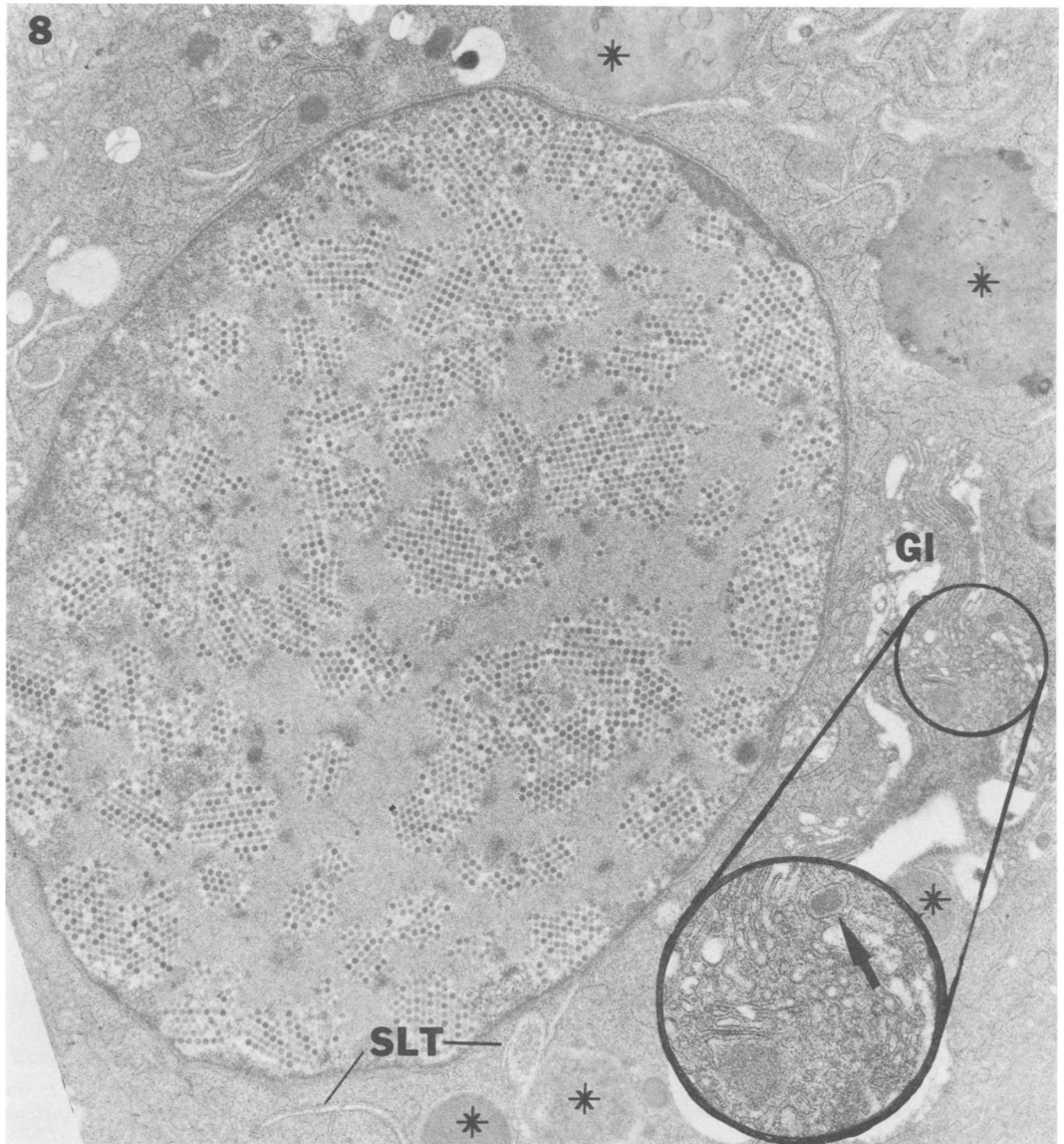


FIG. 7. Apical portion of infected ileal villus epithelium. The columnar cell shows a large nucleus containing crystalline arrays of virions. Note the difference between the infected nucleus and noninfected nucleus on the left (N). The other cytoplasmic components, including microvilli (MV), and the intercellular junctions (arrows) remain unaltered. Basal lamina of epithelial cells is marked by arrowheads; below it is a capillary (C).  $\times 8,200$ . Inset shows differences in density within the inner core of some virions.  $\times 110,000$ .

cores and others with electron-lucent centers (Fig. 8, 9, and 10). Most virions were arranged in typical arrays (Fig. 7, 8, and 9), whereas others were free and randomly scattered in the nucleoplasm, close to arrays in a dense homogeneous matrix, or abutted to a less dense and granular matrix (Fig. 11). The number of vi-

rons in each infected nucleus varied from one cell to another; in some nuclei they aggregated in small numbers (Fig. 10), whereas in others they formed large crystals (Fig. 8), often exhibiting alternate light and dark bands (Fig. 8 and 10). In some infected nuclei there were several ill-defined, electron-dense spherical



**FIG. 8.** Paneth cell in infected ileal crypt epithelium. Numerous virions form crystalline arrays. The nuclear membrane shows the typical double or parallel membranes. The Paneth granules are synthesized in the Golgi system (GI) and accumulate in the cisterna (arrow), developing into larger and denser mature granules (\*). In the cytoplasm, there are slitlike translucent structures (SLT). Other cytoplasmic components are not remarkable.  $\times 13,000$ .

masses (Fig. 8, 9, and 10), whereas in others, also containing homogeneously dark spheres, portions of the peripheral nucleoplasm, including virus aggregates, projected toward the cytoplasmic matrix (Fig. 9 and 10). These nuclear projections resembled the nuclear projections filled with virus aggregates that have been described by Fong et al. (7) as well as the "protrusions of the nuclear membrane" of Yamamoto

(30). Occasionally the nuclear membrane topographically close to viral particles was partially dissolved, resulting in free communication between the nucleoplasm and cytoplasmic matrix and the release of virions from the nucleus.

In the cytoplasm of infected cells, virions might be enclosed in membrane-bound vacuoles together with dense amorphous material

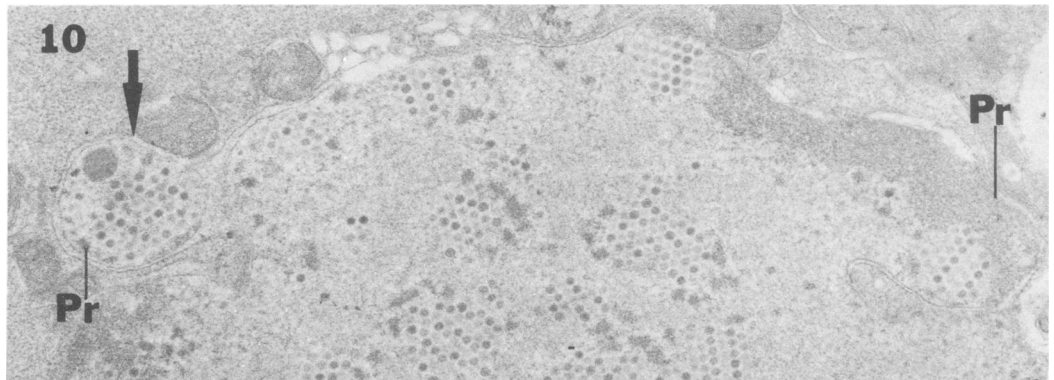
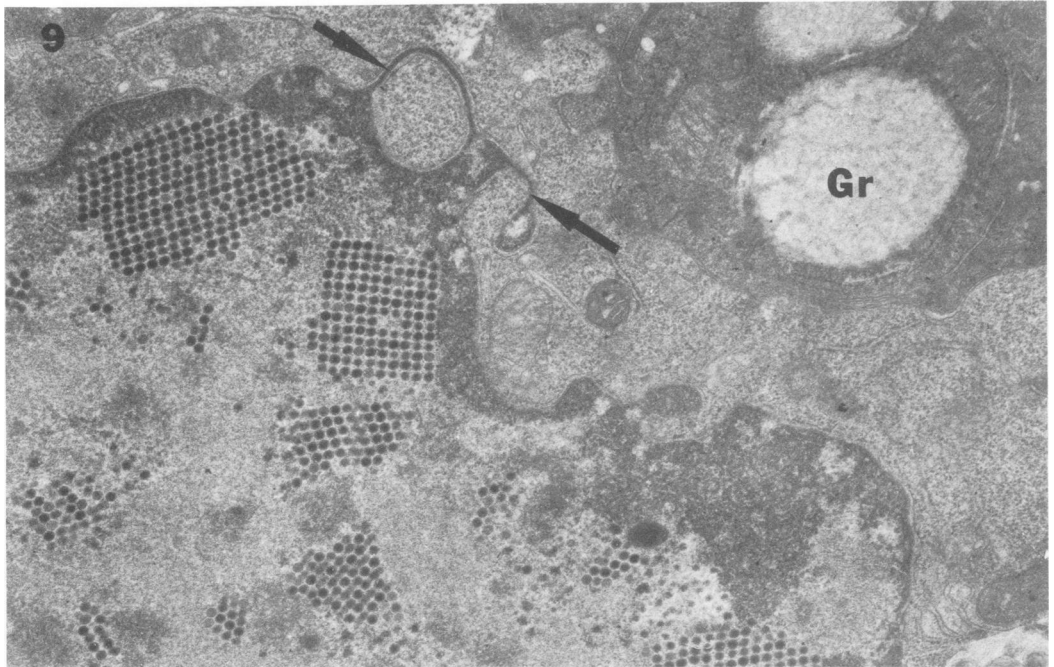


FIG. 9. Portion of nucleus of villus columnar cell showing peculiar projections of nucleoplasm into the cytoplasm, which focally enfold the cytoplasmic matrix (arrows). Note crystalline arrays of virions in nucleus and mucus granule (Gr) of adjacent goblet cell.  $\times 19,000$ .

FIG. 10. Part of infected nucleus of villus columnar cell. Nuclear protrusions are developing at both ends (Pr); the left one, separated from the main portion of the nucleus and enclosed by the inner nuclear membrane (arrow), contains virus particles and a dark round inclusion.  $\times 22,000$ .

and fragments of membranes or they might lie free, without enclosing membranes (Fig. 11). Other cytopathic changes in infected columnar cells included the emergence of slitlike translucent spaces enclosed by a single membrane (Fig. 8) and swelling of mitochondria, whereas other cytoplasmic organelles such as endoplasmic reticulum remained unchanged. In contrast, the cytoplasmic components, including the granules, of the goblet and Paneth cells showed no significant changes, even though they contained a large number of virions.

Both columnar and goblet infected cells were seen in the process of shedding from the midvillus epithelium into the intestinal lumen (Fig. 11), whereas the Paneth cells were seen shedding into the crypt lumen (Fig. 12). Extruded cells containing virions showed a variety of degenerating cytoplasmic organelles, as described above. Sometimes virions were identified free in the gut lumen.

Neither viral attachment to the microvillus nor viral penetration through the microvillus and nuclear membrane was observed. Mesen-



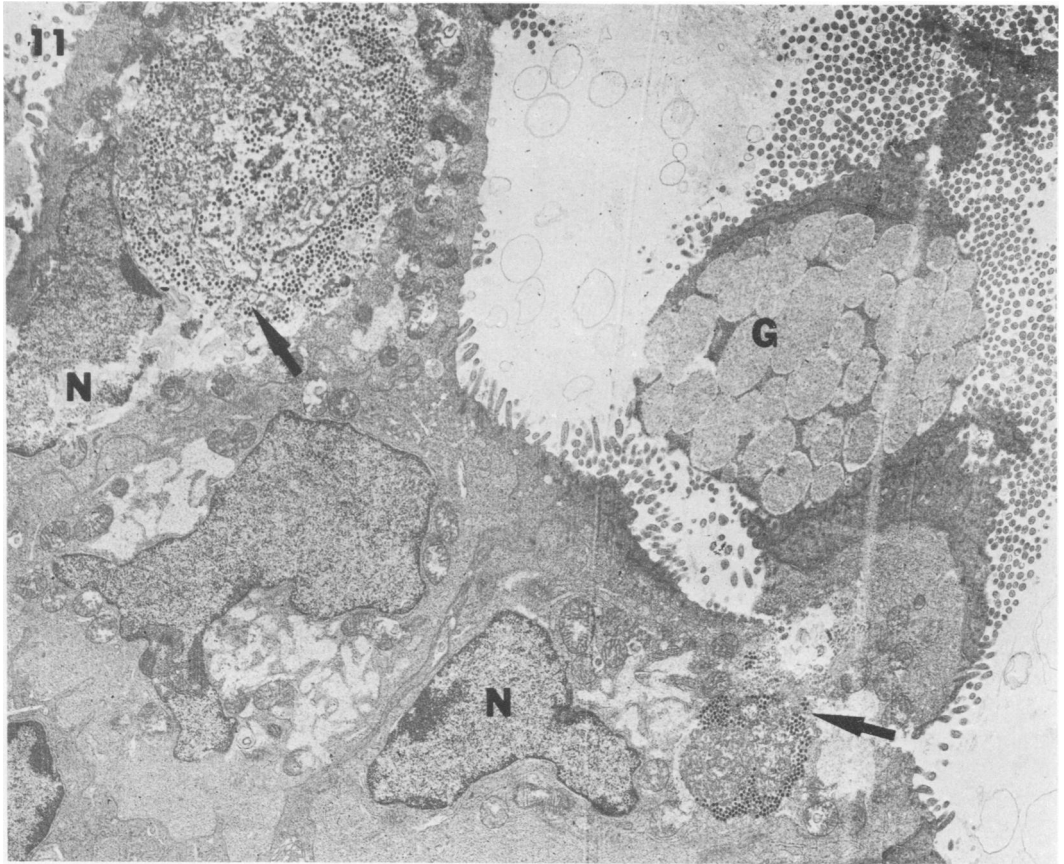


FIG. 11. Midvillus portion of infected ileal epithelium. Infected columnar cells together with goblet cell (G) are in the process of shedding into the lumen. Aggregates of virions are present in the cytoplasm (arrows). The nuclei (N) of these infected cells are free of virions, as confirmed when observed at a higher magnification.  $\times 5,800$ .

chymal cells and the extracellular space of the lamina propria were free of virions.

#### DISCUSSION

The present observations have demonstrated viral replication of mouse adenovirus K87 in the epithelial cells of the small gut mucosa. By FA technique, the specifically labeled fluorescent viral antigen has been clearly localized within the intestinal epithelial layer of both villus and crypt, and LM has identified it with nuclear inclusions of cells in the epithelium. Since the epithelium of the small bowel of normal mice consists of four kinds of epithelial cells, i.e., columnar (absorptive), goblet, Paneth, and argentaffine cells, and includes also migrating cells of mesenchymal origin (21) such as lymphocytes, neutrophilic leukocytes and globular leukocytes, it has not been possible to determine by FA and LM the specific cell type in which the adenovirus replicates.

The present EM evidence has ruled out the possibility of mesenchymal cells as the replication site of the K87 viral antigen and has established without a doubt that K87 adenovirus replicates only in columnar, goblet, and Paneth cells. Adenovirus K87, therefore, demonstrates a specific tissue tropism, since virions are absent from other intraepithelial cells such as argentaffine cells and lymphocytes. Characteristically, the columnar, goblet, and Paneth cells are the only cells that face the gut lumen with a microvillus surface. It is, therefore, possible that specific receptor sites such as those shown in cultured cells for other adenoviruses (6, 14, 17) might be present on the microvilli. The adenovirus K87 might absorb to such a receptor site and penetrate the cells through the microvilli. The demonstration of such penetration, however, has not been possible during the present *in vivo* study.

A tissue tropism to the villus epithelium

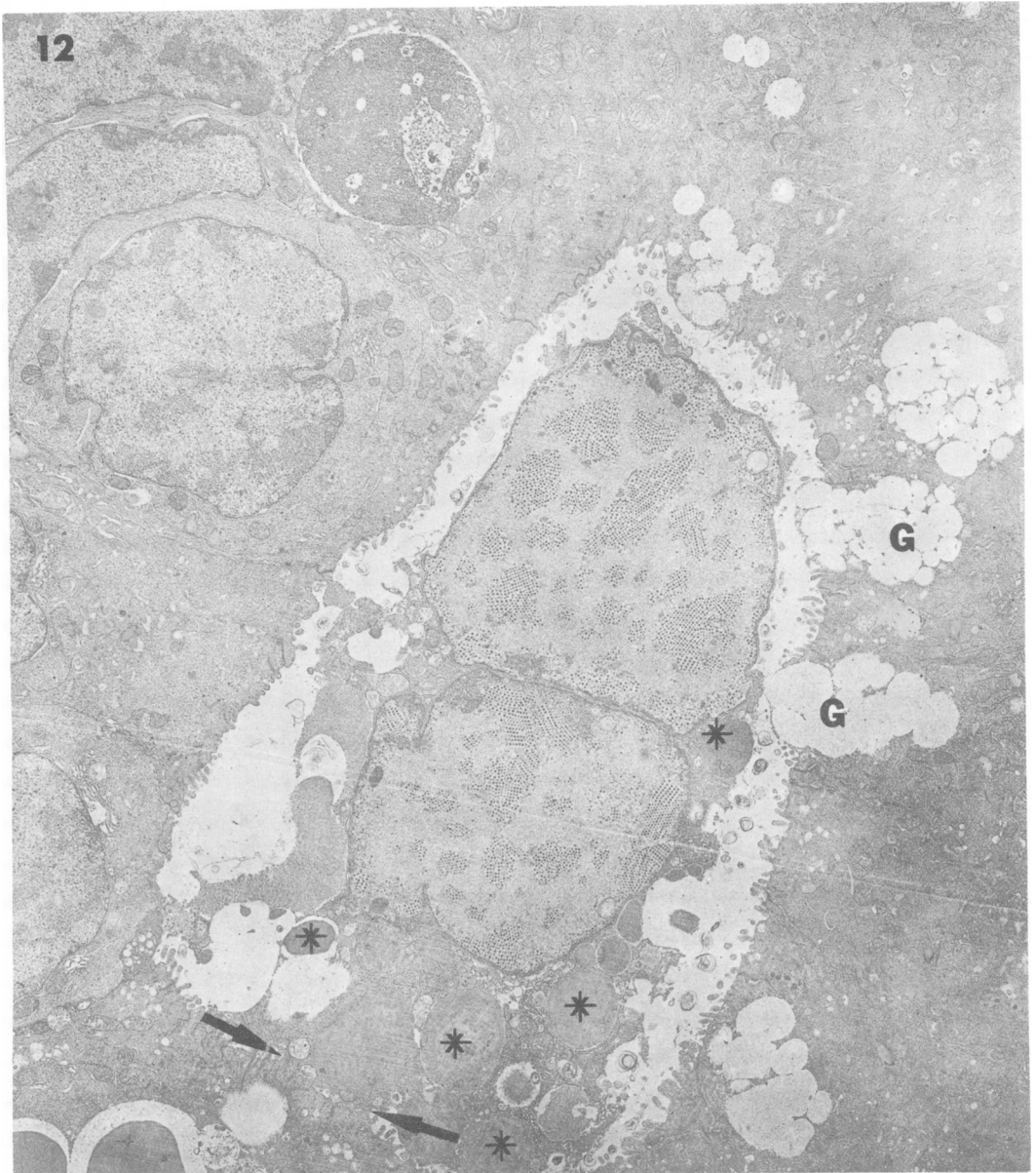


FIG. 12. Crypt of infected ileum. The nuclei of two cells, apparently Paneth cells, are in the process of shedding into the crypt lumen. A portion of shedding cell is still attached to epithelial cells (arrows). Note Paneth granules (\*). Goblet cell is discharging mucus into crypt lumen (G).  $\times 6,800$ .

only, similar to that seen in the mouse enteric adenovirus K87, has been reported by Clemmer and Ichinose also in the small bowel of chickens infected orally with adenovirus strain 93 (4, 5). They have postulated that adenovirus 93 probably infects the epithelial cells in the crypts and replicates during their migration onto the villi, where it becomes visible (5). In this context it must be remembered that chickens lack Paneth cells (29).

The columnar cells of the epithelium of the small intestine of mice also undergo continuous renewal and rapid migration out of the crypts (16, 26) as do, if albeit more slowly, the mucus-secreting goblet cells (1, 16). In contrast, the Paneth cells are renewed at a much slower rate and do not migrate out of the crypts (1, 3). It is conceivable that, in the mouse adenovirus K87 infection reported here, all cells may be also infected in the crypts, but that, in the time

necessary for viral replication and visualization, the columnar and most goblet cells would have migrated out of the crypts and onto the villi, whereas the Paneth cells, which remain in the crypts and whose turnover is much slower, would allow replication to occur in the crypts to such an extent as to be easily visualized.

In the normal mucosa, epithelial and goblet cells are not extruded until they reach the tip of the villi, and the structural integrity of the gut epithelium is maintained by characteristic interdigitation and invagination of the lateral plasmalemma of epithelial cells, which are tightly connected through intercellular junctional complexes. During the adenovirus K87 infection, extrusion of infected columnar and goblet cells may occur at the midvillus level, whereas an accelerated extrusion of Paneth cells has been observed in the crypts. The premature shedding of adenovirus-infected cells, we believe, represents a morphological expression of adenovirus-induced cytopathic effect. A similar, excessive loss of epithelial cells is commonly associated with acute enteric infections (20, 22-24). It has been suggested that under these conditions accelerated shedding of epithelial cells results from failure of intercellular junctions, which may be related to loss of calcium due to changes in calcium metabolism (22). It may be possible that a similar mechanism is at work in the present virus infection.

Intracytoplasmic membrane-enclosed vacuoles bearing viral particles resemble the phagocytic inclusions containing adenovirus 7, described by Chardonnet and Dales in HeLa cells infected with that agent (2), and also the autophagic vacuoles and phagolysosomes containing pathogenic bacteria, which are found in intestinal epithelial cells (24).

In contrast to the columnar cells, the cytoplasm of the secretory goblet and Paneth cells appears unaltered, even when infected with virus. Under normal conditions, in both goblet and Paneth cells, granular contents are synthesized in the endoplasmic reticulum and packaged in the Golgi complex, where they accumulate and develop into membrane-bound mature granules. Synthesis and secretion continue in the infected cells, indicating that they are capable of functioning in spite of the presence of large numbers of virions.

Early changes observed in adenovirus-infected cell cultures, such as intranuclear fibers (13), and paracrystalline formation (11) have not been seen in either columnar or secretory epithelial cells. These morphological differences between *in vivo* and *in vitro* response to viral infection may be due to difficulty of sampling, but may be also related to differences in the strain of adenovirus or to host factors (8).

Nor has cell necrosis been observed even in the prematurely shedding cells of the gut, such as has been reported by Margolis and colleagues (12, 15) in their study on the interaction between host cells and the adrenotropic mouse adenovirus. Multiplication of this adenovirus produces severe degeneration and necrosis of the infected adrenal cortical cells and an acute inflammatory response, the latter, possibly, secondary to cell necrosis. It is possible that the premature extrusion of the mouse intestinal epithelial cells infected with K87 adenovirus may prevent the severe degeneration and death seen in the adrenotropic adenovirus infection and, therefore, may also be responsible for the lack of inflammation noted in the viral enteric infection.

In conclusion, the present FA, LM, and EM *in vivo* studies of adenovirus K87 in mice have provided new information on several aspects of the interaction between virus and host cells as yet undisclosed by *in vitro* observations.

#### ACKNOWLEDGMENTS

We wish to thank Helen R. Jervis for critical review of this manuscript. Fred F. Bland III and Garnett Lee Henley, Department of Experimental Pathology, Walter Reed Army Institute of Research, and Tamako Yano, Department of Microbiology, Keio University School of Medicine, have provided excellent technical assistance.

This research was supported in part by grants from the Waksman Foundation of Japan, Inc., and the Naito Foundation, Japan.

#### LITERATURE CITED

1. Cairnie, A. B. 1970. Renewal of goblet and Paneth cells in the small intestine. *Cell Tissue Kinet.* 3:35-45.
2. Chardonnet, Y., and S. Dales. 1970. Early events in the interaction of adenoviruses with HeLa cells. II. Comparative observations on the penetration of types 1, 5, 7, and 12. *Virology* 40:478-485.
3. Cheng, H., J. Merzel, and C. P. Leblond. 1969. Renewal of Paneth cells in the small intestine of the mouse. *Am. J. Anat.* 126:507-526.
4. Clemmer, D. L. 1965. Experimental enteric infection of chickens with an avian adenovirus (Strain 93). *Proc. Soc. Exp. Biol. Med.* 118:943-947.
5. Clemmer, D. I., and H. Ichinose. 1968. The cellular site of virus replication in the intestine of chicks infected with avian adenovirus. *Arch. Gesamte Virusforsch.* 25:277-287.
6. Dales, S. 1973. Early events in cell-animal virus interactions. *Bacteriol. Rev.* 37:103-135.
7. Fong, C. K. Y., K. G. Bensch, and G. D. Hsiung. 1968. Productive and abortive infections of simian and non-simian cells with a simian adenovirus SV15. I. Microscopic observations. *Virology* 35:297-310.
8. Hashimoto, K., N. Onishi, T. Tajiri, Y. Okada, R. Maeda, Y. Sugihara, and S. Sasaki. 1973. Viral enteric infection and local IgA antibody: studies in germfree mice thymectomized and/or infected with a mouse adenovirus, p. 501-506. *In* J. B. Heneghan (ed.), *Germfree research: biological effect of gnotobiotic environments*. Academic Press Inc., New York.
9. Hashimoto, K., T. Sugiyama, and S. Sasaki. 1966. An adenovirus isolated from the feces of mice. I. Isolation and identification. *Jpn. J. Microbiol.* 10:115-125.
10. Hashimoto, K., T. Sugiyama, M. Yoshikawa, and S.

- Sasaki. 1970. Intestinal resistance in the experimental enteric infection of mice with a mouse adenovirus. I. Growth of the virus and appearance of a neutralizing substance in the intestinal tract. *Jpn. J. Microbiol.* 14:381-395.
11. Henry, C. J., M. Slikin, L. P. Merkow, and M. Pardo. 1971. The ultrastructure and nature of adenovirus type 2-induced paracrystalline formations. *Virology* 44:215-218.
  12. Hoenig, E. M., G. Margolis, and L. Kilham. 1974. Experimental adenovirus infection of the mouse adrenal gland. II. Electron microscopic observations. *Am. J. Pathol.* 75:375-386.
  13. Kalnins, V. I., H. F. Stich, and D. S. Yohn. 1966. Electron microscopic localization of virus-associated antigens in human amnion cells (AV-3) infected with human adenovirus type 12. *Virology* 28:751-754.
  14. Lonberg-Holm, K., and L. Philipson. 1969. Early events of virus cell interaction in an adenovirus system. *J. Virol.* 4:323-338.
  15. Margolis, G., L. Kilham, and E. M. Hoenig. 1974. Experimental adenovirus infection of the mouse adrenal gland. I. Light microscopic observations. *Am. J. Pathol.* 75:363-374.
  16. Merzel, J., and C. P. Leblond. 1969. Origin and renewal of goblet cells in the epithelium of the mouse small intestine. *Am. J. Anat.* 124:281-306.
  17. Philipson, L., K. Longberg-Holm, and U. Petterson. 1968. Virus receptor interaction in an adenovirus system. *J. Virol.* 2:1064-1065.
  18. Phillips, D. M., and H. J. Raskas. 1972. Ultrastructural changes in KB cultures infected with adenovirus type 2. *Virology* 48:156-169.
  19. Sugiyama, T., K. Hashimoto, and S. Sasaki. 1967. An adenovirus isolated from the feces of mice. II. Experimental infection. *Jpn. J. Microbiol.* 11:33-42.
  20. Takeuchi, A., S. B. Formal, and H. Sprinz. 1968. Experimental acute colitis in the Rhesus monkey following peroral infection with *Shigella flexneri*. An electron microscope study. *Am. J. Pathol.* 52:503-529.
  21. Takeuchi, A., H. R. Jervis, and H. Sprinz. 1969. The globule leucocyte in the intestinal mucosa of the cat: a histochemical, light and electron microscopic study. *Anat. Rec.* 164:79-99.
  22. Takeuchi, A., and B. P. Phillips. 1975. Electron microscope studies of experimental *Entamoeba histolytica* infections in the guinea pig. I. Penetration of the intestinal epithelium by trophozoites. *Am. J. Trop. Med. Hyg.* 24:34-48.
  23. Takeuchi, A., and H. Sprinz. 1967. Electron microscope studies of experimental *Salmonella* infection in the preconditioned guinea pig. II. Response of the intestinal mucosa to the invasion by *Salmonella typhimurium*. *Am. J. Pathol.* 51:137-161.
  24. Takeuchi, A., H. Sprinz, E. H. LaBrec, and S. B. Formal. 1965. Experimental bacillary dysentery. An electron microscopic study of the response of the intestinal mucosa to bacterial invasion. *Am. J. Pathol.* 47:1011-1044.
  25. Takeuchi, A., and J. A. Zeller. 1972. Ultrastructural identification of spirochetes and flagellated microbes at the brush border of the large intestinal epithelium of the rhesus monkey. *Infect. Immun.* 6:1008-1018.
  26. Thrasher, J. D., and R. C. Greulich. 1966. The duodenal progenitor population. III. The progenitor cell cycle of principal, goblet, and Paneth cells. *J. Exp. Zool.* 161:9-19.
  27. Trier, J. S. 1963. Studies on small intestinal crypt epithelium. I. The fine structure of the crypt epithelium of the proximal small intestine of fasting humans. *J. Cell Biol.* 18:599-620.
  28. Ushiba, D., B. Kitasato, K. Saito, M. Nakano, and T. Nomura. 1962. Selective inbreeding of mouse strains uniformly susceptible to mouse typhoid and experimental infections of those strains. I. Trial of establishing inbred strains with different time-to-death after infection with *Salmonella enteritidis*. *Jpn. J. Exp. Med.* 32:505-517.
  29. Windisch, M.-C. 1966. Étude morphologique des cellules de Paneth dans diverses conditions physiologiques. *Rev. Can. Biol.* 25:167-177.
  30. Yamamoto, T. 1969. Sequential study on the development of infectious canine laryngotracheitis adenovirus. *J. Gen. Virol.* 4:397-401.