

Case Report

Chronic cough as a presenting feature of cerebral lymphoma

Stephen P. Williams^{1,*} and Mahmood F. Bhutta²

¹Department of Otorhinolaryngology, Countess of Chester Hospital, Cheshire CH6 1UL, UK and ²Department of Otorhinolaryngology, John Radcliffe Hospital, Oxford OX3 9DU, UK

*Correspondence address. Department of Otorhinolaryngology, Countess of Chester Hospital, Cheshire CH6 1UL, UK. Tel: +44 781 108 0614; E-mail: spwilliams@doctors.org.uk

Received 5 September 2014; accepted 30 September 2014

We report a rare case of chronic cough as the presenting symptom of a primary brainstem lesion. A 69-year-old gentleman presented with chronic cough followed by onset of progressive truncal ataxia, incoordination and nystagmus. Contrast-enhanced imaging showed a midbrain lesion extending into the cerebellum, confirmed as lymphoma by stereotactic brain biopsy. The patient was successfully treated with chemotherapy, but his cough persists. We present this case to highlight the possibility of a brainstem lesion as a rare central cause of chronic cough, and suggest that the diagnosis is considered in those with concomitant neurological symptoms.

INTRODUCTION

Chronic cough is a frequent presenting complaint to not only the general practitioner but also the otolaryngologist and respiratory specialist. Diagnosis can be difficult, especially in primary care, but empirical treatment for common causes such as asthma, chronic obstructive pulmonary disease, gastro-oesophageal reflux disease, postnasal drip or drug-induced cough (most commonly secondary to angiotensin converting enzyme inhibition [1]) is recommended when there are no associated worrying symptoms, and is successful in the majority of cases [2]. Symptoms that may signify a rarer but more

serious cause for chronic cough include the copious production of sputum, fever, sweats, unintentional weight loss, haemoptysis, clubbing, hoarseness and marked dyspnoea [3].

Here we highlight a unique cause of chronic cough: the initial symptom of lymphoma compressing the brainstem. This highlights another potentially serious, albeit rare, cause of chronic cough.

CASE REPORT

A 69-year-old gentleman presented to his general practitioner with a 3-month history of progressive unsteadiness. On further

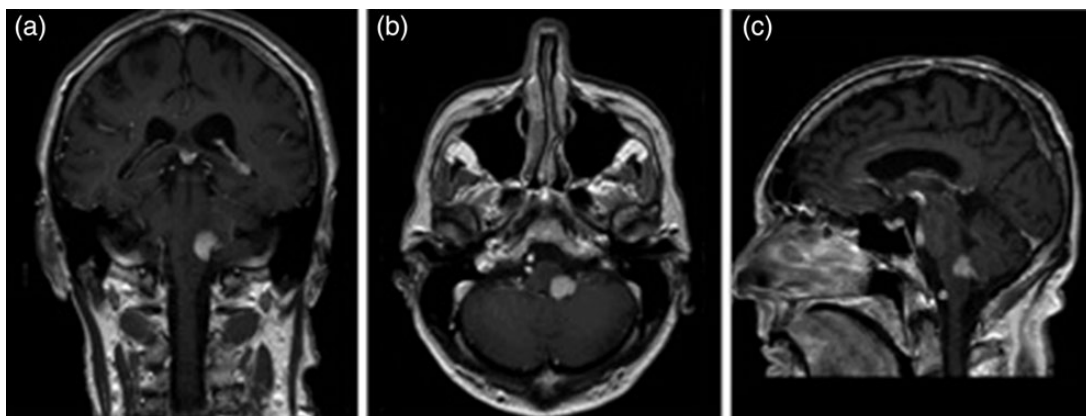


Figure 1: Gadolinium-enhanced T₁-weighted MRI images (panes lettered with coronal (a), axial (b) and sagittal (c) sections) showing a homogenous enhancement of a clearly demarcated lesion in the left posterior and lateral midbrain with extension into the inferior cerebellar peduncle.

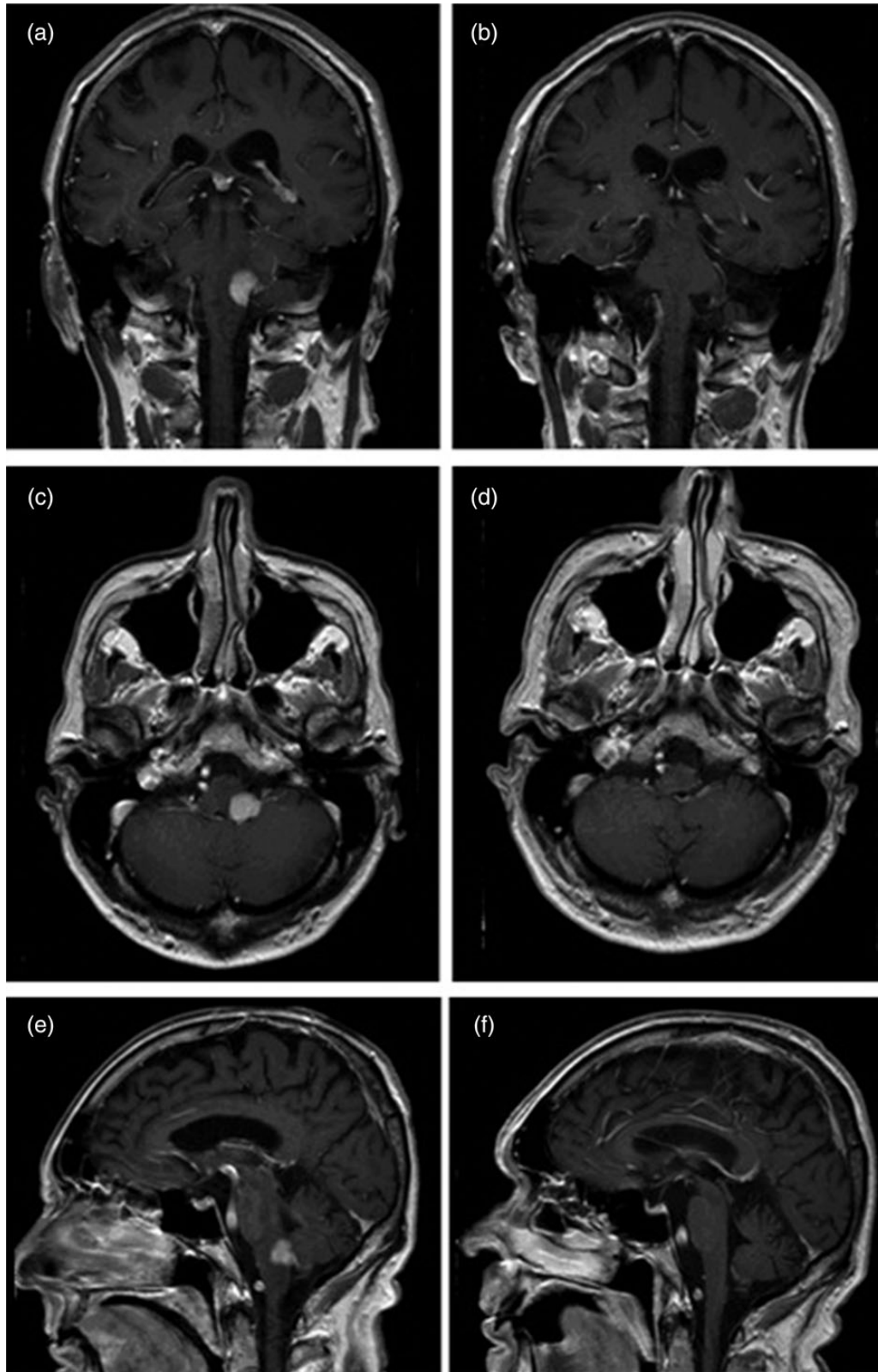


Figure 2: Compares initial T₁-weighted gadolinium-enhanced MRI images (seen in panes on left hand side: **a**, **c** and **e**) with those taken following completion of treatment (panes on right: **b**, **d** and **f**). Radiological remission is shown in the post-treatment images.

questioning he also volunteered that these symptoms had been preceded by a chronic cough, which had no obvious precipitant, and which had failed to resolve. On examination he had

truncal ataxia, to the point where he had difficulty remaining upright when walking, and exhibited gaze-evoked first-degree nystagmus in his left eye on looking to the right. The patient

had suffered an episode of labyrinthitis 10 years earlier, and so he was prescribed pharmacological therapy aimed at a presumptive diagnosis of a second episode. Successive trials of prochlorperazine, betahistine, cyclizine and arlevert were not noted to have any positive effect on the patient's dizziness and he was referred for outpatient neurological opinion.

By the time of specialist review, the patient's symptoms had worsened and he now described periods of severe nausea, with progression of his ataxia to the point where he was unable to stand unaided. He had also developed an area of hypoesthesia on the left side of his face. Eye movements were adjudged to be markedly abnormal with dysmetric horizontal saccadic movements in addition to his ongoing nystagmus. His right vestibular ocular reflex was reduced and his left upper limb movements lacked coordination.

Gadolinium-enhanced magnetic resonance imaging (MRI) of the brain revealed a homogeneously enhancing, sharply demarcated 13 mm diameter lesion in the left posterior and lateral midbrain extending into the inferior cerebellar peduncle, with some adjacent oedema, suggestive of primary lymphoma (see Fig. 1). Stereotactic brain biopsy confirmed diffuse large B-cell lymphoma (DLBCL) and subsequent bone marrow biopsy and computer tomography (CT) imaging showed no evidence of lymphoma at any additional anatomical site.

The patient embarked on IDARAM (idarubicin, cytarabine, methotrexate, dexamethasone) chemotherapy followed by two rounds of high-dose methotrexate mono-therapy. Imaging following treatment showed radiological remission and this is also seen on recent scans, now 2 years later (see Fig. 2). While the symptoms of cerebellar dysfunction have largely abated since discharge, the patient has, however, been continually troubled by his cough.

Otolaryngology assessment, including symptom review, medication history, endoscopic evaluation and chest X-ray, was unable to elucidate any cause for cough other than the presumed effects of the medullary lesion. Empirical trials of nasal steroids, nasal saline washes, high-dose proton pump inhibitor and inhaled bronchodilators were all unsuccessful. Codeine linctus also had no effect. The patient, unfortunately, continues to be troubled by his cough.

DISCUSSION

Coughing is a protective motor reflex under both voluntary and involuntary regulation, integrating physiological, psychological and social inputs. Studies in experimental animals have shown that vagal afferents signal peripheral sensory stimulation from the airways and lungs, and project centrally to the nucleus tractus solitarius (NTS) with further projections between the NTS and the medulla and pons [4]. That such projections constitute a regulatory brainstem 'cough centre' is a concept that has been extensively pursued; attempting to determine the specific central pathways involved in the initiation and regulation of the efferent arc of the cough reflex [5].

The aetiology of chronic cough has been considered in a similar manner to the aetiology of chronic pain, with elements of both peripheral and central sensitization [6]. Most of the common causes of chronic cough, and notably the classically described 'diagnostic triad' of asthma, gastro-oesophageal reflux disease and postnasal drip [7], arise primarily through the activation of peripheral vagal afferents, but with probable central maladaptation contributing to hyper-sensitization to peripheral stimuli [8].

Primary central causes of chronic cough are exceedingly rare. Pathological impingement of the dorsal medullary region of the brainstem is recognized as a neurogenic cause of chronic cough in cases of patients with Chiari I malformations and cough may be the initial symptom [9]. However, to our knowledge, this is the first reported case of a lymphoma around the brainstem with chronic cough as one of the first symptoms.

It is difficult to be certain as to the mechanism of chronic cough induced by this lymphoma. It may be that the expanding mass of the DLBCL compressed nearby nerve efferents serving the cough reflex, leading to aberrant hypersensitization. However, DLBCL can be an aggressive lesion and has been reported to present with focal neurology from local invasion into nerves [10]. It is possible, therefore, that the chronic cough in this case was caused by tumour infiltration into nerves rather than compression.

Although clearly cerebral lymphoma is a very rare cause of chronic cough, we believe that clinicians in primary and secondary care should consider rare central causes of chronic cough in cases where neurological symptoms or signs are present, or in cases where empirical treatment for the more common causes of cough fails to provide symptomatic relief.

REFERENCES

1. Barraclough K. Chronic cough in adults. *BMJ* 2009;**338**:b1218.
2. Bolser DC. Pharmacological management of cough. *Otolaryngol Clin North Am* 2010;**43**:147–55.
3. National Institute for Health and Clinical Excellence: The diagnosis and treatment of lung cancer. 2011. <http://www.nice.org.uk/nicemedia/live/13465/54208/54208.pdf>.
4. Kubin L, Alheid GF, Zuperku EJ, McCrimmon DR. Central pathways of pulmonary and lower airway vagal afferents. *J Appl Physiol* 2006;**101**:618–27.
5. Widdicombe DG. Neurophysiology of the cough reflex. *Eur Respir J* 1995;**8**:1193–202.
6. Woodcock A, Young EC, Smith JA. New insights in cough. *Br Med Bull* 2010;**96**:61–73.
7. Palombini BC, Villanova CA, Araujo E, Gastal OL, Alt DC, Stolz DP, Palombini CO. A pathogenic triad in chronic cough: asthma, postnasal drip syndrome, and gastroesophageal reflux disease. *Chest*. 2009;**136** (5 Suppl):e30.
8. Bonham AC, Sekizawa S, Chen CY, Joad JP. Plasticity of brainstem mechanisms of cough. *Respir Physiol Neurobiol* 2006;**152**:312–9.
9. Amos LB, Quintero DR. Chiari I malformation presenting as chronic cough. *Pediatr Pulmonol* 2008;**43**:1040–2.
10. Kim UR, Shah AD, Arora V, Solanki U. Isolated optic nerve infiltration in systemic lymphoma—a case report and review of literature. *Ophthalm Plast Reconstr Surg* 2010;**26**:291–3.