

Case Report

Symptomatic *de novo* arteriovenous malformation in an adult: Case report and review of the literature

Jayson A. Neil, Daphne Li, Michael F. Stiefel, Yin C. Hu

Department of Neurological Surgery, New York Medical College, Valhalla, New York, USA

E-mail: Jayson A. Neil - Jayson.neil@gmail.com; Daphne Li - daphne.li@gmail.com; Michael F. Stiefel - StiefelM@wcmc.com; *Yin C. Hu - HuY@wcmc.com

*Corresponding author

Received: 29 March 14 Accepted: 02 July 14 Published: 13 October 14

This article may be cited as:Neil JA, Li D, Stiefel MF, Hu YC. Symptomatic *de novo* arteriovenous malformation in an adult: Case report and review of the literature. *Surg Neurol Int* 2014;5:148.Available FREE in open access from: <http://www.surgicalneurologyint.com/text.asp?2014/5/1/148/142796>

Copyright: © 2014 Neil JA. This is an open-access article distributed under the terms of the Creative Commons Attribution License, which permits unrestricted use, distribution, and reproduction in any medium, provided the original author and source are credited.

Abstract

Background: Cerebral arteriovenous malformations (AVMs) have been long thought to be a congenital anomaly of vasculogenesis in which arteries and veins form direct connections forming a vascular nidus without an intervening capillary bed or neural tissue. Scattered case reports have described that AVMs may form *de novo* suggesting they can become an acquired lesion.

Case Description: The current case report describes a patient who presented with new-onset seizures with an initial negative magnetic resonance imaging (MRI) of the brain and subsequently developed an AVM on a MRI 9 years later.

Conclusion: This case joins a small, but growing body of literature that challenges the notion that all AVMs are congenital.

Key Words: AVM, arteriovenous malformation, AVM formation, adult onset AVM, *de novo* AVM

Access this article online**Website:**www.surgicalneurologyint.com**DOI:**

10.4103/2152-7806.142796

Quick Response Code:

INTRODUCTION

Cerebral arteriovenous malformations (AVMs) are abnormal vascular connections that form between arteries and veins, without an intervening capillary bed or neuronal tissues.^[6] They are a heterogeneous group of vascular lesions varying in locations, sizes, and venous drainages. The incidence of cerebral AVMs in the general population is less than 1%. AVMs may be clinically silent or present with hemorrhages, often in the second or third decade of life.^[2] Less commonly, AVMs may manifest other symptoms such as seizures and those related to mass effect or ischemic steal.^[7] The pathogenesis of AVMs remains incompletely elucidated and has traditionally been thought to be congenital. We present a case of symptomatic *de novo* cerebral AVM in a patient with an initial negative magnetic resonance imaging (MRI) of the

brain at the age of 15, but 9 years later developed a left parietal AVM.

CASE REPORT

History and presentation

The patient is a 24-year-old right-handed male with a past medical history significant for a seizure disorder. He experienced his first seizure at age 15, resulting in a severe facial burn after falling on a home heater. An initial MRI of the brain was performed, which was negative [Figure 1]. He continued to have intermittent seizures until age 17 when he was placed on antiepileptic medications. At the age of 24, he suffered a 4-min generalized tonic-clonic seizure. Further workup including an MRI of the brain revealed a 2 × 1.7 × 1.8 cm left parietal AVM [Figure 2], which was not present

on the MRI 9 years ago. Digital subtraction cerebral angiogram (DSA) showed a Spetzler–Martin grade II AVM in the left parietal region with arterial feeders from the left middle cerebral artery (MCA) and the left posterior cerebral artery (PCA) and early venous drainage into the superior sagittal sinus [Figure 3].

Procedure

After a thorough discussion about the natural history and treatment options (observation, microsurgical, and radiosurgery), the patient elected to have the AVM resected. The patient underwent presurgical Onyx (eV3 Neurovascular Inc., Irvine, CA) embolization of the AVM followed by a left parietal craniotomy and resection of the

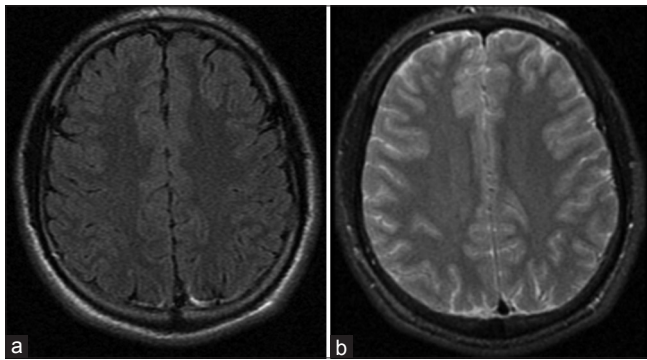


Figure 1: Axial Flair (a) and T2 weighted (b) MRI performed December 06, 2003 without evidence of vascular malformation

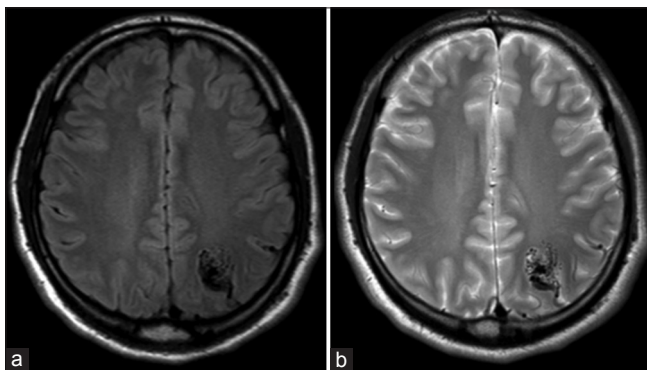


Figure 2: Axial Flair (a) and T2 weighted (b) MRI performed July 21, 2012 demonstrating left parietal AVM

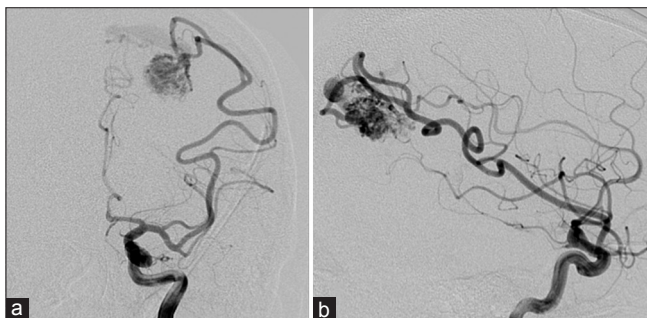

Figure 3: AP (a) and Lateral (b) left internal carotid injections demonstrating left parietal AVM

AVM without complication or morbidity. Postoperative cerebral angiography demonstrated no residual AVM nidus or early venous drainage. The hospital course was unremarkable and the patient was discharged home on postoperative day three. At 6 months follow-up, the patient remained seizure free and not on antiepileptic medications.

DISCUSSION

Although cerebral AVMs have traditionally been considered congenital lesions, there is an increasing number of case reports of *de novo* AVMs [Table 1]. To date, there are nine other cases that have reported these phenomena. Of these nine cases, seven reported the occurrence of *de novo* AVMs in patients that had other vascular pathology, such as prior resection of AVMs in different locations during childhood.^[1,3,4,13,16-18] The majority of those cases were documented in pediatric patients. The literature review yielded five cases that reported *de novo* AVM development in patients without vascular pathology on prior MRI, as is the case in this patient.^[5,9,11,14,20] Of these *de novo* AVM cases, only two of the reported cases involved adult patients.^[5,14] Together, with the case we have presented in this paper, these reports comprised a very small, but growing body of literature that challenged the traditional view of the pathogenesis of cerebral AVMs.

The pathogenesis of AVMs remains ill defined. It is a widespread belief that AVMs are congenital, arising between weeks 4-8 of embryological growth.^[8] The symptomatic presentation of AVMs in adults before the age of 40, in addition to the *de novo* AVMs reported in children, support the concept of the temporal vulnerability of vascular elements to a physiologic or environmental trigger.^[20] These triggers, which can be mechanical, inflammatory, thrombogenic, ischemic/hypoxic, or hormonal, generally lead to hemodynamic stress.^[5,20] Disturbances of the venous drainage system may contribute to the formation of cerebral AVMs. Venous stenosis, occlusion, or agenesis during embryology or chronic venous hypertension during childhood and adulthood can result in tissue hypoxia and drive the impetus for angiogenesis.^[12,15,21,22,25] However, the role of the venous hypertension in the growth of an AVM remains indeterminate. Other vascular lesions such as dural or pial arteriovenous fistula in the brain and spine can develop after trauma, infection, or inflammation further support the notion of environmental influences stimulating angiogenesis. Many of these injuries result in the release or increased expression of transforming growth factor (TGF) and vascular endothelial growth factor (VEGF), which play important roles in angiogenesis. The overstimulation of angiogenesis due to these stressors leads to vascular remodeling and other changes resulting in the maturation of AVMs.^[24]

Table 1: Previously reported cases of *de novo* AVM formation

Literature	Patient gender	Age at time of initial imaging	Reason for initial imaging	Type of imaging performed	Age at AVM diagnosis	Presenting symptoms at time of AVM diagnosis	Type of imaging performed for AVM diagnosis
No prior vascular pathology							
Bulsara KR, Alexander MJ, Villavicencio AT, Graffagnino C: De novo cerebral arteriovenous malformation: Case report. <i>Neurosurgery</i> 50:1137-40; discussion 1140-1, 2002	Female	26 years old	Multiple cranial nerve deficits and ataxia a few days after a streptococcal throat infection. Exclusion of vasculitis	Cerebral angiogram	32 years old	Severe headache, nausea and vomiting	CT, MRI, cerebral angiogram
Gonzalez LF, Bristol RE, Porter RW, Spetzler RF: De novo presentation of an arteriovenous malformation: Case report and review of the literature. <i>J Neurosurg</i> 102:726-729, 2005	Female	3 years old	Struck by car suffering mild head injury and experiencing posttraumatic epilepsy	CT and MRI	7 years old	Intractable epilepsy	MRI, MR angiography, cerebral angiogram
Stevens J, Leach JL, Abruzzo T, Jones BV: De novo cerebral arteriovenous malformation: Case report and literature review. <i>AJNR Am J Neuroradiol</i> 30:111-112, 2009	Female	6 years old	Seizures and developmental delay	MRI	9 years old	Increased seizure activity, behavioral changes, ataxia, aphasia after minor head injury	CT, MRI
Mahajan A, Manchandia TC, Gould G, Bulsara KR: De novo arteriovenous malformations: Case report and review of the literature. <i>Neurosurg Rev</i> 33:115-119, 2010	Female	16 years old	Bell's Palsy	MRI	30 years old	5 year history of complicated migraines and 1 episode of seizure	CT post-contrast, MRI, bilateral carotid angiography
Ozsarac M, Aksay E, Kiyan S, Unek O, Gulec FF: De novo cerebral arteriovenous malformation: Pink floyd's song "brick in the wall" as a warning sign. <i>J Emerg Med</i> 43:e17-20, 2012	Male	25 years old	Evaluation of seizures leading to diagnosis of epilepsy treated with phenytoin	Cerebral angiogram	50 years old	Generalized tonic-clonic seizure	Non-contrast and contrast CT
Prior vascular pathology							
Schmit BP, Burrows PE, Kuban K, <i>et al.</i> Acquired cerebral arteriovenous malformation in a child with Moyamoya disease: case report. <i>J Neurosurg</i> 84:677-80, 1996	Female	2 years old	Cerebral infarctions, seizures	CT, angiogram-moyamoya	11 years old	Follow-up	MRI, cerebral angiogram
Akimoto H, Komatsu K, Kubota Y. Symptomatic de novo arteriovenous malformation appearing 17 years after the resection of two other arteriovenous malformations in childhood: case report. <i>Neurosurgery</i> 52 (1):228-232, 2003	Female	10 years old	Intraventricular hemorrhage	CT, cerebral angiogram, post-operative angiogram confirming complete AVM resection	27 years old	Sudden headache, right-sided numbness	CT, bilateral carotid angiography, post-operative angiogram confirming complete AVM resection
O'Shaughnessy BA, DiPatri AJ Jr, Parkinson RJ, Batjer HH. Development of a de novo cerebral arteriovenous malformation in a child with sickle cell disease and moyamoya arteriopathy. Case report. <i>J Neurosurg</i> 102 (2 Suppl):238-243, 2005	Female	3 years old	History of sickle cell disease and associated moyamoya arteriopathy	MRI	6 years old	Incidental finding	MRI, CT angiography, cerebral angiogram

Table 1: Contd...

Literature	Patient gender	Age at time of initial imaging	Reason for initial imaging	Type of imaging performed	Age at AVM diagnosis	Presenting symptoms at time of AVM diagnosis	Type of imaging performed for AVM diagnosis
Alvarez H, Perry V, Solle M, Castillo M. De novo cerebral arteriovenous malformation in a child with previous cavernous malformation and developmental venous anomaly. <i>J Neurosurg Pediatr</i> 9:327-330, 2012	Male	6 years old	Giant cavernous malformation	CT, MRI	8 years old	Incidental finding	MRI, cerebral angiogram
Bai Y, He C, Zhang H, Ling F. De novo multiple dural arteriovenous fistulas and arteriovenous malformation after embolization of cerebral arteriovenous fistula: Case report. <i>Childs Nerv Syst</i> 28:1981-1983, 2012	Male	3 years old	Generalized tonic-clonic seizure	MRI, angiogram-dural venous fistula	7 years old	Relapse of seizures 4 years after embolization of fistula and continued sodium valproate therapy	MRI, cerebral angiogram
Miki Fujimura, M.D., Ph.D., Naoto Kimura, M.D., Ph.D., Masayuki Ezura, M.D., Ph.D., Kuniyasu Niizuma, M.D., Ph.D., Hiroshi Uenohara, M.D., Ph.D., and Teiji Tominaga, M.D., Ph.D. Development of a de novo arteriovenous malformation after bilateral revascularization surgery in a child with moyamoya disease. <i>Journal of Neurosurgery: Pediatrics</i> 0:0, 1-3, 2014	Female	10 years old	Transient ischemic attack with hemodynamic compromise of bilateral hemispheres in setting of Moyamoya disease	MRI, MR angiography	14 years old	Follow-up for bilateral direct and indirect revascularization surgery	MR angiography, cerebral angiogram

AVM: Arteriovenous malformations, MRI: Magnetic resonance imaging, CT: Computerized tomography

Genetic etiologies for cerebral AVMs are also currently being explored. AVMs have been known to occur in the context of certain genetic disorders, such as hereditary hemorrhagic telangiectasia (HHT), Wyburn–Mason syndrome, and Sturge–Weber syndrome. Through studies of knockout mice modeled after the loss-of-function mutations found in HHT, a genetic two-hit mechanism has been proposed for the development of AVMs.^[10] In this two-hit model, a loss-of-function mutation of various receptors in the TGF- β family or a dysregulation of nitric oxide synthase activity results in vascular destabilization. This leaves the vasculature more vulnerable to a second hit by environmental factors.

The growing number of sporadic cases of cerebral AVMs still warrants an explanation. Some studies suggest that germ-line mutations of certain proteins may be involved in AVM development.^[10,19] Potential target proteins include endothelial angioprotein receptor Tie-2, TGF- β , nitric oxide synthase, vascular endothelial growth factor (VEGF), and fibroblast growth factor. A recent study has also suggested an association between single nucleotide polymorphisms and sporadic cerebral AVM susceptibility, implicating proteins, and cytokines involved in the inflammatory

cascade, angiogenesis, vascular remodeling, and stabilization.^[23]

Thus the pathomechanism of cerebral AVMs remains incompletely elucidated. The theory of congenital formation of all cerebral AVMs is being challenged as *de novo* AVMs are increasingly being reported. This case report documents a rare occurrence of a symptomatic *de novo* AVM in an adult male with no prior vascular cerebral pathology with an initial negative MRI at age 15 who subsequently developed an AVM on later imaging, providing further evidence that not all cerebral AVMs are congenital.

ACKNOWLEDGMENTS

The authors have no personal or institutional interest with regard to the authorship and/or publication of this manuscript.

REFERENCES

1. Akimoto H, Komatsu K, Kubota Y. Symptomatic de novo arteriovenous malformation appearing 17 years after the resection of two other arteriovenous malformations in childhood: Case report. *Neurosurgery* 2003;52:228-31.

2. Al-Shahi R, Warlow C. A systematic review of the frequency and prognosis of arteriovenous malformations of the brain in adults. *Brain* 2001;124:1900-26.
3. Alvarez H, Perry V, Solle M, Castillo M. De novo cerebral arteriovenous malformation in a child with previous cavernous malformation and developmental venous anomaly. *J Neurosurg Pediatr* 2012;9:327-30.
4. Bai Y, He C, Zhang H, Ling F. De novo multiple dural arteriovenous fistulas and arteriovenous malformation after embolization of cerebral arteriovenous fistula: Case report. *Childs Nerv Syst* 2012;28:1981-3.
5. Bulsara KR, Alexander MJ, Villavicencio AT, Graffagnino C. De novo cerebral arteriovenous malformation: Case report. *Neurosurgery* 2002;50:1137-40.
6. Farhat HI. Cerebral arteriovenous malformations. *Dis Mon* 2011;57:625-37.
7. Friedlander RM. Clinical practice. Arteriovenous malformations of the brain. *N Engl J Med* 2007;356:2704-12.
8. Garretson H. Intracranial arteriovenous malformations, in Wilkins RH RS: *Neurosurgery*, New York: McGraw-Hill; 1996. p. 2433-42.
9. Gonzalez LF, Bristol RE, Porter RW, Spetzler RF. De novo presentation of an arteriovenous malformation: Case report and review of the literature. *J Neurosurg* 2005;102:726-9.
10. Leblanc GG, Golanov E, Awad IA, Young WL; Biology of Vascular Malformations of the Brain NINDS Workshop Collaborators: Biology of vascular malformations of the brain. *Stroke* 2009;40:e694-702.
11. Mahajan A, Manchandia TC, Gould G, Bulsara KR. De novo arteriovenous malformations: Case report and review of the literature. *Neurosurg Rev* 2010;33:115-9.
12. Nussbaum ES, Heros RC, Madison MT, Awasthi D, Truwit CL. The pathogenesis of arteriovenous malformations: Insights provided by a case of multiple arteriovenous malformations developing in relation to a developmental venous anomaly. *Neurosurgery* 1998;43:347-51.
13. O'Shaughnessy BA, DiPatri AJ Jr, Parkinson RJ, Batjer HH. Development of a de novo cerebral arteriovenous malformation in a child with sickle cell disease and moyamoya arteriopathy: Case report. *J Neurosurg* 2005;102 (2 Suppl):S238-43.
14. Ozsarac M, Aksay E, Kiyas S, Unek O, Gulec FF. De novo cerebral arteriovenous malformation: Pink floyd's song "brick in the wall" as a warning sign. *J Emerg Med* 2012;43:e17-20.
15. Pietila TA, Zabramski JM, Thellier-Janko A, Duvencek K, Bichard WD, Brock M, et al. Animal model for cerebral arteriovenous malformation. *Acta Neurochir (Wien)* 2000;142:1231-40.
16. Rodriguez-Arias C, Martinez R, Rey G, Bravo G. Recurrence in a different location of a cerebral arteriovenous malformation in a child after radiosurgery. *Childs Nerv Syst* 2000;16:363-5.
17. Schmit BP, Burrows PE, Kuban K, Goumnerova L, Scott RM. Acquired cerebral arteriovenous malformation in a child with moyamoya disease: Case report. *J Neurosurg* 1996;84:677-80.
18. Song JK, Niimi Y, Kupersmith MJ, Berenstein A. Postnatal growth and development of a cerebral arteriovenous malformation on serial magnetic resonance imaging in a child with hemangiomas: Case report. *J Neurosurg* 2007;106 (5 Suppl):S384-7.
19. Stapf C, Mohr JP. New concepts in adult brain arteriovenous malformations. *Curr Opin Neurol* 2000;13:63-7.
20. Stevens J, Leach JL, Abruzzo T, Jones BV. De novo cerebral arteriovenous malformation: Case report and literature review. *AJNR Am J Neuroradiol* 2009;30:1111-2.
21. Streeter G. The development of the venous sinus of the dura mater in the human embryo. *Am J Anat* 1915;18:145-78.
22. Streeter G. The developmental alterations in the vascular system of the brain of the human embryo. *Contrib Embryol* 1918;8:5-38.
23. Sturiale CL, Puca A, Sebastiani P, Gatto I, Albanese A, Di Rocco C, et al. Single nucleotide polymorphisms associated with sporadic brain arteriovenous malformations: Where do we stand? *Brain* 2013;136:665-81.
24. Sure U, Butz N, Schlegel J, Siegel AM, Wakat JP, Mennel HD, et al. Endothelial proliferation, neoangiogenesis, and potential de novo generation of cerebrovascular malformations. *J Neurosurg* 2001;94:972-7.
25. Wilson CB. Cryptic vascular malformations. *Clin Neurosurg* 1992;38:49-84.