

The appearance of angiolipomatosis after using laptop computer on the thighs: a relationship?

Marie Caucanas,¹ Gebhard Müller,²
Olivier Vanhooetghem¹

¹Department of Dermatology,
Clinique Sainte Elisabeth, Namur;

²Institute of Pathology and Genetics,
Gosselies, Belgium

Abstract

A 56-year-old patient developed angiolipomatosis of the anterior part of the thighs after repeated laptop contact localisation. Histological findings exhibit an unusual inflammatory infiltrate. We postulate that the computer could favour lipoma development by a physiopathological mechanism that remains to be clarified.

Case Report

A 56-year-old woman gradually developed subcutaneous nodules on the thighs over the course of two years. The patient has no medical or familial history and does not take any medication. She is a speech specialist and admits working several times a week for a couple of hours with her laptop over her thighs. Clinical examination shows the existence of approximately ten nodules strictly localised on the anterior part of the thighs (Figure 1), suggesting clinical lipomatosis.

An excisional biopsy of a nodule shows angiolipomatosis with mild to moderate inflammatory infiltrate with CD68-positive macrophages and T lymphocytes (Figure 2).

The patient stopped putting her laptop on her thighs for one year and observed stabilisation of nodule count number, but no regression was noted.

Discussion

This is the first description of a secondary lipomatosis of the thighs with the regular use of a laptop computer on this specific location. Histological examination shows angiolipomatosis associated with an inflammatory infiltrate of histiocytes and T lymphocytes. According to the imputability criteria,¹

it is highly plausible that the use of the laptop in contact with the thighs caused the development of underlying lipomas, as the rapid onset of nodules was observed with the use of the laptop, and the stabilisation of the lesions was observed after the laptop was no longer used at that location. This suggests a symmetric semiology and parallel evolution, and the absence of any other explanation for the condition after full examination supports this conclusion despite the absence of any reliable specific complementary examination proving the link of causality to the histological findings. We think that the laptop is responsible for the development of the lipomas. The inflammation found upon histological examination could have been provoked by the computer through an unknown mechanism and could involve the influence of the heat emitted by the battery and/or the electromagnetic waves emanating from the device. After changing her working habits, the number of lipomas stabilised but did not regress.

The use of new technologies, which continue to development and become more accessible, were recently associated with unsuspected pathologies. The semicircular lipoatrophy of the thighs, described by a series of hundreds of patients in companies equipped with the most recent models of fixed computers, is secondary to electromagnetic lipolysis, which is facilitated by local circumstances such as the conductivity of the material of the desks, the ambient humidity and the inappropriate insulation of computer wiring.²⁻⁶

Correspondence: Olivier Vanhooetghem, Sainte Elisabeth Hospital, Dermatology Unit, Namur, Belgium.

E-mail: ovanhooetghem@hotmail.com

Key words: lipoma, angiolipomatosis, laptop computer, electromagnetic waves, thighs, nodules.

Conflict of interest: all authors certified that they have no conflicts of interest, including specific financial interests and relationships and affiliations relevant to the subject of this manuscript.

Received for publication: 6 August 2011.

Accepted for publication: 9 August 2011.

This work is licensed under a Creative Commons Attribution NonCommercial 3.0 License (CC BY-NC 3.0).

©Copyright M. Caucanas et al., 2011

Licensee PAGEPress, Italy

Dermatology Reports 2011; 3:e22

doi:10.4081/dr.2011.e22

Five cases of erythema ab igne dermatitis developed after regular use of a laptop on the thighs have been described since 2004.⁷⁻¹⁴ As suggested by the case of our patient, the development of lipoma could be a consequence of the extensive usage of the computer with immediate contact on the body. The exact physiopathological mechanism behind this pathology remains to be clarified.

References

1. Bégaud B, Evreux JC, Jouglard J, Lagier G. Imputabilité des effets inattendus ou toxiques des médicaments. Actualisation de la méthode utilisée en France. *Therapie* 1985;40:111-8.
2. Flagothier C, Quatresooz P, Pierard G-E. Electrolipolysis and semicircular lipoatrophy of the thighs. *Ann Dermatol Venereol* 2006;133:577-80.
3. Panella H, Juanola E, de Peray JL, Artazcoz L. Semicircular lipoatrophy: a new occupational disease. *Gac Sanit* 2008;22:73-5.
4. Lachapelle JM, Tennstedt D. Nouvelles dermatoses de l'environnement. *Progress en dermato-allergologie*. Dijon 2002. Ed. E. Collet. John Libbey Eurotext, Montrouge 2002, pp.157-65.
5. Hermans V, Hautekiet M, Haex B, Spaepen AJ, Van der Perre G. Lipoatrophia semicircularis and the relation with office work. *Applied Ergonomics* 1999;30:319-24.
6. Curvers B, Maes A. Lipoatrophia semicircularis: a new office disease? 900 cases reported in Belgium. www.next-up.org

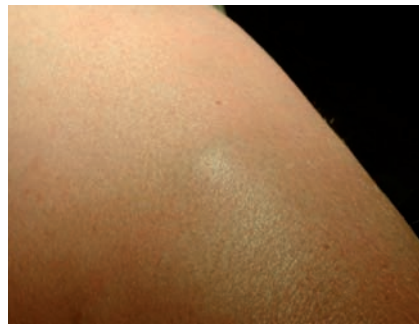


Figure 1. Lipomatosis of the anterior part of the thigh.

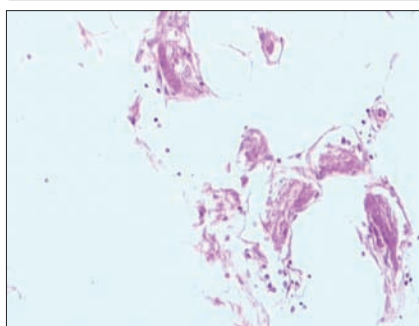


Figure 2. Inflammatory infiltrate associated with angiolipomatosis.

7. Bilic M, Adams BB. Erythema ab igne induced by a laptop computer. *J Am Acad Dermatol* 2004;50:973-4.
8. Jagtman BA. Erythema ab igne due to a laptop computer. *Contact Dermatitis* 2004;50:105.
9. Maalouf E, Simantov A, Rosenbaum F, Chosidow O. Erythema ab igne as an unexpected computer side-effect. *Dermatology* 2006;212:392-3.
10. Mohr MR, Scott KA, Pariser RM, Hood AF. Laptop computer-induced erythema ab igne: a case report. *Cutis* 2007;79:59-60.
11. Levinbook WS, Mallett J, Grant-Kels JM. Laptop computer associated erythema ab igne. *Cutis* 2007;80:319-20.
12. Bachmeyer C, Bensaid P, Bégon E. Laptop computer as a modern cause of erythema ab igne. *J Eur Acad Dermatol Venereol* 2009;23:736-7.
13. Fite C, Bouscarat F. Laptop computer-induced erythema Ab Igne. *Presse Med* 2009;38:1164-5.
14. Gohar A. Comment on the letter by Bachmeyer, Bensaid and Bégon on laptop computer as a modern cause of erythema ab igne. *J Eur Acad Dermatol Venereol* 2009;23:1221-2.