

Nocardia Infections in Congenitally Athymic (Nude) Mice and in Other Inbred Mouse Strains

P. I. FOLB,^{1*} A. TIMME,² AND A. HOROWITZ³

Departments of Pharmacology¹ and Pathology,² University of Cape Town Medical School, Cape Town, South Africa, and Departments of Medicine and Pathology, Ch. Sheba Medical Center, Tel Hashomer and Tel Aviv University Medical School, Tel Aviv, Israel³

Received for publication 20 June 1977

The mortality rate and histopathological features of *Nocardia asteroides* and *Nocardia brasiliensis* infections in congenitally athymic (nude) mice of ICR and C₃H/eB origins were quite different from what we found for Swiss white mice and other inbred mouse strains (namely, C57/BL/6J, New Zealand Black, BALB/c, CBA/LAC, and C₃H/eB). The immunocompetent littermates of the congenitally athymic mice occupied an intermediate position between their athymic siblings and Swiss white mice in terms of their responses to both these organisms. Macrophage ingestion and destruction of *N. brasiliensis*, as demonstrated by electron microscopy, was found to occur. The T-lymphocyte appears to be an essential component in normal mouse resistance to infection by both *N. asteroides* and *N. brasiliensis*.

Nocardia infections in humans are becoming increasingly common after transplantation surgery (1, 10) and in patients whose normal immunity has been undermined by immunosuppressive drug therapy (5, 11). The precise mechanisms by which nocardiosis develops in these situations have not been defined, although there is some evidence to suggest that disorders of cell-mediated immunity may be of particular importance in the pathogenesis of these infections (6, 10, 11).

In an attempt to define more clearly the role of the T-lymphocyte in normal host immunity to *Nocardia* infections, we have studied the natural history, cumulative mortality, histopathological features, and electron microscopic (EM) features of experimental *Nocardia asteroides* and *Nocardia brasiliensis* infections in congenitally athymic (nude) mice. Comparison was made with the model we have established in Swiss white mice (6) and with other inbred mouse strains, namely, C57/BL/6J, New Zealand Black (NZB), BALB/c, CBA/LAC, and C₃H/eB.

The EM studies were directed towards determining whether or not macrophage function is normal in thymus- and T-lymphocyte-depleted nude mice infected with *Nocardia*.

Our studies of nocardia infections in Swiss white mice (6) have shown that *N. asteroides* and *N. brasiliensis* produce distinctive lesions, which are quite different in their morphological appearances. This was in accordance with the earlier findings of Uesaka et al. (12), from whom

we took the terms "asteroides lesion" and "brasiliensis lesion." An acute suppurative abscess characterizes the lesions of *N. asteroides*. The "brasiliensis lesion" is a granuloma, in which a striking feature is the presence of large numbers of foam-laden macrophages. EM studies have demonstrated that these macrophages contain within their cytoplasm organisms in varying stages of degeneration.

MATERIALS AND METHODS

***Nocardia* organisms.** The cultures of *N. asteroides* and *N. brasiliensis* were isolated, respectively, from the sputum and from a subcutaneous abscess of patients suffering from clinical illnesses. The actinomycetes were identified and characterized by established criteria (7, 9). Confirmation of the *N. asteroides* isolate was obtained from Ruth Gordon, Rutgers University, New Brunswick, N.J. The *N. brasiliensis* culture was confirmed by L. Kaufman, Center for Disease Control, Atlanta, Ga.

Experimental mice. Swiss white mice weighing between 25 and 30 g were used. Congenitally athymic (nude) mice of both ICR and C₃H/eB origins, and their normal littermates, and ICR, C57/BL/6J, NZB, BALB/c, CBA/LAC, and C₃H/eB mice, weighing between 25 and 30 g, were obtained from the Veterinary Department, Weizmann Institute, Rehovot, Israel.

Inoculations. The mice were inoculated intraperitoneally in the manner we described previously (6).

Pathological studies. Intraperitoneal *N. asteroides* infections were produced in the following mouse strains: Swiss white, ICR, ICR nude (nu/nu) and their normal littermates (nu/+), C₃H/eB nude (nu/nu) and their normal littermates (nu/+), NZB, BALB/c, C57/BL/6J, and CBA/LAC. In each case 10 mice

were studied. With the exception of the nude mice, four mice were examined from each group at intervals of 11 and 21 days, and two mice were examined at 60 days after inoculation. The mice were anesthetized and killed with ethyl ether. In the two groups of nude mice, five were examined from each group at 11 days, and the remainder of those surviving were examined at 21 days. A full postmortem examination in each case, including those mice that died during the course of the experiment, was performed. Portions of the organs, including the brain, were taken for histological examination. These experiments were repeated in an identical manner with inoculations of *N. brasiliensis*.

Routine staining of the histological sections and postmortem bacteriological examinations were performed as we described previously (6).

EM studies. Selected lesions produced by *N. brasiliensis* in ICR nude mice and their normal littermates were removed for EM study. The EM studies were confined to lesions at 11 days after inoculation. The method used for the fixation, preparation, and cutting of the specimens was the same as that described previously (6). A Siemens 1A electron microscope was used.

Cumulative mortality studies. In a separate experiment, 10 mice from each of the following groups were inoculated intraperitoneally with 10 mg (wet weight) of *N. asteroides* cells: Swiss white, ICR, ICR nu/nu and their normal littermates, C₃H/eB, C₃H/eB nu/nu and their normal littermates, NZB, BALB/c, C57/BL/6J, and CBA/LAC. In the case of the Swiss white and the nude mice and their littermates, this experiment was repeated once. A control group of 10 mice was injected intraperitoneally with 0.5 ml of sterile saline. (This dose of inoculum was chosen since higher doses of the organism had produced a uniformly high mortality rate.)

The experiment was repeated in an identical manner with inoculations of *N. brasiliensis*.

RESULTS

There were no differences in cumulative mortality rate or in histopathological features produced by *N. asteroides* and *N. brasiliensis*, respectively, in Swiss white mice and in the ICR, C₃H/eB, NZB, BALB/c, C57/BL/6J, and CBA/LAC mice. (This does not refer to the nude varieties of the ICR and C₃H/eB mice; Table 1.) The characteristic *asteroides* and *brasiliensis* lesions, which were demonstrated to occur consistently in the Swiss white mice (6), were found with the same consistency in each of these genetic mouse strains.

In the groups of ICR and C₃H/eB nude mice, the cumulative mortality produced by both *N. asteroides* and *N. brasiliensis* infections differed considerably from that which had been noted for the Swiss white mice and the other inbred strains referred to above. Within 28 days of inoculation both *N. asteroides* and *N. brasiliensis* had produced 100% mortality in the nude mice. The cumulative mortality in the nude

mouse groups over the first 28-day period differed from that in all the other mouse groups at a significance level of $P < 0.001$. There was no difference in cumulative mortality in the normal littermates (nu/+) of the ICR and C₃H/eB nude mice after inoculations of *N. asteroides* and *N. brasiliensis* or in the Swiss white mice and the other inbred strains (Table 1).

N. asteroides produced a fulminating systemic disease in the ICR and C₃H/eB strains of nude mice. There was no localization of the organism at the original site of inoculation in the peritoneum. A disseminated pyemic process involving virtually every organ of the body was well established by day 11 after inoculation. Invariably the organs involved with abscess formation included skin and subcutaneous tissues, lymph nodes, lungs, liver, skeletal muscle, and retro-orbital area. Remarkably, no case of metastatic spread to the brain or meninges was noted. The brain appeared to be protected from the disseminated effects of the infection. The microscopic features of the microabscesses produced did not differ appreciably from those found in the Swiss white mouse (6).

The morbid anatomical features of the infection resulting from inoculation of *N. brasiliensis* in the nude mice were identical to those produced by *N. asteroides*, described above. The characteristic *brasiliensis* lesion that was noted on histological examination in Swiss white mice (6) did not develop in nude mice. There were occasional exceptions to this general statement, when a typical *brasiliensis* lesion or an identifiable *forme fruste* was noted in the nude mice. Generally, multiple pyemic lesions characterized by necrosis and an acute purulent reaction were found. Hyaloid bodies and the marked lymphocytic reaction, which were characteristic of the "*brasiliensis* lesion," were not apparent. Numerous organisms were identified in the center of the necrotic area. There was early capsule formation at the periphery of the lesions by 11 days, and this was further developed by 21 days. In common with the *brasiliensis* lesion in the Swiss white mouse, numerous large macrophages were noted at the periphery of the lesions (6).

The electron microscopic studies confirmed that the *N. brasiliensis* organisms were both free-lying and ingested by the macrophages. The ultrastructural features of the former were similar to those described for *N. asteroides*, except that the cell wall was not as thick as has been illustrated for *N. asteroides* (2) (Fig. 1). Once the organisms had been phagocytosed they became surrounded by the single membrane of the phagosome (Fig. 2). Dense granular or fibrillar material partly filled the residual space of the

TABLE 1. *Cumulative mortality studies*

Mouse strain	Inoculation	No. of mice inoculated	Cumulative mortality ^a at:		
			11 days	21 days	28 days
Swiss white	<i>N. asteroides</i>	20	0	0	0
	<i>N. brasiliensis</i>	20	2	2	2
	Saline	10	0	0	0
ICR	<i>N. asteroides</i>	10	0	0	0
	<i>N. brasiliensis</i>	10	0	0	0
ICR-nu/nu	<i>N. asteroides</i>	20	4	11	20
	<i>N. brasiliensis</i>	20	8	13	20
	Saline	10	0	0	0
ICR-nu/+ (littermates)	<i>N. asteroides</i>	20	4	6	6
	<i>N. brasiliensis</i>	20	1	2	2
	Saline	10	0	0	0
C ₃ H/eB	<i>N. asteroides</i>	10	0	0	1
	<i>N. brasiliensis</i>	10	0	0	0
C ₃ H/eB-nu/nu	<i>N. asteroides</i>	20	9	18	20
	<i>N. brasiliensis</i>	20	11	16	20
	Saline	10	0	0	2
C ₃ H/eB-nu/+ (littermates)	<i>N. asteroides</i>	20	0	2	3
	<i>N. brasiliensis</i>	20	0	4	4
	Saline	10	0	0	0
NZB	<i>N. asteroides</i>	10	0	0	0
	<i>N. brasiliensis</i>	10	0	0	0
BALB/c	<i>N. asteroides</i>	10	0	0	0
	<i>N. brasiliensis</i>	10	0	0	0
C57/BL/6J	<i>N. asteroides</i>	10	0	0	0
	<i>N. brasiliensis</i>	10	0	0	0
CBA/LAC	<i>N. asteroides</i>	10	2	2	2
	<i>N. brasiliensis</i>	10	0	0	0

^a Cumulative mortality of various mouse strains after intraperitoneal inoculation of 10 mg (wet weight) of *N. asteroides* or *N. brasiliensis* suspended in 0.5 ml of normal saline.

phagosome and adhered to the wall of the organism. Dense round or oval bodies, which were presumed to be lysosomes, were commonly present in the vicinity of the organisms, but fusion of these structures with the phagosomes was not observed (Fig. 2 and 3). The earliest degenerative changes noted in the organisms were variable reduction in the number of lipid vacuoles and polyphosphate granules (Fig. 2). These changes became more pronounced, so that lipid vacuoles, dense granules, and ribosomes could no longer be identified, and the cells contained only thin strands of nuclear material and mesosomes (Fig. 3). The cell wall generally became appreciably thickened. In the more advanced stages of disintegration, only osmophilic debris or membranous fragments were found in the interior of the cells, but the cell membrane re-

mained surprisingly intact in some cases (Fig. 4). Ultimately, only dense cell walls could be identified (Fig. 5). In some macrophages several organisms separated by septa were found.

In the littermates of the congenitally athymic mice, a picture intermediate between the ICR and C₃H/3B mice and their nude counterparts was found with respect to cumulative mortality, dissemination of the primary infection, and histopathological changes. In the case of *N. brasiliensis*, the typical brasiliensis lesion was found in only 2 of 10 of both the ICR and C₃H/3B littermates. Dissemination of infection from the primary peritoneal source of the infection was found in 5 of 10 of the ICR littermates and in 6 of 10 of the C₃H/eB littermates. However, foam-laden macrophages, which are a feature of the brasiliensis lesion in Swiss white mice (6), were

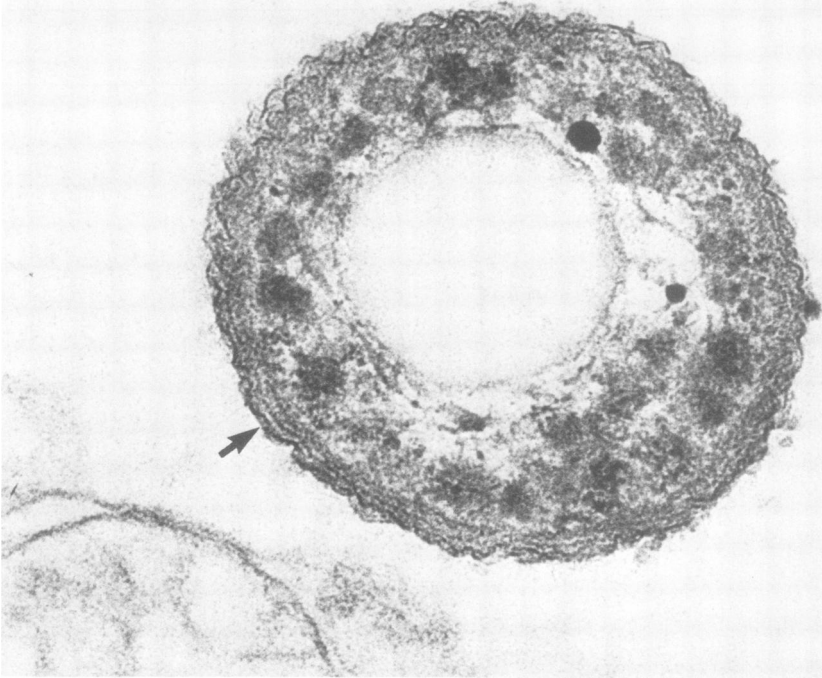


FIG. 1. Electron micrograph of a free-lying *N. brasiliensis*, 11 days after inoculation. The cell wall (arrow) stains more densely than the trilaminar cell membrane immediately internal to it. $\times 150,000$. Nude (*nu/nu*) mouse.

invariably identified, even when other features of the typical granuloma were absent.

The progressive degenerative changes in *N. brasiliensis* organisms, which were demonstrated by EM to take place in the macrophages of the littermates, proved to be similar to those that were noted in the nude mice. However, certain organisms showed a different change in their structure, and these findings were confined to the littermates only. These organisms were more slender and lance shaped, and the cell content was more uniformly dense staining, without the normal lipid vacuoles and dense granules being obvious. The wall of the organism thickened (Fig. 6). The ultimate fate of these organisms could not be determined, but it appeared to be the same as that already shown in *N. brasiliensis* infection in Swiss white mice (6).

DISCUSSION

These findings demonstrate that there is an altered natural history and mortality produced

by both *N. asteroides* and *N. brasiliensis* in congenitally athymic (nude) mice, compared with Swiss white mice and the other inbred strains examined. Both organisms invariably produced disseminated infection and a high mortality in nude mice. The loss of the ability of nude mice to produce a granuloma in response to *N. brasiliensis* suggests that the T-lymphocyte has a central role in the development of the granuloma. The results obtained in the C57/BL/6J, NZB, ICR, BALB/c, CBA/LAC, and C₃H/eB mice indicate that other genetic factors do not influence the pathological picture that we have described previously for Swiss white mice (6).

The littermates (*nu/+*) occupied an intermediate position between the nude (*nu/nu*) and other mice studied, in terms of mortality and histological response to inocula of both *N. asteroides* and *N. brasiliensis*. It is possible that the reduction in the number of θ -bearing lymphocytes in littermates of nude mice (8) might ac-

FIG. 2. *N. brasiliensis*, 11 days after inoculation. Intact organisms are seen within phagosomes. There is granular or fibrillar material adherent to the cell wall (arrow). $\times 45,000$. Nude (*nu/nu*) mouse.

FIG. 3. *N. brasiliensis*, 11 days after inoculation. Thin strands of nuclear material and a mesosome (*m*) are seen in this organism, but ribosomes and dense granules are absent. Lysosomal dense bodies are noted in the proximity. $\times 45,000$. Nude (*nu/nu*) mouse.

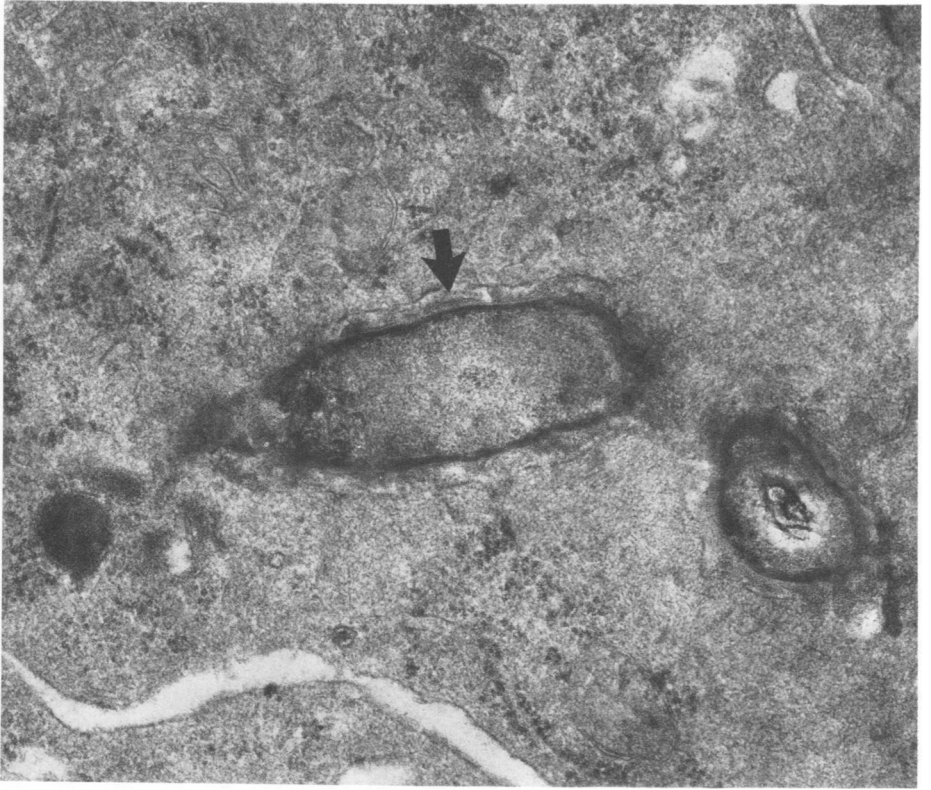


FIG. 2.

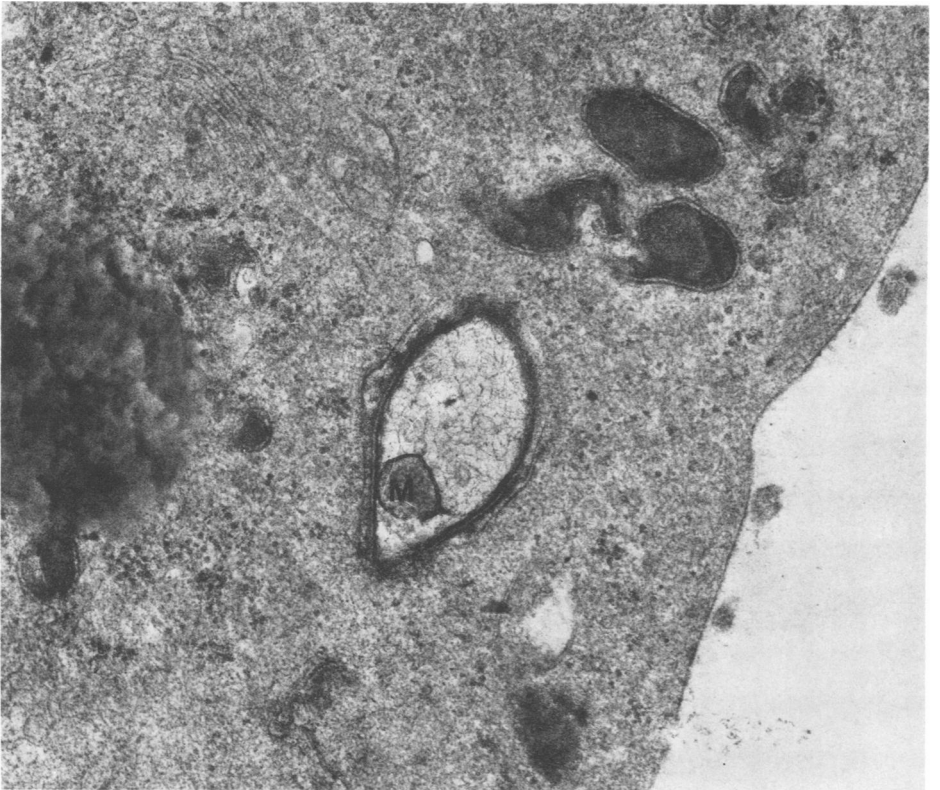


FIG. 3.

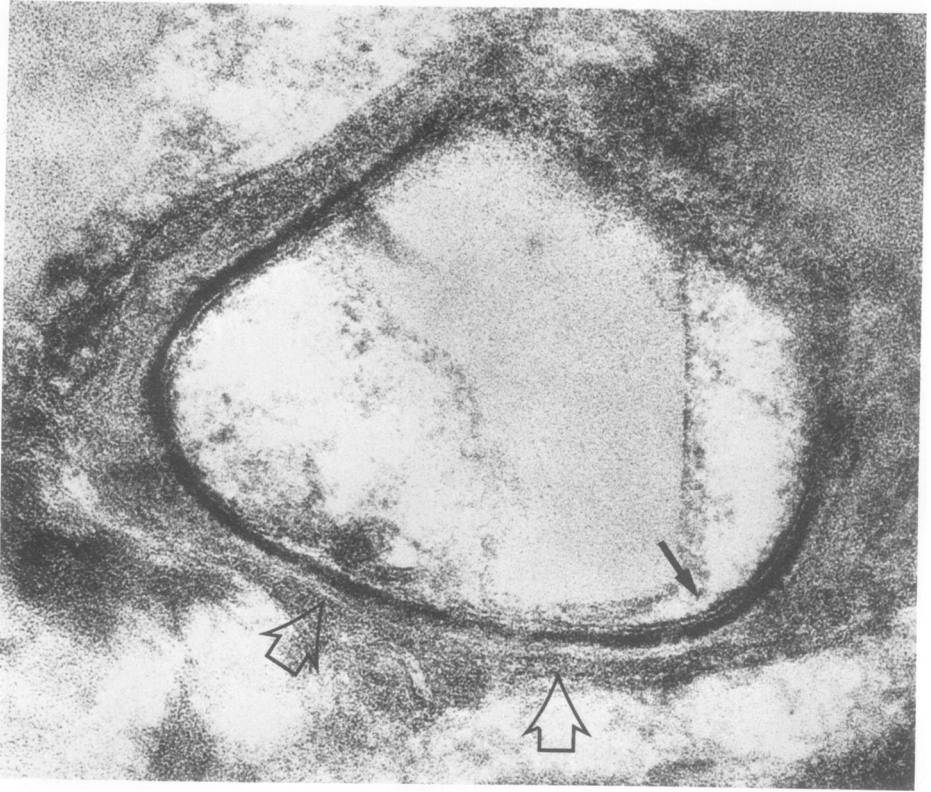


FIG. 4.

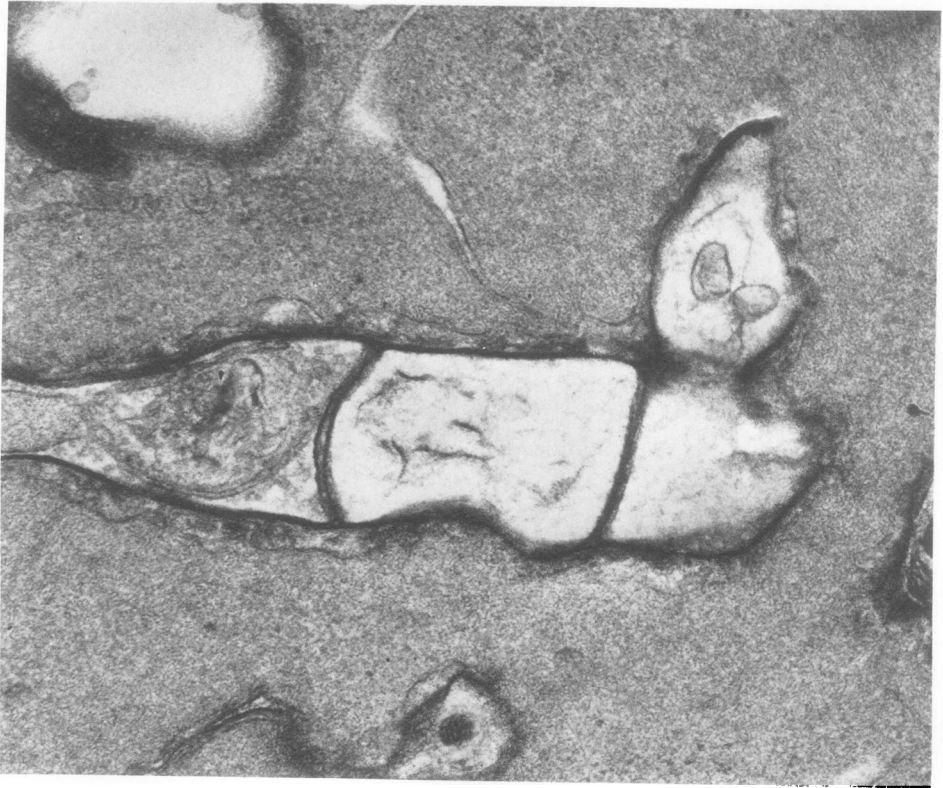


FIG. 5.

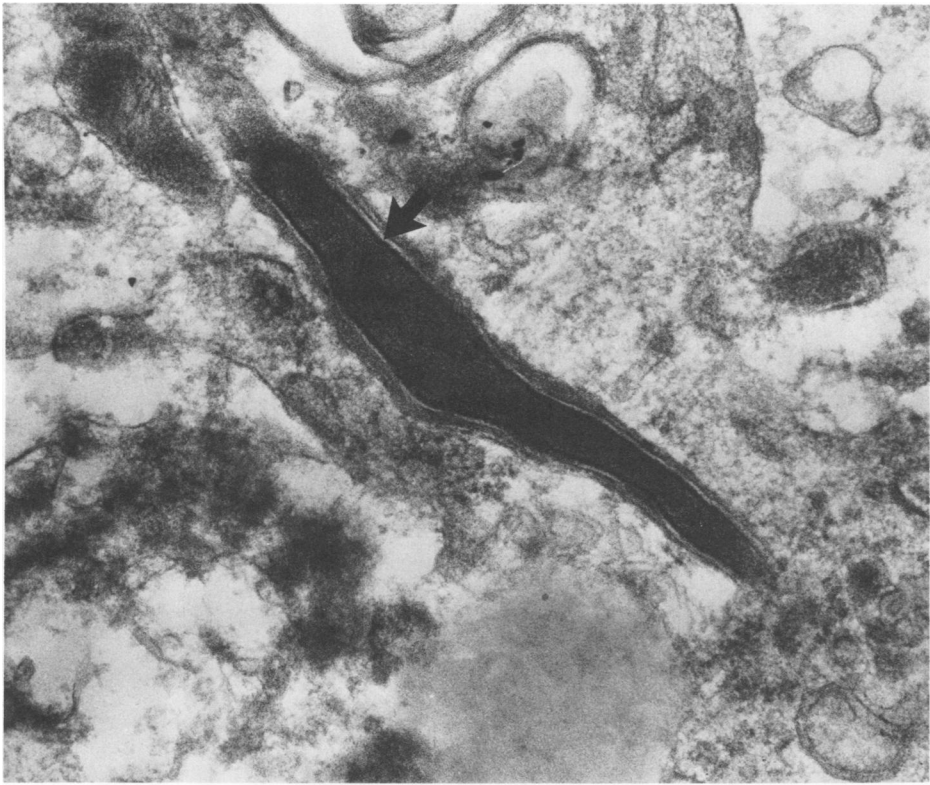

FIG. 6. *N. brasiliensis* infection in the littermate (nu/+) of a nude mouse, 11 days after inoculation. The organism has assumed a lanceolate appearance, and no normal internal structure can be noted. The arrow indicates a thickened cell wall. $\times 40,000$.

count for this rather unexpected finding in what normally are regarded as negative controls for their abnormal siblings. It would appear that the nu/+ littermate has limited value as a control in the study of experimental nocardiosis.

In the case of *N. brasiliensis* infection, the EM studies showed that the capacity of the macrophages of nude mice and their littermates both to phagocytose the organism and subsequently to produce its degradation was comparable to that demonstrated in Swiss white mice. This finding is in contradistinction to what has been described in experimental *Listeria monocytogenes* infection, where the presence of sensitized T-lymphocytes has been shown to directly influence the macrophages in their capacity to ingest and kill the organism (4), although macrophages of nude mice are capable of being activated during the course of *L. monocytogenes*

infection (3). Our findings, as do those of Cheers and Waller (3), have interesting implications in terms of their demonstration of possible autonomy of the macrophage from the T-lymphocyte system in nude mice, and they further highlight the caution required in interpreting the antibacterial immune status of nude mice as hosts.

The thickening that we have demonstrated by EM to occur in the cell wall of *N. brasiliensis* after phagocytosis by macrophages has been described by Beaman (2). We were surprised to find that the trilaminar pattern of the cell membrane remained clearly discernible in portions even when the organisms had reached an advanced stage of disintegration. This suggests that the cell wall is remarkably resistant to lysosomal attack. The nature of the condensed material surrounding the organisms in the phagosomes is not clear. The ultrastructural findings

FIG. 4. *N. brasiliensis* in an advanced stage of degeneration, 11 days after inoculation. The trilaminar image of the cell membrane is indicated by the small arrow, and fibrillar material adherent to the thickened cell wall is indicated by the open arrows. $\times 150,000$. Nude (nu/nu) mouse.

FIG. 5. *N. brasiliensis* in the final stages of degradation, 11 days after inoculation. Only thickened cell wall can be identified. A septate appearance is noted. $\times 45,000$. Nude (nu/nu) mouse.

suggest that microfilaments may contribute to the formation of this material. The significance of the lanceolate transformation of some organisms in the littermates is obscure.

The characteristics of the end stage of the organism of *N. brasiliensis* depicted in Fig. 6 (littermate) differ from those of the nude mouse and are similar to those we have observed for Swiss white mice (6). In Swiss white mice and their littermates, we have noted two forms of degeneration of nocardia organisms. In nude mice the degenerating organisms appear to take one form only. The significance of this observation with regard to the pathogenesis or immune basis of *N. brasiliensis* infection is not clear.

It is clear that much work remains to be done before we can understand basic mechanisms of normal host defense against *Nocardia* organisms.

ACKNOWLEDGMENT

This work was supported by a grant awarded to P.I.F. by the Chief Scientist, Ministry of Health, Israel.

LITERATURE CITED

- Bach, M. C., A. Sahyoun, J. L. Adler, R. M. Schlesinger, J. Breman, P. Madras, F.-K. Pleng, and A. P. Monaco. 1973. Influence of rejection therapy on fungal and nocardial infections in renal-transplant recipients. *Lancet* **i**:180-184.
- Beaman, B. L. 1973. An ultrastructural analysis of nocardia during experimental infections in mice. *Infect. Immun.* **8**:828-840.
- Cheers, C., and R. Waller. 1975. Activated macrophages in congenitally athymic "nude" mice and in lethally irradiated mice. *J. Immunol.* **115**:844-847.
- Emmerling, P., H. Finger, and J. Bockemuhl. 1975. *Listeria monocytogenes* infection in nude mice. *Infect. Immun.* **12**:437-439.
- Folb, P. I., G. Altmann, D. Merzbach, and E. Ipp. 1976. Nocardiosis in Israel. *Isr. J. Med. Sci.* **12**:150-153.
- Folb, P. I., R. Jaffe, and G. Altmann. 1976. *Nocardia asteroides* and *Nocardia brasiliensis* infections in mice. *Infect. Immun.* **13**:1490-1496.
- Georg, L. K., L. Ajello, C. McDermont, and T. S. Hosty. 1961. The identification of *Nocardia asteroides* and *Nocardia brasiliensis*. *Am. Rev. Respir. Dis.* **84**:337-347.
- Gershwin, M. E., B. Merchant, M. C. Gelfand, J. Vickers, A. D. Steinberg, and C. T. Hansen. 1975. The natural history and immunopathology of outbred athymic (nude) mice. *Clin. Immunol. Immunopathol.* **4**:324-340.
- Gordon, M. A. 1974. Aerobic pathogenic *Actinomycetales*, p. 175-188. *In* E. H. Lennette, E. H. Spaulding, and J. P. Truant (ed.), *Manual of clinical microbiology*, 2nd ed. American Society for Microbiology, Washington, D.C.
- Krick, J. A., E. B. Stinson, and J. S. Remington. 1975. *Nocardia* infection in heart transplant patients. *Ann. Intern. Med.* **82**:18-26.
- Palmer, D. L., R. L. Harvey, and J. K. Wheeler. 1974. Diagnostic and therapeutic considerations in *Nocardia asteroides* infection. *Medicine (Baltimore)* **53**:391-401.
- Uesaka, I., K. Oiwa, K. Yasuhira, Y. Kobara, and N. M. McClung. 1971. Studies on the pathogenicity of *Nocardia* isolates for mice. *Jpn. J. Exp. Med.* **41**:443-457.