



Angiokeratoma circumscriptum of the buccal mucosa: a case report and literature review

Young-Hoon Kang*, June-Ho Byun*, Bong-Wook Park

Department of Oral and Maxillofacial Surgery, Gyeongsang National University School of Medicine, Jinju, Korea

Abstract (J Korean Assoc Oral Maxillofac Surg 2014;40:240-245)

Angiokeratoma is a benign cutaneous lesion of the capillaries, presenting as dilated vessels in the upper part of the dermis. Although this disorder is classified into various types and has been occasionally reported in the skin of the scrotum or extremities, the involvement of the oral cavity mucosa has been rarely reported. The present study reports a case of angiokeratoma circumscriptum in the buccal mucosa. The expression of vascular endothelial growth factor (VEGF) and both of its receptors (VEGFR-1 and VEGFR-2) was demonstrated by immunohistochemistry in the endothelial cells lining the dilated vessels. The expression of VEGFR-2 was higher than that of VEGFR-1 in the endothelial cells in the lesion, indicating an increased rate of endothelial cell proliferation within the lesion. Interestingly, some of the endothelial cells co-expressed VEGF and its two receptors. These results suggest that endothelial cells in the pathologically dilated vessels possess VEGF autocrine growth activity involved in vasculogenesis and maintenance in angiokeratoma lesions. To our knowledge, this is the second report published on isolated oral angiokeratoma confined to the buccal mucosa and the first case report on angiokeratoma circumscriptum involving the buccal mucosa.

Key words: Angiokeratoma circumscriptum, Buccal mucosa

[paper submitted 2014. 6. 18 / accepted 2014. 7. 12]

I. Introduction

Angiokeratoma is a rare cutaneous vascular disorder of the papillary dermis that is characterized by one or more dilated vessels in the upper part of the dermis. In the majority of cases, it is also associated with epidermal reactions such as acanthosis and/or hyperkeratosis¹. This disorder can be classified into five types: (1) a generalized systemic form (angiokeratoma corporis diffusum of Fabry); (2) a bilateral form occurring on the dorsal surfaces of the fingers and toes (angiokeratoma of Mibelli); (3) a localized scrotal form (angiokeratoma of Fordyce); (4) a solitary papular angiokeratoma;

and (5) a multiple papular and plaque-like form (angiokeratoma circumscriptum)^{2,3}. Although the clinical characteristics are different, common histological features include hyperkeratosis of the epidermis and dilated vascular spaces with or without organizing thrombi in the papillary dermis of cutaneous lesions^{4,5}. Among the five types of angiokeratomas, solitary angiokeratoma is the most common, and angiokeratoma circumscriptum is the least frequent².

Most of the cases of angiokeratoma in the oral cavity have presented in conjunction with generalized systemic conditions (Fabry disease and fucosidosis). Isolated oral angiokeratoma unrelated to any systemic disease or cutaneous lesion has been rarely reported. To the best of our knowledge, only ten cases of isolated angiokeratoma in the oral cavity have been reported in the literature³⁻¹². (Table 1) The majority of reported oral angiokeratoma cases occurred on the tongue, but one case involved the buccal mucosa.

In this report, we describe an additional case of angiokeratoma circumscriptum in the oral cavity that involved the buccal mucosa without accompanying systemic disease or skin lesion. To characterize this unusual oral lesion, the surgical specimen was analyzed by immunohistochemistry for the

Bong-Wook Park

Department of Oral and Maxillofacial Surgery and Institute of Health Science,
Gyeongsang National University School of Medicine, 79 Gangnam-ro, Jinju
660-702, Korea

TEL: +82-55-750-8263 FAX: +82-55-761-7024

E-mail: parkbw@gnu.ac.kr

*These authors contributed equally to this work.

©This is an open-access article distributed under the terms of the Creative Commons Attribution Non-Commercial License (<http://creativecommons.org/licenses/by-nc/3.0/>), which permits unrestricted non-commercial use, distribution, and reproduction in any medium, provided the original work is properly cited.

Copyright © 2014 The Korean Association of Oral and Maxillofacial Surgeons. All rights reserved.

This work was supported by a National Research Foundation of Korea (NRF) grant funded by the Korean Government (NRF-2012R1A1A4A01009879).

Table 1. Review of the literature on isolated angiokeratoma in the oral cavity

References	Age (yr)/gender	Site	Type of angiokeratoma
Leung and Jordan ⁶ (1997)	82/female	Buccal mucosa	Solitary angiokeratoma
Kumar et al. ⁷ (1998)	16/male	Tongue	Angiokeratoma circumscriptum
Bhargava et al. ⁸ (2001)	5/male	Tongue	Angiokeratoma circumscriptum
Vijaikumar et al. ³ (2003)	12/male	Tongue	Angiokeratoma circumscriptum
Varshney ⁴ (2005)	12/female	Tongue	Angiokeratoma circumscriptum
Siponen et al. ⁹ (2006)	54/female	Tongue	Solitary angiokeratoma
Green and Roy ¹¹ (2006)	6/male	Tongue	Angiokeratoma circumscriptum
Sion-Vardy et al. ⁵ (2008)	45/female	Tongue	Solitary angiokeratoma
Patigaroo et al. ¹⁰ (2012)	16/male	Tongue	Angiokeratoma circumscriptum
Erkal et al. ¹² (2013)	67/female	Tongue	Solitary angiokeratoma
Current case	18/female	Buccal mucosa	Angiokeratoma circumscriptum

Young-Hoon Kang et al: Angiokeratoma circumscriptum of the buccal mucosa: a case report and literature review. *J Korean Assoc Oral Maxillofac Surg* 2014

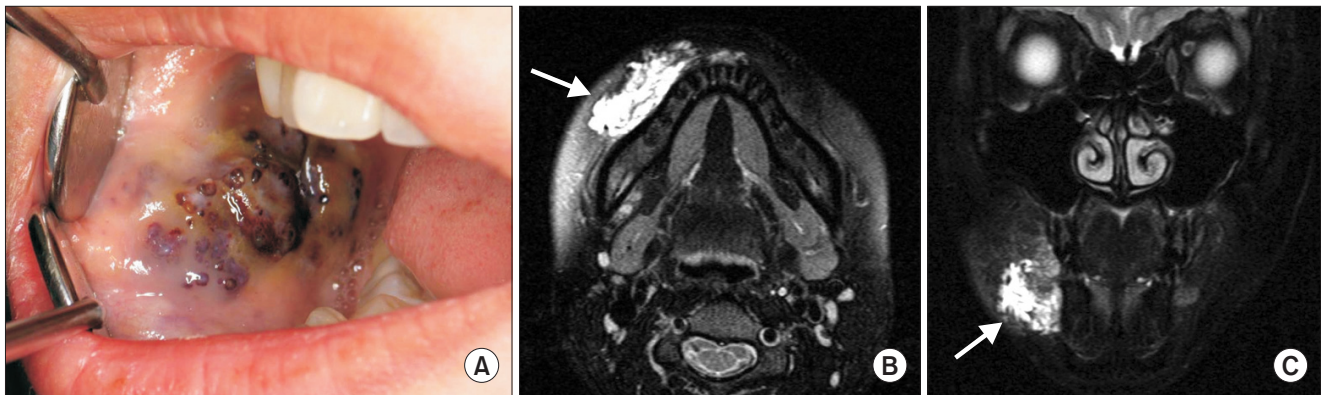


Fig. 1. Preoperative clinical and magnetic resonance imaging (MRI) findings. A. Primary lesions presented as multiple, small, irregular, raised lesions on the right side of the buccal mucosa. B, C. MRI shows an ill-defined heterogeneously enhanced lesion on the right side of the cheek (arrows).

Young-Hoon Kang et al: Angiokeratoma circumscriptum of the buccal mucosa: a case report and literature review. *J Korean Assoc Oral Maxillofac Surg* 2014

expression of vascular endothelial growth factor (VEGF) and its two receptors, VEGFR-1 and VEGFR-2.

II. Case Report

An 18-year-old female patient was referred for an evaluation of a dark-colored, painless, elevated lesion in the oral cavity. Clinically, a 5×2-cm-sized, multi-lobular, irregular, raised lesion was observed on the right side of the buccal mucosa (Fig. 1. A). The lesion was firm, did not bleed on manipulation, and was not accompanied by mucosal ulceration. The patient had no history of trauma. She had first recognized a small lesion on her cheek mucosa about three years prior, which had gradually increased in size. She had no history of systemic diseases or of skin or mucosal abnormalities. Magnetic resonance imaging showed an ill-defined, heterogeneously enhanced lesion on the right side of the buccal mucosa (Fig. 1. B, 1. C). A punch biopsy of the lesion showed epithelial hyperkeratosis, acanthosis, papillomatosis, and large

dilated cystic lesions containing erythrocytes under the epithelial tissue (Fig. 2. A, 2. B). These characteristics were consistent with angiokeratoma. Under general anesthesia, the cheek lesion was completely excised, and the surgical defect was primarily closed with a cheek advancement flap (Fig. 3. A, 3. B). The patient was followed for more than three years without any evidence of recurrence.

To confirm the angiogenic characteristics of the tumor, the specimen was immunostained for VEGF and two of its receptors (VEGFR-1 and VEGFR-2). For immunohistochemical analysis, the tumor specimen was embedded in a paraffin block, cut into 4- μ m sections, and mounted on glass slides. The sections were maintained at room temperature for 12 hours and deparaffinized. After hydration, immunohistochemical staining was performed using an automated immunostainer (BenchMark XT; Ventana Medical Systems Inc., Tucson, AZ, USA), and detection was performed using the UltraVIEW Universal DAB kit (Ventana Medical Systems Inc.) according to the manufacturer's protocol. Briefly, sec-

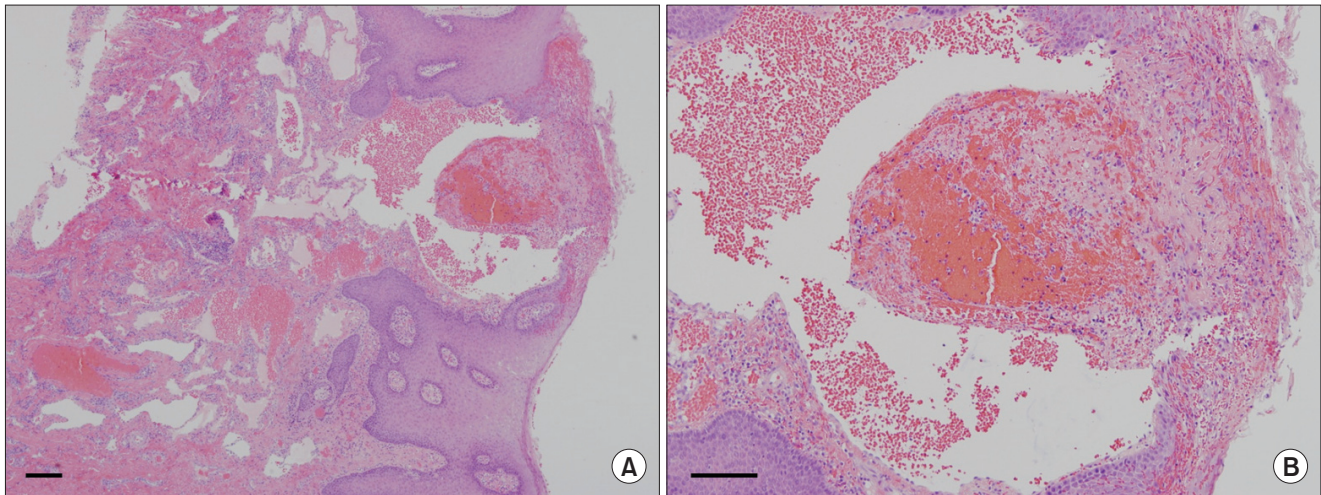


Fig. 2. H&E staining showing the histopathological features of the angiokeratoma circumscriptum lesion on the buccal mucosa (scale bars=200 μ m). A. Low-power magnification shows epithelial hyperkeratosis, acanthosis, and large cystic lesions. B. High-power magnification shows erythrocytes filling the dilated cystic lesion. These pathological features are consistent with those of angiokeratoma circumscriptum.

Young-Hoon Kang et al: *Angiokeratoma circumscriptum of the buccal mucosa: a case report and literature review. J Korean Assoc Oral Maxillofac Surg 2014*

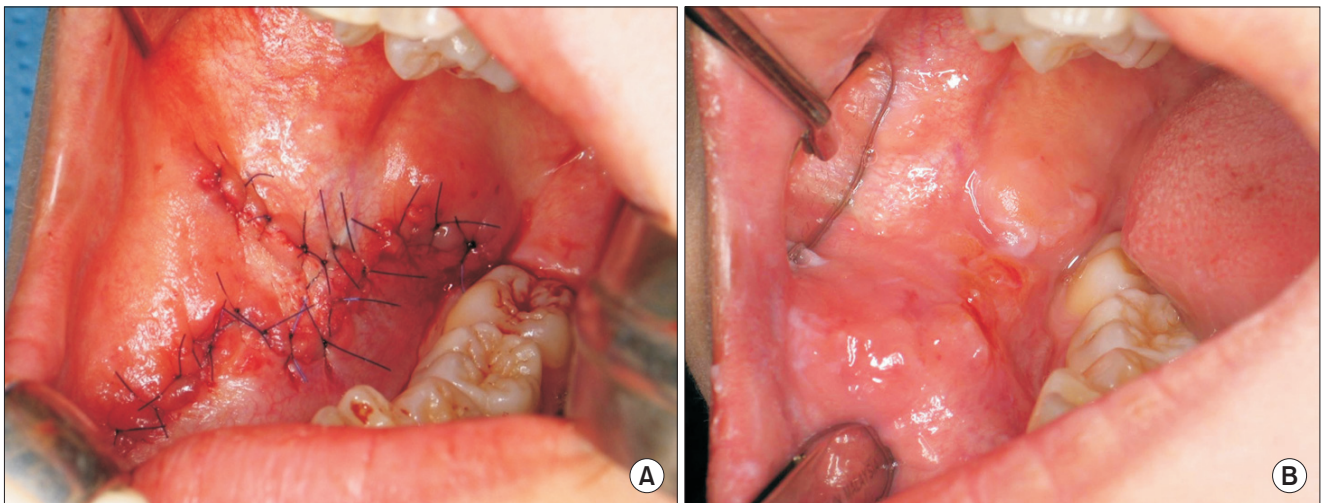


Fig. 3. Intraoperative and postoperative views. A. The cheek lesion was excised, and the surgical defect was primarily closed with an advancement flap. B. Two months after the operation, the surgical site was healed uneventfully.

Young-Hoon Kang et al: *Angiokeratoma circumscriptum of the buccal mucosa: a case report and literature review. J Korean Assoc Oral Maxillofac Surg 2014*

tions were deparaffinized using an EZ Prep solution (Ventana Medical Systems Inc.) and then treated with CC1 standard (ethylenediaminetetraacetic acid [EDTA], pH 8.4) for 60 minutes at 100°C for antigen retrieval. Next, the slides were treated at 37°C for 4 minutes with UltraVIEW Universal DAB Inhibitor (3% H₂O₂) to block endogenous peroxidase activity. Slides were then incubated at 37°C first with each primary antibody for 32 minutes and then with the secondary antibody (Universal HRP Multimer; Ventana Medical Systems Inc.) for 8 minutes. Finally slides were treated with

DAB+H₂O₂ substrate for 8 minutes, and nuclei were counterstained in hematoxylin II and bluing reagent at 37°C. Immunostained sections were photographed under a Nikon Eclipse Ti-U microscope (Nikon Instruments Inc., Tokyo, Japan), and the proportion of positive staining was calculated for both endothelial and stromal cells in the lesion. At least three different specimens were used to calculate the proportion of positive cells. The primary antibodies used and the results of the immunohistochemical staining are summarized in Table 2.

Immunostaining revealed that the stromal cells in the lesion

Table 2. Primary antibodies, dilutions used, and the proportion of cells staining positive for each protein

Antibody	Dilution	Source	Lot No.	Positive-cell ratio (%)	
				Endothelial cells	Stromal cells
VEGF	1 : 400	Santa Cruz ¹	sc-152	68.1±6.0	37.3±3.1
VEGFR-1	1 : 400	Abcam ²	ab9540	22.8±3.8	11.1±1.9
VEGFR-2	1 : 400	Abcam ²	ab71772	81.8±2.9	72.8±1.7

(VEGF: vascular endothelial cell growth factor, VEGFR-1: vascular endothelial cell growth factor receptor-1, VEGFR-2: vascular endothelial cell growth factor receptor-2)

¹Santa Cruz Biotechnology Inc., Dallas, TX, USA. ²Abcam, Cambridge, UK.

Values are presented as mean±standard deviation.

Young-Hoon Kang et al: Angiokeratoma circumscriptum of the buccal mucosa: a case report and literature review. *J Korean Assoc Oral Maxillofac Surg* 2014

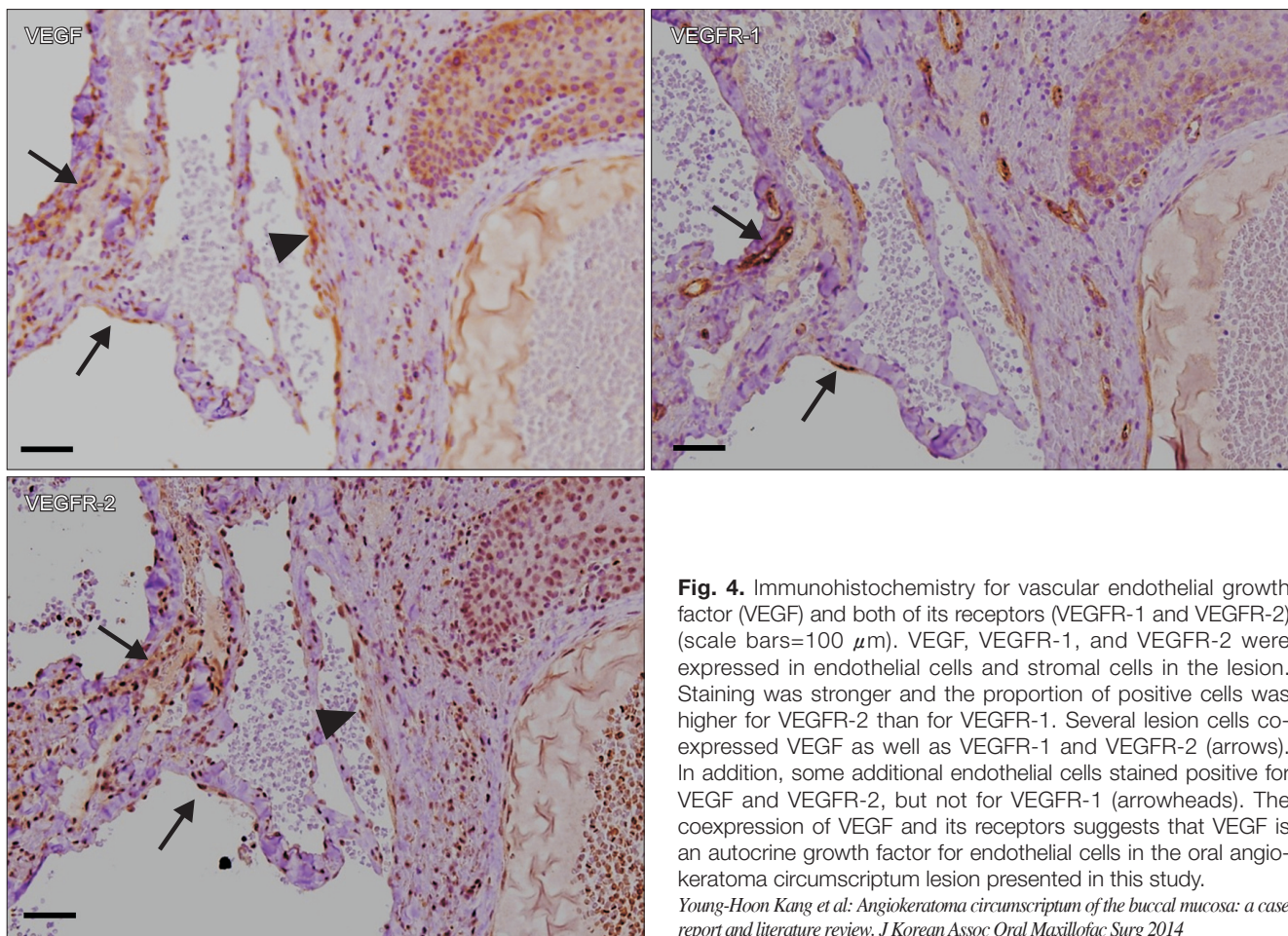


Fig. 4. Immunohistochemistry for vascular endothelial growth factor (VEGF) and both of its receptors (VEGFR-1 and VEGFR-2) (scale bars=100 μm). VEGF, VEGFR-1, and VEGFR-2 were expressed in endothelial cells and stromal cells in the lesion. Staining was stronger and the proportion of positive cells was higher for VEGFR-2 than for VEGFR-1. Several lesion cells co-expressed VEGF as well as VEGFR-1 and VEGFR-2 (arrows). In addition, some additional endothelial cells stained positive for VEGF and VEGFR-2, but not for VEGFR-1 (arrowheads). The coexpression of VEGF and its receptors suggests that VEGF is an autocrine growth factor for endothelial cells in the oral angiokeratoma circumscriptum lesion presented in this study.

Young-Hoon Kang et al: Angiokeratoma circumscriptum of the buccal mucosa: a case report and literature review. *J Korean Assoc Oral Maxillofac Surg* 2014

and endothelial cells lining the pathologically dilated vessels expressed VEGF and its two receptors (VEGFR-1 and VEGFR-2). (Fig. 4) Among both stromal and endothelial cells in the lesion, the percentage of positive-staining cells was higher for VEGFR-2 than that for VEGFR-1. Interestingly, some endothelial cells showed co-expression of VEGF and both of its receptors (arrows), whereas others co-expressed only VEGF and VEGFR-2 (arrowhead). Proportions of the cells staining positive for each of VEGF, VEGFR-1, and

VEGFR-2 are shown in Table 2.

III. Discussion

The first case of angiokeratoma was reported by Mibelli in 1890, and the manifestation of the disorder found on fingers and toes is now known as angiokeratoma of Mibelli¹³. Angiokeratoma circumscriptum was first described in 1915 by Fabry as a localized lesion on a lower extremity^{13,14}. It typi-

cally occurs unilaterally on the lower legs or feet, but it has also been observed on the thighs, buttocks, or elsewhere. The lesions are deep red to blue-black in color and are usually elevated, warty, purplish and compressible papules¹³. In most cases, angiokeratoma circumscriptum is present at birth, but in some cases, it develops during childhood or adulthood^{4,7}.

Oral mucosal involvement is most commonly detected as a component of angiokeratoma corporis diffusum (Fabry disease and fucosidosis). However, the oral mucosa is very seldom involved in other types of angiokeratoma^{3,4}. In addition to the present case, a review of the literature revealed ten cases of isolated angiokeratoma that occurred in the oral cavity. (Table 1) Of those, four cases were solitary angiokeratoma and six were angiokeratoma circumscriptum. Except for one case of solitary angiokeratoma that involved the buccal mucosa⁶, the remaining nine occurred on the tongue (pathologically, six were angiokeratoma circumscriptum and three were solitary angiokeratoma)^{3,5,7-12}. To our knowledge, the present report is the second case published on isolated oral angiokeratoma confined to the buccal mucosa and the first case report on angiokeratoma circumscriptum involving the buccal mucosa.

The histopathological features of angiokeratoma in the oral cavity are similar to those in skin lesions, which are hyperkeratosis, acanthosis, papillomatosis of the squamous epithelium, and dilated subepithelial blood vessels with thrombosis⁵. The pathogenesis of angiokeratoma is still unknown. It has been thought that altered hemodynamics, such as local injury to papillary capillaries, cause telangiectatic lesions in the papillary dermis with overlying reactive hyperkeratosis and acanthosis of the epidermis^{3,4}. Interestingly, matrix metalloproteinase-9 (MMP-9) has been identified in the epidermis, particularly in hyperkeratotic lesions of angiokeratoma circumscriptum, by immunohistochemistry¹⁵. The expression of MMP-9 may be related to the hyperkeratotic changes in angiokeratoma^{3,15}.

In the surgical specimen analyzed in the present study, VEGF and its two receptors (VEGFR-1 and VEGFR-2) were expressed in the endothelial cells of dilated vessels. VEGF has been characterized as a heparin-binding angiogenic growth factor that plays a critical role in angiogenesis and vasculogenesis during tumor growth and tissue regeneration^{16,17}. Of the several VEGF receptors, VEGFR-1 is primarily involved in cell migration and vascular maintenance rather than cell proliferation, whereas VEGFR-2 participates directly in regulating cell mitosis and proliferation; however, their precise roles have not been completely elucidated¹⁶. In

the specimen analyzed in the present study, immunostaining intensity was stronger and the proportion of positive cells was higher for VEGFR-2 than for VEGFR-1, indicating enhanced cell proliferation of endothelial cells. Additionally, the coexpression of VEGF and both of its receptors or only VEGF-2 was detected in some of the endothelial cells lining the pathologically dilated vessels. The coexpression of VEGF and VEGFRs by the endothelial cells in the lesion indicates that VEGF is an autocrine growth factor for these cells¹⁷. These results suggest that endothelial cells in the pathologically dilated vessels possess VEGF autocrine growth activity involved in vasculogenesis and maintenance in the angiokeratoma lesion.

Conflict of Interest

No potential conflict of interest relevant to this article was reported.

References

1. Schiller PI, Itin PH. Angiokeratomas: an update. *Dermatology* 1996;193:275-82.
2. Ozdemir R, Karaaslan O, Tiftikcioglu YO, Kocer U. Angiokeratoma circumscriptum. *Dermatol Surg* 2004;30:1364-6.
3. Vijaikumar M, Thappa DM, Karthikeyan K, Jayanthi S. Angiokeratoma circumscriptum of the tongue. *Pediatr Dermatol* 2003;20:180-2.
4. Varshney S. Angiokeratoma circumscriptum of the tongue. *Int J Dermatol* 2005;44:886-8.
5. Sion-Vardy N, Manor E, Puterman M, Bodner L. Solitary angiokeratoma of the tongue. *Med Oral Patol Oral Cir Bucal* 2008;13:E12-4.
6. Leung CS, Jordan RC. Solitary angiokeratoma of the oral cavity. *Oral Surg Oral Med Oral Pathol Oral Radiol Endod* 1997;84:51-3.
7. Kumar MV, Thappa DM, Shanmugam S, Ratnakar C. Angiokeratoma circumscriptum of the oral cavity. *Acta Derm Venereol* 1998;78:472.
8. Bhargava P, Bhargava S, Mathur D, Agarwal US, Bhargava R. Angiokeratoma of tongue. *Indian J Dermatol Venereol Leprol* 2001;67:270.
9. Siponen M, Penna T, Apaja-Sarkkinen M, Palatsi R, Salo T. Solitary angiokeratoma of the tongue. *J Oral Pathol Med* 2006;35:252-3.
10. Patigaroo S, Khan N, Manzoor S, Gupta N, Jain P, Shakeel M. Isolated multiple angiokeratoma of tongue--a case report and review of literature. *Int J Pediatr Otorhinolaryngol Extra* 2012;7:126-8.
11. Green JB, Roy S. Angiokeratoma circumscriptum of the dorsal tongue in a child. *Int J Pediatr Otorhinolaryngol Extra* 2006;1:107-9.
12. Erkal EY, Karabey MS, Vural Ç, Mutlu F, Aksu G, Sarper B, et al. Solitary angiokeratoma of the tongue in an adult patient treated with intensity modulated radiation therapy. *Am J Otolaryngol* 2013;34:582-5.
13. Mittal R, Aggarwal A, Srivastava G. Angiokeratoma circumscriptum: a case report and review of the literature. *Int J Dermatol* 2005;44:1031-4.
14. Fabry J. Uber einen fall von angiokeratoma circumscriptum am linken Oberschenkel. *Derm Z* 1915;22:1-4.
15. Kobayashi T, Sakuraoka K. A case of angiokeratoma circumscrip-

- tum: immunolocalization of matrix metalloproteinase (MMP)-9. *J Dermatol* 1998;25:391-4.
16. Neufeld G, Cohen T, Gengrinovitch S, Poltorak Z. Vascular endothelial growth factor (VEGF) and its receptors. *FASEB J* 1999;13:9-22.
 17. Masood R, Cai J, Zheng T, Smith DL, Hinton DR, Gill PS. Vascular endothelial growth factor (VEGF) is an autocrine growth factor for VEGF receptor-positive human tumors. *Blood* 2001;98:1904-13.