

Uniportal video-assisted thoracoscopic lymph node dissection

María Delgado Roel, Eva María Fieira Costa, Diego González-Rivas, Lucía Méndez Fernández, Ricardo Fernández Prado, Mercedes de la Torre

Department of Thoracic Surgery Coruña's University Hospital, La Coruña, Spain

Correspondence to: María Delgado Roel. Department of Thoracic Surgery Coruña's University Hospital, La Coruña, As Xubias de Arriba, 84, A Coruña, 15006, Spain. Email: mdelgadoel@hotmail.com.

Abstract: Lymphadenectomy is an important part of lung cancer surgery. At the moment, video-assisted thoracoscopic (VATS) is the most common approach to remove these tumors, when it is technically possible. With our current experience in VATS in major resections we have obtained a radical videothoracoscopic mediastinal lymphadenectomy, and single-port provides us with the best anatomic instrumentation and a direct view.

Keywords: Video-assisted thoracoscopic (VATS); lymphadenectomy; lung cancer; uniportal

Submitted Jun 23, 2014. Accepted for publication Sep 04, 2014.

doi: 10.3978/j.issn.2072-1439.2014.10.04

View this article at: <http://dx.doi.org/10.3978/j.issn.2072-1439.2014.10.04>

Introduction

Lymphadenectomy is important to identify the N, because it has a direct relationship to the prognosis after a lung tumor resection. For this reason, during the surgery, we have to be very careful with the N2 stations.

We have to distinguish between: (I) lymph node biopsy; obtaining a fragment (II) sampling; to obtain a node from each station and (III) the standard mediastinal dissection: which is to remove all the lymph nodes from at least three mediastinal stations from the affected side.

One of the principal concerns that appeared with video-assisted thoracic surgery (VATS) lobectomy was whether we could perform the same lymphadenectomy with VATS as we could perform with thoracotomy.

At present, with our current experience using VATS in many groups, we have achieved the same lymphadenectomy results with VATS as was previously obtained by a thoracotomy with even better results.

Thereby D'amico TA supports the view that videothoracoscopic mediastinal lymphadenectomy is just as feasible as conventional surgery, with similar results (1).

Watanabe A *et al.* analyzed a group of patients with lung tumor diagnosis and clinical N0, but with pathological N2 following lung resection by VATS or thoracotomy: they did not find any differences between groups in: (I) number of nodes, (II) number of nodal metastasis and (III) the 3- and 5-year recurrence-free survival. The authors concluded that it is unnecessary to convert the VATS approach to thoracotomy to do a radical mediastinal lymphadenectomy (2).

Wang W *et al.* compare the differences between VATS group and thoracotomy group in VATS lymphadenectomy results for 5,620 patients. They perform a systematic lymph node dissection with a greater number of nodes in VATS group, in addition to the known advantages of the VATS approach (3).



Figure 1 Paratracheal lymph node dissection (5).

Available online: <http://www.asvide.com/articles/336>




Figure 2 Energy device for paratracheal lymph node dissection (6).

Available online: <http://www.asvide.com/articles/337>

Operative techniques

We analyzed our experience in VATS for major resections for over a 3-year period [2007-2010] involving 200 cases, and we compared the differences between the three periods of time. We started performing VATS lobectomies with three ports (99 cases in the first year) and after that with only two ports or even the first single port lobectomy in the third year (4).

We observed improvements with the experience; we reduced the conversion rate, the mean surgical time, the number of lymph nodes as well as the explored nodal stations.

We must bear in mind the importance of the surgical material, which helps us to improve the lymphadenectomy. Especially with regards to:

- (I) 10 mm thoracoscope (HD 30 degree);
- (II) High definition monitor screen;

- (III) Long, short and double-jointed curved ring forceps;
- (IV) Long and double-jointed Metzenbaum scissors;
- (V) Curved suction;
- (VI) Long and double jointed thoracoscopic dissector;
- (VII) Endopath 5 mm endoscopic peanut (x2);
- (VIII) Energy devices;
- (IX) Sponge stick.

Curved ring forceps are very useful to dissect and to pull the lymph nodes. We use the curved suction and sponge stick to dissect and to expose the structures. The Harmonic scalpel makes the haemostasis easier. To sum up, we give more than one use to the different instruments.

Instrumentation in VATS lymphadenectomy is vital because the surgeon works in a reduced space: in single port the camera goes into the posterior part of the incision. We obtain a direct view which makes the instrumentation easier since the view of the camera and the surgeon moving are in parallel.

The technical aspects in mediastinal spaces are:

- (I) Right paratracheal space: we remove all the mediastinal nodes and fat between trachea and cava vein (*Figure 1*). Usually it is not necessary to open the mediastinal pleura, we dissect going under the azygos vein, the result is a tunnel view (*Figure 2*). A long endothoracoscopic peanut is very useful to separate the join between azygos and cava vein. The use of energy devices facilitate the dissection and reduce the rate of postoperative bleeding.
- (II) Subcarinal space: the most difficult lymphadenectomy is left subcarinal lymphadenectomy, because it is the deepest area. You have to retract the aorta on the left side and the oesophagus on both sides. That is possible with a sponge stick or another instrument like curved suction. With single port VATS you can even see the main contralateral bronchus, and the contralateral lower vein (*Figure 3*).
- (III) Aortopulmonary window space: For this procedure lymph nodes should be removed from the aorta and the pulmonary artery and usually it is necessary to retract the phrenic nerve to better expose the prevascular area (*Figure 4*). Sometimes even with single port you can perform a left paratracheal lymphadenectomy under the aortic arch (*Figure 5*).

The key for a correct lymphadenectomy in single-port VATS is good exposition and bimanual instrumentation. Moving the surgical table allows for better results thus improving the lung exposition; moving the table anteriorly



Figure 3 Left subcarinal lymph node dissection (7).
Available online: <http://www.asvide.com/articles/338>



Figure 4 Aortopulmonary window lymph node dissection (awake patient) (8).
Available online: <http://www.asvide.com/articles/339>

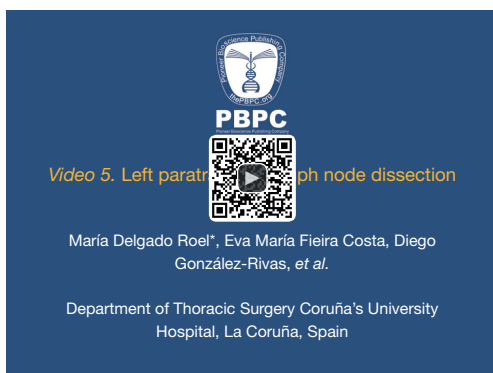

Figure 5 Left paratracheal lymph node dissection (9).
Available online: <http://www.asvide.com/articles/340>

exposes the subcarinal space and the anti-trendelenburg position which exposes the paratracheal area.

Comments

We currently perform a complete and radical lymph node dissection by VATS. In our experience the lymphadenectomy achieved by uniportal VATS can be even better than open approach thanks to the high definition. As more cases are treated with the single-port approach, the number of lymph nodes removed increases—thus reflecting improvement in the surgical technique. In our uniportal series, the mean number of lymph nodes resected is greater than the mean number we reported by two or three port VATS (14.5 ± 7 vs. 11.9 ± 6.7) (10).

If we divide the period into two years, we observe more lymph node dissection performed during the second period: 12.2 ± 4.7 vs. 16 ± 8 ($P=0.055$).

Conclusions

- (I) Lymphadenectomy is an important part of the lung cancer surgery.
- (II) To perform a standard lymphadenectomy by single port approach is possible and represents the best view if we compare with three and two ports.
- (III) We can use conventional material, but it is easier with double-jointed and long instruments.
- (IV) Do not forget the importance of the learning curve.

Acknowledgements

Disclosure: The authors declare no conflict of interest.

References

1. D'Amico TA. Videothoroscopic mediastinal lymphadenectomy. *Thorac Surg Clin* 2010;20:207-13.
2. Watanabe A, Mishina T, Ohori S, et al. Is video-assisted thoracoscopic surgery a feasible approach for clinical N0 and postoperatively pathological N2 non-small cell lung cancer? *Eur J Cardiothorac Surg* 2008;33:812-8.
3. Wang W, Yin W, Shao W, et al. Comparative study of systematic thoracoscopic lymphadenectomy and conventional thoracotomy in resectable non-small cell lung cancer. *J Thorac Dis* 2014;6:45-51.
4. Gonzalez D, de la Torre M, Paradela M, et al. Video-assisted thoracic surgery lobectomy: 3-year initial

- experience with 200 cases. *Eur J Cardiothorac Surg* 2011;40:e21-8.
5. Delgado Roel M, Fieira Costa EM, González-Rivas D, et al. Paratracheal lymph node dissection. *Asvide* 2014;1:323. Available online: <http://www.asvide.com/articles/336>
 6. Delgado Roel M, Fieira Costa EM, González-Rivas D, et al. Energy device for paratracheal lymph node dissection. *Asvide* 2014;1:324. Available online: <http://www.asvide.com/articles/337>
 7. Delgado Roel M, Fieira Costa EM, González-Rivas D, et al. Left subcarinal lymph node dissection. *Asvide* 2014;1:325. Available online: <http://www.asvide.com/articles/338>
 8. Delgado Roel M, Fieira Costa EM, González-Rivas D, et al. Aortopulmonary window lymph node dissection (awake patient). *Asvide* 2014;1:326. Available online: <http://www.asvide.com/articles/339>
 9. Delgado Roel M, Fieira Costa EM, González-Rivas D, et al. Left paratracheal lymph node dissection. *Asvide* 2014;1:327. Available online: <http://www.asvide.com/articles/340>
 10. Gonzalez-Rivas D, Paradela M, Fernandez R, et al. Uniportal video-assisted thoracoscopic lobectomy: two years of experience. *Ann Thorac Surg* 2013;95:426-32.

Cite this article as: Delgado Roel M, Fieira Costa EM, González-Rivas D, Fernández LM, Fernández Prado R, de la Torre M. Uniportal video-assisted thoracoscopic lymph node dissection. *J Thorac Dis* 2014;6(S6):S665-S668. doi: 10.3978/j.issn.2072-1439.2014.10.04