

## Half-and-half nail in a case of isoniazid-induced pellagra

Yiping Ma, Zhi Xiang, Lin Lin, Jiechen Zhang, Hongsheng Wang

Institute of Dermatology, Chinese Academy of Medical Sciences, Nanjing, China  
Head of Department: Prof. Baoxi Wang

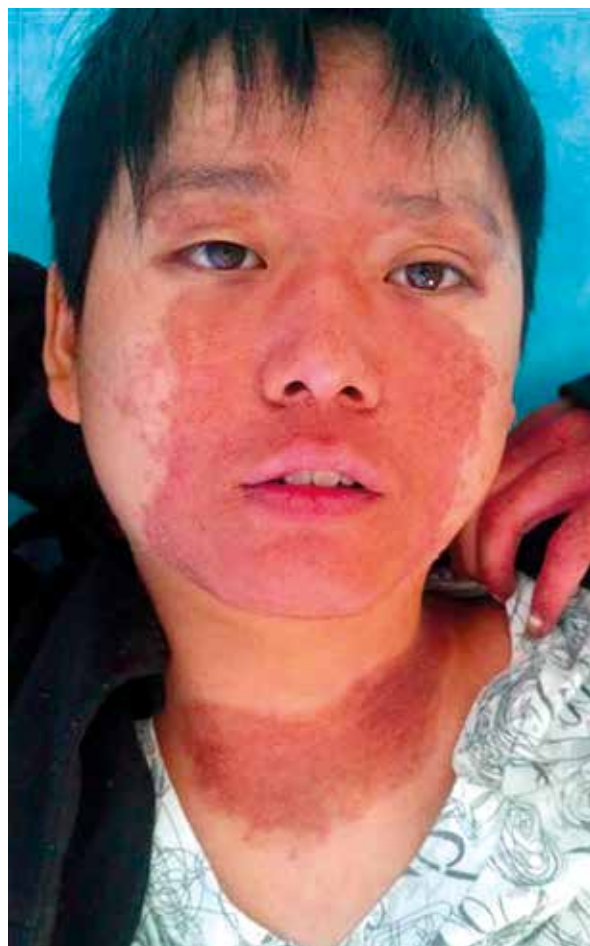Postep Derm Alergol 2014; XXXI, 5: 329–331  
DOI: 10.5114/pdia.2014.40969

Pellagra is a forgotten disease, particularly in developed countries. It is a nutritional disorder characterized by 4 “Ds”: diarrhea, dermatitis, dementia, and death. Causes of pellagra are chronic alcoholism, inadequate diet, malabsorption, metabolic derangement and drugs. Half-and-half nail is an occasional but specific clinical finding in chronic renal failure. We report a case of Isoniazid-induced pellagra associated with half-and-half nail.

We present a case of a 23-year-old man presenting with a month's history of a painful, cervicofacial, cutaneous lesion appearing after sun exposure, initially as an acute onset of erythema that progressed to a bullous surface, exudative plaque. The patient also mentioned bulla on the dorsum of his feet, which evolved into erosions and crusts. The patient also has cheilitis and glossitis. The patient has a history of 7 years of schizophrenia, with long-term oral administration of clozapine and risperidone. Five months ago, because of recurrent diarrhea, the local hospital diagnosed “secondary pulmonary tuberculosis”, with oral administration of rifampicin 0.45 g qd, isoniazid 0.3 g qd for 4 months, and ethambutol 0.5 g qd, pyrazinamide 0.75 g qd for 2 months.

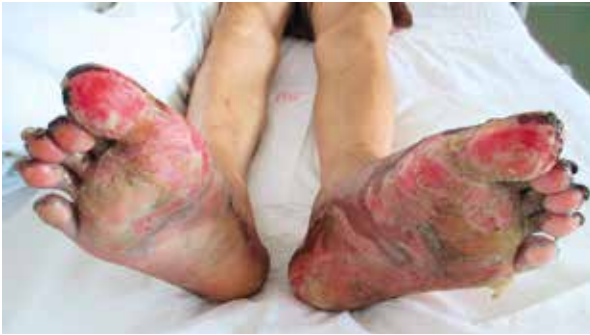He had no history of alcoholism. His physical examination was normal. On dermatological examination, symmetric, well-defined, red to brown colored, scaly eruptions were observed on his face, front of the neck, resembling a necklace (Casal's necklace), dorsa of his hands/feet and extensor surface of the forearms. Visible bulla on the dorsum of his feet, erosion, exudation plaque on pelma. Scrotal and perineal erythema and erosions can also be seen. The proximal half of the nails of his hands were white and the distal portion were pinkish-red with a sharply demarcated contrast between the 2 zones (Figures 1–4). He stated that the nail changes occurred at the same time as the skin lesions. The laboratory tests (glucose, urea, creatinine, liver function tests, urine analysis, hemoglobin, hematocrit, creatinine clearance, complement and immunoglobulins, thyroid hormones) were within normal limits. Antinuclear anti-

body and anti-DNA antibody were negative. A skin biopsy showed hyperkeratosis, perivascular lymphohistiocytic infiltrate in the dermis and vacuolar degeneration of the basal layer (Figure 5).

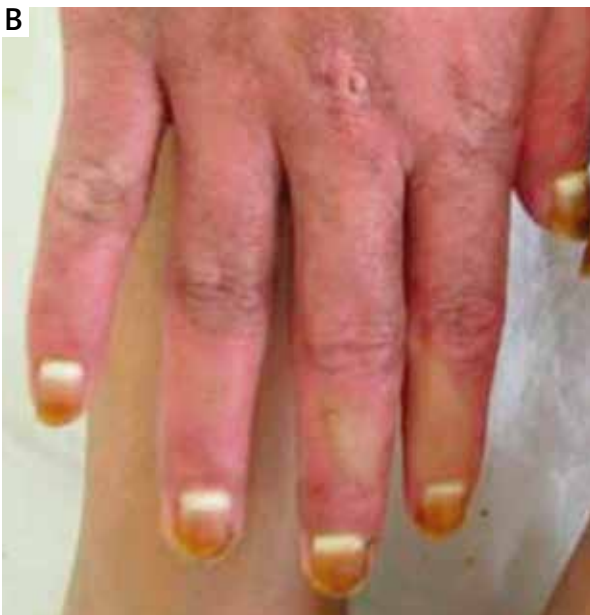
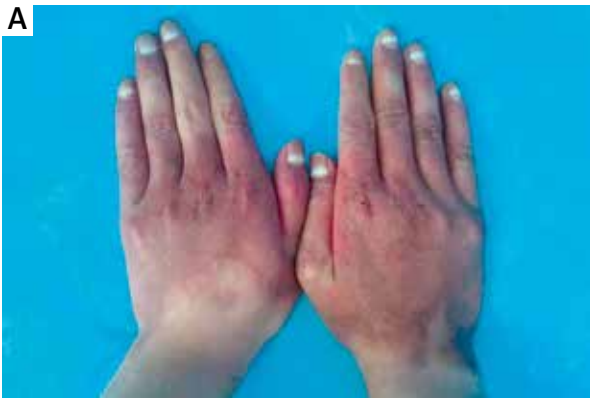
**Figure 1.** Symmetric, well-defined, red to brown colored, scaly eruptions were observed on his face, front of the neck, resembling a necklace (Casal's necklace)

**Address for correspondence:** Yiping Ma MD, Institute of Dermatology, Chinese Academy of Medical Sciences, Nanjing City, Jiangsu Province Wang Jiang Temple Street No. 12, 210098 Nanjing, China, phone: +86 2583787991, e-mail: mayipinggg@sohu.com  
**Received:** 11.12.2013, **accepted:** 6.01.2014.

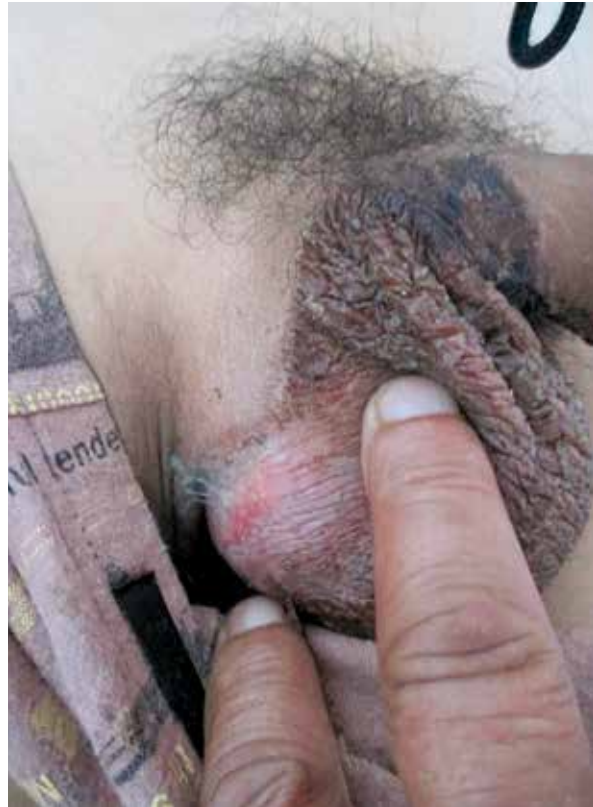

**Figure 2.** Visible bulla on the dorsum of his feet, erosion, exudation plaque on pelma

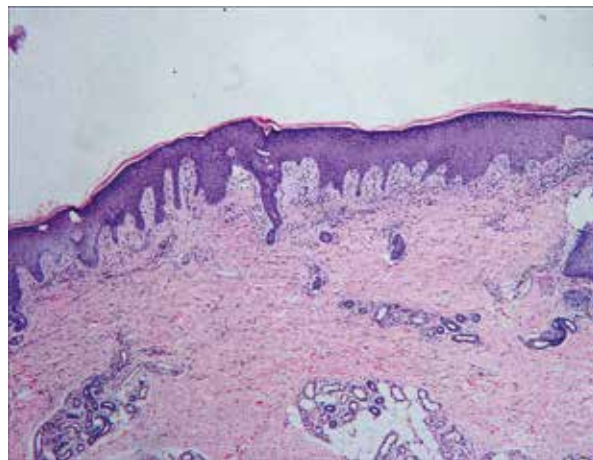


**Figure 4.** Half-and-half nail

Pellagra was diagnosed clinically and histopathologically. Half-and-half nail was diagnosed clinically. Isoniazid (INH) treatment was not discontinued and 900 mg of nicotinamide per day was started. Topical mometasone furoate cream, multivitamin, and adequate nutritional intake were parts of the treatment as well. The pellagra-re-



**Figure 3.** Scrotal and perineal erythema and erosions



**Figure 5.** Hyperkeratosis, perivascular lymphohistiocytic infiltrate in the dermis and vacuolar degeneration of the basal layer

lated signs and symptoms were resolved after 3 weeks' niacin therapy and dietary supplementations. The half and half nail resolved normal 4 months later.

Several etiological factors can cause pellagra including tryptophan deficiency, particularly diets high in maize and low in animal protein, chronic alcoholism, and biochemical abnormalities of tryptophan metab-

olism, such as carcinoid syndrome and Hartnup's disease. Chemotherapeutic agents are well-known causes of pellagra. The INH, 6-mercaptopurine, 5-fluorouracil and chloramphenicol are the most common causative agents. Drugs may interact with compounds in the tryptophan-kynurenine-niacin pathway that may interfere with NAD and NADP synthesis. The INH, a structural analog of niacin, may lead to suppression of endogenous niacin production that may end up with pellagra. Patients with slow acetylators may be at a greater risk to develop drug-induced pellagra [1]. Based on the above reasons, we think our patient's pellagra was caused by INH.

Half-and-half nail, a type of pseudo leukonychia, is a nail bed change in which the proximal half of the nail appears white and the distal portion appears to be red-brown. It has been stated that if the distal portion is less than 20% of the total nail length, Terry nails are the culprit and not half and half nails [2]. Although this change may be seen in patients with no demonstrable systemic abnormality, it is noted most commonly in patients with chronic renal failure undergoing hemodialysis. Prevalence of half-and-half nail is reported to be 7.7–50.6% in this group [3]. The pathogenesis of this color change is not clear; some authors have reported melanin deposits in the nail plate and thickening in the capillary wall, but others have considered the whiteness of this disorder to be caused by excessive development of connective tissue between the nail and bone that reduces the quantity of blood in the subpapillary plexus [4, 5].

Although this change was noted most commonly in patients with chronic renal disorder, associations with pellagra, Behçet's disease, yellow nail syndrome, Crohn's disease, and citrullinemia have been reported [6]. It may also be seen in patients without any demonstrable systemic abnormality. First, we did not detect any systemic pathology that can cause half-and-half nail in our case except pellagra. Secondly, the patient's pellagra lesions and half-and-half nail had occurred simultaneously. Thirdly, the patient's nail returned to normal accompanied with pellagra recovery. As a result, we think that half-and-half nail was due to the pellagra in our patient.

To the best of our knowledge, our patient is the second known case of the association of pellagra and half-and-half nail to be reported. We do not know the pathogenesis of half-and-half nail in pellagra. We believe that the future studies will shed light on this relationship.

#### References

1. Bilgili SG, Karadag AS, Calka O, et al. Isoniazid-induced pellagra. *Cutan Ocul Toxicol* 2011; 30: 317-9.
2. Iorizzo M, Daniel CR, Tosti A. Half and half nails: a past and presents napshot. *Cutis* 2011; 88: 138-9.
3. Martinez MA, Gregório CL, Santos VP, et al. Nail disorders in patients with chronic renal failure undergoing hemodialysis. *An Bras Dermatol* 2010; 85: 318-23.
4. Pellegrino M, Taddeucci P, Mei S, et al. Half-and-half nail in a patient with Crohn's disease. *J Eur Acad Dermatol Venerol* 2010; 24: 1359-69.
5. Gönül M, Hızlı P, Gül U. Half-and-half nail in Behçet's disease. *Int J Dermatol* 2014; 53: e26-7.
6. Cakmak SK, Gönül M, Aslan E, et al. Half-and-half nail in a case of pellagra. *Eur J Dermatol* 2006; 16: 695-6.