

WJG 20th Anniversary Special Issues (15): Laparoscopic resection of gastrointestinal

Laparoscopic excision of Meckel's diverticulum in children: What is the current evidence?

Kin Wai Edwin Chan, Kim Hung Lee, Hei Yi Vicky Wong, Siu Yan Bess Tsui, Yuen Shan Wong,
Kit Yi Kristine Pang, Jennifer Wai Cheung Mou, Yuk Him Tam

Kin Wai Edwin Chan, Kim Hung Lee, Hei Yi Vicky Wong, Siu Yan Bess Tsui, Yuen Shan Wong, Kit Yi Kristine Pang, Jennifer Wai Cheung Mou, Yuk Him Tam, Division of Paediatric Surgery and Paediatric Urology, Department of Surgery, The Prince of Wales Hospital, The Chinese University of Hong Kong, Hong Kong, China

Author contributions: Chan KWE contributed to the study design, literature search, manuscript writing and final revision of the article; Wong HYV, Tsui SYB, Wong YS, Pang KYK and Mou JWC performed the research; Lee KH and Tam YH contributed to supervision.

Correspondence to: Kin Wai Edwin Chan, MBChB, FRCSed (Paed), FCSHK, FHKAM(Surgery), Division of Paediatric Surgery and Paediatric Urology, Department of Surgery, The Prince of Wales Hospital, The Chinese University of Hong Kong, Hong Kong, China. edwinchan@surgery.cuhk.edu.hk

Telephone: +86-852- 26322953 Fax: +86-852-26324669

Received: November 6, 2013 Revised: March 6, 2014

Accepted: June 2, 2014

Published online: November 7, 2014

Abstract

Complications aroused from Meckel's diverticulum tend to developed in children. Children presented with abdominal pain, intestinal obstruction, intussusception or gastrointestinal bleeding may actually suffered from complicated Meckel's diverticulum. With the advancement of minimally invasive surgery (MIS) in children, the use of laparoscopy in the diagnosis and subsequent laparoscopic excision of Meckel's diverticulum has gained popularity. Recently, single incision laparoscopic surgery (SILS) has emerged as a new technique in minimally invasive surgery. This review offers the overview in the development of MIS in the management of children suffered from Meckel's diverticulum. The current evidence in different laparoscopic techniques, including conventional laparoscopy, SILS, the use of special laparoscopic instruments, intracorporeal diver-

ticulectomy and extracorporeal diverticulectomy in the management of Meckel's diverticulum in children were revealed.

© 2014 Baishideng Publishing Group Inc. All rights reserved.

Key words: Laparoscopy; Meckel's diverticulum; Children

Core tip: With the advances in the development of minimally invasive surgery in children, laparoscopic excision of Meckel's diverticulum has gained popularity. New technique including single incision laparoscopic surgery (SILS) in the management of Meckel's diverticulum was reported. This review offers the overview of the current evidence in different laparoscopic techniques, including conventional laparoscopy, SILS, the use of special laparoscopic instruments, intracorporeal diverticulectomy and extracorporeal diverticulectomy in the management of Meckel's diverticulum in children.

Chan KWE, Lee KH, Wong HYV, Tsui SYB, Wong YS, Pang KYK, Mou JWC, Tam YH. Laparoscopic excision of Meckel's diverticulum in children: What is the current evidence? *World J Gastroenterol* 2014; 20(41): 15158-15162 Available from: URL: <http://www.wjgnet.com/1007-9327/full/v20/i41/15158.htm> DOI: <http://dx.doi.org/10.3748/wjg.v20.i41.15158>

INTRODUCTION

Complications aroused from Meckel's diverticulum included gastrointestinal bleeding, intussusception, intestinal obstruction, abdominal pain and incarcerated hernia^[1]. These complications tend to develop in children^[2].

During the past decades, there has been a tremendous development of minimally invasive surgery in children^[3-6]. Increasing number of reports on the use of laparoscopy

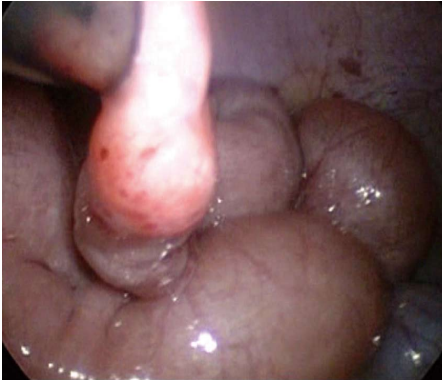

Figure 1 Laparoscopic view of a Meckel's diverticulum in a child with gastrointestinal bleeding.

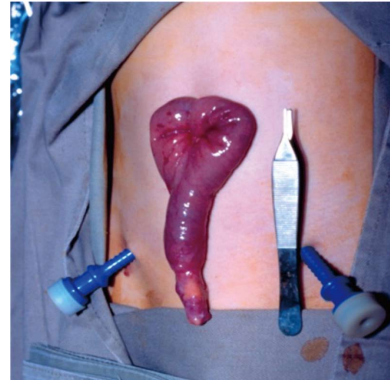


Figure 2 Meckel's diverticulum was exteriorized through the umbilical wound in conventional laparoscopy.

Table 1 Results of Meckel's scan in reports studying laparoscopic management of Meckel's diverticulum in children

Ref.	Number of children included in the study	Number of children presented with gastrointestinal bleeding	Meckel's scan	
			Positive	Negative
Chan <i>et al</i> ^[1]	20	12	5	3
Shalaby <i>et al</i> ^[9]	33	7	4	3
Prasad <i>et al</i> ^[11]	8	3	2	0
Sai Prasad <i>et al</i> ^[12]	36	16	12	2

in children with Meckel's diverticulum was observed^[1,7-13]. Recently, single incision laparoscopic surgery (SILS) has emerged as an evolution from conventional laparoscopy (CL)^[14]. This review provides the updated and the current evidence in the laparoscopic management of Meckel's diverticulum in children.

USE OF LAPAROSCOPY IN THE DIAGNOSIS OF COMPLICATED MECKEL'S DIVERTICULUM

Bleeding is the most common presentation of Meckel's diverticulum in children^[15]. Tc-99 m pertechnetate scan has been the standard investigation in children with Meckel's diverticulum containing ectopic gastric mucosa^[16]. Pre-medication with histamine-2 blockers (ranitidine) has been reported to increase the diagnostic yield^[16]. The reported sensitivity of the Meckel's scan varies from 60% to 90% with the specificity varies from 90% to 98%^[17-20]. Sinha *et al*^[21] recently reported the sensitivity and specificity of the Meckel's scan for ectopic gastric mucosa were 94% and 97%, respectively.

In children with persistent symptoms despite a negative Meckel's scan, laparoscopy is still warrant to exclude underlying small bowel anomalies (Figure 1). Lee *et al*^[22] reported the use of laparoscopy in children with gastrointestinal bleeding of obscure origin. 8 out the 17 children had Meckel's diverticulum identified by the laparoscopy. 4

children in the study had a positive Meckel's scan.

In the reports studying the use of laparoscopy in the management of Meckel's diverticulum in children, Meckel's scan was arranged as the pre-operative investigation in children presented with gastrointestinal bleeding. The results were listed in Table 1.

Besides gastrointestinal bleeding, children with complicated Meckel's diverticulum may present as acute abdomen. Diverticulitis, intussusception and intestinal obstruction were the underlying causes identified by laparoscopy^[1]. Clinicians should have a high index of suspicion of the exact pathology in children presented with abdominal pain.

CONVENTIONAL LAPAROSCOPY

It has been 20 years since the first reports describing the use of laparoscopy in the management of Meckel's diverticulum in children. Case reports on laparoscopic diverticulectomy in infants were published since 1993. Huang *et al*^[23] safely performed the operation in 3 symptomatic infants. There was an increasing number of case reports published since then. Some reports focused on the use of laparoscopy in the management of Meckel's diverticulum only^[7,8]. Others focused on the management on the acute abdominal condition in children including gastrointestinal bleeding or small bowel obstruction in which Meckel's diverticulum was one of the underlying cause^[22].

Although Meckel's diverticulum is the commonest congenital anomalies of the gastrointestinal tract and the complications tends to occurred in children, each pediatric surgical centers may only handled few cases per year. Since 2005, a number of case series were published^[1,9,11]. Each series included more than 20 patients underwent laparoscopy in the management of Meckel's diverticulum. The patients' inclusion criteria of these studies were different. Some included both symptomatic and asymptomatic children while other only included symptomatic patients.

Throughout these 20 years, the set-up of the laparoscopic procedure is essentially the same^[1,9,11,23]. In younger infants, the laparoscope was inserted at the subumbilical 5 mm port. Additional 5 mm ports were inserted at left and right lower quadrant of the abdomen

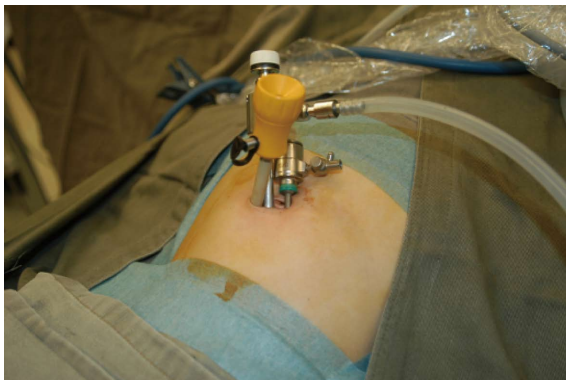


Figure 3 Single incision laparoscopic surgery setup. Three ports were inserted over the same fascial plane.

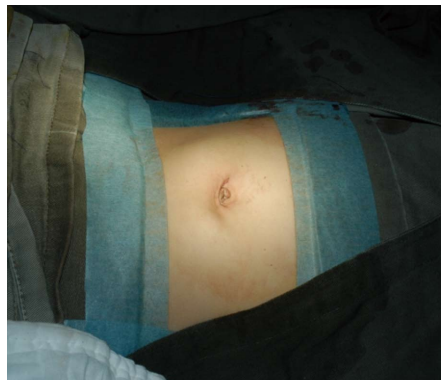

Figure 5 Appearance of the umbilical wound after single incision laparoscopic surgery for Meckel's diverticulum.

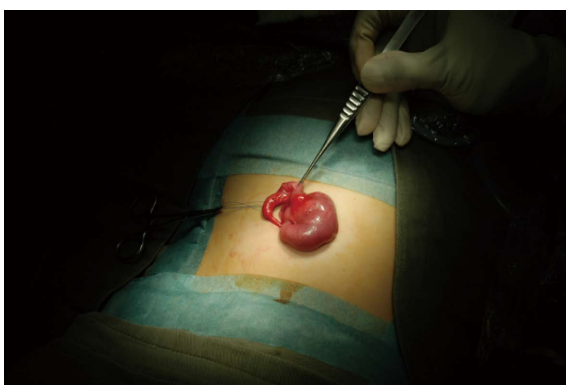


Figure 4 Meckel's diverticulum was exteriorized through the umbilical wound in single incision laparoscopic surgery.

respectively (Figure 2). In older children, 10 mm or 12 mm ports were used. The procedure started from identifying the cecum. The small intestine was then examined from the terminal ileum toward the jejunum. The Meckel's diverticulectomy were then performed intracorporeally or extracorporeally. Practically, the procedure did not required advance laparoscopic skills since laparoscopic intracorporeal suturing did not required. All reports concluded laparoscopy was safe and effective in the management of Meckel's diverticulum^[1,9-11].

SILS

The reports of single-incision or SILS in children were published since 2008. Initial reports studied the safety and feasibility of SILS in various pediatric condition included appendectomy, cholecystectomy, varicocelectomy^[17]. Cobellis *et al*^[24] used a 10-mm working laparoscope in the management of Meckel diverticulum since 2001. He only used 1 trocar and the Meckel's diverticulum was grasped and delivered through the umbilical wound. Meckel's diverticulectomy were performed extracorporeally. This may represent the "first" series of single incision laparoscopic surgery for Meckel's diverticulum in children.

Using the current concept of SILS, laparoscope and

the instruments were inserted through a multilumen port or through multiple ports that were inserted over the same fascial plane^[25] (Figure 3). Tam *et al*^[26] reported the experience in single incision umbilical laparoscopic segmental small bowel resection. The study included 2 patients with Meckel's diverticulum. In conventional laparoscopic technique, the umbilical wound required extension in order to facilitate segmental resection of the small intestine and the diverticulum. In SILS, the umbilical wound did not required further extension (Figure 4) and good cosmesis can be achieved (Figure 5).

Because the development of SILS is still at its infancy, limited numbers of reports on SILS in the management of Meckel's diverticulum were available^[26]. There is no case series of SILS in the management of Meckel's diverticulum. Isolated cases of SILS in Meckel's diverticulum were reported in studies focused on the experience of SILS in children^[27,28], or in studies focused on the use of SILS in segmental small bowel resection and in studies focused in the use of SILS in the management of obscure gastrointestinal bleeding in children^[26,29]. Although in SILS, specially designed instruments including flexible laparoscope or instrument were developed to facilitate the operation, in all reported cases of SILS in Meckel's diverticulum, conventional laparoscopic instruments were adopted^[26-29].

INTRACORPOREAL DIVERTICULECTOMY VS EXTRACORPOREAL DIVERTICULECTOMY

Meckel's diverticulectomy can be performed either intracorporeally or extracorporeally. Intracorporeal diverticulectomy can be performed total laparoscopically without the need to enlarge the umbilical wound. The use of endoscopic staplers was the most frequent reported device used in diverticulectomy^[7,23]. Schier *et al*^[30], on the other hand, reported the use of endoloop and divided the diverticulum as in appendectomy. The early reports on laparoscopic assisted diverticulectomy favored the intracorporeal method.

One of the concerns in total laparoscopic intracorporeally diverticulectomy was failure to perform segmental resection of Meckel's diverticulum. Isolated diverticulectomy bears the risk of leaving ectopic gastric mucosa in the adjacent ileum. Varcoe advised the use the height-to-diameter ratio to determine the method of resection^[31]. If the ratio is less than 2, there will be an increased risk in having the ectopic mucosa in the adjacent ileum, segmental resection will be advised.

In extracorporeal diverticulectomy, the Meckel's diverticulum was delivered through an enlarged umbilical wound. Segmental resection of the Meckel's diverticulum and the adjacent ileum were carried out. Hand-sewn small to small intestine anastomosis were performed^[1,12]. The principle of surgery is the same in conventional or SILS approach. The use of expensive laparoscopic staplers was avoided^[9]. Ng *et al*^[32] described the use of laparoscopic assisted extracorporeal Meckel's diverticulectomy with endo GIA stapler and side-to-side ileal anastomosis. However, this method did not gain popularity.

SAFETY ISSUES ON LAPAROSCOPIC ASSISTED MECKEL'S DIVERTICULECTOMY

Park *et al*^[2] reported the Mayo clinic experience with 1476 patients with Meckel's diverticulum. The study included children and adult and did not specifically define the approach of operation. Post-operative complication in the most 100 resected diverticulum was 13% in symptomatic group and 20% in asymptomatic group. It is reported that the rate for postdiverticulectomy adhesive intestinal obstruction could be as high as 10% to 15% in children^[33].

Intraoperative complication after laparoscopic assisted diverticulectomy was never reported in the literature. Sai Prasad *et al*^[12] reported 8% of patients had intestinal obstruction after the operation. He suggested that the adhesion is secondary to ischemic bowel after release of the obstruction. Other studies did not show any intestinal obstruction post-operatively^[1,9]. They all concluded laparoscopic assisted Meckel's diverticulectomy was safe and feasible with good outcome.

LAPAROSCOPIC MANAGEMENT OF MECKEL'S DIVERTICULUM IN ADULT

Since majority of complicated Meckel's diverticulum occurred in childhood, there were only few case series in reporting the use of laparoscopy in the management of Meckel's diverticulum in adult^[34,35]. Ding *et al*^[34] reported 15 cases of perforated Meckel's diverticulum managed by laparoscopy. They reported the use of laparoscopic assisted extracorporeally resection of the diverticulum if the base was > 2 cm. If the base of the diverticulum was < 2 cm, they would performed laparoscopic intracorporeally excision with laparoscopic staplers.

Rivas *et al*^[35] reported their experience in the lapa-

roscopic management of Meckel's diverticulum. In his study, laparoscopic assisted extracorporeal excision of the diverticulum was adopted in all the cases.

CONCLUSION

Laparoscopy has emerged as an important tool in the diagnosis and management of children with Meckel's diverticulum. Conventional laparoscopy or single site incision surgery were reported to be safe and feasible in Meckel's diverticulectomy. Extracorporeal diverticulectomy was in favors than intracorporeal diverticulectomy in reports series because segmental resection of the Meckel's diverticulum can be performed without the use of expensive laparoscopic staplers. Complete excision of the diverticulum and the adjacent intestine containing ectopic mucosa is essential to minimize the chance of recurrent symptom.

REFERENCES

- 1 Chan KW, Lee KH, Mou JW, Cheung ST, Tam YH. Laparoscopic management of complicated Meckel's diverticulum in children: a 10-year review. *Surg Endosc* 2008; **22**: 1509-1512 [PMID: 18322735 DOI: 10.1007/s00464-008-9832-0]
- 2 Park JJ, Wolff BG, Tollefson MK, Walsh EE, Larson DR. Meckel diverticulum: the Mayo Clinic experience with 1476 patients (1950-2002). *Ann Surg* 2005; **241**: 529-533 [PMID: 15729078 DOI: 10.1097/01.sla.0000154270.14308.5f]
- 3 Chan KW, Lee KH, Tam YH, Yeung CK. Minimal invasive surgery in pediatric solid tumors. *J Laparoendosc Adv Surg Tech A* 2007; **17**: 817-820 [PMID: 18158818 DOI: 10.1089/lap.2007.0033]
- 4 Lee KH, Tam YH, Yeung CK, Chan KW, Sihoe JD, Cheung ST, Mou JW. Laparoscopic excision of choledochal cysts in children: an intermediate-term report. *Pediatr Surg Int* 2009; **25**: 355-360 [PMID: 19255762 DOI: 10.1007/s00383-009-2343-9]
- 5 Tam YH, Lee KH, Sihoe JD, Chan KW, Wong PY, Cheung ST, Mou JW. Laparoscopic hernia repair in children by the hook method: a single-center series of 433 consecutive patients. *J Pediatr Surg* 2009; **44**: 1502-1505 [PMID: 19635295 DOI: 10.1016/j.jpedsurg.2008.10.071]
- 6 Chan KW, Lee KH, Mou JW, Cheung ST, Tam YH. The outcome of laparoscopic portoenterostomy for biliary atresia in children. *Pediatr Surg Int* 2011; **27**: 671-674 [PMID: 21286732 DOI: 10.1007/s00383-011-2859-7]
- 7 Teitelbaum DH, Polley TZ, Obeid F. Laparoscopic diagnosis and excision of Meckel's diverticulum. *J Pediatr Surg* 1994; **29**: 495-497 [PMID: 8014801 DOI: 10.1016/0022-3468(94)9007-5-2]
- 8 Valla JS, Steyaert H, Leculée R, Pebeyre B, Jordana F. Meckel's diverticulum and laparoscopy of children. What's new? *Eur J Pediatr Surg* 1998; **8**: 26-28 [PMID: 9550273 DOI: 10.1055/s-2008-1071114]
- 9 Shalaby RY, Soliman SM, Fawy M, Samaha A. Laparoscopic management of Meckel's diverticulum in children. *J Pediatr Surg* 2005; **40**: 562-567 [PMID: 15793736 DOI: 10.1016/j.jpedsurg.2004.11.032]
- 10 Craigie RJ, Forrest N, Nanthakumaran S, Mahomed AA. Laparoscopy in diagnosis and management of Meckel's diverticulum. *J Laparoendosc Adv Surg Tech A* 2006; **16**: 70-73 [PMID: 16494554 DOI: 10.1089/lap.2006.16.70]
- 11 Prasad TR, Chui CH, Jacobsen AS. Laparoscopic-assisted resection of Meckel's diverticulum in children. *JLS* 2006; **10**: 310-316 [PMID: 17212886]

- 12 **Sai Prasad TR**, Chui CH, Singaporewalla FR, Ong CP, Low Y, Yap TL, Jacobsen AS. Meckel's diverticular complications in children: is laparoscopy the order of the day? *Pediatr Surg Int* 2007; **23**: 141-147 [PMID: 17171378 DOI: 10.1007/s00383-006-1844-z]
- 13 **Palanivelu C**, Rangarajan M, Senthilkumar R, Madankumar MV, Kavalakat AJ. Laparoscopic management of symptomatic Meckel's diverticula: a simple tangential stapler excision. *JLS* 2008; **12**: 66-70 [PMID: 18402742]
- 14 **Ponsky TA**, Diluciano J, Chwals W, Parry R, Boulanger S. Early experience with single-port laparoscopic surgery in children. *J Laparoendosc Adv Surg Tech A* 2009; **19**: 551-553 [PMID: 19575633 DOI: 10.1089/lap.2009.0092]
- 15 **Vane DW**, West KW, Grosfeld JL. Vitelline duct anomalies. Experience with 217 childhood cases. *Arch Surg* 1987; **122**: 542-547 [PMID: 3495250 DOI: 10.1001/archsurg.1987.01400170048007]
- 16 **Rerksuppaphol S**, Hutson JM, Oliver MR. Ranitidine-enhanced 99mtechnetium pertechnetate imaging in children improves the sensitivity of identifying heterotopic gastric mucosa in Meckel's diverticulum. *Pediatr Surg Int* 2004; **20**: 323-325 [PMID: 15241619]
- 17 **Poulsen KA**, Qvist N. Sodium pertechnetate scintigraphy in detection of Meckel's diverticulum: is it usable? *Eur J Pediatr Surg* 2000; **10**: 228-231 [PMID: 11034511 DOI: 10.1055/s-2008-1072364]
- 18 **Tseng YY**, Yang YJ. Clinical and diagnostic relevance of Meckel's diverticulum in children. *Eur J Pediatr* 2009; **168**: 1519-1523 [PMID: 19575216 DOI: 10.1007/s00431-009-1023-z]
- 19 **Cooney DR**, Duszynski DO, Camboa E, Karp MP, Jewett TC. The abdominal technetium scan (a decade of experience). *J Pediatr Surg* 1982; **17**: 611-619 [PMID: 6294268]
- 20 **Mariani G**, Pauwels EK, AlSharif A, Marchi S, Boni G, Barreca M, Bellini M, Grosso M, de Bortoli N, Mumolo G, Costa F, Rubello D, Strauss HW. Radionuclide evaluation of the lower gastrointestinal tract. *J Nucl Med* 2008; **49**: 776-787 [PMID: 18413380 DOI: 10.2967/jnumed.107.040113]
- 21 **Sinha CK**, Pallewatte A, Easty M, De Coppi P, Pierro A, Misra D, Biassoni L. Meckel's scan in children: a review of 183 cases referred to two paediatric surgery specialist centres over 18 years. *Pediatr Surg Int* 2013; **29**: 511-517 [PMID: 23417523 DOI: 10.1007/s00383-013-3270-3]
- 22 **Lee KH**, Yeung CK, Tam YH, Ng WT, Yip KF. Laparoscopy for definitive diagnosis and treatment of gastrointestinal bleeding of obscure origin in children. *J Pediatr Surg* 2000; **35**: 1291-1293 [PMID: 10999681 DOI: 10.1053/jpsu.2000.9299]
- 23 **Huang CS**, Lin LH. Laparoscopic Meckel's diverticulectomy in infants: report of three cases. *J Pediatr Surg* 1993; **28**: 1486-1489 [PMID: 8301465 DOI: 10.1016/0022-3468(93)90437-P]
- 24 **Cobellis G**, Crucetti A, Mastroianni L, Amici G, Martino A. One-trocar transumbilical laparoscopic-assisted management of Meckel's diverticulum in children. *J Laparoendosc Adv Surg Tech A* 2007; **17**: 238-241 [PMID: 17484657 DOI: 10.1089/lap.2006.0036]
- 25 **Krpata DM**, Ponsky TA. Instrumentation and equipment for single-site umbilical laparoscopic surgery. *Semin Pediatr Surg* 2011; **20**: 190-195 [PMID: 21968153 DOI: 10.1053/j.sempedsurg.2011.05.002]
- 26 **Tam YH**, Chan KW, Wong YS, Houben CH, Pang KK, Tsui SY, Mou JW, Lee KH. Single-incision laparoscopic surgery in diagnosis and treatment for gastrointestinal bleeding of obscure origin in children. *Surg Laparosc Endosc Percutan Tech* 2013; **23**: e106-e108 [PMID: 23752016 DOI: 10.1097/SLE.0b013e3182806517]
- 27 **Tam YH**, Lee KH, Sihoe JD, Chan KW, Cheung ST, Pang KK. Initial experience in children using conventional laparoscopic instruments in single-incision laparoscopic surgery. *J Pediatr Surg* 2010; **45**: 2381-2385 [PMID: 21129550 DOI: 10.1016/j.jpedsurg.2010.08.036]
- 28 **Garey CL**, Laituri CA, Ostlie DJ, Snyder CL, Andrews WS, Holcomb GW, St Peter SD. Single-incision laparoscopic surgery in children: initial single-center experience. *J Pediatr Surg* 2011; **46**: 904-907 [PMID: 21616250 DOI: 10.1016/j.jpedsurg.2011.02.020]
- 29 **Hattori K**, Sato M, Miyauchi Y. Single-incision laparoscopic surgery for small bowel resection with an intraumbilical arcuate incision in children. *Asian J Endosc Surg* 2012; **5**: 172-175 [PMID: 23095294 DOI: 10.1111/j.1758-5910.2012.00150.x]
- 30 **Schier F**, Hoffmann K, Waldschmidt J. Laparoscopic removal of Meckel's diverticula in children. *Eur J Pediatr Surg* 1996; **6**: 38-39 [PMID: 8721178 DOI: 10.1055/s-2008-1066466]
- 31 **Varcoe RL**, Wong SW, Taylor CF, Newstead GL. Diverticulectomy is inadequate treatment for short Meckel's diverticulum with heterotopic mucosa. *ANZ J Surg* 2004; **74**: 869-872 [PMID: 15456435 DOI: 10.1111/j.1445-1433.2004.03191.x]
- 32 **Ng WT**, Wong MK, Kong CK, Chan YT. Laparoscopic approach to Meckel's diverticulectomy. *Br J Surg* 1992; **79**: 973-974 [PMID: 1422773]
- 33 **Amoury RA**, Snyder CL. Meckel's diverticulum. Pediatric surgery. Louis: Mosby, St., 1988: 1173-1184
- 34 **Ding Y**, Zhou Y, Ji Z, Zhang J, Wang Q. Laparoscopic management of perforated Meckel's diverticulum in adults. *Int J Med Sci* 2012; **9**: 243-247 [PMID: 22577339 DOI: 10.7150/ijms.4170]
- 35 **Rivas H**, Cacchione RN, Allen JW. Laparoscopic management of Meckel's diverticulum in adults. *Surg Endosc* 2003; **17**: 620-622 [PMID: 12582775]

P- Reviewer: Fabozzi M, Herbella FAM, Li B, Tanyi M
S- Editor: Ma YJ **L- Editor:** A **E- Editor:** Wang CH





Published by **Baishideng Publishing Group Inc**

8226 Regency Drive, Pleasanton, CA 94588, USA

Telephone: +1-925-223-8242

Fax: +1-925-223-8243

E-mail: bpgooffice@wjgnet.com

Help Desk: <http://www.wjgnet.com/esps/helpdesk.aspx>

<http://www.wjgnet.com>



ISSN 1007-9327



9 771007 932045