

Ocular Pathogenicity of Types 1 and 2 *Herpesvirus hominis* in Rabbits

J. O. OH, G. B. MOSCHINI, M. OKUMOTO, AND T. STEVENS

Francis I. Proctor Foundation, University of California, San Francisco, California 94122

Received for publication 30 August 1971

Type 2 strains of *Herpesvirus hominis* produced more severe lesions in rabbit corneas than type 1 strains.

There are two types of *Herpesvirus hominis* (HVH), each possessing distinct antigenic and biologic characteristics (3). Type 1 HVH is recovered primarily from nongenital sites and spreads nongenitally; type 2 ("genital herpesvirus") is recovered primarily from genital sites and spreads venereally or from mother to newborn infant. Type 2 HVH is known to be associated with fetal and neonatal disease (3), cervical cancer (4, 6), and chronic neurological disease (3). Recently, it was also found to be responsible for cases of neonatal keratoconjunctivitis with chorioretinitis that resulted in severe visual impairment (1). In view of this reported pathogenicity for the human eye and the high frequency of various types of oculogenital infection at present, information on the pathogenesis of type 2 HVH in the eye is urgently needed. To supply some of this information, we have compared the clinical manifestations of type 2 HVH infections of the rabbit eye with the manifestations of comparable type 1 HVH infections.

Seven strains of type 1 (VR₃, Sheely, Tyler, W270-1, W270-4, W270-11, W270-12) and seven strains of type 2 (MS, Cornelius, Curtis, P124, P407, E91, X263) of HVH were employed. All of the viruses were passed and grown in primary cultures of rabbit kidney cells. Both eyes of five to six rabbits (New Zealand White male, weighing 2 kg each) were used to test each strain of HVH. Approximately 10⁵ 50% tissue culture infectious doses (TCID₅₀) of the virus under investigation were instilled to either intact or abraded corneas. The lesions were examined daily by gross inspection and staining of the epithelial lesions with fluorescein followed by washing with phosphate-buffered saline containing 100 units of penicillin and 100 μg of streptomycin per ml. The stained corneal lesions were graded from 0 to 4 in terms of the relation of the size of lesions to the size of the cornea (2), a grade of 0 representing no lesions and a grade of 4 representing complete corneal involvement.

Ocular changes after instillation of HVH onto intact corneas. The principal lesions were conjunctivitis, corneal ulceration, pannus, and iritis. The onset, severity, and duration of the lesions were remarkably similar among strains of the same type of HVH but were sharply different from type to type as described below.

All seven strains of type 1 HVH caused a slight-to-moderate conjunctivitis and punctate corneal epithelial erosion that began to appear on day 3 or 4 postinfection (Fig. 1). This punctate keratitis progressed rapidly to a dendritic or geographic ulcer and by day seven had reached a peak of severity. However, the lesions were still superficial. After day 7, they regressed rapidly, and between day 10 and day 30 they had disappeared completely from all eyes without leaving any obvious scars or opacity of the cornea (Table 1).

In contrast to the type 1 HVH infection, the onset of the ocular lesions in type 2 HVH-infected eyes was much later, ranging from day 5 to day 12. However, the lesions themselves, with an exception of the eyes infected with strain E91, were much more severe and of longer duration as shown in Fig. 1. Corneal lesions were deep, extending into the stroma, and covered more than two-thirds of the corneal surface within 10 days after their first appearance. The severe corneal lesions were accompanied by extensive pannus (new blood vessels) that arose from the entire circumference of the limbus and rapidly extended centripetally. Eventually, there were total pannus, severe opacification, and scarring in many corneas (Table 1). The conjunctivitis had subsided by day 25, but the pannus and corneal scarring persisted throughout the 2-month period of observation.

Ocular lesions after instillation of HVH onto abraded corneas. The onset of conjunctivitis and punctate keratitis was 2 or 5 days earlier in the abraded corneas infected with type 1 or type 2 HVH, respectively, than that in the intact corneas. As for the corneal scarring, four out of seven strains of type 1 HVH produced scars, opacity,

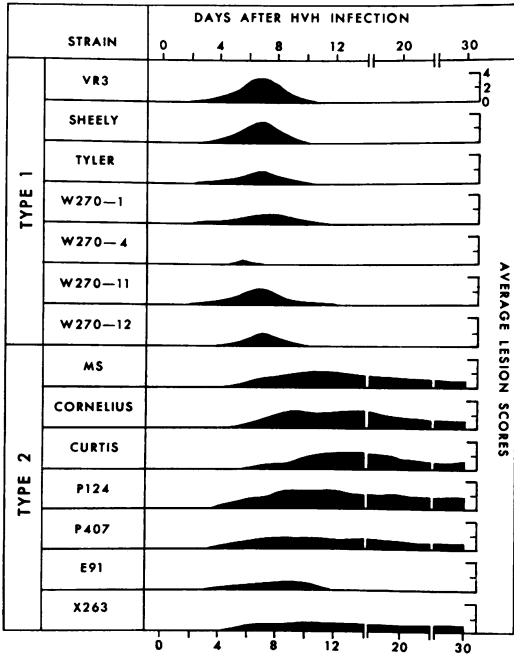


FIG. 1. Corneal lesions produced after instillation of strains of type 1 and type 2 *Herpesvirus hominis* (10^8 TCD₅₀) onto intact rabbit corneas. The graph represents the average lesion scores of 10 to 12 corneas.

and total pannus in 50 to 60% of the corneas, and the remaining three strains failed to produce them in any eyes (Table 1). On the other hand, all seven strains of type 2 HVH produced corneal scarring, opacity, and pannus which were present in all eyes infected with four strains, and in 85, 75, and 25% of corneas infected with each of the remaining three strains. The periodic bacterial cultures of material from all of the infected eyes were either negative or revealed a negligible number of bacteria.

A smaller inoculum (10^8 TCD₅₀) of a strain of each type (Sheely and Curtis strains) was also tested for the production of ocular lesions in the abraded corneas. The corneal lesions produced by the type 1 strain healed without scarring in all eyes, whereas 60% of the type 2-infected corneas showed scars.

Rapp (5) reported that small plaque variants were less capable of producing keratitis in rabbits than large plaque variants, and Wheeler (7) showed that the HF strain (type 2) of HVH caused a more severe keratoconjunctivitis than HPF strain (type 1). Our study also indicated that type 2 strains of HVH caused more severe ocular

TABLE 1. Scar formation in intact and abraded corneas inoculated with type 1 or type 2 *Herpesvirus hominis*

<i>H. hominis</i> type and strain	Per cent of corneas with scars ^a	
	Intact cornea	Abraded cornea
Type 1, strain VR ₁	0	0
Sheely	0	50
Tyler	0	50
W270-1	0	0
W270-4	0	0
W270-11	0	60
W270-12	0	60
Type 2, strain MS	57	100
Cornelius	67	100
Curtis	67	100
P124	33	85
P407	33	100
E91	0	25
X263	17	75

^a One month after instillation of *H. hominis* (10^8 TCD₅₀).

lesions than strains of type 1 virus in both intact and abraded rabbit corneas. The results apparently reveal a difference between type 1 and type 2 HVH in their ocular pathogenicity.

We thank A. J. Nahmias for strains of types 1 and 2 *Herpesvirus hominis* and Nancy Schlenke for excellent technical assistance.

This study was supported by Public Health Service grant EY 00310 from the National Eye Institute. G. B. Moschini was a Fight for Sight Postgraduate Research Fellow, and T. Stevens is a National Institutes of Health Research Fellow.

LITERATURE CITED

- Hagler, W. S., P. V. Walters, and A. J. Nahmias. 1969. Ocular involvement in neonatal herpes simplex virus infection. *Arch. Ophthalmol.* 82:169-176.
- Kaufman, H. E., and E. D. Maloney. 1961. Experimental herpes simplex keratitis. *Arch. Ophthalmol.* 66:99-102.
- Nahmias, A. J., and W. R. Dowdle. 1968. Antigenic and biologic differences in *Herpesvirus hominis*. *Progr. Med. Virol.* 10:110-159.
- Naib, Z. M., A. J. Nahmias, W. E. Josey, and J. H. Kramer. 1969. Genital herpes infection: association with cervical dysplasia and carcinoma. *Cancer* 23:940-945.
- Rapp, F. 1963. Variants of herpes simplex virus: isolation, characterization, and factors influencing plaque formation. *J. Bacteriol.* 86:985-991.
- Rawls, W., W. A. F. Tompkins, M. E. Figueroa, and J. L. Meinicke. 1968. Herpesvirus type 2: association with carcinoma of the cervix. *Science* 161:1255-1256.
- Wheeler, C. E. 1964. Biologic comparison of a syncytial and a small giant cell-forming strain of herpes simplex. *J. Immunol.* 93:749-756.