

Autologous Transplantation of a Free Tenon's Graft for Repairing Excessive Bleb Leakage after Trabeculectomy: A Case Report

Motofumi Kawai^a Seigo Nakabayashi^a Kosuke Shimizu^b
Kazuomi Hanada^a Akitoshi Yoshida^a

^aDepartment of Ophthalmology, Asahikawa Medical University, Asahikawa, and

^bDepartment of Ophthalmology, Oji General Hospital, Tomakomai, Japan

Key Words

Autologous Tenon's graft · Bleb leak · Trabeculectomy · Hypotony

Abstract

Purpose: To report a case of autologous transplantation of a free Tenon's graft to repair excessive bleb leakage after trabeculectomy. **Case Report:** A 39-year-old Japanese woman presented with severe hypotony in her left eye. She had undergone trabeculectomy with mitomycin C 14 years ago. Slit-lamp examination showed an ischemic and ruptured bleb, excessive bleb leakage, and an extremely shallow anterior chamber. A large scleral defect was vaguely observed through the bleb conjunctiva. The hypotony was attributed to excessive bleb leakage. A surgical revision was required. First, the avascular bleb conjunctiva and the melted scleral flap were excised. A scleral defect was observed. Thick fibrotic tissue, i.e., the autologous Tenon's graft, was separated from the underlying sclera, cut to the desired size to cover the defect, and sutured to the sclera with 10-0 nylon sutures. Irrigation with balanced salt solution through the paracentesis confirmed deepening of the anterior chamber with no bleb leakage. In the current case, a layer of amniotic membrane was applied to cover the largely exposed sclera. Two weeks postoperatively, the surgical site was totally re-epithelialized with no aqueous leakage. Three months postoperatively, vascularization into the surgical site was observed. The intraocular pressure remained within normal levels without recurrent bleb leakage. **Conclusions:** Autologous transplantation of a free Tenon's graft successfully repaired excessive bleb leakage through a scleral defect after trabeculectomy. This technique is easier, safer, and may be more cost effective for repairing excessive bleb leakage after trabeculectomy than conventional management techniques.

© 2014 S. Karger AG, Basel

Motofumi Kawai, MD, PhD
Department of Ophthalmology
Asahikawa Medical University
Midorigaokahigashi 2-1-1-1, Asahikawa 078–8510 (Japan)
E-Mail m-kawai@asahikawa-med.ac.jp

Introduction

Hypotony is a major complication after trabeculectomy [1, 2]. Persistent hypotony may cause hypotony maculopathy that can lead to irreversible visual loss. Therefore, ophthalmologists who perform trabeculectomy should be familiar with strategies to repair this condition. In many cases, hypotony results from either aqueous overfiltration or a bleb leak. The latter, especially, is considered to be a strong risk factor for bleb-related infections [3].

Many measures for repairing bleb leaks have been reported. Usually, the first steps are conservative. If those methods failed, surgery is required. However, in cases of late-onset bleb leaks, it is sometimes challenging to restore bleb function because of a weakened bleb wall and melted scleral flap, especially long time after trabeculectomy with mitomycin C (MMC). In such cases, bleb leaks occur almost directly from the anterior chamber (AC), resulting in a shallow AC with severe hypotony. Every effort should be made to repair the bleb leak first. Although preserved sclera [4] or cornea [5, 6] has been used successfully to reconstruct the leaking site, there is a risk in relation to storage, i.e., infection or immunogenicity. In addition, the use of those materials requires several procedures before approval in many hospitals.

We report a successful case of autologous transplantation of a free Tenon's graft to repair excessive bleb leakage with a scleral defect that occurred long time after trabeculectomy with MMC.

Case Report

A 39-year-old Japanese woman was referred to our hospital with severe hypotony in her left eye on November 22, 2013. She had previously undergone trabeculectomy with MMC for secondary glaucoma in July 1999. The best-corrected visual acuity was 10/20 and the intraocular pressure (IOP) was 3 mm Hg. Slit-lamp examination (fig. 1) showed an ischemic and ruptured bleb, excessive bleb leakage, and an extremely shallow AC. Fundus examination showed a choroidal detachment. The hypotony was attributed to excessive bleb leakage.

We again observed the leaking bleb by slit-lamp examination. A large scleral defect, which probably represented the corneoscleral block excision made during the initial surgery, was vaguely visible, suggesting that the scleral flap was almost melted. The bleb leak appeared to occur through a direct filtration mechanism. Therefore, common conservative techniques for leaking blebs were considered to be inadequate, and surgical revision was performed promptly. The procedure and the results are described below (fig. 2).

After the avascular bleb tissue and the melted scleral flap had been removed, a scleral fistula was observed. A viscoelastic was injected through the paracentesis to deepen the AC to facilitate the following procedures. Thick fibrotic Tenon's tissue was carefully separated in a sheet of membrane for use as the autologous Tenon's graft. The graft was cut to the desired size to cover the scleral defect and sutured tightly to the sclera with 10-0 nylon sutures. The viscoelastic was removed, and the AC was deepened after irrigation with balanced salt solution. No aqueous leakage through the graft was observed. To promote conjunctival re-epithelialization, a layer of amniotic membrane was applied to cover the largely exposed sclera in the current case. Subconjunctival injection of betamethasone and tobramycin was administered at the end of the surgery.

Two weeks postoperatively, the surgical site was totally re-epithelialized with no aqueous leakage using the Seidel test. Three months postoperatively, vascularization into the surgical site was observed. The visual acuity was 20/20 and the IOP remained within normal levels without recurrent bleb leaks.

Discussion

Numerous measures for repairing leaking blebs have been reported. Spontaneous closure with a pressure patch [7], a large-diameter therapeutic soft contact lens [8] or autologous fibrin glue [9, 10] may be effective when the bleb leak is small. Injection of autologous blood into the bleb [11] or tapering topical corticosteroids to allow enhanced fibrosis may also be effective. In cases with a large conjunctival defect, suturing the defect or conjunctival autografts [12–14] are required. In the current case, however, those techniques were considered to be inadequate because of copious bleb leakage.

First, we planned to use preserved sclera as a patch graft. During the operation, however, we decided to use a fibrotic Tenon's membrane, because thick fibrotic tissue could be obtained by carefully excising it from the underlying sclera. As a result, we obtained a successful outcome.

Morris et al. [15] also used an autologous Tenon's capsule as a patch graft and successfully created a functional bleb. Those authors dissected the graft leaving a pedicle attachment abutting the fistula site, which differed from our procedure by which we obtained a free graft. The use of a free graft was advantageous in that it could be acquired from anywhere, increasing the chance of obtaining a thick membrane with good durability. This technique may be applicable to microholes in the scleral or the conjunctival flap.

Although the use of a conjunctival autograft may be effective for covering the fistula, our technique was advantageous in that Tenon's tissue is rich in fibroblasts compared to conjunctival tissue. This feature may accelerate wound healing on the scleral fistula, resulting in prompt and robust scarring. Other advantages are that there is no risk of infection in relation to the storage, no immunogenicity, and no cost. An autologous lamellar scleral graft [15] is free from these problems, but it is more invasive than the current technique.

In the current case, we obtained a thick Tenon's membrane probably because the patient was young. However, it is likely that Tenon's tissue in elderly patients may be thin. In those cases, an alternative approach may be required. Further, in the current case, the IOP remained within normal levels, although repairing a leaky fistula can cause IOP elevations due to loss of the IOP-lowering effect. When IOP elevations occur, further trabeculectomy is required.

In conclusion, we used a free autologous Tenon's graft as a patch graft to repair excessive bleb leakage through a scleral defect after trabeculectomy. Although this is a single case report, we believe that this technique is easier, safer, and may be more cost effective than conventional management procedures for repairing complicated leaking blebs.

References

- 1 Fannin LA, Schiffman JC, Budenz DL: Risk factors for hypotony maculopathy. *Ophthalmology* 2003;110:1185–1191.
- 2 Tan YL, Tsou PF, Tan GS, Perera SA, Ho CL, Wong TT, Aung T: Postoperative complications after glaucoma surgery for primary angle-closure glaucoma vs primary open-angle glaucoma. *Arch Ophthalmol* 2011;129:987–992.
- 3 Ciulla TA, Beck AD, Topping TM, Baker AS: Blebitis, early endophthalmitis, and late endophthalmitis after glaucoma-filtering surgery. *Ophthalmology* 1997;104:986–995.
- 4 Melamed S, Ashkenazi I, Belcher DC 3rd, Blumenthal M: Donor scleral graft patching for persistent filtration bleb leak. *Ophthalmic Surg* 1991;22:164–165.

- 5 Fukuchi T, Matsuda H, Ueda J, Yamada A, Suda K, Abe H: Corneal lamellar grafting to repair late complications of mitomycin C trabeculectomy. *Clin Ophthalmol* 2010;4:197–202.
- 6 Bochmann F, Kaufmann C, Kipfer A, Thiel MA: Corneal patch graft for the repair of late-onset hypotony or filtering bleb leak after trabeculectomy: a new surgical technique. *J Glaucoma* 2014;23:e76–e80.
- 7 Sugar HS: Treatment of hypotony following filtering surgery for glaucoma. *Am J Ophthalmol* 1971;71:1023–1033.
- 8 Blok MD, Kok JH, van Mil C, Greve EL, Kijlstra A: Use of the Megasoft Bandage Lens for treatment of complications after trabeculectomy. *Am J Ophthalmol* 1990;110:264–268.
- 9 Kajiwara K: Repair of a leaking bleb with fibrin glue. *Am J Ophthalmol* 1990;109:599–601.
- 10 Asrani SG, Wilensky JT: Management of bleb leaks after glaucoma filtering surgery. Use of autologous fibrin tissue glue as an alternative. *Ophthalmology* 1996;103:294–298.
- 11 Choudhri SA, Herndon LW, Damji KF, Allingham RR, Shields MB: Efficacy of autologous blood injection for treating overfiltering or leaking blebs after glaucoma surgery. *Am J Ophthalmol* 1997;123:554–555.
- 12 Wilson MR, Kotas-Neumann R: Free conjunctival patch for repair of persistent late bleb leak. *Am J Ophthalmol* 1994;117:569–574.
- 13 Honjo M, Tanihara H, Inatani M, Honda Y: Removal of a large non-functional bleb and reconstruction with free conjunctival autograft after trabeculectomy. *Acta Ophthalmol Scand* 2001;79:326–327.
- 14 Panday M, Shantha B, George R, Boda S, Vijaya L: Outcomes of bleb excision with free autologous conjunctival patch grafting for bleb leak and hypotony after glaucoma filtering surgery. *J Glaucoma* 2011;20:392–397.
- 15 Morris DA, Ramocki JM, Shin DH, Glover BK, Kim YY: Use of autologous Tenon's capsule and scleral patch grafts for repair of excessively draining fistulas with leaking filtering blebs. *J Glaucoma* 1998;7:417–419.

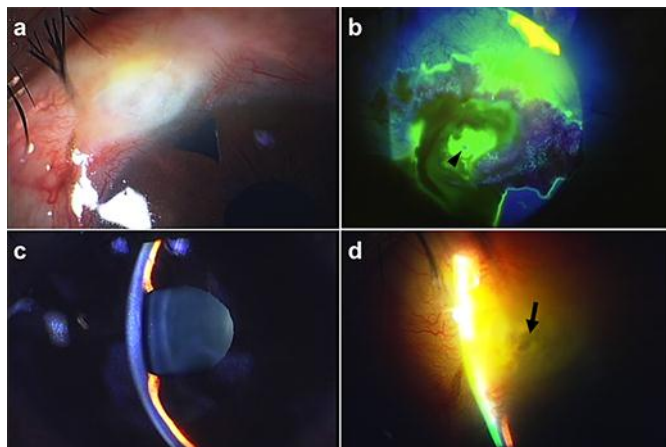


Fig. 1. Preoperative slit-lamp examination shows the ischemic and ruptured bleb (a), excessive bleb leak by Seidel testing (arrowheads) (b), and an extremely shallow AC (c). d A large scleral defect (arrow) is vaguely visible.

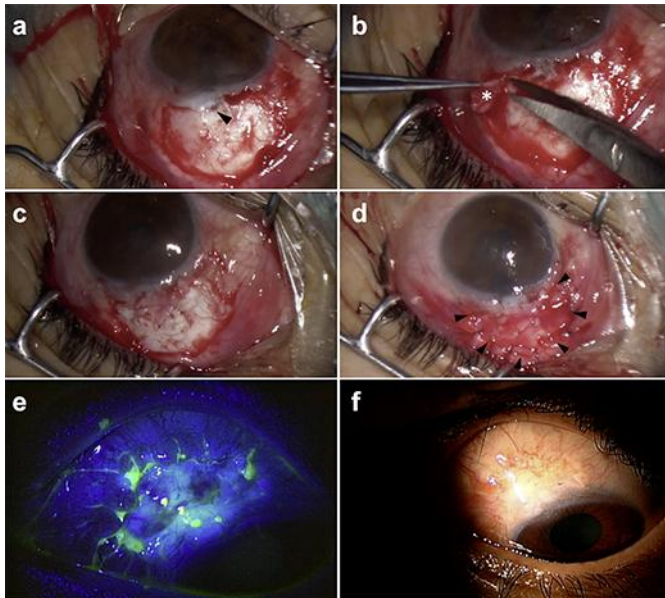


Fig. 2. **a** After the avascular bleb tissue and the melted scleral flap had been removed, the scleral fistula (arrowhead) can be seen. **b** Thick fibrotic tissue is carefully separated in a sheet of membrane (*) that is used for the autologous Tenon's graft. **c** The graft is cut to the desired size to cover the defect and sutured with 10-0 nylon sutures. **d** A layer of amniotic membrane (arrowheads) is applied over the exposed sclera. **e** Two weeks postoperatively, the site is totally re-epithelialized with no aqueous leak. **f** Three months postoperatively, vascularization into the surgical site is observed.