

# Anatomical Study of Pterygospinous and Pterygoalar Bar in Human Skulls with their Phylogeny and Clinical Significance

KAVITHA KAMATH. B<sup>1</sup>, VASANTHA. K<sup>2</sup>

## ABSTRACT

**Background:** Pterygospinous and pterygoalar ligaments present at the cranial base may sometimes get ossified leading to the formation of complete or incomplete bony bars in relation to foramen ovale. These are of clinical importance because these may obliterate the foramen ovale causing mandibular neuralgia. They may cause trouble in performing thermocoagulation and anaesthesia for trigeminal neuralgia. They may pose surgical difficulty in approaching the retro and parapharyngeal spaces and hence the anatomy of these bony bars is very important.

**Materials and Methods:** The present study was conducted in 100 dry human skulls of unknown sex to know the incidence, side, degree of ossification (complete/ incomplete) and relation of the pterygospinous and pterygoalar bars to the foramen ovale.

**Results:** Pterygospinous and pterygoalar bars were seen in 41 skulls which were classified into Type I (26.83%), Type II (58.54%)

and Type III (14.63%) based on the presence of pterygospinous bar, pterygoalar bar or both together. Pterygospinous bars were seen in 17 skulls of which, one skull (5.88%) had complete and 16 skulls (94.12%) showed incomplete bars. Out of the 30 skulls with pterygoalar bars, complete bar was seen in one (3.33%) and incomplete in 29 skulls (96.67%). These bars were seen more on the left side of the skull than on the right. They were in close relation to the foramen ovale; the pterygospinous bar was inferior or medial to foramen ovale and pterygoalar bar was lateral, inferior or medial to the foramen ovale.

**Conclusion:** The presence of the pterygospinous and pterygoalar bars cause variety of symptoms due to neurovascular entrapment and also obstruct surgical approaches to the base of skull. Hence the anatomical knowledge of these osseous bars is essential for anaesthetists, radiologists, dentists and neurosurgeons to increase the success of diagnostic evaluation and surgical approaches to the cranial base.

**Keywords:** Foramen ovale, Pterygospinous bar, Pterygoalar bar, Trigeminal neuralgia

## INTRODUCTION

Ossification of ligaments can lead to symptomatic compression of regional structures, especially nerves, and should be considered in patients in whom other causes for compressive syndrome cannot be identified. Ossification of ligaments of cranial base can also obstruct surgical corridors and interfere with operative access in this area [1]. Osseous bridging in various parts of the body is a frequent age dependent process, poorly understood and represents the outcome of secondary ossification of fibrous structures [2]. However the presence of these bony bridges in children suggested the possibility of genetic factors [3]. Various ligaments of skull are of clinical importance, among which the pterygospinous and pterygoalar ligaments are located close to the foramen ovale and maintain an important clinical relation with this structure. The pterygospinous bar is either below or medial to the foramen ovale in contrast to the pterygoalar bar which lies lateral to the foramen or runs beneath it, dividing the foramen ovale into two parts [2].

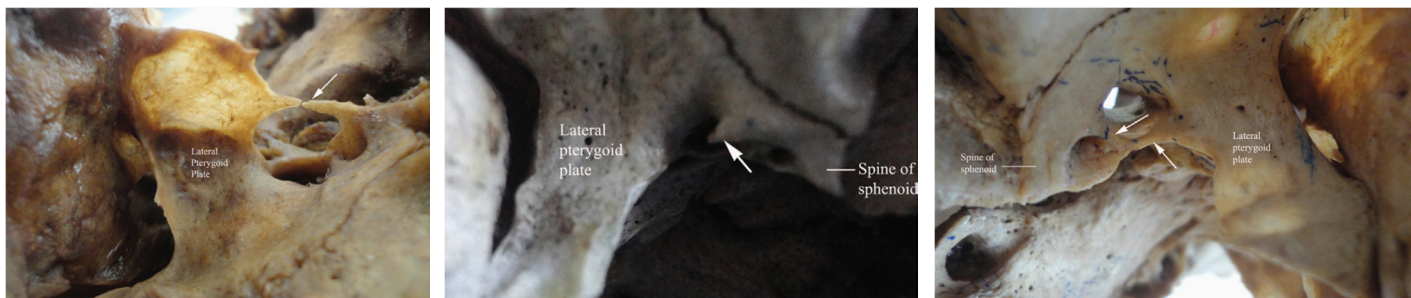
The pterygospinous ligament which is the thickening of the fascia between the lateral and medial pterygoid muscles stretches between the spine of sphenoid to the upper part of the posterior border of the lateral pterygoid plate. The pterygospinous ligament is occasionally replaced by muscular formations such as the pterygospinous muscle which is inserted into the temporomandibular joint capsule extending to the articular disc. Sometimes the pterygospinous ligament may get ossified completely or incompletely. Complete ossification of this ligament was named after Civinini, an Italian anatomist as Civinini bar or pterygospinous bar. The foramen formed by this bar was called as foramen of Civinini or pterygospinous foramen through which passes the medial pterygoid vessels and nerves as well as branches of mandibular nerve to the muscles of mastication [3-5]. So ossification of this ligament may entrap the neurovascular structures and this may be an obstacle for mandibular nerve block [6].

In 1862, German anatomist Hyrtl described the pterygoalar ligament (Hyrtl's ligament) which extends from the root of lateral pterygoid plate to the undersurface of greater wing of sphenoid near the anterolateral edge of foramen spinosum [1]. This ligament may ossify completely or incompletely forming a pterygoalar bar. Complete ossification of pterygoalar ligament leads to a foramen called porus crotaphitico-buccinatorium or pterygoalar foramen [4]. Through this foramen pass some of the branches of the mandibular nerve such as the nerve to masseter and deep temporal nerves [1]. The existence of pterygoalar bar has great clinical significance as it can be responsible for compression of branches of mandibular division of trigeminal nerve producing various neurological disturbances or by blocking the passage of needle through the foramen ovale during percutaneous procedures for treating trigeminal neuralgias [7].

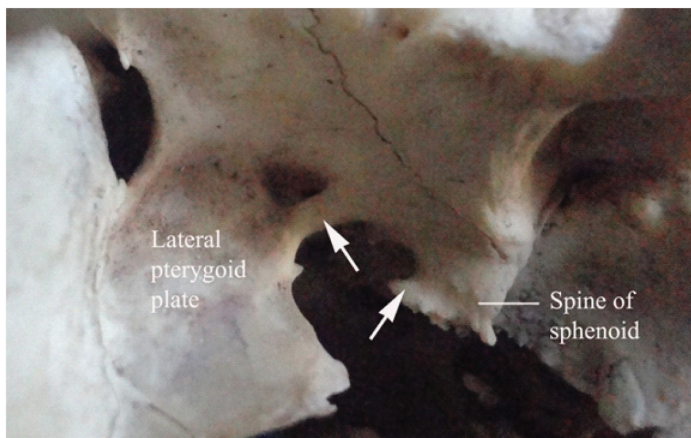
Partial or complete ossification of these ligaments is important from anatomical, anthropologic and clinical point of view, especially with respect to treatment of trigeminal neuralgia [8]. Studies on the incidence of these anatomical formations in human population are very few and there is only scarce information on its morphology in literature [1,4,8-12]. The present study is undertaken to study the

	Type I	Type II	Type III	Total
Right	2(18.18%)	6(25%)	1(16.66%)	9(21.95%)
Left	8(72.73%)	12(50%)	2(33.33%)	22(53.66%)
Bilateral	1(9.09%)	6(25%)	3(50%)	10(24.39%)
Total	11(26.83%)	24(58.54%)	6(14.63%)	41(100%)

**[Table/Fig-1]:** Showing the distribution of Types I, II and III of pterygospinous and pterygoalar bars. NS= non significant, p<0.05 statistically significant



**[Table/Fig-2]:** Type I pattern showing an incomplete pterygospinous bar (arrow) on the right side of the skull  
**[Table/Fig-3]:** Type II pattern showing an incomplete pterygoalar bar (arrow) on left side of the skull  
**[Table/Fig-4]:** Type III pattern showing a complete pterygospinous bar (lower arrow) and incomplete pterygoalar bar (upper arrow) overlapping the pterygospinous bar at its lower end, both these bars seen on right side of the skull



**[Table/Fig-5]:** Type III pattern showing a complete pterygoalar bar (upper arrow) and incomplete pterygospinous bar (lower arrow) on left side of skull

	Pterygospinous bar		Total	Pterygoalar bar		Total
	Complete	Incomplete		Complete	Incomplete	
Right	1(100%)	5(31.25%)	6(35.29%)	0	7(24.14%)	7(23.33%)
Left	0	10(62.5%)	10(58.82%)	1(100%)	15(51.72%)	16(53.33%)
Bilateral	0	1(6.25%)	1(5.88%)	0	7(24.14%)	7(23.33%)
Total	1(5.88%)	16(94.12%)	17(100%)	1(3.33%)	29(96.67%)	30(100%)

**[Table/Fig-6]:** Showing the distribution of complete and incomplete pterygospinous and pterygoalar bars

incidence and anatomy of pterygospinous and pterygoalar bars in human skulls and also their phylogeny and clinical importance.

**MATERIALS AND METHODS**

The present study was conducted in 100 dry adult human skulls of unknown sex available from the Department of Anatomy and Forensic Medicine of Shimoga Institute of Medical Sciences, Shimoga from October 2013 to January 2014. Damaged skulls were excluded from the study. The base of skull was studied for the presence of pterygospinous and pterygoalar bar, whether complete or incomplete, their side (right, left or bilateral) and relation to the foramen ovale (medial, lateral, inferior). Photographs were taken and results were compared with those of previous studies.

**RESULTS**

Out of the 100 skulls studied, 41 showed the presence of pterygospinous and pterygoalar bars. We classified these 41 skulls into 3 types [Table/Fig-1]. Type I [Table/Fig-2] showed the presence of only pterygospinous bar, Type II [Table/Fig-3] showed only pterygoalar bar and Type III [Table/Fig-4,5] showed combination of both. Type I pattern of distribution was seen in 11 skulls (26.83%), Type II in 24 skulls (58.54%) and Type III in 6 skulls (14.63%). Among those which showed Type I pattern, two skulls (18.18%) showed

Study	Population	Pterygospinous bar			Pterygoalar bar		
		Complete	Incomplete	Total	Complete	Incomplete	Total
Tubbs et al., [1]	American	0.65	0.65	1.3	0.65	0.65	1.3
Kapur et al., [28]	Croatian	1.31	14.74	16.05	5.9	14.4	20.3
Peker et al., [26]	Anatolian	5.5	-	-	4.9	-	-
Pinar et al., [10]	Turkish	3.3	9.7	13	1.1	4.98	6.08
Skrzat et al., [14]	Polish	-	-	-	1.43	5.7	7.1
Natsis et al., [2]	Greek	-	-	-	4.1	27.6	31.7
Antonopoulou et al., [11]	Greek	2	25	27	1	7	8
Rosa et al., [8]	Brazilian	8.61	19.36	31.2	12.9	49.4	62.4
Galdames et al., [9]	Brazilian	1.6	13.14	14.74	3.84	22.43	26.27
Devi et al., [4]	Indian	0.98	10.78	11.78	2.45	3.92	6.37
Chakravarthi et al., [25]	Indian	-	-	-	19.7	8.5	28.2
Saran et al., [6]	Indian	1.25	7.5	8.75	-	-	-
Das et al., [13]	Indian	0	1	1	-	-	-
Verma et al., [19]	Indian	1.72	12.93	18.1	-	-	-
Nayak et al., [12]	Indian	5.76	3.84	9.61	-	-	-
Present study	Indian	1	16	17	1	29	30

**[Table/Fig-7]:** Showing the occurrence of pterygospinous and pterygoalar bars in different populations

the presence of bars on the right side, 8 skulls (72.73%) on left and in one skull (9.09%) bilateral. Among those skulls which showed Type II pattern, 6 skulls (25%) showed the bars on right, 12 skulls (50%) on left and 6 skulls (25%) bilateral. Among the skulls which showed Type III pattern, in one case (16.66%) both pterygospinous and pterygoalar bars were seen on right side, in two cases (33.33%) both the bars were seen on left side, two cases (33.33%) showed the presence of right pterygospinous bar with left pterygoalar bar and one skull (16.66%) showed bilateral pterygoalar bars with left pterygospinous bar.

Out of the 100 skulls studied, pterygospinous bars (found in Type I and Type III cases) were seen in total of 17 skulls, out of which one skull (5.88%) showed the presence of complete bar and 16 skulls (94.12%) showed the presence of incomplete bars [Table/Fig-2,4-6]. The only complete pterygospinous bar we found was seen on the right side (100%). In 16 skulls with incomplete pterygospinous bars, 5 skulls (31.25%) had the bar on right side, 10 skulls (62.5%) on left and in one case (6.25%) the bars were bilateral. These osseous

bars were in close relation to the foramen ovale, 5 passed medial to it and 13 crossed the foramen inferiorly.

Pterygoalar bars (seen in Type II and Type III) were present in 30 skulls, of which one skull (3.33%) showed the presence of complete bar and 29 skulls (96.67%) had incomplete pterygoalar bars [Table/Fig-3,4-6]. The only complete pterygoalar bar we found was seen on the left side (100%). Among the 29 skulls with incomplete pterygoalar bars, seven skulls (24.14%) had them on right side, 15 skulls (51.72%) on left and in seven skulls (24.14%) the pterygoalar bars were bilateral. The pterygoalar bars were in close relation to the foramen ovale, five passed medial, 17 passed lateral and 15 crossed the foramen inferiorly.

## DISCUSSION

Present study is one among the very few which provides data on the incidence of both pterygospinous and pterygoalar bars in Indian population. The incidence of pterygospinous and pterygoalar bars in our study is 17% and 30% respectively. The incidence of pterygospinous bars as found in other studies [Table/Fig-7] ranged from 1% to 31.2% whereas that of pterygoalar bars ranged between 1.3% to 62.4% [1,8,13]. Findings from our study were within this range.

According to previous studies, the position of pterygospinous bar was medial or inferior to foramen ovale and the pterygoalar bar was medial, lateral or inferior to the foramen ovale [6,8,14]. In the present study, the pterygospinous bar was most commonly seen to cross the foramen inferiorly and in few cases was medial to the foramen ovale. The pterygoalar bar was most commonly found lateral or inferior to the foramen ovale, and in few cases medial to it.

In our study both the bars were seen more frequently on the left side. Some of the previous studies reported a preference for left side in the unilateral occurrence of the pterygoalar bar [1,15-17] which was similar to our findings. The pterygospinous bar was reported to occur predominantly bilaterally or on the left side when unilateral [16]. No explanation is given in the literature so far to account for the left sided predominance of these bars.

**Phylogeny:** Regarding the ligament of Civinini, some opined that such fibres are derived from the lateral pterygoid muscle or from the pterygoid fascia. In lemurs, the caudal extension of lateral pterygoid plate passes medial to the foramen ovale and a perforation of the plate transmits a part of the mandibular division of trigeminal nerve towards the medial side. In the typical pithecoïd, the pterygospinous bar is complete and passes lateral to foramen ovale, the perforation of bar transmitting the nerve to lateral side. In human and anthropoids, it is usually incomplete. When it is present in varying degrees, it gives rise to ptergoalar and pterygospinous foramen [6,18]. A wide pterygospinous bar exists in skulls of herbivores, rodents, carnivores and mature monkeys and small pterygospinous bar is seen in rodents but not seen in new world monkeys [3,4,6]. Therefore the presence of pterygospinous bar in man is considered to be a phylogenetic remnant [4,19]. There were reports that ossification of pterygospinous ligament was genetically controlled and showed racial variation in frequency [6]. The pterygoalar bar and foramen are normally seen in lower animals and persist in variable percentage of human population of different races [18]. The incidence of these bars in different population of the world is shown in [Table/Fig-7].

**Clinical significance:** Disordered ossification of these ligaments can compress the neighbouring structures, may cause complications in regional surgeries and can also seriously hamper clinical and diagnostic procedures [20]. These formations occupy a deep and high portion in the infratemporal fossa establishing important relationships with mandibular nerve and its branches, otic ganglion, middle meningeal vessels, tympanic nerve and medial and lateral pterygoid muscles. These are compressed against the bone formations and are capable of generating clinically important alterations [9,19]. The neighbouring osseous bars around the

foramen ovale could influence the anatomical organization of the structures that run through this opening and can change their course resulting in their entrapment between the osseous structures and muscles causing neuralgia [21]. Compression or entrapment of motor branches of mandibular nerve can lead to paresis or weakness in the innervated muscle and that of sensory branches can provoke neuralgia or paraesthesia [22].

An ossified pterygospinous ligament can cause entrapment of lingual nerve which runs between the ligament and medial pterygoid muscle. The pterygospinous bridge can also pass between the fibres of lingual nerve and divide it into anterior and posterior parts. The posterior fibres pass lateral to bony bridge while the anterior fibres passes medially in between the tensor veli palatini and the bony bridge, thus vulnerable to risk of compression [23]. This can lead to sensory impairment in anterior two third of tongue, anaesthesia of lingual gums and pain related to articulation. Dentists should therefore be aware of the possible signs of neurovascular compression in regions where lingual nerve is distributed [3,24]. Chorda tympani branch of facial nerve can also get compressed by an ossified pterygospinous ligament and may result in impaired taste sensation from anterior two third of tongue [13]. This ligament could also occlude the blood vessels supplying the trigeminal ganglion [1].

Pterygoalar ligament can potentially compress the deep temporal, lateral pterygoid, buccal nerve, auriculotemporal nerve, chorda tympani or lingual nerve. This can cause several neurological symptoms such as chewing disorders, pain and numbness of buccal region and tongue and salivatory changes of the parotid gland [7,25,26].

The complete pterygoalar bar is of greater clinical importance than the complete pterygospinous bar since the former is more exuberant and may obliterate the foramen ovale [8,18]. In surgical interventions required for relieving trigeminal neuralgia, these ossified ligaments can obstruct the passage of needle into the foramen ovale, thereby disabling the anaesthetization of the trigeminal ganglion or the mandibular nerve [14,24]. These bars may make thermocoagulation of trigeminal ganglion difficult or impossible [4,13]. CT scan of the cranial base may be obtained to better delineate the anatomy of obstructive lesions around the foramen ovale [1]. The Hirtz axial radiograph and submentovertebral projection permit a clear observation of anatomical structures at the skull base [2,8]. If these bars are identified before the procedures, it is recommended to prefer inframandibular approach to the trigeminal ganglion instead of routine supramandibular or transzygomatic approach to overcome failure of trigeminal ganglion block. Thus radiological guidance is required to visualize the foramen ovale and its related structures, which makes puncture easier and more precise [14]. Such information may be of particular use to anaesthetists, dentists, oral maxillofacial surgeons and neurosurgeons to perform invasive procedures in or near the infratemporal fossa [1].

The presence of ossified pterygospinous and pterygoalar bars may obliterate the space between the lateral pterygoid plate and spine of sphenoid which restricts access to retropharyngeal and parapharyngeal space by surgeons [4]. Presence of these bony bars have to be borne in mind when one finds difficulty during surgical approach to base of skull and special care has to be taken to avoid injuries to structures which pass under these ossified ligaments [27]. Anatomical knowledge of these bony bridges around the foramen ovale may be helpful for diagnostic and neurosurgical procedures like percutaneous biopsy of cavernous sinus tumors, electroencephalographic analysis and microvascular decompression by percutaneous trigeminal rhizotomy [20].

From a clinical standpoint, ossified ligaments have become very critical whenever considering block anaesthesia for the mandibular nerve [24]. Mandibular nerve block is a preferred method for pain relief especially for the fractures of mandible or cancer patients [19].

While applying conductive anaesthesia on mandibular nerve by lateral subzygomatic route, these bars act as an obstacle to the high quality conductive anaesthesia [13,28]. Thus the lateral pterygoid plate forms an important landmark for mandibular anaesthesia and any anomaly at the lateral pterygoid plate is bound to confuse anaesthetists [13].

## CONCLUSION

Because of the high incidence of these bars in human population it seems necessary to extend our knowledge of the morphology and topography of these structures. To improve therapeutic success, surgeons and practitioners need more accurate knowledge about the variability of human morphology. The knowledge of osseous bridges of the cranial base helps in understanding and treating complex clinical neuralgias involving oral and maxillofacial region. Thus knowledge of these anatomical entities and their radiographic evaluation help surgeons to do proper planning which increases rate of success of their procedures in trigeminal neuralgias. Hence the detailed anatomical study of this abnormality can contribute to both the investigation of neurological pathologies and the effectiveness of surgical procedures.

## REFERENCES

- [1] Tubbs RS, May Jr WR, Apaydin N, Shoja MM, Shokouhi G, Loukas M, et al. Ossification of ligaments near the foramen ovale: An anatomical study with potential clinical significance regarding transcutaneous approaches to the skull base. *Neurosurgery*. 2009;65:60-64.
- [2] Natsis K, Piagkou M, Skotsimara G, Totlis T, Apostolidis S, Panagiotopoulos NA, et al. The ossified pterygoalar ligament: An anatomical study with pathological and surgical implications. *J Craniomaxillofac Surg*. [Internet] 2013 [cited 2014 Jan 31] [about 5pp]. Available from: <http://dx.doi.org/10.1016/j.jcms.2013.10.003>.
- [3] Piagkou M, Demesticha T, Piagkos G, Georgios A, Panagiotis S. Lingual nerve entrapment in muscular and osseous structures. *Int J Oral Sci*. 2010;2:181-89.
- [4] Devi JD, Mugunthan N, Anbalagan J, Sudha R, Shivadeep S. A study on ossified pterygospinous and pterygoalar ligaments in Indian skulls. *Nat J Basic Med Sci*. 2012;3(2):103-08.
- [5] Standing S, Section editor. Gray's Anatomy. The anatomical basis of clinical practice. Section 3: Head and neck. 39<sup>th</sup> ed. Edinburgh:Elsevier Churchill Livingstone; 2005. p.521.
- [6] Saran RS, Ananthi KS, Subramaniam A, Balaji MST, Vinaitha D, Vaithianathan G. Foramen of Civinini: A new anatomical guide for maxillofacial surgeons. *J Clin Diagn Res*. 2013;7(7):1271-75.
- [7] Rossi AC, Freire AR, Manoel C, Prado FB, Botacin PR, Caria PHF. Incidence of the ossified pterygoalar ligament in Brazilian human skulls and its clinical implications. *J Morphol Sci*. 2011;28:69-71.
- [8] Rosa RR, Faig-Leite H, Faig-Leite FS, Moraes LC, Moraes MEL, Filho EM. Radiographic study on ossification of the pterygospinous and pterygoalar ligaments by the Hirtz axial technique. *Acta Odontol Latinoam*. 2010;23:63-67.
- [9] Galdames IS, Zavando MD, Smith RL. Anatomical study of the pterygospinous and pterygoalar bony bridges and foramina in dried crania and its clinical relevance. *Int J Morphol*. 2010;28:405-08.
- [10] Pinar Y, Arsu G, Aktanlkiz ZA, Bilge O. Pterygospinous and pterygoalar bridges. *Sendrom*. 2004;16:66-69.
- [11] Antonopoulou M, Piagou M, Anagnostopoulou S. An anatomical study of the pterygospinous and pterygoalar bars and foramina- Their clinical relevance. *J Craniomaxillofac Surg*. 2008;36:104-08.
- [12] Nayak SR, Rai R, Krishnamurthy A, Prabhu LV, Ranade AV, Mansur DI, et al. An unusual course and entrapment of the lingual nerve in the infratemporal fossa. *Bratisl Lek Listy*. 2008;109:525-27.
- [13] Das S, Paul S. Ossified pterygospinous ligament and its clinical implications. *Bratisl Lek Listy*. 2007;108:141-43.
- [14] Skrzat J, Walocha J, Srodek R. An anatomical study of the pterygoalar bar and the pterygoalar foramen. *Folia Morphol*. 2005;62:92-96.
- [15] Chouke KS. On the incidence of the foramen of Civinini and the porus crotaphiticobuccinatorius in American Whites and Negroes; observations on 1544 skulls. *Am J Phys Anthropol*. 1946;4:203-25.
- [16] Zarkrzewska JM. Medical management of trigeminal neuralgia. *Br Dent J*. 1990;168:399-401.
- [17] Shaw JP. Pterygospinous and pterygoalar foramina: A role in the etiology of trigeminal neuralgia? *Clin Anat*. 1993; 6:173-78.
- [18] Patnaik VVG, Singla RK, Bala S. Bilateral pterygoalar bar and porus crotaphiticobuccinatorius- A case report. *J Anat Soc India*. 2001;50:161-62.
- [19] Verma RK, Archana R, Anitha R, Chopra J, Pankaj AK, Kumar N, et al. Civinini bar: Incidence in North Indians and its clinical relevance. *National Journal of Clinical Anatomy*. 2013;2:128-33.
- [20] Chakravarthi KK, Venumadhav N, Gandrakota R. Abnormal bone outgrowths and osseous structures around the foramen ovale may lead to mandibular compression or entrapment neuropathy. *Int Jou Bioassays*. 2013;2:922-925.
- [21] Skrzat J, Walocha J, Srodek R, Nizankowska. An atypical position of the foramen ovale. *Folia Morphol*. 2006; 65:396-99.
- [22] Shinde VS, Mallikarjun M, Patil R. A study on an ossified pterygospinous ligament. *J Clin Diagn Res*. 2011;5:978-79.
- [23] Erdogmus S, Pinar Y, Celik S. A cause of entrapment of the lingual nerve: ossified pterygospinous ligament- A case report. *Neuroanatomy*. 2009;8:43-45.
- [24] Daimi SR, Siddiqui AU, Gill SS. Analysis of foramen ovale with special emphasis on pterygoalar bar and pterygoalar foramen. *Folia Morphol*. 2011;70:149-53.
- [25] Chakravarthi KK, Babu KS. An anatomical study of the pterygoalar bar and porus crotaphiticobuccinatorius. *Int J Med Health Sci*. 2012;1(3):3-9.
- [26] Peker T, Karkose M, Anil A, Turgut HB, Gulekon N. The incidence of basal sphenoid bridges in dried crania and cadavers: Their anthropological and clinical relevance. *Eur J Morphol*. 2002;40:171-80.
- [27] Aggarwal B, Gupta M, Kumar H. Ossified ligaments of the skull. *J Anat Soc India*. 2012;61:37-40.
- [28] Kapur E, Dilberovic F, Redzepagic S, Berhamovic E. Variation in the lateral plate of the pterygoid process and the lateral subzygomatic approach to the mandibular nerve. *Med Arh*. 2000;54:133-37.

### PARTICULARS OF CONTRIBUTORS:

1. Assistant Professor, Department of anatomy, SIMS, Shimoga, karnataka, India.
2. Tutor, Department of Anatomy, SIMS, Shimoga, karnataka, India.

### NAME, ADDRESS, E-MAIL ID OF THE CORRESPONDING AUTHOR:

Dr. Kavitha Kamath. B,  
Assistant Professor, Department of Anatomy,  
Shimoga Institute of Medical Sciences, Shimoga-577201, Karnataka, India.  
Phone : 9739463168, E-mail : [drkavithakamath@rediffmail.com](mailto:drkavithakamath@rediffmail.com)

FINANCIAL OR OTHER COMPETING INTERESTS: None.

Date of Submission: **Mar 19, 2014**

Date of Peer Review: **Jul 01, 2014**

Date of Acceptance: **Jul 23, 2014**

Date of Publishing: **Sep 20, 2014**