

Warthin's Tumour: A Case Report and Review on Pathogenesis and its Histological Subtypes

RAGHU A R¹, SHWETA REHANI², KUNDENDU ARYA BISHEN³, SHITALKUMAR SAGARI⁴

ABSTRACT

Warthin's tumour/ Papillary cystadenoma lymphomatosum (PCL) constitutes a minority of salivary gland neoplasms and it is a monomorphic adenoma which primarily involves the parotid gland. Warthin's tumour shows multiple cysts that have numerous papillations covered by bilayered columnar and basaloid oncocytic epithelium. The connective tissue portion shows proliferation of follicle-containing lymphoid tissue which necessitates careful distinction for diagnosis. Although, Warthin's tumour presents as a clinically benign, slow-growing, usually asymptomatic lesion with low rates of recurrences and malignant transformation, but still this tumour is considered unique because of its histological appearance and unknown origin and pathogenesis. Here, we report a case of Warthin's tumour of five years duration in a 50-year-old male patient in the right parotid gland and also review and discuss various concepts concerning the development of this tumour along with a comprehensive literature on its clinic-pathologic features.

Keywords: Development, Histogenesis, Warthin's tumor

CASE REPORT

A 50-year-old male patient attended the outpatient unit of Manipal college of dental sciences (MCODS), Manipal, India, presenting with a painless swelling on the right lower side of the face since five years. It was insidious in onset and gradually increased to its present size. There was no history of pain, bleeding, trismus, parathesia or discharge from swelling during the course of enlargement, history of fever or altered salivary flow. His medical history was noncontributory with the exception of being a heavy smoker for the last 10yrs. Patient's family history was negative regarding similar complaints.

Extra-oral examination revealed a large, localized roughly oval swelling in the right preauricular region measuring about 3.2 X 3.5 cm of normal temperature. The overlying skin appeared normal with no evidence of scar, sinus, discoloration or punctum. On palpation, the swelling was soft and fluctuant in anterior region while slightly hard post-auricularly. Skin over the swelling was mobile and pinchable. The right ear lobe was slightly raised and lymph nodes were not palpable.

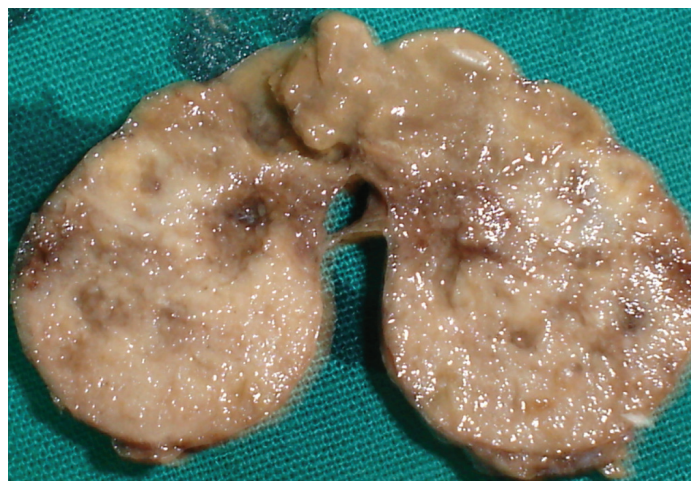
Intra-oral examination revealed that the swelling extended anteroposteriorly from retromolar area to lateral faucial pillars and inferiorly it extended 2-3 cm below the lower border of mandible. There was no obliteration of buccal sulcus superiorly or inferiorly. The swelling was non tender and orifices of the parotid gland appeared to be normal. Stimulation of the parotid gland yielded normal salivary flow with normal consistency, quantity and colour. Other intra-oral findings were non-contributory.

Based on the history and clinical examination, a provisional diagnosis of benign tumour, of salivary gland origin, was made. Patient was investigated accordingly. The panoramic radiograph revealed no abnormality. Due to poor economic status patient was not willing for scintigraphy, hence Ultrasonography was done. Ultrasonographic findings revealed a heterogeneous lesion in the right parotid with more of hypoechoic areas measuring 2.77 x 2.64 x 2.07 cm and few anechoic areas, suggestive of necrosis. There was no echochity of calcification in the lesion and an increased vascularity within mass was noted. The lesion was well defined with adjacent normal parenchyma tissue surrounding it. This investigation confirmed the location of the swelling arising within the parotid gland as well as its encapsulated nature. Computed tomography revealed

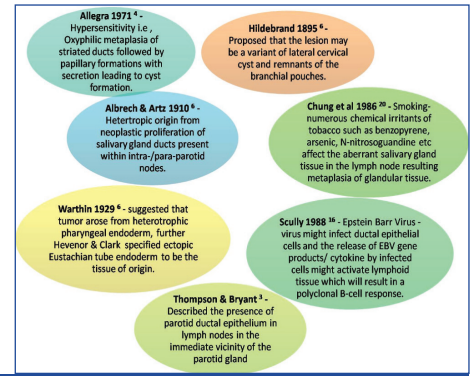
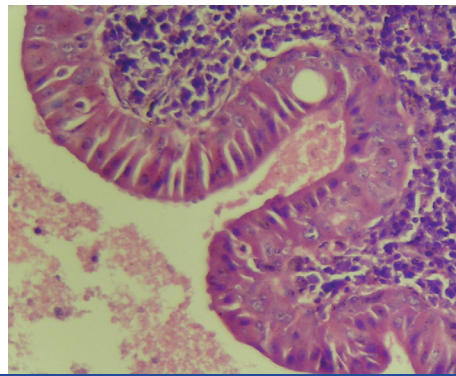
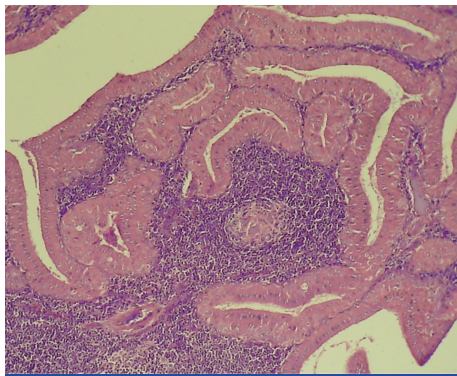
an enhancing mass of 26x26mm in superior lobe of right parotid with no sign of calcification. Thus, the final impression was that of a benign hyper vascular lesion of right parotid gland, probably Pleomorphic adenoma.

Fine needle aspiration cytology (FNAC) and biopsy was advised for further evaluation. The aspirate yielded a whitish material and the smear studied showed monolayered sheets of oncocytic cells with round nuclei and moderate cytoplasm. Background showed sheets of lymphocytes and granular debris. The microscopic features suggested the possibility of Warthin's tumour. Finally, under all aseptic conditions, the mass was excised using a lazy-S incision in the preauricular region and the specimen was sent for histopathological examination to confirm the diagnosis. The patient recovery was uneventful and there was no recurrence at one year followup.

The gross examination of the excised mass revealed a creamish brown to dark brown in colour, spherical to ovoid mass measuring 3.2 x 2.5 cm in diameter. The mass was encapsulated, lobular and fluctuant at one pole while for most of the remaining part it was firm. The cut surface showed few cystic areas with exudation of clear,



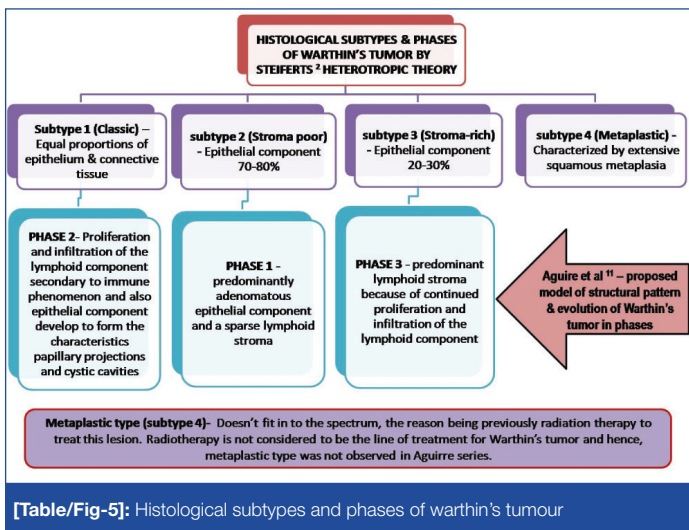
[Table/Fig-1]: Cut section reveals soft with a well defined capsule having cystic space filled with chocolate coloured fluid at places



[Table/Fig-2]: Photomicrograph reveals numerous papillary elements lining cystic spaces in a lymphoid stroma (x100; H& E)

[Table/Fig-3]: Photomicrograph reveals double layered epithelial lining with inner oncocyctic columnar layer and outer cuboidal cells abutting the basement membrane (x400; H& E)

[Table/Fig-4]: Summary of different theories of warthin's tumour according to various authors



[Table/Fig-5]: Histological subtypes and phases of warthin's tumour

mucoid material and intercystic areas were solid and grayish white in color with areas of focal hemorrhage [Table/Fig-1].

The microscopic examination revealed an encapsulated mass enclosing numerous irregular cystic spaces lined by bilayered oncocyctic epithelium growing in the cystic spaces as papillary projections [Table/Fig-2]. The lining epithelium at places showed squamous and mucous metaplasia. The underlying stroma separating the lining epithelium is typically a lymphoid matrix with germinal centers [Table/Fig-3]. The above features confirmed the diagnosis of the lesion as Warthin's tumour.

DISCUSSION

Warthin's tumour, also known as Papillary cystadenoma lymphomatosum (PCL), is the second most frequent benign salivary gland neoplasm and represents 10-15 % of the total. It is almost exclusively limited to the parotid gland and its extra-parotid locations are considered to be very rare. There is an apparent male predilection for its occurrence, although with the recent reports the difference in ratio is declining [1].

Histologically, it is a well-defined entity with dual component, oncocyctic epithelium and lymphoid stroma. Based on the relative amount of these components, it is divided into different histological subtypes, with the possible implication to the pathogenic development/evolution to the lesion [2]. Although, numerous theories concerning histogenesis of this tumour are mentioned in the literature, still its origin is unknown [3,4]. This interesting tumour is the only benign neoplasm of salivary glands associated with the smoking [5].

History: It is a well known fact that Warthin's tumour is a relatively rare and generally benign salivary gland neoplasm. It was first reported by

Hildebrand in 1895 as a form of lateral cervical cyst variant. Albrecht and Artz, in 1910, termed this tumour as papillary cystadenoma. In 1929, Aldred Scott Warthin's published two additional cases and called it as Papillary cystadenoma lymphomatosum (PCL). The term 'Warthin's tumour' was first applied in 1944 by Martin and Ehrlich in respect to Warthin's and since then the term 'Warthin's tumour' has been extensively used. The alternative term for this lesion is adenolymphoma, however, this should not be promoted as it overemphasizes the lymphoid component and the lesion may be mistaken as a type of lymphoma [6, 7].

Clinical Features : Warthin's tumour mainly arises in parotid salivary glands. Before 1982, it comprised only 6-16% of all parotid tumours but incidence rate has been doubled in the past years due to smoking. It has also been described in other extremely uncommon sites, including submaxillary or sublingual or minor salivary glands, larynx, cervical lymph nodes, nasopharynx [8]. Warthin's tumour has highest incidence in the early 60's and occasionally occurs in young patients. In men, the peak incidence is in the 7th decade whereas it is 6th decade in women [9]. In our case the patient was a male aged 50yrs.

Initially, most studies showed a definitive male predilection but there is a progressive change in the sex distribution. Some early studies demonstrated male-to-female ratio up to 10:1 while later studies the difference has been on decline and reached up to 1:1. This tumour has been associated with cigarette smoking and increased prevalence of smoking in female over the past few decades explains this change in the sex ratio [9-11]. The present case also showed history of smoking since 25yrs.

Clinically, the tumour presents as a nodular painless, slow growing, firm to fluctuant at palpation. It can be unilateral, bilateral or multicentric and is asymptomatic in 90% of cases [10,12,13]. The patient in our case reported a slow growing tumour of five year duration. Thus, all the features described in above case are typical of Warthin's tumour.

Pathogenesis: The histogenesis of Warthin's tumour has been the subject of controversy since its earliest description. Numerous theories have been proposed with each having different interpretations. Initially Hildebrand proposed that the lesion may be a variant of lateral cervical cyst and remnants of the branchial pouches. Later Albrecht and Artz proposed its heterotropic origin from neoplastic proliferation of salivary gland ducts present within intra-/ para-parotid nodes [6] [Table/Fig-4]. This theory is widely accepted and was supported by immunohistochemistry (IHC) finding which showed that luminal and basal epithelial cells of Warthin's tumour posses characteristics similar to those of the striated duct cells and basal cells of the excretory duct of salivary gland [14].

Warthin [6] in 1929 had suggested that PCL arose from heterotropic pharyngeal endoderm when he introduced the lesion in American

literature. He was supported by Hevenor and Clark who specified ectopic Eustachian tube endoderm to be the tissue of origin. Orbital inclusions, heterotopic oncocytes, sebaceous glands, hypertrophic lymph node endothelium, and thymic anlage have been included in other theories of histogenesis [6].

An embryology based study of PCL was conducted by Thompson and Bryant [3] and they described the presence of parotid ductal epithelium in lymph nodes in the immediate vicinity of the parotid gland. They also described tumours which showed no evidence of lymph node architecture but typical epithelial elements were present. They suggested a second theory that involved neoplastic proliferation of the parotid ductal epithelium and concomitant secondary formation of lymphoid tissue [Table/Fig-4]. Ellis et al., [6] showed by histochemical investigations that PCL most likely arose from salivary ducts in lymphoid stroma. Although there are several evidences which support the enclaved ductal epithelium theory, other theories regarding a reactive histogenesis cannot be ruled out. The absence of lymph node architecture and a high frequency of bilateral occurrence support a reactive pathogenesis, which involve the accompanying inflammatory process and secondary neoplastic proliferation.

Allegra [4] proposed hypersensitivity as the main cause of Warthin's tumour histogenesis. The cascade of the event as suggested by him was: oxyphilic metaplasia of striated ducts followed by papillary formations with secretion leading to cyst formation. Then basophils and histocytes infiltrate the basement membrane and eventuate in a complete delayed hypersensitivity reaction and formation of a lymphoid stroma [6]. Folusham et al., supported this concept by IHC investigation which showed distribution of immunoglobulin-A (IgA) and IgG similar that seen in autoimmune thyroiditis and also the presence of Langerhans cells. However, the highly organized structure of the lymphoid component, predominantly of IgA producing cells and lack of circulating auto-antibodies were factors against this theory [15] [Table/Fig-4].

Earlier authors suggested that Epstein Barr Virus (EBV) may play an important role in the pathogenesis of Warthin's tumour, especially in multiple and bilateral cases. This virus might infect ductal epithelial cells and the release of EBV gene products/ cytokine by infected cells might activate lymphoid tissue which will result in a polyclonal B-cell response [16,17]. However, some studies have not substantially found any association of the EBV-DNA in tumour cells [18].

The association between smoking and Warthin's tumour has been reported since 1980's [19]. Numerous studies have compared and reported that smoking habit has four- to-eight fold greater risk of Warthin's tumour than do non-smokers [5]. Further, in a study done in Asian population, this risk was 40 times higher when compared with non-smokers [20]. The pathogenesis may relate to the fact that numerous chemical irritants of tobacco such as benzopyrene, arsenic, N-nitrosoguanidine etc affect the aberrant salivary gland tissue in the lymph node [Table/Fig-4]. This result in metaplasia of the glandular tissue and secondary tumour changes occurs which is a lengthy phenomenon which would explain why tumours occur later in life [21]. In our case, the patient gave a long history of cigarette smoking. Studies conducted among atomic survivors suggest that radiation may also be implicated in the development of this tumour [22].

Up to now no agreement has been reached regarding the pathogenesis of this disease. The theory involving development from heterotropic tissue in a lymph node is the most substantiated pathogenesis and has stood the test of time. This theory, however, does not explain when aberrant salivary gland tissue develops in the embryo/infants, why Warthin's tumour does not occur until middle/old age [6]. The aberrant salivary gland tissues in the lymph node of parotid glands are the basis for the tumorigenesis and probably smoking may act as a promoter.

In accordance with the heterotropic theory, Steifert G [2] analysed 275 cases of Warthin's tumour and classified histologically them into four different subtypes depending upon the relative proportions of epithelium to connective tissue [Table/Fig-5]. Aguire et al., [11] proposed a new model of structural pattern and evolution of Warthin's tumour in several phases and subtypes.

Thus, Warthin's tumour may consist of epithelial component as the fundamental neoplastic element and number of factors like tobacco/virus/any other stimulus triggers epithelial proliferations.

One of the most consistent histologic characteristic of this tumour is its abundant lymphoid stroma, the origin of which has also been the subject of much debate in the past. It is unclear whether the lymphoid tissue is reactive or neoplastic response. Some authors consider that the lymphoid component with typical germinal centers represents previously residual lymph node tissue, may result from a response to the epithelial cells which has got entrapped there; so called- heterotropic theory [9,23]. This theory may provide an explanation for the appearance of Warthin's tumour in location in which lymph nodes were not commonly found. Others think that it is an adenoma with lymphocytic infiltration [3,8]. Although there are several evidence which support the heterotropic theory, others theories regarding a reactive histogenesis can't be ruled out. The absence of lymph node architecture and high frequency of bilateral appearance supports a reactive histogenesis, which involve the accompanying inflammatory process and secondary neoplastic proliferation [6].

Whether this lesion is a true neoplasm or not???

This is one more field on which argument is persistent. The clinical behaviour of the lesion as the total lack of recurrence and low malignant transformation rate of this tumour further supports this view. In fact only one study has shown clonal abnormalities, while most have not. Recent immunohistochemical and molecular studies showed no clonal allelic losses suggesting that Warthin's tumour is a non-neoplastic lesion [24,25].

Treatment and prognosis

The majority of Warthin's tumours is benign and rarely invades the surrounding tissue. The salivary gland usually retains its normal function and demonstrates only occasional inflammation. Thus, the salivary gland tissue need not be removed completely. Optimal treatment of Warthin's tumour is surgical removal which can be easily performed due to the superficial location of the tumour. Some surgeons prefer local resection with surrounding tissue; others chose the superficial parotidectomy in order to avoid the rupture of tumour capsule [12]. Bastakis has regarded Warthin's tumour as among the most innocuous of salivary gland tumour [26].

In summary, major salivary gland Warthin's tumour presents as a slow growing, painless mass without significant clinical symptoms. Histopathologic findings suggest lymphoid stroma entrapment of the salivary component as a possible mechanism for its histogenesis. Though, Warthin's tumour is common lesion, more number of incidences will help dentist and even general physicians to be familiar with its histopathology and consequently understanding its histogenesis.

CONCLUSION

The current report presents the case of painless swelling of parotid gland in a 50-year-old smoker. The tumour had slowly and asymptotically grown in five years duration and was situated in characteristic area of Warthin's tumour. History, clinical examination and other investigations were suggestive of benign salivary gland lesion. The final diagnosis was achieved only after the cytological and histopathological examinations guiding us the treatment plan. Though the lesion is common, a more number of incidences will help dentist and even general physicians to understand the pathology of Warthin's tumour.

REFERENCES

- [1] Fanatasia JE, Miller AS. Papillary cystadenoma lymphomatosum arising in minor salivary glands. *Oral Surgery Oral Medicine Oral Pathology*. 1981;52:411-16.
- [2] Seifert G, Bull HG, Donath K. Histologic subclassification of the cystadenoma of the parotid gland: analysis of 275 cases. *Virchows Archive (Pathology Anatomy)*. 1980;388:13-38.
- [3] Thompson AS, Bryant HC Jr. Histogenesis of papillary cystadenoma lymphomatosum (Warthin's tumour) of the parotid gland. *American Journal of Pathology*. 1950;26:807-49.
- [4] Allegra SR. Warthin's Tumour: a hypersensitivity disease? Ultrastructural, light and immunofluorescent study. *Human Pathology*. 1971;2:403-20.
- [5] Kotwall CA. Smoking as an etiologic factor in the development of Warthin's tumour of the parotid gland. *American Journal of Surgery*. 1992;164:646-47.
- [6] Ellis GL, Auclair PL. Surgical Pathology of salivary glands Philadelphia: W.B. Saunders Company Ltd., 1991: p 187-201.
- [7] Neville BW, Damm DD, Allen CM, Bouquot JE. Oral and Maxillofacial Pathology. 2nd ed. Elsevier, New Delhi: 2002:344-46.
- [8] Chapnik J. The controversy of Warthin's tumour. *Laryngoscope*. 1983;93:695-716.
- [9] Eveson J, Cawson R. Warthin's's tumour (cystadenolymphoma) of salivary glands. A clinicopathologic investigation of 278 cases. *Oral Surgery Oral Medicine Oral Pathology*. 1986;61:256-52.
- [10] Lamela J, Terry JH, Alfonso AE. Warthin's's tumour: multicentricity and increasing incidence in women. *American Journal of Surgery*. 1987;154: 347-51.
- [11] Aguirre JM, Echebarria MA, Martinez-Conde R, Rodriguez C, Burgos JJ, Riveria Jm. Warthin's tumour. A new hypothesis concerning its development. *Oral Surgery Oral Medicine Oral Pathology*. 1998;85:60-63.
- [12] Barners L, Eveson JW, Reichart P, Sidransky D. World health organization classification of tumours. Pathology and genetics, head and neck tumours. IARC. Press, Lyon, 2005:209-81.
- [13] Maiorana E, Lo Muzio L, Favia G, Piattelli A. Warthin's's tumour: a study of 78 cases with emphasis on bilaterality, multifocality and association with other malignancies. *Oral Oncology*. 2002;38(1):35-40.
- [14] Segami N, Fukuda M, Manabe T. Immunohistochemical study of the epithelial component of Warthin's's tumour. *International Journal Oral Maxillofacial Surgery*. 1989;18:133-37.
- [15] Foulsham CKb, Synder CG, Carpenter RJ. Papillary cystadenoma lymphomatosum of the larynx. *Otolaryngology- Head Neck Surgery*. 1981;89: 960-64.
- [16] Scully C. Viruses and salivary gland disease: are there any associations? *Oral Surgery Oral Medicine Oral Pathology*. 1988;66:179-83.
- [17] Santucci M, Gallo O, Calzolari, Bondi R. Detection of Epstein-Barr viral genome in tumour cells of Warthin's tumour's of parotid gland. *American Journal of Clinical Pathology*. 1993;100:662-65.
- [18] Ogata T, Hongfang Y, Kayano T, Hirari K. No significant role of Epstein-Barr virus in the tumorigenesis of Warthin's Tumour. *Journal of Medicine Dental Sciences*. 1997;44(2):45-52.
- [19] Ebbs SR, Webb AJ. Adenolymphoma of the parotid: aetiology, diagnosis and treatment. *British Journal of Surgery*. 1986;73: 627-30.
- [20] Chung YEA, Khoo MLC Heng MKD, Hong GS, Soo KC. Epidemiology of Warthin's's tumour of the parotid gland in an Asian population. *British Journal of Surgery*. 1999;86:661- 64.
- [21] Yu G Y, Liu X B, Li Z L and Peng X. Smoking and the development of Warthin's's Tumour of the parotid gland. *British Journal of Oral and Maxillofacial Surgery*. 1998;36:183-85.
- [22] Saku T, Hiyashi Y, Takahara O, Matsuura H, Tokunga M, Tokuoaka S, et al. Salivary gland tumours among atomic bomb survivors, 1950-1987. *Cancer*. 1997;79(8):1465-775.
- [23] Martinez-Madrigal F, Bosq J, Casiragh O. Major salivary glands. In: Mills S E (eds), histology for pathologists, 3rd edition, Lippincott Williams & Wilkins. 2007:445-73.
- [24] Honda K, Kashima K, Daa T, Yokoyama S, Nakayama I. Clonal Analysis of the epithelial component of Warthin's's tumour. *Hum Pathology*. 2003;31:1377-80.
- [25] Teymoortash A, Werner JA. Tissue that has lost its track: Warthin's's tumour. *Virchows Archive*. 2005;446:585-88.
- [26] Batsakis JG, El-Naggar AK. Warthin's's tumour. *Annals of Otolaryngology and Laryngology*. 1990;99:588-91.

PARTICULARS OF CONTRIBUTORS:

1. Professor, Department of Oral Pathology & Microbiology, Manipal College of Dental Sciences, Manipal, Karnataka, India.
2. Reader, Department of Oral Pathology & Microbiology, Sudha Rustagi College of Dental Sciences and Research Institute, Faridabad, Haryana, India.
3. Reader, Department of Oral Pathology & Microbiology, Jodhpur Dental College, Jodhpur, Rajasthan, India.
4. Senior Lecturer, Department of Oral Pathology & Microbiology, Jodhpur Dental College, Jodhpur, Rajasthan, India.

NAME, ADDRESS, E-MAIL ID OF THE CORRESPONDING AUTHOR:

Dr. Shweta Rehani,
Reader, Department of Oral Pathology & Microbiology, Sudha Rustagi College of Dental Sciences and Research Institute,
Faridabad, Haryana, India.
Phone : 9810192332, E-mail : rehanishweta@gmail.com

FINANCIAL OR OTHER COMPETING INTERESTS: None.

Date of Submission: **Feb 11, 2014**
Date of Peer Review: **Jun 18, 2014**
Date of Acceptance: **Jul 03, 2014**
Date of Publishing: **Sep 20, 2014**