

Falcon Herpesvirus, the Etiologic Agent of Inclusion Body Disease of Falcons

C. J. MARÉ AND D. L. GRAHAM

Departments of Veterinary Microbiology and Veterinary Pathology, Iowa State University, Ames, Iowa 50010

Received for publication 6 February 1973

A viral agent has been isolated from five fatal cases of naturally occurring inclusion body disease in three different falcon species, namely, the prairie falcon (*Falco mexicanus*), the red-headed falcon (*F. chiquera*), and the peregrine falcon (*F. peregrinus*). The virus has been shown to possess the physical, chemical, and biological properties of a herpesvirus and has been used to reproduce inclusion body disease in the prairie falcon, merlin (*F. columbarius*), and American kestrel (*F. sparverius*). A similar disease was also produced with this virus in the great horned owl (*Bubo virginianus*), screech owl (*Otus asio*), and ring-necked turtle dove (*Streptopelia risoria*). Serological comparison of the falcon herpesvirus with other known avian herpesviruses revealed that the virus is antigenically closely related to a pigeon herpesvirus and an owl herpesvirus while differing from the former in host range. No antigenic relationship to infectious laryngotracheitis virus, duck virus enteritis, or Marek's disease virus could be demonstrated.

Herpesviruses have been isolated from several species of wild birds, caged birds, and domestic poultry. A number of these viruses have been shown to cause fatal necrotic hepatitis in their host species. In Germany, a fatal hepatosplenitis of owls is believed to be caused by a herpesvirus (1, 2, 14), and in Great Britain a fatal hepatitis of pigeons is caused by a herpesvirus (3, 4). Duck virus enteritis, in which necrotic hepatitis is observed, has been shown to be caused by a herpesvirus (5), and Pacheco's disease of parrots, also characterized by focal necrotic hepatitis (10, 13), is probably of herpesviral etiology. In all of these diseases intranuclear inclusions are observed in cells adjacent to the liver lesions.

Inclusion body hepatitis in a prairie falcon has recently been described (16). An agent was isolated in chicken embryos from the liver of the falcon, and although the agent was not characterized, it was suggested that it may be a herpesvirus. The name "inclusion body disease of falcons" (IBDF) has subsequently been proposed as a more appropriate name for this disease (D. L. Graham, C. J. Maré, F. P. Ward, and M. C. Peckham, manuscript in press).

This report describes the isolation of a virus from five cases of naturally occurring fatal IBDF in three falcon species, the characterization of the virus as a herpesvirus, the experimental reproduction of IBDF in the prairie

falcon and in two other falcon species, the American kestrel and the merlin, and the serological comparison of the falcon virus with known avian herpesviruses.

MATERIALS AND METHODS

Cell cultures. Primary cultures of chicken embryo fibroblasts (CEF) and duck embryo fibroblasts (DEF) were prepared from 9- to 12-day-old embryos by using conventional methods (15). The cells were grown in Eagle basal medium (EBM) supplemented with 10% heat-inactivated fetal calf serum (FCS) and maintained in the same medium with 2% FCS. (Media and sera were obtained from Grand Island Biological Co., Grand Island, N.Y.). All media contained 100 U of penicillin per ml, 200 µg of streptomycin per ml, and sufficient sodium bicarbonate to maintain a pH of 7.2 to 7.4. All cell cultures were incubated at 37 C and examined daily for cytopathic effects (CPE).

Chicken embryos. The chorioallantoic membranes of 13-day-old chicken embryos obtained from the Veterinary Medical Research Institute, Iowa State University, were inoculated for primary isolation of virus from falcon tissues. All chicken embryos were incubated at 37 C and examined daily to determine embryo deaths. After 5 days of incubation, surviving eggs were chilled, and membranes of both dead and surviving eggs were examined for lesions.

Virus isolation. Tissues from naturally occurring cases of IBDF in three prairie falcons (*Falco mexicanus*), one peregrine falcon (*F. peregrinus*), and one red-headed falcon (*F. chiquera*) were examined for virus. Liver or spleen from the affected birds was

macerated in antibiotic-containing EBM to yield a 10% suspension of tissue. The suspension was centrifuged lightly ($500 \times g/10$ min), and 0.2 ml of the supernatant fluid was used for inoculation of each egg or cell culture tube.

Viruses. The virus used in the characterization studies was the first virus isolated from a dead prairie falcon (*F. mexicanus*) submitted to this laboratory for examination. The virus was designated "falcon herpesvirus (FHV) strain S-18" and has been submitted to the American Type Culture Collection. The other four falcon virus isolates have been serologically compared to the prototype strain S-18 by one-way neutralization, but their physical and chemical characteristics have not been defined.

Prior to physical and chemical characterization or the production of antiserum, FHV strain S-18 was cloned three times by plaque selection to reduce the likelihood of contamination by extraneous virus. The virus was used at the sixth to twelfth serial cell culture passage levels.

The pigeon herpesvirus (PHV) used in these studies was obtained from H. G. Purchase, Regional Poultry Research Laboratory, East Lansing, Michigan, and was the virus isolated and characterized by Cornwell et al. in England (3).

The owl herpesvirus (OHV) was also obtained from H. G. Purchase and was a virus isolated by Herman Schettler of the Ludwig-Maximilian University in Munich, West Germany (14).

The duck virus enteritis (duck plague) virus was the "Holland attenuated duck plague virus" (HAV) originally from J. Jansen, Institute of Infectious Diseases, University of Utrecht, The Netherlands, and was obtained from the National Animal Disease Laboratory, U.S. Department of Agriculture, Ames, Iowa.

The infectious laryngotracheitis (ILT) virus was strain 707 obtained from M. S. Hofstad of the Veterinary Medical Research Institute, Iowa State University, Ames, Iowa.

Experimental animals. The American kestrels used in these experiments were trapped under permit in Iowa. The prairie falcon and merlin were trapped under permit in South Dakota. The other raptors were received as gifts from the Iowa Conservation Commission and other interested parties.

The chickens and turkeys were obtained from the Veterinary Medical Research Institute, and the ring-necked doves from the Genetics Department, Iowa State University.

The dogs, mice, rabbits, guinea-pigs, and pigs were available in the department. With the exception of the mice, all of the mammals were bled for serum prior to virus inoculation and were shown to be free of neutralizing antibodies to FHV.

The chickens, turkeys, and larger raptors were also tested prior to inoculation and were found to be free of FHV antibodies.

Animal inoculation. All of the birds and mammals were inoculated intramuscularly with cell-culture-propagated virus. Birds were invariably inoculated into the breast muscles, and mammals were inoculated into the thigh muscles.

The FHV strain S-18 was inoculated into one

prairie falcon (*F. mexicanus*), three American kestrels (*F. sparverius*), one merlin (*F. columbarius*), three great horned owls (*Bubo virginianus*), one screech owl (*Otus asio*), three ring-necked turtle doves (*Streptopelia risoria*), six Swiss albino mice, two beagle dogs, one pig, two guinea pigs, two rabbits, ten 15-day-old turkey poults, and five day-old chickens. The dosage of virus used ranged from 10^3 to $10^{4.5}$ mean tissue culture infective dose (TCID₅₀) per inoculation.

The PHV was inoculated into one American kestrel, two great horned owls, and three ring-necked turtle doves at a dosage of $10^{4.0}$ TCID₅₀ per inoculation. The OHV was inoculated into two American kestrels, two great horned owls, and three ring-necked turtle doves at a dosage level of $10^{3.5}$ TCID₅₀ per inoculum.

Antisera. The FHV antiserum was prepared against the cloned S-18 strain of the virus by injecting rabbits intravenously with $10^{4.0}$ TCID₅₀ of CEF-propagated virus at weekly intervals. Ten days after the fourth injection the rabbits were bled, and the serum was removed, heat inactivated at 56 C for 30 min, and then stored at -20 C. Antisera to the PHV, OHV, ILT, and HAV were prepared in the same way, except that the ILT antigen was chorioallantoic membrane (CAM)-propagated virus. The antiserum to Marek's disease virus (MDV) was obtained from P. D. Beard, Veterinary Biologics Division, U.S. Department of Agriculture, Ames, Iowa.

Virus titration. Virus titrations were carried out by inoculating 0.2 ml of serial 10-fold dilutions of virus into CEF or DEF cell cultures which were then incubated at 37 C in a stationary position. End points were determined after 10 to 12 days by the appearance of typical CPE. The 50% infective dose was determined by the method of Reed and Muench (12).

For viral cloning, virus was titrated on cells grown in petri dishes and overlaid with a nutrient overlay containing 1% agar. When plaques became visible 5 to 7 days postinoculation, they were removed and propagated in tube cultures. The cloning procedure was performed three times.

Neutralization tests. Tenfold dilutions of virus were mixed with equal volumes of heat-inactivated undiluted test sera and held at 4 C for 18 h after which 0.2 ml of each test mixture was inoculated into each of two DEF cell-culture monolayers. Cultures were examined daily for the readily detectable CPE, and after 10 days the differences in titer between negative control and immune sera were calculated. Antibody titers are expressed as the neutralization index.

Electron microscopy. Infected CEF or DEF cells showing distinct cytopathic effects were scraped from the vessel surfaces and prepared for electron microscope examination by a modification of the method described by Parsons (11). Uninfected control cells were treated in the same way. The cells were compacted by centrifugation at $1,000 \times g$ for 20 min, the supernatant fluid was poured off, and a sterile 20-gauge hypodermic needle was pushed into the compacted cells to pick up a few cells. The cells were then floated off the needle by inserting the needle point into a 2% solution of potassium phosphotungstate (pH 6.0) containing 0.01% bovine serum albumin to which had been added 88-nm Latex spheres to serve as size

markers. Formvar-coated copper grids were floated onto the surface to pick up the cells. The specimens were then dried and examined.

Liver lesions were taken from experimentally infected American kestrels immediately after death, fixed in 2% glutaraldehyde, postfixed in 1% osmium tetroxide, embedded in Epon 812 resin, sectioned on a LKB ultramicrotome, and stained with lead citrate and uranyl acetate prior to examination.

All electron microscope examinations were made on a Hitachi 11A electron microscope.

Staining procedures. Selected tissue blocks fixed in buffered Formalin were sectioned at 6 μm and stained with hematoxylin and eosin. Infected cell culture monolayers grown on cover slips in Leighton tubes were fixed in Bouins fluid and then stained with Lendrum's inclusion body stain (7). All photomicrographs were taken on a Zeiss Photomicroscope.

Chemical characterization. The ether sensitivity of the virus was determined by exposing a virus suspension containing 10^4 TCID₅₀ per 0.2 ml to diethyl ether. One part of ether was added to four parts of virus, and the mixture was thoroughly shaken, chilled to 4 C, and held for 18 h, after which the ether was removed and residual virus was titrated in CEF tube cultures.

The nucleic acid type of the virus was determined by titration of virus in the presence of the deoxyribonucleic acid inhibitor 5-iodo-2'-deoxyuridine (IDU). The falcon virus S-18 was titrated by inoculation of serial 10-fold dilutions of virus into two sets of CEF tube cultures. After viral adsorption at room temperature of 25 C for 90 min, the cells were washed and refed with EBM maintenance medium containing 0.1 μM IDU per ml. The control titration was refed with medium without IDU. All tubes were examined daily for 10 days when the viral titers were calculated.

The acid sensitivity of the virus was assessed by holding a virus suspension in EBM adjusted to pH 2.8 at 26 C for 2 h, while control virus suspensions at pH 7.4 were held at 4 and 26 C for 2 h. All of the viral suspensions were then titrated in CEF cell cultures.

RESULTS

Isolation of falcon viruses. The first virus (strain S-18) was isolated from a Prairie falcon liver on the CAM of chicken embryos and in CEF cell cultures. Inoculated chicken embryos did not die, but when the CAM of inoculated eggs were examined 5 days postinoculation, distinct edema of the membranes was observed. Subinoculation of membrane suspensions resulted in sporadic embryo mortality and the development of white focal necrotic lesions on the membranes. Touch preparations made from infected membranes and stained with Lendrum's stain were found to contain large acidophilic intranuclear inclusions.

CEF cell cultures inoculated with the liver suspension were examined daily for CPE indicative of viral growth. On the 12th day postinoculation focal rounding of cells was observed.

Serial passage of the virus on CEF and DEF cells resulted in more rapid development of CPE. Small syncytia were observed, and upon microscope examination of stained monolayers these were found to represent multi-nucleated giant cells (Fig. 1). Many cells were found to contain large acidophilic intranuclear inclusions (Fig. 2). After initial adaptation, the FHV strain S-18 was serially propagated in CEF and DEF cell cultures, with CPE usually developing after 2 to 4 days with complete destruction of cell sheets occurring within 4 to 8 days after the first appearance of CPE. The incidence of giant cells was observed to be significantly higher in DEF cells than in CEF cells. Both CAM- and cell-culture-propagated virus were sterility tested by inoculation of blood agar and two different mycoplasma media. No bacterial or mycoplasmal contaminants were detected.

The second falcon virus (strain H-4) was isolated from pooled liver and spleen of a red-headed falcon which died of IBDF. The virus was isolated by CAM inoculation and on DEF cells. The lesions produced by this virus on CAM resembled those produced by S-18, but on DEF cells a more rapid destruction of cells with the production of very large syncytia was observed.

The FHV strain 1A was isolated on CEF cells from the liver of an American kestrel inoculated with liver suspension from the case of IBDF in a prairie falcon described by Ward et al. (16). FHV strain 2A was isolated on CEF cells from the liver of a peregrine falcon with IBDF which was also obtained from F. P. Ward. The fifth FHV isolate, strain H-48, was isolated on CEF cells from the liver of a prairie falcon with IBDF which was submitted from Idaho.

The CPE of FHV strains 1A, 2A, and H-48 on both CEF and DEF cells resembled the CPE produced by S-18.

The lesions observed in the five cases of IBDF from which these viruses were isolated were described by Graham et al. (manuscript in press). The prominent lesions in each case were focal necrosis of the liver and spleen, usually accompanied by necrosis of the bone marrow and intestines.

Falcon virus pathogenicity and host range. The prairie falcon which was inoculated intramuscularly with 10^3 TCID₅₀ of FHV S-18 died on the 6th day postinoculation after a brief period of anorexia and depression. Post-mortem examination revealed the characteristic lesions of IBDF which included hepatic, splenic, and bone-marrow necrosis. Microscope examination of stained sections of infected tissues revealed the presence of acidophilic and baso-

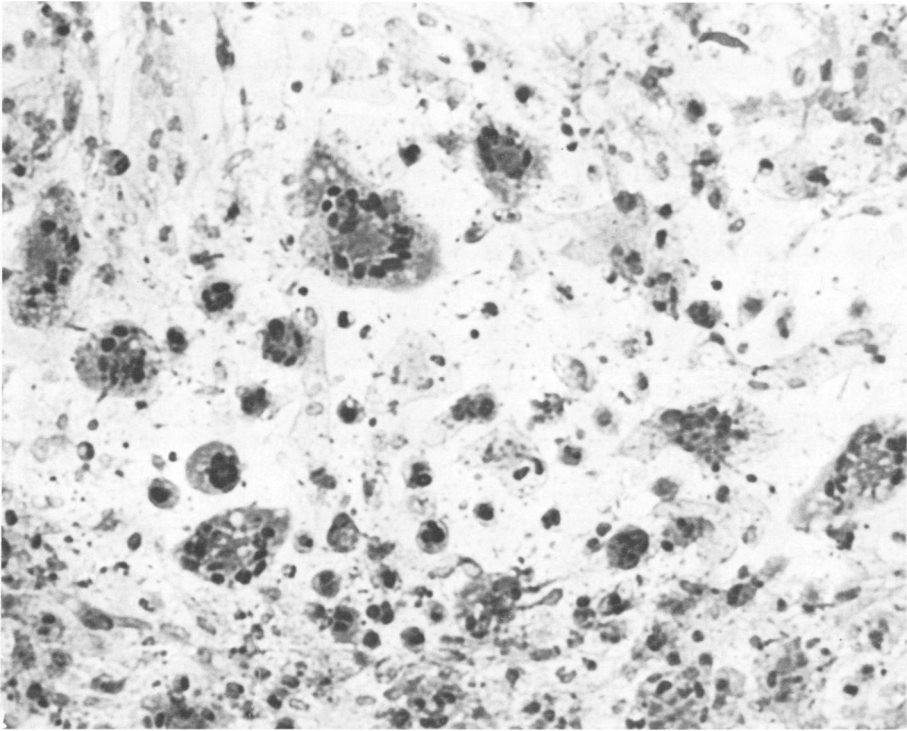


FIG. 1. DEF cells fixed and stained 6 days after infection with FHV S-18. Photomicrograph shows several multinucleated giant cells; Lendrum's stain; magnification, $\times 150$.

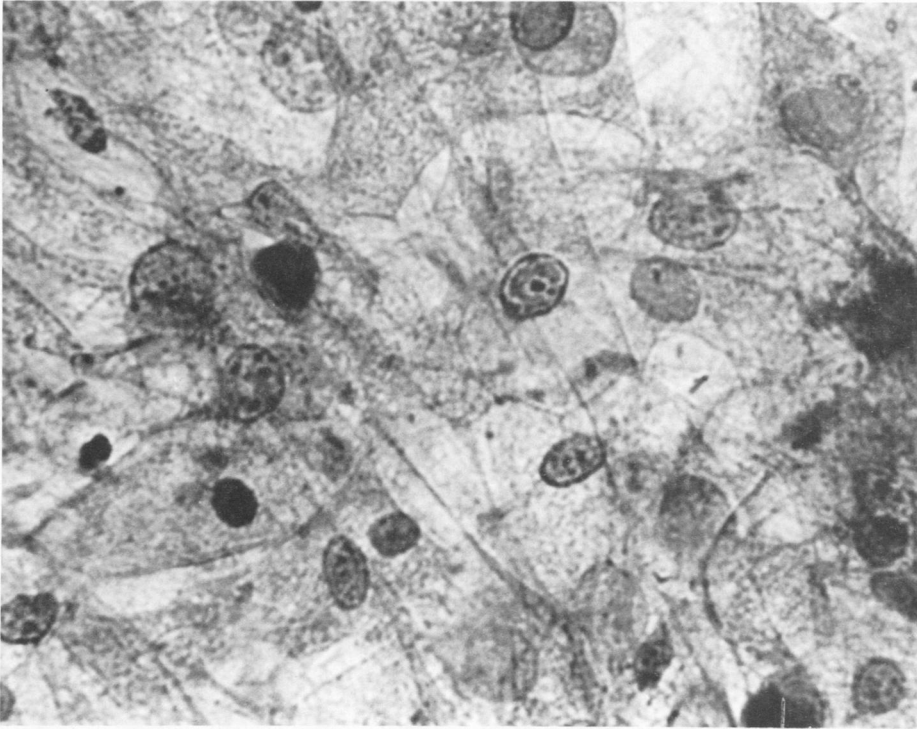


FIG. 2. DEF cells fixed and stained 72 h after inoculation with FHV S-18. Photomicrograph shows cell with large intranuclear inclusion. Lendrum's stain; magnification, $\times 400$.

philic intranuclear inclusions in cells on the periphery of the necrotic foci (Fig. 3). The three American kestrels which received from 10^3 to 10^4 TCID₅₀ of FHV S-18 died suddenly between the 4th and 6th day postinoculation. On post-mortem examination the characteristic lesions of IBDF were again observed. IBDF was also reproduced by the intramuscular inoculation of a merlin with 10^3 TCID₅₀ of the FHV S-18.

Three great horned owls which were inoculated intramuscularly with 10^3 to 10^4 of FHV S-18 died on the 9th and 10th day postinoculation after brief periods of depression and anorexia. Post-mortem examination revealed focal hepatic and splenic necrosis, necrosis of the small intestine, and diffuse necrosis of the bone marrow. Intranuclear inclusions were observed in all of the affected tissues. The screech owl which was inoculated with 10^3 TCID₅₀ of FHV S-18 died suddenly on the 8th day postinoculation. No clinical signs were observed in this bird. At necropsy focal hepatic necrosis was observed, and histological examination revealed the presence of intranuclear inclusions.

The three ring-necked doves were inoculated with $10^{3.5}$ TCID₅₀ of FHV S-18 and died sud-

denly on the 3rd day postinoculation. Focal hepatic necrosis with intranuclear inclusions was observed in each of these birds.

The FHV S-18 was reisolated in cell cultures from the livers of all of the experimental birds which had succumbed after inoculation with the virus.

No disease was observed in the mice, rabbits, guinea pigs, dogs, pig, turkeys, or chickens exposed to the virus. Pre- and postinoculation sera from all the recovered animals, except the mice, were tested and shown to be free of FHV antibodies.

Pathogenicity of pigeon and owl viruses. The PHV did not cause detectable disease in the American kestrel and two great horned owls inoculated with the virus. Serum was not collected from the American kestrel because of its size, but both pre- and postinoculation sera taken from the owls were shown to be free of PHV-neutralizing antibodies. Three ring-necked turtle doves inoculated with PHV died on the 7th day postinoculation. Necropsy revealed focal hepatic and splenic necrosis with occasional intranuclear inclusions near the necrotic foci.

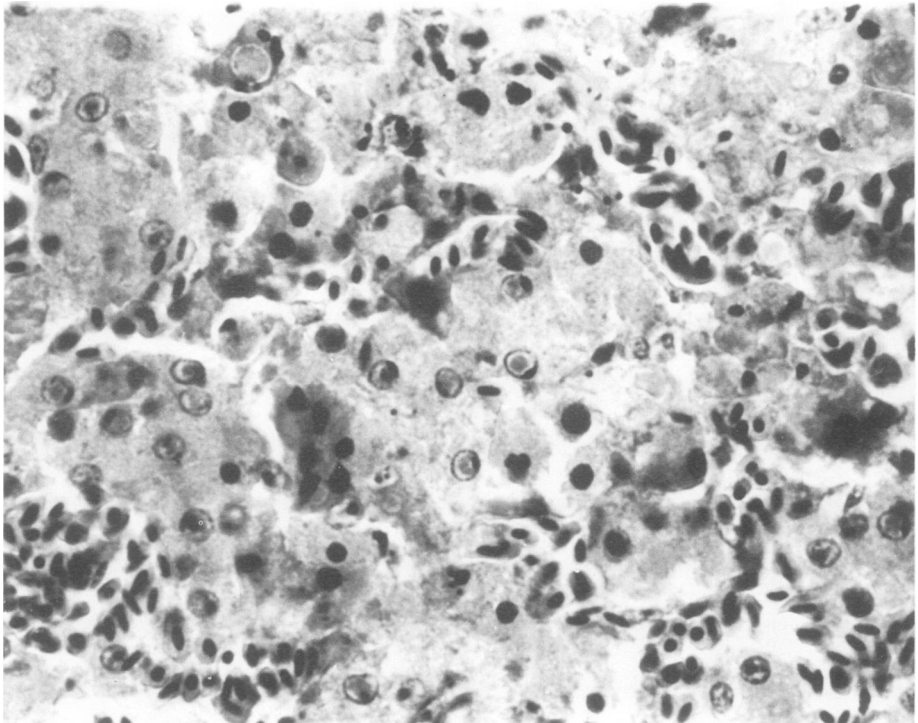


FIG. 3. Section of necrotic lesion in liver of prairie falcon experimentally infected with FHV S-18. Photomicrograph shows several hepatocyte nuclei containing large intranuclear inclusions. Hematoxylin and eosin stain; magnification, $\times 600$.

The two American kestrels, two great horned owls, and three ring-necked turtle doves inoculated with OHV all died between the 3rd and 9th day postinoculation. Focal necrosis of the liver, spleen, and small intestine was observed in all of these birds, and intranuclear inclusions were readily demonstrated.

The comparative pathogenicity of the FHV, PHV, and OHV is summarized in Table 1.

Chemical characteristics. Ether treatment of the FHV resulted in complete inactivation of 10^4 TCID₅₀ per ml of virus.

The presence of IDU in the maintenance medium resulted in a 100-fold reduction in the titer of the virus indicating that the virus is sensitive to the thymidine analogue IDU and is thus a DNA-containing virus.

Exposure of the virus to pH 2.8 for 2 h resulted in complete destruction of infectivity of $10^{3.5}$ TCID₅₀ of virus.

Size. An estimate of the size of FHV was obtained by filtration through membrane filters (Millipore Corp.) of graded pore size. Virus with a titer of $10^{3.5}$ TCID₅₀ was completely retained by membrane filters with 100- and 220-nm pore sizes, but passed through membrane filters of 450-nm pore size with no loss of infectivity.

Electron microscopy. The negatively stained viral preparations were examined electron microscopically to determine the symmetry, morphology, and size of the virus particle. Both enveloped and nonenveloped viruses were observed; the latter were probably products of the preparative technique. The virus was found to consist of an icosahedral nucleocapsid consisting of hollow elongated capsomeres measuring 12 nm in diameter. The resolution of the micrographs did not allow accurate assessment of the capsomere number, but a rough estimate indicated that the nucleocapsid consists of a number of capsomeres approaching the 162 characteristic of herpesviruses. Comparison of the nucleocapsid with the 88-nm Latex markers (Fig. 4) allowed an accurate determination of the nucleocapsid diameter. Nucleocapsid diam-

eter was found to range from 115 to 120 nm. Examination of positively stained thin sections of experimentally produced liver lesions revealed viral particles indistinguishable from other members of the herpesvirus group, such as *Herpesvirus suis* (6), *Herpesvirus hominis* (8), and *Herpesvirus cuniculi* (9). Both incomplete intranuclear particles and complete cytoplasmic virus were observed (Fig. 5). The complete cytoplasmic particles had a rough outer surface and measured 160 to 170 nm in diameter.

Heat stability. Two identical sealed fractions of FHV S-18 were immersed in 4 and 56 C waterbaths. After 15 min, the 56 C sample was moved to the 4 C waterbath, and both samples were titrated on CEF cells. Exposure to 56 C for 15 min resulted in a 2.5-log reduction over the virus held at 4 C which had a titer of $10^{4.5}$ TCID₅₀.

Antigenic interrelationships. Antiserum produced by repeated injections of rabbits with FHV S-18 gave reproducibly high neutralization of the homologous virus in the in vitro serum-virus-neutralization test. This antiserum also neutralized the other falcon herpes isolates H-4, 1A, 2A, and H-48, but not HAV and ILT. In a reciprocal neutralization test the FHV antiserum neutralized both PHV and OHV. The PHV antiserum also neutralized all three viruses, but the OHV antiserum while neutralizing OHV and PHV gave only questionable neutralization of FHV S-18.

High-titer antisera against the avian herpesviruses ILT, MDV, and HAV failed to neutralize FHV S-18.

The neutralization of FHV by antisera to several avian herpesviruses is summarized in Table 2.

DISCUSSION

The agent described in this report possesses the physical, chemical, cytopathic, histological, and electron microscopic characteristics of a virus of the herpesvirus group. It is a deoxyribonucleic acid virus, ether and acid labile, heat sensitive, and possesses the size and distinctive capsid structure of the herpesviruses. The virus induces the formation of type-A intranuclear inclusions in infected cell cultures, and on electron microscopic examination of infected cells the virus is seen to replicate in the nucleus of the cell, apparently acquiring its outer envelope on passing through the nuclear envelope.

The virus is not highly cell associated, as evidenced by the fact that it can be demonstrated in the supernatant fluid of lightly centrifuged preparations. This suggests that the FHV should be considered a herpesvirus of

TABLE 1. Susceptibility of three avian species to FHV, PHV, and OHV

Virus	Avian species		
	Ring-necked turtle dove	Great horned owl	American kestrel
FHV S-18	3/3 ^a	3/3	3/3
PHV	3/3	0/2	0/1
OHV	3/3	2/2	2/2

^a Numerator indicates number of birds which died; denominator indicates number of birds inoculated.

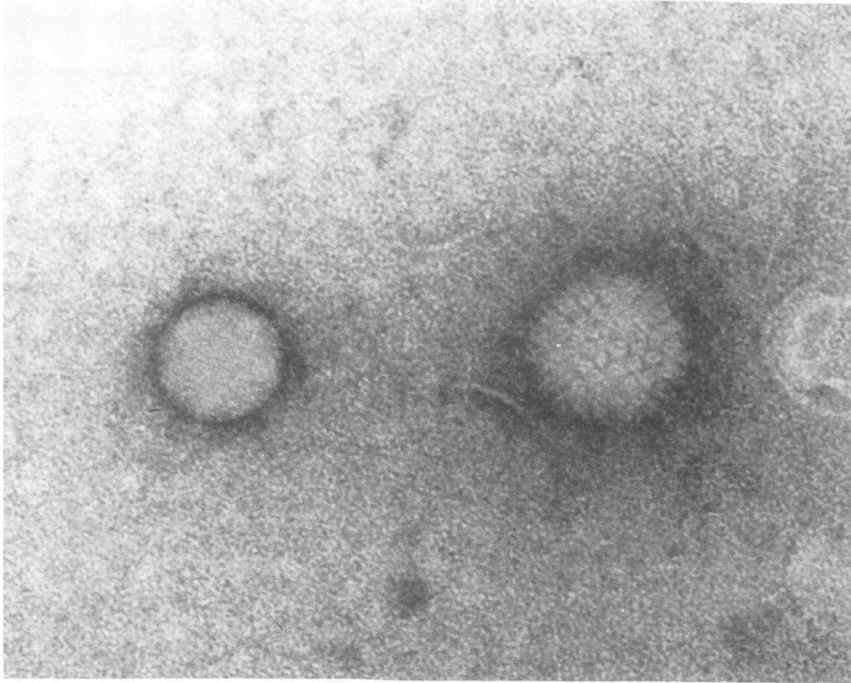


FIG. 4. Electron micrograph of negatively stained virion of FHV S-18 showing hollow capsomeres and vestige of envelope disrupted during preparation. Homogeneous particle is 88-nm Latex marker. Magnification, $\times 210,000$.

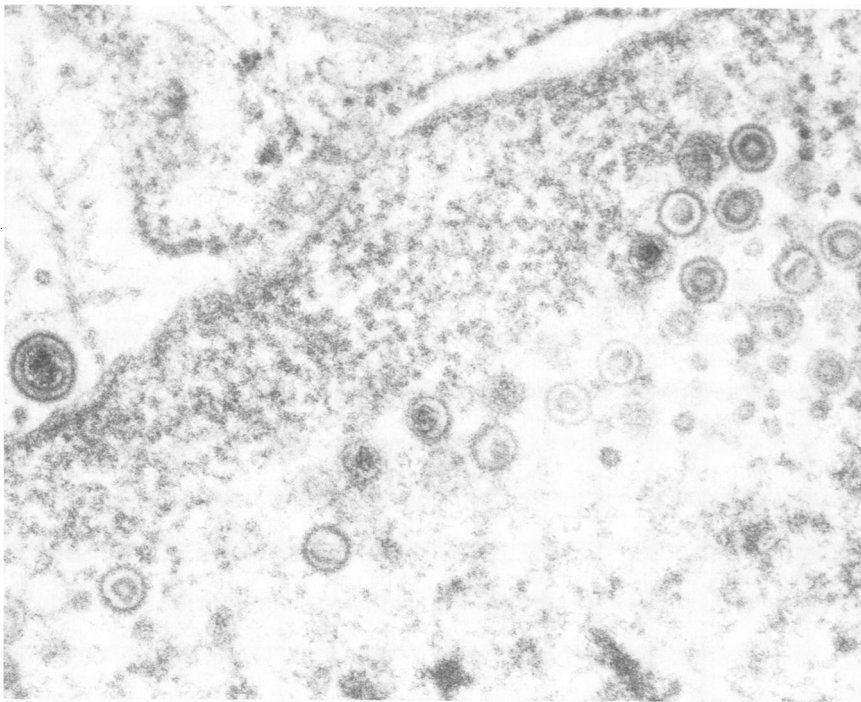


FIG. 5. Hepatic cell nucleus showing numerous nonenveloped virus particles. One enveloped particle can be seen immediately outside of the nuclear envelope. Magnification, $\times 65,000$.

TABLE 2. Neutralization of falcon herpesvirus (FHV) by antisera to avian herpesviruses^a

Antiserum to	Antiserum prepared in	Neutralization against homologous virus	Neutralization of FHV
Falcon herpesvirus S-18	Rabbit	+	+
Owl herpesvirus	Rabbit	+	?
Pigeon herpesvirus	Rabbit	+	+
Infectious laryngotracheitis virus	Rabbit	+	-
Marek's disease virus	Chicken	+	-
Duck virus enteritis (HAV)	Rabbit	+	-

^a Symbols: (+) neutralization index of 100 or more, (?) neutralization index of 50, (-) no neutralization.

subgroup A. However, considerable loss of titer has been observed after centrifugation, suggesting that the degree of cell association between this virus and its host cells should be further explored.

The cell-culture-propagated FHV has been used to reproduce IBDF in its species of origin, the prairie falcon. The virus was subsequently reisolated from the tissues of the bird, thus fulfilling the classic criteria for defining the etiological relationship between an agent and its host species. The virus has also been used to reproduce IBDF in two other falcon species. A similar disease was reproduced in two owl species and in the ring-necked dove, showing that the virus has a potential natural host range extending beyond the members of the genus *Falco* from which it was isolated.

Comparison of FHV S-18 with the other four falcon virus isolates by one-way serum-virus neutralization resulted in neutralization of all four of the other isolates by FHV S-18 antiserum, indicating a close serological relationship between the five viruses. Reciprocal neutralization between the FHV, PHV, and OHV revealed substantial antigenic homogeneity between these viruses also. However, cross neutralization was not complete, indicating that some antigenic heterogeneity may exist. Such differences in antigenic structure could be revealed by kinetic neutralization tests currently planned. Preliminary comparative pathogenicity studies have revealed that the FHV and OHV have a very similar host susceptibility range. The PHV differs from these viruses in that two species of raptors, namely the great horned owl and the American kestrel, both susceptible to FHV and OHV, were refractory to

the PHV. The absence of antibodies in post-inoculation serum from the owls inoculated with PHV implies that virus replication did not occur. It would appear that a combination of antigenic analyses and pathogenicity spectra will be necessary to clearly define the interrelationships between these viruses.

The FHV virus was not neutralized by ILT, MDV, or HAV antisera, nor would the FHV antiserum neutralize ILT or HAV viruses. These findings indicate that FHV is not closely related to the three major herpesviruses of domestic poultry.

The results obtained in this study clearly demonstrate that the causative agent of IBDF is a herpesvirus and that this virus is closely related to two other avian herpesviruses, the PHV and OHV, while differing from ILT, MDV, and HAV.

ACKNOWLEDGMENTS

This investigation was supported by a grant from the Iowa State University Research Foundation.

The technical assistance of Maureen Rohret is gratefully acknowledged.

LITERATURE CITED

- Burtscher, H. 1968. Die virusbedingte Hepatosplenitis infectiosa Strigum. II. Mitteilung: Kultur- und Infektionsversuche. Zentralbl. Veterinärmed. 15:540-554.
- Burtscher, H., and A. Schumacher. 1966. Morphologische Untersuchungen zur Virusätiologie der Hepatosplenitis Infectiosa Strigum. Pathol. Vet. 3:506-528.
- Cornwell, H. J. C., and A. R. Weir. 1970. Herpesvirus infection of pigeons. III. Use of embryonated eggs for the growth and characterization of the virus. J. Comp. Pathol. 80:509-515.
- Cornwell, H. J. C., A. R. Weir, and E. A. C. Follett. 1967. A herpesvirus infection of pigeons. Vet. Rec. 81:267-268.
- Hess, W. R., and A. H. Dardiri. 1968. Some properties of the virus of duck plague. Archiv. Gesamte Virusforsch. 24:148-153.
- Kaplan, A. S., and A. E. Vatter. 1959. A comparison of herpes simplex and pseudorabies viruses. Virology 7:394-407.
- Luna, L. G. 1968. Armed Forces Institute of Pathology Manual of Histologic Staining Methods, 3rd ed, p. 234. Blakiston Division, McGraw-Hill Book Company, New York.
- Morgan, C., S. A. Ellison, H. M. Rose, and D. H. Moore. 1954. Structure and development of viruses as observed in the electron microscope: herpes simplex virus. J. Exp. Med. 100:195-202.
- Nesburn, A. B. 1969. Isolation and characterization of a herpes-like virus from New Zealand albino rabbit kidney cell cultures: a probable re-isolation of virus III of Rivers. J. Virol. 3:59-69.
- Pacheco, G., and C. Bier. 1930. Epizootic chez les pettoquets du Bresil. Relations avec la psittacose. C. R. Soc. Biol. 105:109.
- Parsons, D. F. 1963. Negative staining of thinly spread cells and associated virus. J. Cell Biol. 16:620-626.
- Reed, L. J., and H. Muench. 1938. A simple method of estimating fifty percent end points. Amer. J. Hyg. 27:493-497.
- Rivers, T. M., and F. F. Schwenker. 1932. A virus disease

- of parrots and parakeets differing from psittacosis. *J. Exp. Med.* 55:911-927.
14. Schettler, C. H. 1970. *In vitro* untersuchungen über die Eigenschaften des Virus der Hepatitis et Splenitis Infectiosa Strigum, p. 205-209. *In* Proc. 12th symposium on diseases of zoo animals—Akademie-Verlag, Berlin.
15. Schmidt, N. J. 1964. Chick embryo cell cultures, p. 101-102. *In* E. H. Lennette and N. J. Schmidt (ed.), *Diagnostic procedures for viral and rickettsial diseases*. Amer. Public Health Assoc., Inc., New York.
16. Ward, F. P., D. G. Fairchild, and J. V. Vuicich. 1971. Inclusion body hepatitis in a prairie falcon. *J. Wildl. Dis.* 7:120-124.