

Pathogenesis of Marek's Disease in Old Chickens: Lesion Regression as the Basis for Age-Related Resistance

J. M. SHARMA, R. L. WITTER, AND B. R. BURMESTER

Agricultural Research Station, Regional Poultry Research Laboratory, East Lansing, Michigan 48823

Received for publication 25 June 1973

Chickens of various age levels, free from prior infection, were simultaneously exposed to Marek's disease virus, and the response of each age group was recorded. Four- and 20-week-old chickens of lines 15x7 and CM (commercial source) had substantial resistance to mortality and gross lesions. In contrast, in line 7, which was tested at 1-day, 2-, 4-, 8-, 12- and 16-week age levels, 4-week-old chickens were fully susceptible to clinical Marek's disease (MD), although resistance was demonstrated at 8-week and older age levels. Genetically resistant chickens of line 6 maintained their resistance at all age levels tested. Pathogenesis of MD was compared in 12-week-old and 1-day-old chickens of line 15x7. Within the 1-day-old group, 23% of the chickens died because of MD, whereas there were no deaths in the 12-week-old group. Both groups developed viremia although duration, incidence, and levels of virus in the 1-day-old group were higher than in the 12-week-old group. Although initially the 12-week-old group responded by producing higher levels of antibody, the long term incidence of agar gel precipitin, immunofluorescent, and virus neutralization antibody in the two groups was similar. Gross and microscopic lesions of MD developed in both groups, but lesions regressed in the 12-week-old group and persisted in the 1-day-old group. It was concluded that age resistance to MD was expressed through lesion regression.

Marek's disease (MD), a lymphoid neoplasm of chickens, has recently been shown to be caused by a cell-associated herpesvirus (9, 15, 25). Since herpesviruses are also being implicated in certain human neoplasms (13, 14, 20), Marek's disease virus (MDV) has a special appeal for the field of viral oncology, not only because the discovery of MDV has provided a distinct proof for the oncogenic potentials of the herpesvirus group, but also because the MDV-chicken system can serve as a model for obtaining useful information on related human neoplasms. This model is unique for experimentation because MDV readily induces a rapidly progressing, often fatal, malignant neoplasm in its natural host. Also, under certain conditions, chickens show a high degree of resistance to MD, thus providing a model for studying the phenomenon of resistance to this neoplasm with potential benefits for related systems.

In general, resistance to MD is of three kinds: (i) genetic, (ii) age related, and (iii) vaccine induced. Of these, age-related resistance is perhaps least understood.

First experimental evidence for age-related resistance was provided by Sevoian and Chamberlain (22) and subsequently by Biggs and Payne (3). However, interpretation of some of this earlier work was difficult because the infection status of older chickens before experimental challenge was not clearly established. Freedom from prior infection seems important because epidemiological studies have shown that mild strains of MDV are endemic in most chicken flocks (2, 31) and that these strains can impart protection against subsequent challenge with virulent virus (21, 32). It was only recently that existence of age-related resistance was firmly established by experiments that excluded prior infection of experimental chickens (1, 28, 29).

In another publication, Witter et al. (29) reported that 20- to 22-week-old chickens, free of prior MDV exposure, were refractory to inoculation with up to 10^6 chick tumor-inducing doses of MDV. Since older chickens were susceptible to infection with MDV and had microscopic lesions at termination, we postulated

that their resistance may have been based on lesion regression.

Objectives of this report were: (i) to extend earlier studies and confirm the existence of age-related resistance in various lines of chickens including a genetically resistant line; and (ii) to compare the pathogenesis of MD in old (resistant) and young (susceptible) chickens in order to elucidate the mechanism through which age resistance is mediated.

MATERIALS AND METHODS

MDV. Stocks of cell-associated preparations of the JM strain of MDV were held at -196°C in sealed glass ampoules. The JM-19 clone, isolated by Purchase et al. (19), and uncloned JM virus (30) were propagated and assayed in duck embryo fibroblast (DEF) cultures as previously described (24) and were at the 20th and the 6th serial cell culture passage levels, respectively, at the time of use.

Cell-free virus used in the virus neutralization (VN) test was prepared by inoculating 1-day-old line 100 chickens with the JM-19 clone and processing their feather tips 3 to 4 weeks later according to the procedures outlined earlier (24). Cell-free virus stocks, held at -70°C , were assayed (6, 24) in primary cultures of chicken kidney cells (23).

Chickens. Four strains of Single Comb White Leghorn chickens were used: (i) inbred line 6; (ii) inbred line 7; (iii) a cross between lines 15 and 7, referred to here as line 15x7 (10); and (iv) chickens from a commercial source (Klager's Hatchery, Bridgewater, Mich.), referred to here as line CM (kindly supplied by L. R. Champion, Michigan State Univ.). Day-old chicks of inbred line 6 have been shown to resist clinical MD even upon challenge with massive doses of MDV (22a, 24). Lines 6, 7, and 15x7 are being maintained at this laboratory. Unvaccinated parent stocks of all four lines survived a natural exposure to MDV, hence their progeny was presumed to have maternal MD antibodies at hatching. Chickens were either used at 1 day of age or were maintained until a desirable age in vinyl canopy isolators (26) supplied with filtered air positive pressure (FAPP). Before using chickens from FAPP isolators, tests were done to ensure freedom from inadvertent infection with MDV. To do this, 15% of chickens in each isolator were blood-sampled and tested for viremia and agar gel precipitin (AGP) antibody. In addition, on occasion, 10 to 15% of the chickens were killed and examined for gross and microscopic lesions of MD. Only the groups of chickens that were negative by all tests were considered in the data. In a given experiment, subsequent to virus exposure, chickens of various ages were usually moved to a common, freshly disinfected, concrete-floor pen (13.4 m²) with clean litter. Different age groups in a common pen were physically separated by wire-mesh partitions (29). Chickens dying within 10 days of birth were excluded from the data.

Viremia. Heparinized blood samples were removed either by venipuncture or cardiac puncture. The buffy coat cells, separated by the albumin flotation method

(16), were inoculated in duplicate DEF cell cultures, and foci of infection were scored 10 to 14 days later. Plasma fractions were saved at -20°C for antibody analysis.

Serology. All plasma samples were heat-inactivated for 30 min at 56°C .

The agar gel precipitin test was done according to conventional procedures (8) with slight modifications (24). The indirect immunofluorescent (IF) and IF tests have been described (18, 24). In the AGP and IF tests, antibody titer corresponded to the reciprocal of highest plasma dilution giving a positive reaction. The VN antibody titer was the reciprocal of the highest plasma dilution that reduced the virus titer by at least 50%.

Age resistance in four lines of chickens. Three experiments were conducted. In experiments 1 and 2, predominantly female chickens of lines 15x7 and CM were used. Three age groups, 1-day-, 4-week-, and 20-week-old groups were simultaneously exposed to MDV either by inoculation (experiment 1) or by contact with MDV-infected donors (experiment 2). Each treatment group consisted of 29 to 40 chickens. In experiment 1, each chicken was inoculated intra-abdominally with 4×10^4 plaque-forming units (PFU) of uncloned virus and held for 12 weeks in a floor pen. Based on an earlier observation that older chickens were resistant to up to 10^4 chick tumor-inducing doses of MDV (29), it was assumed that the resistance of older chickens was not dose dependent, hence similar virus dose levels were used for all age levels in a given experiment without making adjustments with respect to body weight of the recipient. In experiment 2, contact exposure was accomplished by forcing the air from an isolator with MDV-infected donor chickens into three adjacent isolators, each with a single age group of recipient chickens. Two-week-old donors consisted of 60 15x7 and 25 line 7 chickens each inoculated at 1 day of age with approximately 1,000 PFU of uncloned MDV. After 3 weeks of forced air exposure, surviving donors were killed and checked for gross lesions of MD. Total incidence of MD based on mortality and gross lesions in donor chickens was 96%. Recipient chickens from three isolators were moved to the floor pen along with the chickens of experiment 1. In each experiment, uninoculated controls, 5 to 8 per age group, were held either in separate vinyl canopy FAPP isolators or in Horsfall-Bauer units (26). Chickens dying 10 days after birth were necropsied, and if gross lesions were absent, sections of vagus nerve, brachial and sciatic plexuses, and gonads were examined histologically. At termination 12 weeks postinoculation (PI), all exposed and unexposed chickens were examined for gross lesions of MD. Statistical analyses were done by the chi-square test.

In experiment 3, six age groups (see Fig. 2) of chickens of lines 6 and 7 were simultaneously inoculated intra-abdominally with 9.5×10^4 PFU of JM-19 clone per chicken and then held in a common floor pen for 13 weeks. Each treatment group consisted of 7 to 12 chickens. Controls of both lines in each age group, 3 to 5 per lot, were held in Horsfall-Bauer units until the end of the experiment. At termination, surviving chickens in each group were blood-sampled and tested for AGP antibody. All chickens that either

died or were killed at termination were necropsied and, if gross lesions were absent, histological sections of nerves and gonads were taken. Microscope examination was not done on control groups.

Pathogenesis of MD in 1-day-old and 12-week-old chickens of line 15x7. Each of 78 1-day-old and 76 12-week-old chickens of lines 15x7 were simultaneously inoculated with approximately 600 PFU of uncloned MDV and housed in a common floor pen. Uninoculated controls consisted of 22 1-day-old and 18 12-week-old 15x7 chickens held in separate FAPP isolators. At 1, 2, 3, 4, 6, 8, 10, 12, 16, and 20 weeks PI, six chickens were randomly selected from each inoculated age group. Random selection was accomplished as follows. Before entering the pen, six wingband numbers were randomly selected from the list of surviving chickens. These chickens with the selected wingbands were then picked out. At 1, 4, 8, 12, and 20 weeks, three control chickens from each age group were also sampled. All sampled chickens were individually tested for viremia, AGP antibody, and gross pathology. At certain time intervals (see Fig. 5 and Table 2), sampled chickens were also assayed for IF and VN antibody. Sections of both vagi, right and left brachial and sciatic plexuses, and gonads were examined by microscope. Microscopic nerve lesions were scored as 1+, 2+, 3+, or 4+ depending upon the intensity of cellular infiltration. A 1+ lesion consisted of a small number of lymphoid cells either diffused through the neurites or aggregated into a focus, whereas in a 4+ lesion, the lymphoid cell infiltration was massive, often resulting in distortion of the structure of the nerve. The scores of 2+ and 3+ represented intermediate stages of involvement. Frequently, various nerves in the same chicken had different lesion scores. In such cases, the highest score was recorded. In a group of chickens, lesion score values were averaged to obtain mean lesion scores.

RESULTS

All through the experiments, uninoculated controls remained free of detectable MD as indicated by the absence of viremia, antibody, or microscopic lesions.

Age-related resistance in four lines of chickens. In experiment 1, in which 15x7 and CM line chickens of 1-day, 4-weeks, and 20-weeks of age were exposed by inoculation, resistance to MD was apparent at 4 weeks of age (Fig. 1a), although results were statistically significant only in line 15x7 ($P < .01$). In both lines, the incidence of MD in 20-week-old chickens was approximately 11% of that in simultaneously exposed 1-day-old chickens. Since the incidence of MD in 1-day-old chickens of line 15x7 was very high (98%), age resistance was more apparent in this line than in line CM, which was found to be relatively resistant to MD.

In contact-exposed groups in experiment 2 (Fig. 1b), incidence of MD in day-old chicks was lower in both lines than in experiment 1.

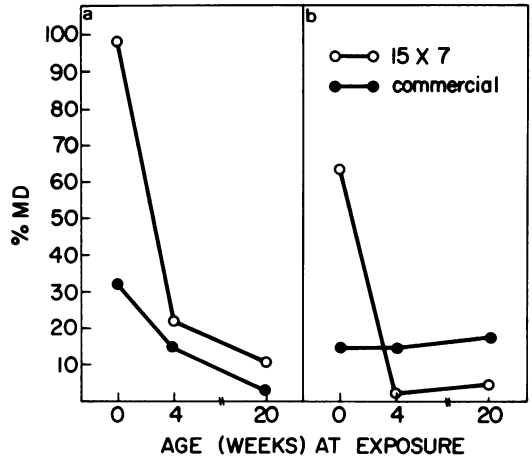

FIG. 1. Relative resistance at different ages of lines 15x7 and CM chickens simultaneously exposed to MDV by inoculation (a) and contact (b) exposure.

Age-related resistance of 15x7 chickens was again well marked. Four-week-old and 20-week-old groups developed an incidence of 3% and 5%, respectively, in contrast with a 63% incidence in 1-day-old groups. Since the incidence of MD in contact-exposed line CM chickens was low in all age groups, resistance of older chickens was not apparent by this exposure route.

In experiment 3, response to MDV inoculation of six different age groups of lines 6 and 7 chickens was studied (Fig. 2a-c). At termination, AGP antibody was demonstrated in all age groups of both lines indicating presence of MDV infection. Line 6 chickens failed to develop mortality or gross lesions at all age levels tested, thus confirming the resistance of this line to inoculation with virulent MDV (24). One of eight 12-week-old line 6 chickens had microscopic nerve lesions consisting of localized infiltration by a homogeneous population of small and medium lymphocytes. Specificity of such mild lesions to MD is questionable because similar lesions may be found sporadically in uninoculated controls (22a). Unlike decreased incidence of MD in 4-week-old chickens of lines 15x7 and CM, in line 7 incidence of mortality and gross lesions was higher in the 4-week-old group than in the 1-day- and 2-week-old groups. There was a marked resistance of 8-, 12- and 16-week-old groups of line 7 to mortality and gross lesions. However, a high incidence of microscopic lesions was present in all age groups (Fig. 2c), thus confirming our earlier observations (29) that age resistance is more pronounced at the level of mortality and gross lymphoma formation than at the level of micro-

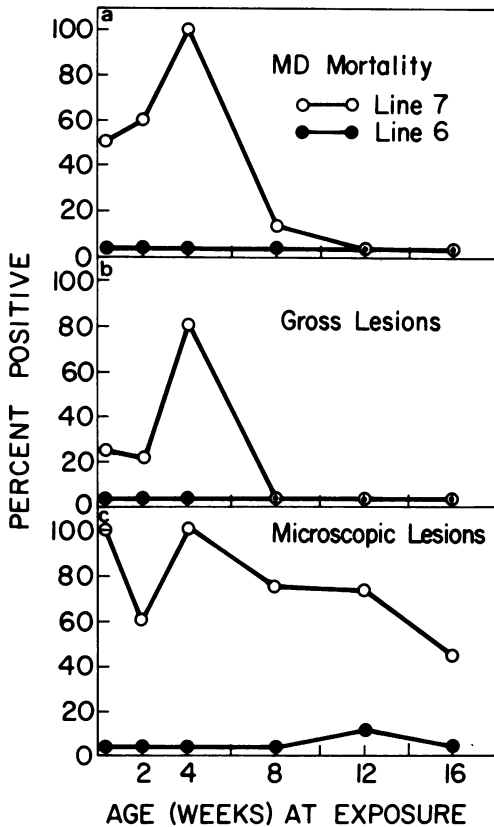


FIG. 2. Relative resistance at different ages of lines 6 and 7 chickens simultaneously inoculated with MDV.

scopic lesions.

Pathogenesis of MD in 1-day-old and 12-week-old chickens of line 15x7. (i) Mortality. Cumulative MD mortality is shown in Fig. 3. In the 1-day-old group, 18 chickens died between the 3rd and 15th weeks PI. There were no MD-specific deaths in the 12-week-old chickens.

(ii) Viremia. In 12-week-old chickens, viremia was detectable at 1 week PI. The incidence of viremia in this group increased until the 3rd week and then declined so that by the 6th week no chickens were viremic (Table 1). In the younger group, although viremia was not detected until the 3rd week of inoculation, the incidence was much higher than in the older chickens and viremia persisted until the 16th week PI. In viremic chickens, levels of virus expressed as numbers of PFU per 10^7 white blood cells was consistently higher in the younger birds than in simultaneously tested older chickens (Table 1).

(iii) AGP antibody. AGP antibody appeared 2 weeks earlier in the older group than in the

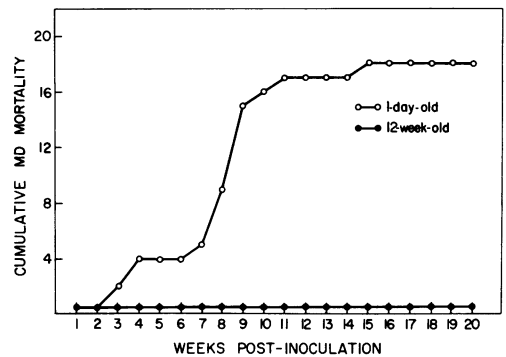


FIG. 3. Cumulative mortality among 78 1-day-old and 76 12-week-old chickens of line 15x7 simultaneously inoculated with MDV. Numbers on the vertical axis refer to actual number of MD-specific deaths.

TABLE 1. Incidence and levels of viremia in 1-day-old and 12-week-old chickens of line 15x7 simultaneously inoculated with MDV

Weeks postinoculation	1-day-old group		12-wk-old group	
	Positive/no. tested	Mean titer (PFU/ 10^7 white blood cells)	No. positive/no. tested	Mean titer (PFU/ 10^7 white blood cells)
1	0/6	0	1/6	1
2	0/6	0	2/6	2
3	6/6	26	4/6	4
4	5/5	26	1/5	12
6	4/6	27	0/6	0
8	5/5	12	0/6	0
10	5/5	3	0/6	0
12	2/5	13	0/6	0
16	2/6	16	0/6	0
20	0/4	0	0/6	0

younger group (Fig. 4). Although this antibody persisted in both groups with a comparable incidence (Fig. 4a), mean titers differed in the two groups (Fig. 4b). In the older chickens, antibody titers reached a sharp peak at 3 weeks PI. This peak subsided, and the levels of antibody in the older chickens sampled after 6 weeks PI were generally quite low. In contrast, mean titers in the younger chickens rose gradually, and at 6 weeks PI and later the titers were higher than in the older group. For unexplainable reasons, in the 1-day-old group, maternal antibody was readily detectable by the VN (Table 2) and IF tests (Fig. 5) but not by the AGP test (Fig. 4).

(iv) IF antibody. All chickens of the 1-day-old group tested at 1 week PI had IF antibody (Fig. 5a). This antibody, apparently passively acquired, disappeared by the 3rd week. Thereafter, the incidence of IF antibody in this group

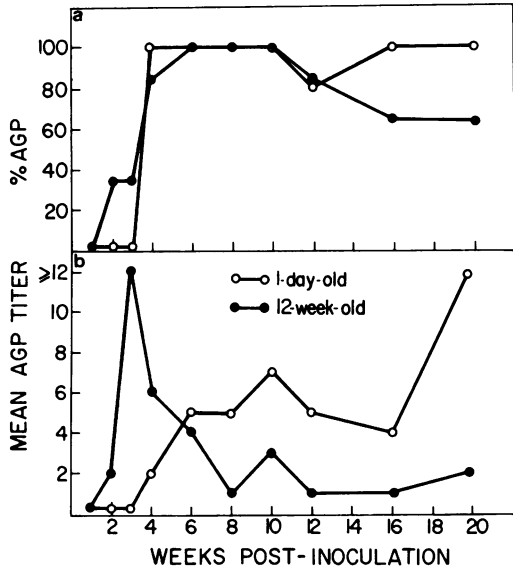


FIG. 4. Incidence (a) and mean titers of positive samples (b) of AGP antibody in 1-day-old and 12-week-old chickens of line 15x7 simultaneously inoculated with MDV.

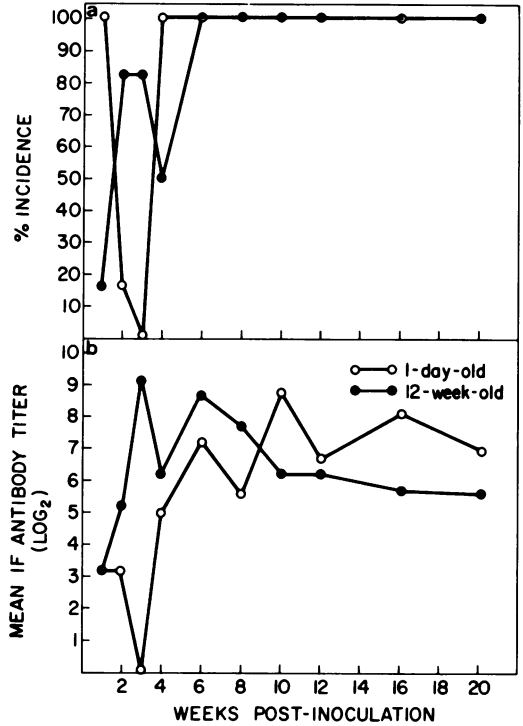


FIG. 5. Incidence (a) and mean titers of positive samples (b) of IF antibody in 1-day-old and 12-week-old chickens of line 15x7 simultaneously inoculated with MDV.

was 100%. In the older chickens, the incidence of IF antibody, first detectable as early as 1 week PI, was also quite high through the entire duration of the experiment. Although initially the older chickens had higher IF antibody titers, once active antibody developed in the younger chickens, the mean titers in the two groups were similar (Fig. 5b).

(v) VN antibody. Results on VN antibody in the two groups of chickens are given in Table 2. Passive antibody in the 1-day-old group persisted until approximately 4 weeks PI. At 6 weeks PI, none of the five younger chickens tested had detectable antibody. Active antibody was demonstrated in one of six birds at 8 weeks. Four of eight chickens examined after 8 weeks had this antibody; two chickens had a titer of $\geq 1:400$. In the older chickens, the incidence of VN antibody was generally quite high. It is noteworthy that active VN antibody could be readily demonstrated in the highly susceptible age group (1-day-old group).

(vi) Pathology. Gross lesions consisting mainly of peripheral nerve enlargements were detected in both age groups at approximately 4 weeks PI (Fig. 6a). Because of the neurotropic nature of the virus strain used, visceral lesions were very rare and were restricted to the gonads. In the younger chickens, gross lesions were detected in 17 to 60% of test chickens through the entire observation period. In the older chickens, after a high incidence of 50% at 4 weeks, the incidence of gross lesions dropped

sharply. All older chickens tested at 8, 12, 16, and 20 weeks lacked detectable gross lesions of MD. Initial appearance and subsequent disappearance suggested that gross lesions may have regressed in the older chickens. As mentioned previously, none of the older chickens died of MD.

The lesion-regression pattern was obvious, especially when the incidence of microscopic lesions in the two age groups was compared (Fig. 6b). In the younger chickens, microscopic lesions became detectable at 3 weeks PI, and at 4 weeks and later, lesions were present in nearly 100% of the chickens examined. In the older chickens, microscopic lesions were present in 60% of the chickens at 1 week PI and the incidence reached over 80% within the next 2 weeks. Thereafter, the percentage of older chickens with microscopic lesions declined steadily, reaching 17% by the 10th week and persisting at a low level thereafter.

The incidence of proliferative nerve lesions was evaluated in both groups (Table 3). Briefly, a proliferative lesion, A-type as described by Payne and Biggs (17), was characterized by the presence of small and medium lymphocytes mixed with blast cells and MD cells (Fig. 7a, b)

TABLE 2. Chronological development of virus-neutralizing antibody in 1-day-old and 12-week-old chickens of line 15x7 simultaneously inoculated with MDV

Weeks post-inoculation	1-day-old group					12-week-old group				
	No. positive/ no. tested	Titer ^a				No. positive/ no. tested	Titer			
		50	100	200	≥400		50	100	200	≥400
2	4/4		4 ^b			4/4	3		1	
4	1/6	1				6/6	5			1
6	0/5					2/3	1	1		
8	1/6	1				3/6	2	1		
12	3/4	1			2	3/4	2	1		
20	1/4		1			1/4				1

^a Reciprocal of highest plasma dilution that reduced the virus titer by at least 50%.

^b Number of chickens with antibody titers indicated.

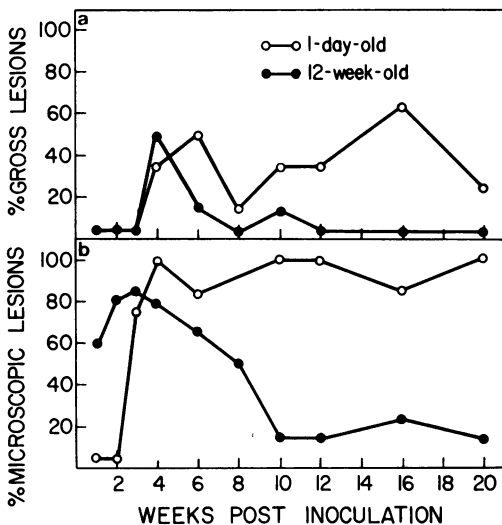


FIG. 6. Incidence of gross (a) and microscopic (b) lesions of MD in 1-day-old and 12-week-old chickens of line 15x7 simultaneously inoculated with MDV.

(17), and plasma cells were rare. In a nonproliferative lesion that responded to B- or C-type lesions of Payne and Biggs (17), small and medium lymphocytes predominated and plasma cells were frequently observed, whereas both blast cells and MD cells were rare (Fig. 8-10). In a given chicken, all sections of nerves were examined, and if both proliferative and nonproliferative areas were present at different sites of the same nerve or in different nerves of the same chicken, the lesion was scored in the category that was most predominant.

In the older chickens, proliferative nerve lesions were observed only through 4 weeks (Table 3). In the older birds, the lesions were initially marked and, in some cases, infiltrating cells more or less completely obliterated the neurites (Table 3, Fig. 7a, b). However, these lesions seemed to subside, and after the 6th week the mean lesion score values were gener-

ally quite low (Table 3). It appeared that a shift from a proliferative to a nonproliferative lesion (Fig. 8, 9) corresponded well with the onset of regression as measured by other criteria (Fig. 6b). In many cases, nonproliferative, presumably regressing lesions consisted of a focal accumulation of lymphoid cells (Fig. 11).

In the younger chickens, proliferative lesions and relatively high mean lesions scores were recorded through the entire observation period (Fig. 12). Several chickens tested after the 8th week had nonproliferative lesions (Table 3; Fig. 10, 13), thus indicating that some lesions in the younger age group may also have regressed.

DISCUSSION

These studies have demonstrated that in chickens of line 15x7, age-related resistance to MD was expressed through lesion regression. Payne and Biggs (17) noted that in a certain proportion of infected chickens, lymph-proliferative lesions in nerves and viscera may regress. Indeed, spontaneous natural recovery from clinical MD presumably accompanied by lesion regression has been observed by others (F. G. Aigster, M.S. thesis, Univ. of Georgia, 1968; R. L. Witter, unpublished data). The factors responsible for recovery from natural or experimentally induced MD have not been investigated, and it is hoped that occurrence of lesion regression in age-related resistance will provide an experimental model for studying such factors.

It has been postulated that early events in MD infection influence the eventual outcome of disease, and there is extensive experimental evidence that in young chickens, presence of passive MD antibody at the time of exposure inhibits or delays the development of clinical disease (5, 8, 11, 12, 27; G. H. Burgoyne and R. L. Witter, submitted for publication). In our studies, chickens of 4 weeks of age or older generally lacked detectable evidence of mater-

TABLE 3. Mean lesion scores and proliferative nerve lesions among chickens diagnosed as positive for MD by histopathological examination

Weeks post-inoculation	1-day-old group			12-week-old group		
	No. of chickens with microscopic nerve lesions ^a	Mean lesion score ^b	No. with proliferative lesions ^c	No. of chickens with microscopic nerve lesions ^a	Mean lesion score ^b	No. with proliferative lesions ^c
1	No lesions	0.0	0	3	1.7	3
2	No lesions	0.0	0	4	2.8	4
3	4	2.0	2	5	3.0	5
4	6	2.8	6	4	3.2	3
6	5	3.0	5	4	2.2	0
8	4	2.5	4	3	1.0	0
10	6	2.3	3	1	1.0	0
12	5	2.2	2	1	1.0	0
16	5	2.2	3	2	1.5	0
20	4	1.8	2	1	2.0	0

^a Four to six chickens were examined at each interval.

^b Microscopic nerve lesions were scored as 1+, 2+, 3+, or 4+ depending upon the intensity of involvement. Numbers in this column represent the mean lesion scores of all chickens in a group.

^c A proliferative lesion was characterized by the presence of blast cells and MD cells.

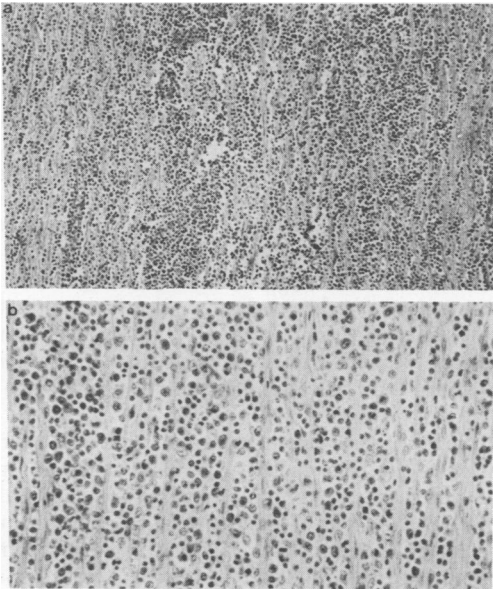


FIG. 7. (a) Massive lymphoid cell infiltration in a peripheral nerve 3 weeks after inoculation with MDV. Line 15x7 chickens inoculated at 12 weeks of age. Hematoxylin and eosin. $\times 148$. (b) Higher magnification of a section of the nerve shown in (a). Note the presence of small and medium lymphocytes mixed with blast cells and MD cells. Hematoxylin and eosin. $\times 350$.

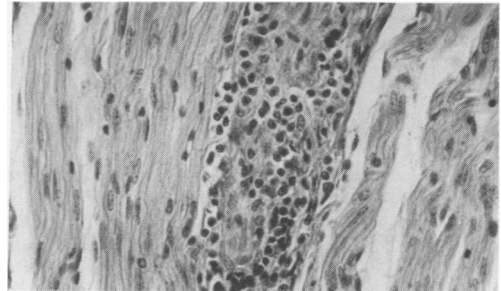


FIG. 8. Nonproliferative lesion in a peripheral nerve 16 weeks after inoculation with MDV. Note scarcity of blast type and MD cells. Line 15x7 chicken inoculated at 12 weeks of age. Hematoxylin and eosin. $\times 592$.

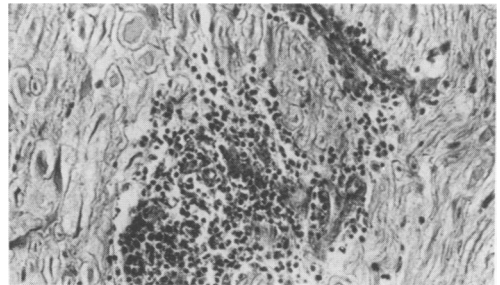


FIG. 9. Nonproliferative lesion in a peripheral nerve 8 weeks after inoculation with MDV. Line 15x7 chicken inoculated at 12 weeks of age. Hematoxylin and eosin. $\times 350$.

nal antibody, hence the observed resistance of older chickens cannot be attributed to the inhibitory effects of pre-existing antibody.

We compared antibody development in the old chickens with that in simultaneously inoculated 1-day-old chicks. Since older chickens were immunologically mature at the time of

infection, they appeared to mount a faster and higher antibody response than did the 1-day-old group. Although the effects of this initial antibody response were not assessed, it was clear

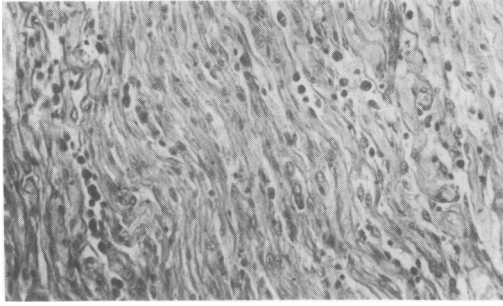


FIG. 10. Nonproliferative lesion in a peripheral nerve 12 weeks after inoculation with MDV. Note presence of plasma cells. Line 15x7 chicken inoculated at 1 day of age. Hematoxylin and eosin. $\times 350$.

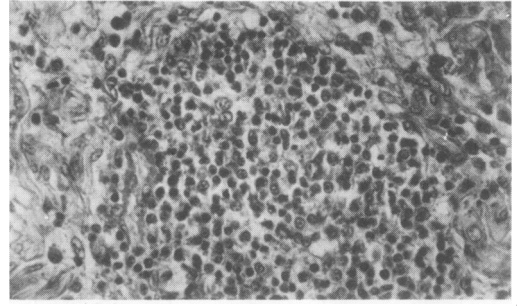


FIG. 13. Nonproliferative lesion in a peripheral nerve 12 weeks after inoculation with MDV. Line 15x7 chicken inoculated at 1 day of age. Hematoxylin and eosin. $\times 592$.

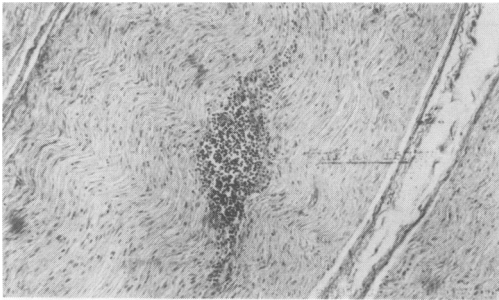


FIG. 11. Nonproliferative lesion in a peripheral nerve 8 weeks after inoculation with MDV. Note focal aggregation of lymphoid cells. Line 15x7 chicken inoculated at 12 weeks of age. Hematoxylin and eosin. $\times 148$.

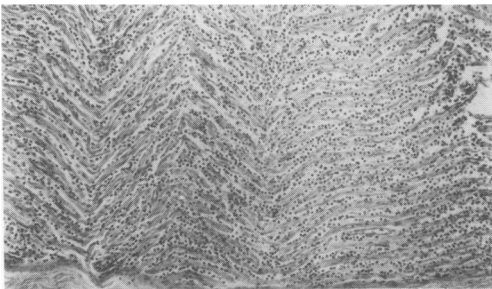


FIG. 12. Massive proliferative lesion in a peripheral nerve 16 weeks after inoculation with MDV. Line 15x7 chicken inoculated at 1 day of age. Hematoxylin and eosin. $\times 148$.

that this active antibody did not prevent the development of proliferative lesions. Overall long-term incidence and titers of AGP, IF, and VN antibodies revealed no striking differences between the two groups to justify anti-viral antibody as the basis for lesion regression. In fact, after an initial elevated antibody response

in the older birds during the first few weeks of infection, AGP and IF antibodies were at a lower level in these birds than in the 1-day-old group. Of interest was the comparable response of VN antibody in the two groups. This antibody has been implicated in genetic resistance to MD. Calnek (4) and subsequently Sharma and Stone (24) found that genetically susceptible chickens that eventually died from MD failed to produce detectable VN antibody as compared with a high incidence of this antibody in genetically resistant chickens. Although the role of VN antibody in genetic resistance is not yet fully settled (22a), our studies indicated that VN antibody was not a major factor in age resistance and consequently in lesion regression. Humoral antibody, perhaps directed against virus-induced tumor antigen(s), and the cellular immune response must be examined to further elucidate the mechanisms involved in age-related resistance to MD.

The low-grade viremia present in 12-week-old chickens in this study was also observed in another study in genetically resistant chickens of line 6 (24). It is of interest that in spite of the similarity in quantities of circulating virus in genetic and age-related resistance, the outcome of cell-virus interactions in the two types of resistance was fundamentally different. In older chickens, virus induced proliferative lesions leading to tumor formation; however, in genetically resistant chickens where proliferative lesions failed to develop (24), virus persisted without apparent harm to the host. The basis for this difference is not known since the conditions under which MDV induces neoplastic transformation of cells are not well understood.

In line 7, chickens exposed at 4 weeks of age had a higher incidence of mortality and gross lymphomas than did simultaneously exposed

1-day-old chickens. The increased susceptibility of 4-week-old chickens apparently corresponded with the disappearance of passive antibody in this line. It was of particular interest that age resistance was well developed at 4 weeks of age in chickens of line 15x7 and was apparent to some extent in chickens of line CM but not in those of line 7. This reflects on the influence of genetic constitution of the chicken on development of age resistance. Further work involving additional genetic stocks of chickens is needed to confirm this observation.

One important facet of this work was to study the effect of age on genetic resistance of line 6 chickens. Since these chickens were equally resistant to clinical MD from 1 day through 16 weeks of age, it could not be determined whether genetic resistance persisted through the entire observation period or whether after an initial protection provided by genetic constitution, age-related resistance became operative. Since 1-day-old chickens of line 6 were fully resistant, it appears that their resistance was expressed independently of age. However, line 6 chickens used in this study had maternal antibody at hatching, and the protective effect of this antibody during early weeks of life may have influenced their response.

ACKNOWLEDGMENTS

We thank Evelyn Young, Karen Juntikka, and Linda Offenbecker for excellent technical assistance.

LITERATURE CITED

- Anderson, D. P., C. S. Eidson, and D. M. Richey. 1971. Age susceptibility of chickens to Marek's disease. *Amer. J. Vet. Res.* **32**:935-938.
- Biggs, P. M., and B. S. Milne. 1972. Biological properties of a number of Marek's disease virus isolates, p. 88-94. *In* P. M. Biggs, G. De-The, and L. N. Payne (ed.), *Oncogenesis and herpesviruses*. IARC Scientific Publication no. 2., Lyon, France.
- Biggs, P. M., and L. N. Payne. 1967. Studies on Marek's disease. I. Experimental transmission. *J. Nat. Cancer Inst.* **39**:267-280.
- Calnek, B. W. 1972. Antibody development in chickens exposed to Marek's disease, p. 129-136. *In* P. M. Biggs, G. De-The, and L. N. Payne (ed.), *Oncogenesis and herpesviruses*. IARC Scientific Publication no. 2., Lyon, France.
- Calnek, B. W. 1972. Effects of passive antibody on early pathogenesis of Marek's disease. *Infect. Immunity* **6**:193-205.
- Calnek, B. W., and H. K. Addinger. 1971. Some characteristics of cell-free preparations of Marek's disease virus. *Avian Dis.* **15**:508-517.
- Chubb, R. C., and A. E. Churchill. 1968. Precipitating antibodies associated with Marek's disease. *Vet. Rec.* **83**:4-7.
- Chubb, R. C., and A. E. Churchill. 1969. The effect of maternal antibody on Marek's disease. *Vet. Rec.* **85**:303-305.
- Churchill, A. E., and P. M. Biggs. 1967. Agent of Marek's disease in tissue culture. *Nature (London)* **215**:528-530.
- Crittenden, L. B. 1968. Avian tumor viruses: prospects for control. *World's Poultry Sci. J.* **24**:18-26.
- Eidson, C. S., D. P. Anderson, and D. D. King. 1971. Resistance of progeny from parental stock of chickens immunized against Marek's disease. *Amer. J. Vet. Res.* **32**:2071-2076.
- Eidson, C. S., S. H. Kleven, J. M. Lacroix, and D. P. Anderson. 1972. Maternal transfer of resistance against development of Marek's disease tumors. *Avian Dis.* **16**:139-152.
- Henle, G., W. Henle, and V. Diehl. 1968. Relation of Burkitt's tumor associated herpes-type virus to infectious mononucleosis. *Proc. Nat. Acad. Sci. U.S.A.* **59**:94-101.
- Henle, W., and G. Henle. 1969. Evidence for a relationship of Epstein-Barr virus to Burkitt's lymphoma and nasopharyngeal carcinoma. *Comp. Leuk. Res. Bibl. Haematol.* **36**:706-713.
- Nazerian, K., J. J. Solomon, R. L. Witter, and B. R. Burmester. 1968. Studies on the etiology of Marek's disease. II. Finding of a herpesvirus in cell culture. *Proc. Soc. Exp. Biol. Med.* **127**:177-182.
- Parker, R. C. 1961. *Method of tissue culture*, 3rd ed., p. 135-137. Harper and Row, New York.
- Payne, L. N., and P. M. Biggs. 1967. Studies on Marek's disease. II. Pathogenesis. *J. Nat. Cancer Inst.* **39**:281-302.
- Purchase, H. G. 1969. Immunofluorescence in the study of Marek's disease. I. Detection of antigen in cell culture and an antigenic comparison of eight isolates. *J. Virol.* **3**:557-563.
- Purchase, H. G., B. R. Burmester, and C. H. Cunningham. 1971. Pathogenicity and antigenicity of clones from strains of Marek's disease virus and the herpesvirus of turkeys. *Infect. Immunity* **3**:295-303.
- Rawls, W. E., W. A. F. Tompkins, M. E. Figueroa, and J. L. Melnick. 1968. Herpesvirus type 2 associated with carcinoma of the cervix. *Science* **161**:1255-1256.
- Rispen, B. H., H. Van Vloten, N. Mastenbroek, H. J. L. Mass, and K. A. Schat. 1972. Control of Marek's disease in the Netherlands. I. Isolation of an avirulent Marek's disease virus (strain CVI988) and its use in laboratory vaccination trials. *Avian Dis.* **16**:108-125.
- Sevoian, M., and D. M. Chamberlain. 1963. Avian lymphomatosis. III. Incidence and manifestations in experimentally infected chickens of various ages. *Avian Dis.* **7**:97-102.
- Sharma, J. M. 1973. Lack of a threshold of genetic resistance to Marek's disease and the incidence of humoral antibody. *Avian Pathol.* **2**:75-90.
- Sharma, J. M., S. G. Kenzy, and A. Rissberger. 1969. Preparation and behavior in chicken kidney cultures of the agent associated with classical Marek's disease. *J. Nat. Cancer Inst.* **43**:907-916.
- Sharma, J. M., and H. A. Stone. 1972. Genetic resistance to Marek's disease. Delineation of the response of genetically resistant chickens to Marek's disease virus infection. *Avian Dis.* **16**:894-906.
- Solomon, J. J., R. L. Witter, K. Nazerian, and B. R. Burmester. 1968. Studies on the etiology of Marek's disease. I. Propagation of the agent in cell culture. *Proc. Soc. Exp. Biol. Med.* **127**:173-177.
- Solomon, J. J., R. L. Witter, H. A. Stone, and L. R. champion. 1970. Evidence against embryo transmission of Marek's disease. *Avian Dis.* **14**:752-762.
- Spencer, J. L., and A. Robertson. 1972. Influence of maternal antibody on infection with virulent or attenuated Marek's disease herpesvirus. *Amer. J. Vet. Res.* **33**:393-400.
- Vielitz, E., and H. Landgraf. 1970. Beitrag zur Epidemi-

- ologie und Kontrolle der Marekschen Krankheit. Deut. Tierärztl. Wochenschr. 77:357-362.
29. Witter, R. L., J. M. Sharma, J. J. Solomon, and L. R. Champion. 1973. An age-related resistance of chickens to Marek's disease: some preliminary observations. *Avian Pathol.* 2:43-54.
 30. Witter, R. L., J. J. Solomon, and G. H. Burgoyne. 1969. Cell culture techniques for primary isolation of Marek's disease-associated herpesvirus. *Avian Dis.* 13:101-118.
 31. Witter, R. L., J. J. Solomon, L. R. Champion, and K. Nazerian. 1971. Long term studies of Marek's disease infection in individual chickens. *Avian Dis.* 15:346-365.
 32. Zander, D. V., R. W. Hill, R. G. Raymond, R. K. Balch, R. W. Mitchell, and J. W. Dunsing. 1972. The use of blood from selected chickens as an immunizing agent for Marek's disease. *Avian Dis.* 16:163-178.