



Published in final edited form as:

Congenit Heart Dis. 2010 ; 5(4): 354–365. doi:10.1111/j.1747-0803.2010.00435.x.

To Close or Not to Close: The Very Small Patent Ductus Arteriosus

Elizabeth B. Fortescue, MD, MPH, James E. Lock, MD, Teresa Galvin, RDCS, and Doff B. McElhinney, MD

Harvard Medical School and Department of Cardiology, Children's Hospital Boston, and Department of Pediatrics, Harvard Medical School, Boston, Mass, USA

Abstract

Patent ductus arteriosus (PDA) accounts for approximately 10% of all congenital heart diseases, with an incidence of at least 2–4 per 1000 term births. Closure of the large, hemodynamically significant PDA is established as the standard of care, and can be performed safely and effectively using either surgical or transcatheter methods. The appropriate management of the very small, hemodynamically insignificant PDA is less clear. Routine closure of such defects has been advocated to eliminate or reduce the risk of infective endocarditis (IE). However, the risk of IE in patients with a small PDA appears to be extremely low, and IE is treatable. Although closure of the small PDA is generally safe and technically successful, it is unknown whether this treatment truly improves the risk : benefit balance compared with observation. In this article, we review the published literature on the natural history and treatment outcomes in individuals with a PDA, the epidemiology and outcomes of IE, particularly in association with PDA, and the rationale and evidence for closure of the very small PDA.

Keywords

Coil Embolization; Congenital Heart Disease; Device Closure; Patent Ductus Arteriosus; Practice Guidelines

Introduction

The purpose of this article is to review the published literature on the natural history and treatment outcomes in individuals with a patent ductus arteriosus (PDA), the epidemiology and outcomes of infective endocarditis (IE) particularly in association with PDA, and the rationale and evidence for closure of the very small PDA.

Patent Ductus Arteriosus

A PDA that persists beyond 1 month of age is estimated to occur in 0.3–0.8–4 per 1000 live births,¹ and to account for approximately 10% of all congenital heart defects.² The size of a PDA can range from very large to <1 mm, and accordingly, the clinical findings associated

with a PDA can vary considerably. In 1991, Houston et al. presented a study in which they evaluated children and adults with no typical PDA murmur on auscultation and no evidence pulmonary hypertension.³ In a random sample of 360 patients screened using Doppler echocardiography, the authors detected 21 patients with a silent PDA. The authors concluded that with the advent of sensitive measures such as Doppler ultrasound, the incidence of PDA may rise, as previously undetected patients come to medical attention. The authors posited that as many as 0.5% of patients presenting with an innocent murmur may have a PDA, which is far higher than earlier estimates (0.065%).⁴

The potential adverse effects of an untreated PDA include: (1) ventricular hypertrophy with congestive heart failure; (2) pulmonary vascular disease including Eisenmenger syndrome with shunt flow reversal; (3) poor physical growth; (4) IE; (5) aneurysmal dilatation of the ductus; and (6) ductal calcification.⁵ In some early series, especially those published prior to the advent of antibiotic therapy for IE, life expectancy for the patient with PDA was quoted as half that for an unaffected patient of the same age and cardiac anatomy.⁶ It has been estimated that one-third of adults with unrepaired, hemodynamically significant PDAs will die of heart failure, pulmonary hypertension, or endocarditis by age 40, and that this figure rises to two-third by age 60.²

The Very Small PDA

As noted above, PDAs can range considerably in size, physiologic significance, and clinical appearance. PDAs in patients with no other structural heart disease, especially small PDAs, can be difficult to detect clinically. Very small PDAs in particular may be associated with an innocent-sounding murmur or have no murmur at all, and are often termed “clinically silent” or “silent” because patients are symptom free and without other clinical findings, and if a murmur is present, it may be innocent sounding. Particularly if the lesion is not hemodynamically significant, a PDA may be missed until some other event, such as the performance of an echocardiogram for another reason or, rarely, the development of IE, leads to its discovery.⁷ Although some silent PDAs are detected incidentally in adulthood on routine clinical examination, this is the exception rather than the rule.⁸ Thus, the true prevalence of isolated, small PDAs unknown, as many patients likely go undetected if some other clinical event does not bring them to medical attention.

In this review, both “small” and “very small” are used to characterize PDA size, without precise definition. While these characterizations may be arguable, we intend “very small” to include clinically silent PDAs and “small” to refer to PDAs that may have a characteristic PDA murmur but are not associated with hemodynamic consequences. The natural history of small or silent PDAs has not been well characterized. Nevertheless, based on these definitions, it stands to reason that the main, if not only, significant complication that might be result from a small or silent PDA is IE.

Outcomes after PDA Closure

The concept of surgical PDA ligation was introduced by Munro in 1888.⁹ Successful PDA division was accomplished for the first time by Gross in 1939.¹⁰ This procedure was associated with significant risk in early experience, as such patients could go on to

experience postoperative complications such as elevated pulmonary pressures, heart failure from a long history of left-to-right ductal shunting, or pulmonary embolic phenomena. Risk of surgical complications including death and pulmonary or cerebral thromboembolism appeared greater in patients who came to medical attention because of the development of IE due to IE-associated vegetations on valves or on the pulmonary artery or aorta.

Over the past few decades, outcomes after surgical ligation of the PDA have improved significantly. In 1982, Marquis et al. reported on 804 adult patients with isolated PDA followed from 1940 to 1979.¹¹ Of these, 15 underwent surgical PDA ligation in adulthood either due to worsening symptoms (n = 14) or increasing heart size (n = 1). One patient's preoperative course was complicated by bacterial IE, which responded to preoperative antibiotics. Surgery was successful in all 15 patients; however, one patient died from a cerebral infarction sustained perioperatively, and another died 8 months postoperatively from heart failure. The authors concluded that operative PDA ligation is less well tolerated in older patients than in the young, and that elective surgical repair of PDAs should be undertaken in childhood whenever possible, no matter "however well the child, however trivial the shunt."¹¹

In a 1994 report, Mavroudis et al. presented a large, retrospective case series of 1108 pediatric patients from Children's Memorial Hospital of Chicago who underwent surgical PDA ligation between 1947 and 1993.¹² Patients with complex congenital heart disease and premature infants were excluded from the analysis. The authors noted that mean age at surgery declined from 5.9 ± 3.3 years in the first decade to 3.6 ± 3.8 years in the last decade. There were no deaths, no PDA recurrences, and no IE in follow-up. The overall morbidity rate was 4.4% and the major morbidity rates, which included reoperation for bleed and reoperation for inadequate ligation, were 0.3% and 0.1%, respectively. The authors concluded that open surgical division of the PDA is a safe and effective technique for PDA closure that avoids the risks of device embolization, PDA recanalization, or exsanguinating hemorrhage seen with other, more recent procedural approaches. The authors suggested that this approach should remain the standard of care until other approaches show similar safety rates.

In a 2006 report, Schneider et al. reviewed PDA closure techniques dating back to the first surgeries performed in 1939.¹³ Transcatheter closure was introduced by Portsmann et al. in 1967 using the conical Ivalon plug.¹⁴ This was followed by Rashkind and Cuaso, who employed an umbrella-type device for PDA closure starting in 1979.¹⁵ This approach was sometimes complicated by residual shunting, and in 1992 Cambier reported the first use of vascular embolization coils for nonsurgical PDA closure, which proved highly effective for the small-to moderate-sized PDA.¹⁶ Subsequently, additional transcatheter devices have been devised, including PDA-specific devices, allowing nonsurgical closure of larger PDAs and fewer postprocedural complications in general.

Over the past 10–15 years, transcatheter closure of PDAs has gained favor over surgical repair for most routine PDAs. A number of studies have been published reporting experience with transcatheter PDA closure, in particular using detachable coils and the Amplatzer ductal occluder device (Table 1).^{17–26} Sample sizes of these series ranged from

43 to 439. In total, 1640 patients were reported with an overall PDA closure rate at latest follow-up of 94%. There were 18 major adverse events, 17 of which (1.1%) were procedural: death unrelated to the procedure (n = 1), embolization of a closure device that was not retrieved (n = 10) or required an additional catheterization or surgery to repair (n = 6), and infective endocarditis (n = 1).²⁷ There were no procedural deaths, strokes, or other major vascular complications. Minor adverse events included embolization of a device that was retrieved in the same procedure and without adverse consequences such as stroke, vessel loss, or dissection (n = 70), aortic or left pulmonary artery narrowing not requiring intervention (n = 32), arrhythmia (n = 2), blood loss requiring transfusion (n = 2), significant hemolysis (n = 12), hypertension (n = 1), inguinal pseudoaneurysm or loss of peripheral pulse (n = 18), and various other minor complications (n = 7). These occurred in 144 patients, or 8.8%. Device embolization requiring intervention occurred in all reported series, at rates ranging from 1.4% to 11.6%. While the majority of embolized devices or coils were successfully retrieved using catheter-based methods, some patients with embolization were referred for surgical device removal and PDA ligation (n = 3). Although most series did not link PDA size to adverse events, Gudausky et al.¹⁸ reported that procedural failure did not occur when the PDA size was <1.5 mm. Overall, only one death was reported in these series, a 15-month-old with partial trisomy 18 who underwent successful PDA closure but died 5 months later from respiratory distress related to overwhelming sepsis.²¹ Postprocedure IE was reported in one patient who had an 8-mm PDA and trivial residual flow through the device on postimplant angiography.¹⁹ The patient recovered fully after antibiotic therapy and surgical device removal with PDA ligation. It is important to note that the duration of follow-up was limited and variable in all of these studies, such that it is impossible to estimate the risk of IE following transcatheter PDA closure.

During the same time period, surgical techniques for PDA ligation have improved, with the development of less invasive approaches with shorter recovery times and fewer operative complications. In the current era, thoracoscopic PDA closure is routinely employed, with similar acute outcomes to open closure^{28,29} Schneider et al. cited 94–100% overall success rates and 0–2% mortality with surgical closure. They remarked that a surgical approach remains the treatment of choice for the very large ductus. The authors also reviewed indications for PDA closure and supported that PDA closure is “clearly indicated” in certain patient groups, including: (1) those who are symptomatic from left-to-right shunting and (2) those who are asymptomatic but have left heart enlargement. PDA closure in the patient with a small PDA is less clear, but given the risk of IE and the low morbidity of closure, the authors concluded that “a strategy advocating routine closure of any PDA in children and young adults appears most reasonable.”¹³

IE: Overview

IE is a serious complication that is almost uniformly fatal if untreated.³⁰ Patients with lesions such as PDA, where an abnormal communication between cardiac structures produces turbulent blood flow, are at increased risk of developing endocarditis.³¹ In a 1995 publication, Durack addressed this issue extensively.³² Citing data from the early 1990s, Durack estimated that the overall incidence of IE was approximately 10–60 cases per million per year, and slightly lower in developed countries at 15–30 cases per million per

year, or 4000–8000 new cases in the United States per year. Of these, roughly 75% have preexisting cardiac abnormalities, including PDA.

In 2000, Ascuncion et al. presented a retrospective descriptive study looking at patients with congenital heart disease at one center treated between January 1990 and November 1998.³³ Among their 30 patients, who ranged in age from 10 to 45 years, ventricular septal defect (VSD) (n = 13) and PDA (n = 7) were the two most common cardiac diagnoses. PDA size was not discussed. Overall survival was 87%, with four patients dying from IE despite antimicrobial treatment, three due to embolism, and one from arrhythmia.

In a 2001 review, Mylonakis and Calderwood focused on progress made in the past decade in the diagnosis and management of IE affecting native and prosthetic heart valves in adults.³⁴ They reported an incidence of native-valve endocarditis of 1.7–6.2 cases per 100 000 person years in the United States and Western Europe, with mitral valve prolapse being the most common predisposing cardiovascular diagnosis in this setting. Patients with PDA were not specifically addressed.

In a 1998 scientific statement by the American Heart Association,³⁵ the authors estimated that the incidence of IE had increased over the prior decade, with 15 000–20 000 new cases of IE in the United States per year. This would make IE the fourth leading cause of life-threatening infectious disease in adults. Patients with PDA were not specifically addressed in that statement.

IE in Association with a PDA

The association between IE and PDA was first documented in the early 1900s.³⁶ Historically, IE was a rare but often fatal complication of PDA: in the preantibiotic era, IE was the single most common cause of death in PDA patients (42–45% of deaths). Over the course of the next few decades, after the introduction and initiation of widespread use of antibiotic therapy, mortality from IE in PDA patients decreased significantly. What was a frequently fatal infectious disease became survivable if appropriate antibiotics were administered in a timely manner.

Between 1939 and 1971, five case series were published characterizing the association between IE and PDA (Table 2).^{38–42} The majority of these investigators concluded that IE is rare in patients with PDA, but that when it does occur, surgical PDA ligation should be performed.

Over time, with the refinement of surgical and antimicrobial interventions, survival of patients with PDA-associated IE has improved. In 1975, Johnson et al. published a series of 149 episodes of IE in 141 patients from 1933 to 1972.³⁶ The patients in that study had a variety of different types of structural congenital heart disease, and all had a diagnosis of IE at study entry. Nine of these patients had PDA, four of whom died from IE, three in the first decade of study and one in the second. Overall, there was a steady decline in mortality from IE from 100% in the first decade to 19% in the last. The authors noted that early corrective surgery resulted in a marked decline in mortality and morbidity from IE in patients with PDA or VSD.

In a 1942 series, Wilson and Lubschez reported a mortality rate from IE among patients aged 2–19 years of 1 per 367 patient years (38 total patients), or 0.27% per annum.⁴¹ In 1968, Campbell reported an IE death rate among 123 patients of 0.6%. He concluded that, since the advent of antibiotic treatment, the short-term outlook for children with PDA and IE was much improved from earlier experiences, but that these patients remained at risk for repeated attacks of IE if the PDA was not subsequently closed. Cosh reported similar results in a 1957 series of 73 largely pediatric patients with isolated PDA followed during the antibiotic era. There were six cases of IE in 1451 patient years, or 0.4% per annum (95% confidence interval [CI]: 0.15–0.9%).⁴³ One of these patients died from the infection. Cosh concluded that PDA ligation is indicated when clinical signs and symptoms suggest the PDA is large, or after the patient has contracted and been treated for IE in order to prevent future attacks. Similar to Marquis et al.¹¹ Cosh remarked that even in the pediatric patient with a small, uncomplicated PDA, surgical ligation is justified, “for the risks of ligation are now less than the small risks of leaving the ductus patent.” However, he concluded that the same does not hold true for adult patients, where surgical ligation can be more difficult. In these patients, he recommended that an asymptomatic PDA may be left open, so long as care is taken to prevent IE.

In 1993, Schrader and Kadel retrospectively analyzed 100 adult patients with PDA who were referred for transcatheter closure.⁴⁴ They cited an annual incidence of IE in PDA of 0.14% (binomial 95% CI: 0.05–0.5%). More recently between 2002 and 2008, five case reports have been published describing IE in patients with an isolated PDA, as summarized in Table 3.^{45–49} Each of these reports emphasizes the importance of a high index of suspicion of IE in a patient with a known PDA who presents with prolonged symptoms of systemic infection. They also illustrate the sensitivity of echocardiography in making the diagnosis of PDA in such patients.

Recent guidelines from the American Heart Association of the Committee on Rheumatic Fever, Endocarditis, and Kawasaki Disease do not recommend routine subacute bacterial endocarditis prophylaxis for unrepaired PDA.⁵⁰

IE in Association with a Very Small PDA

As discussed above, Houston et al.³ observed a very small PDA in 21 of 360 children and adults without a typical PDA murmur who were screened with Doppler echocardiography, and estimated that as many as 0.5% of individuals with an innocent-sounding murmur may have a PDA. In the Discussion of that study, the authors commented on previous studies advocating routine PDA closure for the prevention of IE^{6,51} and questioned whether such recommendations should also apply to the clinically silent PDA. At the time of publication, the authors did not support routine PDA closure or antibiotic prophylaxis in these patients. The investigators hypothesized that some patients considered to have IE in a structurally normal heart may actually have a silent PDA, and that with the increasingly widespread use of color flow Doppler, these false-negative errors are likely to diminish. They proposed that patients with a silent PDA may benefit from PDA closure or prophylactic antibiotics.

In the 1990s, two notable reports were published regarding IE in patients with a silent PDA. In 1993, Balzer et al.⁵² presented a case of IE in a patient with a clinically silent PDA in which prompt diagnosis and effective treatment led to a good outcome (Table 4). The patient had no history of murmur and no murmur on presentation. The authors concluded that, like patients with larger PDAs, all patients with a silent PDA should undergo antibiotic prophylaxis and surgical closure. In a 1994 letter to the editor, Lloyd and Beekman commented on the Balzer et al. findings and questioned this conclusion.⁵³ Lloyd and Beekman argued that if the overall prevalence of silent PDA was estimated at 0.5%, then 300 000 US children would require PDA ligation to prevent the single episode of silent PDA associated IE observed by Balzer et al. Furthermore, if the mortality risk from surgical PDA ligation is 1 in 20 000, then 15 children would have died to prevent one episode of IE. Here, Lloyd and Beekman are implicitly arguing that the risk (not annualized) of IE in patients with a silent PDA is 1:300 000 based on Balzer et al.'s single case report, with the rhetorical assumption that Balzer et al.'s case represents 100% reporting of such occurrences. Lloyd and Beekman also brought up the troubling issue of detecting patients with a clinically silent PDA: such widespread application of echocardiography in an effort to detect these patients would not be feasible. The authors concluded that the risk of IE in a patient with silent PDA must be "more than a thousand-fold less than the risk when a continuous murmur is present," and ended their letter with a quotation from Latson et al. referring to the silent PDA as a "benign technomalady."⁵⁴

In 1997, Thilen and Astrom-Olsson presented a retrospective review of patient records and death certificates of 270 pediatric and adult cases of PDA from a large academic medical center in Sweden. Cases were collected from 1980 to 1995.⁵⁵ Among 270 PDA cases, 173 (64%) were isolated PDA and 38 of these were clinically silent. Half of the patients with a "silent" PDA had enlargement of the left atrium and/or ventricle, which highlights the limitations in our understanding of the relationship between a ductal murmur and hemodynamic significance. In 39 cases, the decision was made to leave the PDA patent. During 1196 patient years at risk, the investigators saw no cases of IE (binomial estimate of 95% CIs: 0.0–0.3%). To look further for IE cases, the authors reviewed all Swedish death certificates from 1960 to 1993 (~3 million) to check for the occurrence of PDA in combination with IE and found only two fatal cases of IE. The authors concluded that IE in patients with a PDA had declined in the last few decades and was currently rare. They suggested that given the low incidence of IE in association with a PDA and the efficacy of modern therapies for IE, routine PDA closure was not warranted solely for the indication of preventing IE. In patients with hemodynamically insignificant PDA and no current or past history of IE, the investigators recommended monitoring alone.

Over the past decade, three cases have been reported of IE in patients with a clinically silent PDA (Table 4).^{56–58} None of these patients had a previous PDA diagnosis prior to presentation or a reported history of murmur. In 2000, Parthenakis et al. reported the case of an 18-year-old female with no known cardiovascular disease who presented with fever for 40 days.⁵⁶ On presentation, cardiac auscultation revealed a soft systolic murmur at the second left intercostal space. Echocardiography showed a small PDA and a vegetation in the left pulmonary artery. The patient received antibiotics and the PDA was subsequently closed. The patient did well. In a 2004 report, Ozkokeli et al. described the case of a 27-

year-old female with no known cardiac disease and no prior murmur suggestive of a PDA, who presented with 3 months of fever, lethargy, and abdominal distention.⁵⁷ Cardiac auscultation at presentation revealed a loud pulmonary second heart sound and a diastolic murmur on the right sternal border. On echocardiography, she was found to have a 5-mm PDA and multiple vegetations on the pulmonary and aortic valves. She was diagnosed with IE and underwent excision of the pulmonary valve, aortic valve replacement, PDA closure, and received antibiotic therapy, after which she recovered uneventfully. The authors commented that, even though Thilen and Astrom-Olsson suggested there was no reason to close small PDAs for the sole purpose of preventing IE, risk of IE still exists even in the small PDA.⁵⁵ Similarly, in a 2006 report, Malnick and Zimhony presented the case of a 31-year-old immigrant female from Ethiopia with no known cardiovascular disease or murmurs who developed *Streptococcus anginosus* IE.⁵⁸ The patient's small, silent PDA was initially missed on transthoracic echocardiography and later detected on transesophageal echocardiography. Cardiac auscultation at presentation revealed a grade 2/6 systolic murmur audible at the cardiac apex. She received antibiotics, her PDA was closed, and she recovered without event. All of these cases were reported as IE in association with a silent PDA, but reported histories were limited and the presence of IE at the time of diagnosis may have confounded the clinical and echocardiographic findings. For example, it is possible that a PDA murmur existed previously and went undiagnosed, or that the development of IE changed the quality of an existing PDA murmur or the observed size of the PDA on echocardiography. The four reported cases of IE associated with a silent PDA underscore the importance of maintaining a high index of clinical suspicion for the presence of a small PDA in a patient with IE, even if there is no PDA history and there are no physical exam findings suggestive of this cardiac lesion. None of these PDAs were diagnosed prior to IE development. PDA size was not reported in three of these patients, and attempts to ascertain detailed anatomic or hemodynamic data through author correspondence to date have been unsuccessful. All four patients survived with antibiotic therapy and PDA closure.

Recent Children's Hospital Boston Experience

From January 1, 2005 to December 31, 2009, 168 patients at Children's Hospital Boston underwent transcatheter PDA closure. The median diameter of the PDA in the 168 patients was 2.6 mm (range 1.0–6.0 mm). The median PDA diameter measured by angiography at the time of PDA closure (n = 159 patients with data available) was 2.4 mm (range 0.5–6.5 mm; Figure 1). All PDAs were closed successfully in the catheterization lab, with no serious adverse events. There were 11 minor adverse events (6.6%; 95% CI 3.3–11.4%). Seven patients experienced embolization of a coil or device that was successfully retrieved (3.6%); there was no difference in PDA size between patients with and without device/coil embolization. Other minor adverse events included left pulmonary artery or aortic narrowing by the device in four patients; in one patient with left pulmonary artery narrowing, the decision was made to take the patient to the operating room electively during the same anesthesia round and ligate the PDA surgically. The possibility that transcatheter closure would be unsuccessful in this patient was recognized prior to the procedure, so the transition to operative closure was not unanticipated. There were no deaths and no reported cases of IE during limited follow-up.

During this same period at our center, 145 patients were diagnosed by echocardiography with an isolated PDA (or with a minor associated cardiac anomaly not requiring intervention) but did not undergo PDA closure. At the time of this report, quantitative echocardiographic assessment of PDA size was available in 139 of these patients (96%). The median PDA diameter in these patients was 1.4 mm (range 0.4–4.5 mm) and the PDA diameter was ≥ 2 mm in 120 patients (Figure 1); six patients lacked a quantitative PDA measurement and were reported only as “small” or “trivial” (3 each). In summary, of 172 patients with an isolated PDA measuring ≥ 2 mm in diameter during this period, 30% (52) were closed and the remaining 70% were left open. No patients developed IE.

Conclusions

PDA is a common congenital cardiovascular anomaly. In many cases, however, a PDA may be of little to no hemodynamic significance. With increasing use of echocardiography, the diagnosis of very small, clinically silent PDAs is likely to rise. Most investigators are in agreement that moderate or large PDAs, especially those with hemodynamic significance or associated IE, should be closed to improve the hemodynamic profile and prevent recurrent IE. Management of the very small or clinically silent PDA is more controversial, with a number of authors recommending routine closure regardless of size,^{11,12,43,52} and others advocating a more judicious approach.^{53,55} A risk: benefit analysis of this problem, which would attempt to balance the risks and benefits of PDA closure against those associated with leaving the PDA open, is hampered by a number of important limitations in the available data. If the sole reason for closing a very small, hemodynamically insignificant PDA is to decrease the risk of IE and its complications, there must be evidence or a good reason to believe that the cumulative risk of procedural events associated with closure and any residual risk of IE after closure is lower than the lifetime risk of IE associated with an open PDA.

Risks and Benefits of Closing the Very Small PDA

The risks associated with closure of a very small PDA are unknown. In the reported series of transcatheter PDA closure summarized in this review, including our experience, there were no procedural deaths, while major procedural events occurred in 1.0% of cases (95% CI: 0.6–1.6%). These are not broken down by PDA size/hemodynamic significance, so it is unclear whether the probability of procedural events is associated with PDA size. In our recent experience, which included no major but 11 minor events (6.6%; 95% CI 3.1–11.4%) in 168 patients, the frequency of minor events did not appear to differ across PDA size. Also, a reporting bias in favor of positive outcomes is well known, particularly with respect to case reports,^{59,60} and the authors are aware that major adverse events, including death, have occurred at other centers with closure of PDAs in otherwise well patients. Based on these limited data, a conservative estimate (i.e., on the low end of the spectrum suggested by the available data) of the major adverse event rate associated with PDA closure is in the range of 0.5–1.0%, while a more liberal estimate might be 1.5%. Additional risks of PDA closure, which may be impossible to ascertain, are the potential incremental risk of exposure of ionizing radiation, and the risks of undetermined chronic issues relating to medication and/or contrast exposure, which we can assume to be negligible. The purported benefit of

closing the very small PDA is reduction or elimination of IE risk. There are no data aside from case reports to support this indication. In the reported series of transcatheter PDA closure, follow-up was generally very short, while the risk of IE is ongoing, so the lack of events in these series does not speak to the true risk of IE after PDA closure. There was one reported case of IE in a patient who had an incompletely closed 8-mm PDA. This highlights an important assumption that underlies closure of the small PDA for IE prophylaxis, namely, that the PDA is successfully closed. Most series report complete closure in upwards of 95% of patients, often 98–99%, so this assumption is usually valid. In the small proportion of patients in whom complete closure is not obtained, however, the risk of IE is likely just as high as, if not higher than, a patient with an open PDA of the same size.

As noted earlier in this review, Lloyd and Beekman⁵³ estimated that if the overall prevalence of silent PDA is 0.5%, then 300 000 US children would require PDA ligation to prevent silent PDA-associated IE.⁵² Furthermore, if the mortality risk from surgical PDA ligation is 1 in 20 000, then 15 children would die to prevent silent PDA associated IE. In the risk: benefit calculations Lloyd and Beekman presented, they assumed (even if only for the sake of argument) that the Balzer et al. case was the only instance of a silent PDA associated with IE, such that the rate of IE in silent PDAs was estimated at 1 in 300 000 (95% CI 0.0 to <0.01%). Of four reported cases of IE associated with a clinically silent PDA, all but the Balzer et al. report were from outside the United States.^{52,56–58} It is arguable that positive reporting bias would be less of an impediment to reporting cases of IE associated with silent PDA, as treatment in such cases is antibiotics followed by surgical PDA closure, and this type of event might be enlisted as a “positive” case to support the utility of closing such defects. Nevertheless, the estimated risk of IE used in the risk: benefit analysis proposed by Lloyd and Beekman is likely an underestimate. In other series discussed above, Thilen and Astrom-Olsson reported no cases of IE in 1196 patient years (binomial 95% CI: 0.0–0.3% per patient-year),⁵⁵ Wilson and Lubschez⁴¹ reported 1 death in 367 patients, or 0.27%, and Schrader and Kadel reported an annual IE risk of 0.14% in a series of 100 adults.⁴⁴ Based on these studies, which include both large and small PDAs, the risk of IE in patients with a PDA is higher than the assumption utilized by Lloyd and Beekman, which was directed only at the question of the clinically silent PDA. Presumably, the risk of IE is lower in patients with a very small PDA than in these series, and higher than the 1 in 300 000 risk assumed by Lloyd and Beekman, but there are limited data upon which to base this assumption. In the study by Schrader and Kadel, the luminal diameter of the PDA was <4.5 mm in 60% of the cases, but 4.5 mm in all six cases complicated by IE. This suggests that the risk of IE is substantially higher in large than small PDAs. Taking all of these data into consideration, and assuming that the risk of IE associated with PDA is weighted toward larger PDAs, 0.01% per year would be a conservative estimate of IE risk in patients with a small PDA, and 0.001% would be substantially higher than the 1 in 300 000 used in the calculations of Lloyd and Beekman, and still reasonable based on the reported literature.

Risks and Benefits of Leaving the Very Small PDA Open

In the absence of hemodynamic significance, the only known risk associated with leaving a very small PDA open is that of IE, which is to the inverse of the benefit of PDA closure in

these patients. Similarly, the clinical benefits of leaving a small PDA open are inversely identical to the risks of closing a PDA. Another potentially important benefit of not closing small PDAs is financial. Lloyd and Beekman addressed the potential costs of ascertaining and closing small PDAs, which are estimated to occur in 0.5% of the population, and estimated a conservative price tag of \$33 billion, making the argument that routine closure of small PDAs for IE prophylaxis is not cost effective.

Using the conservative estimates reached above, the lifetime risk of IE associated with leaving a very small PDA open, assuming that there is no change in the size or hemodynamic significance of such PDAs over time (0.01% per year for 85–90 years, 0.1% lifetime risk) is similar to the risk associated with a major procedural adverse event for closing a small PDA, and there is no clear preference for either approach. Using the more liberal estimates proposed above (0.001% annual risk of IE associated with a very small PDA and 1.5% risk of a major procedural adverse event associated with closing a small PDA), the risk of procedural events is more than an order of magnitude higher than the lifetime risk of IE. Based on the currently available data and crude estimates of risk derived from those data, which are limited and confounded with respect to the present exercise, there is no evidence to support a superior risk: benefit balance for routine closure of the very small, hemodynamically insignificant PDA, and accordingly, it is difficult to justify closure of such defects simply to reduce the risk of IE and its complications. There are a number of unknowns data addressing these questions may shift the balance of evidence. Because IE is a very rare event in the population of patients with a very small PDA, and may occur many years after diagnosis of the PDA, it would be impractical to perform a prospective trial of closure of the very small PDA for IE prophylaxis. Thus, further refinement of risk: benefit calculations concerning this problem will depend largely on prospective clinical practice-based evidence and/or decision analysis, and, in this evolving health care landscape, may require more candid cost: benefit considerations.

Acknowledgments

This work was supported by the National Institutes of Health under award number: T32 HL007572. The content is solely the responsibility of the authors and does not necessarily represent the official views of the National Institutes of Health.

References

1. Hoffman JI, Kaplan S. The incidence of congenital heart disease. *J Am Coll Cardiol.* 2002; 39:1890–900. [PubMed: 12084585]
2. Brickner ME, Hillis LD, Lange RA. Congenital heart disease in adults. First of two parts. *N Engl J Med.* 2000; 342:256–263. [PubMed: 10648769]
3. Houston AB, Gnanpragasam JP, Lim MK, Doig WB, Coleman EN. Doppler ultrasound and the silent ductus arteriosus. *Br Heart J.* 1991; 65:97–99. [PubMed: 1867953]
4. Dickinson DF, Arnold R, Wilkinson JL. Congenital heart disease among 160,480 liveborn children in Liverpool 1960 to 1969. Implications for surgical treatment. *Br Heart J.* 1981; 46:55–62. [PubMed: 7272113]
5. Panagopoulos PG, Tatooles CJ, Aberdeen E, Waterston DJ, Carter REB. Patent ductus arteriosus in infants and children: a review of 936 operations (1946–1969). *Thorax.* 1971; 26:137–144. [PubMed: 5576528]
6. Keys A, Shapiro MJ. Patency of the ductus arteriosus in adults. *Am Heart J.* 1943; 25:158.

7. Malnick SDH, Shimoni S, Zimhony O. An unusual case of endocarditis. *CMAJ*. 2006; 174:1087–1088. [PubMed: 16606955]
8. Cassidy HD, Cassidy LA, Blackshear JL. Incidental discovery of a PDA in adults. *J Am Board Fam Med*. 2009; 22:214–218. [PubMed: 19264947]
9. Munro JC. Surgery of the vascular system, I. Ligation of the ductus arteriosus. *Ann Surg*. 1907; 46:335. [PubMed: 17862026]
10. Gross RE. Complete division for the patent ductus arteriosus. *J Thorac Surg*. 1947; 16:314. [PubMed: 20256742]
11. Marquis RM, Miller HC, McCormack RJM, Matthews MB, Kitchin AH. Persistence of ductus arteriosus with left to right shunt in the older patient. *Br Heart J*. 1982; 48:469–484. [PubMed: 7138711]
12. Mavroudis C, Backer CL, Gevitz M. Forty-six years of patent ductus arteriosus division at Children's Memorial Hospital of Chicago: standards for comparison. *Ann Surg*. 1994; 220:402–410. [PubMed: 8092906]
13. Schneider DJ, Moore JW. Patent ductus arteriosus. *Circulation*. 2006; 114:1873–1882. [PubMed: 17060397]
14. Portsman W, Wierny L, Warnke H. Closure of persistent ductus arteriosus without thoracotomy. *Ger Med Mon*. 1967; 12:259–261. [PubMed: 6045537]
15. Rashkind WJ, Cuaso CC. Transcatheter closure of a patent ductus arteriosus: successful use in a 3.5 Kg infant. *Pediatr Cardiol*. 1979; 1:3–7.
16. Cambier PA, Kirby WC, Wortham DC, Moore JW. Percutaneous closure of the small (<2.5 mm) patent ductus arteriosus using coil embolization. *Am J Cardiol*. 1992; 69:815–816. [PubMed: 1546662]
17. Azhar AS, El-Azim AAA, Habib HS. Transcatheter closure of patent ductus arteriosus: evaluating the effect of the learning curve on the outcome. *Ann Pediatr Card*. 2009; 2:36–40.
18. Gudauskas TM, Hirsch R, Khoury PR, Beekman RH. Comparison of two transcatheter device strategies for occlusion of the patent ductus arteriosus. *Catheter Cardiovasc Interv*. 2008; 72:675–680. [PubMed: 18942128]
19. Jang GY, Son CS, Lee JW, Lee JY, Kim SJ. Complications after transcatheter closure of patent ductus arteriosus. *J Korean Med Sci*. 2007; 22:484–490. [PubMed: 17596658]
20. Wang JK, Hwang JJ, Chiang FT, et al. A strategic approach to transcatheter closure of patent ductus: gianturco coils for small-to-moderate ductus and Amplatzer duct occluder for large ductus. *Int J Cardiol*. 2006; 106:10–15. [PubMed: 16146660]
21. Pass RH, Hijazi Z, Hsu DT, Lewis V, Hellenbrand WE. Multicenter USA Amplatzer patent ductus arteriosus occlusion device trial. *J Am Coll Cardiol*. 2004; 44:513–519. [PubMed: 15358013]
22. Galal MO, Bulbul Z, Kakadekar A, et al. Comparison between the safety profile and clinical results of the Cook detachable and Gianturco coils for transcatheter closure of patent ductus arteriosus in 272 patients. *J Interv Cardiol*. 2001; 14:169–177. [PubMed: 12053300]
23. Thanopoulos BD, Hakim FA, Hiari A, et al. Further experience with transcatheter closure of the patent ductus arteriosus using the Amplatzer duct occluder. *JACC*. 2000; 35:1016–1021. [PubMed: 10732903]
24. Celiker A, Qureshi SA, Bilgic A, et al. Transcatheter closure of patent arterial ductus using controlled-release coils. *Eur Heart Journal*. 1997; 18:450–454.
25. Tometzki AJP, Arnold R, Peart I, et al. Transcatheter occlusion of the patent ductus arteriosus with Cook detachable coils. *Heart*. 1996; 76:531–535. [PubMed: 9014804]
26. Uzun O, Hancock S, Parsons JM, Dickinson DF, Gibbs JL. Transcatheter occlusion of the arterial duct with Cook detachable coils: early experience. *Heart*. 1996; 76:269–273. [PubMed: 8868988]
27. Bergersen L, Marshall A, Gauvreau K, et al. Adverse event rates in congenital cardiac catheterization—a multicenter experience. *Catheter Cardiovasc Interv*. 2010; 75:389–400. [PubMed: 19885913]
28. Dutta S, Mihailovic A, Benson L, et al. Thoraco-scopic ligation versus coil occlusion for patent ductus arteriosus: a matched cohort study of out-comes and cost. *Surg Endosc*. 2008; 22:1643–1648. [PubMed: 18027029]

29. Vanamo K, Berg E, Kokki H, Tikanoja T. Video-assisted thoracoscopic versus open surgery for persistent ductus arteriosus. *J Pediatr Surg.* 2006; 41:1226–1229. [PubMed: 16818053]
30. Kaye D, Abrutyn E. Prevention of bacterial endocarditis: 1991. *Ann Int Med.* 1991; 114:803–804. [PubMed: 2012361]
31. Durack DT. Current issues in prevention of infective endocarditis. *Am J Med.* 1985; 78:149–156. [PubMed: 4014277]
32. Durack DT. Prevention of infective endocarditis. *N Engl J Med.* 1995; 332:38–44. [PubMed: 7990863]
33. Ascuncion AML, Reyes-Javier D, Pena AC, et al. Infective endocarditis in patients with congenital heart disease at the Philippine Heart Center. *Phil J Microbiol Infect Dis.* 2000; 29:171–176.
34. Mylonakis E, Calderwood SB. Infective endocarditis in adults. *N Engl J Med.* 2001; 345:1318–1330. [PubMed: 11794152]
35. Bayer AS, Bolger AF, Taubert KA, et al. Diagnosis and management of infective endocarditis and its complications. *Circulation.* 1998; 98:2936–2948. [PubMed: 9860802]
36. Johnson D, Rosenthal A, Nadas A. A forty-year review of bacterial endocarditis in infancy and childhood. *Circulation.* 1975; 51:581–588. [PubMed: 1116249]
37. Campbell M. Natural history of persistent ductus arteriosus. *Br Heart J.* 1968; 30:4–13. [PubMed: 5637557]
38. Benn J. The prognosis of patent ductus arteriosus. *Br Heart J.* 1947; 9:283–291. [PubMed: 18610079]
39. Abbott, M. *Atlas of Congenital Heart Disease.* New York: The American Heart Association; 1936.
40. Keys A, Shapiro MJ. Patency of the ductus arteriosus in adults. *Am Heart J.* 1943; 25:158.
41. Wilson MG, Lubschez R. Prognosis for children with congenital anomalies of the heart and central vessels: Life expectancy in patent ductus arteriosus. *J Pediatr.* 1942; 21:23.
42. Panagopoulos PG, Tatoes CJ, Aberdeen E, Waterston DJ, Carter RE. Patent ductus arteriosus in infants and children. *Thorax.* 1971; 26:137–144. [PubMed: 5576528]
43. Cosh JA. Patent ductus arteriosus: a follow-up study of 73 cases. *Br Heart J.* 1957; 19:13. [PubMed: 13396072]
44. Schrader R, Kadel C. Persistierender Ductus arteriosus—ist auch bei asymptomatischen Erwachsenen mit kleinem Ductus und geringen Shunt ein Verschluss indiziert? *Z Kardiol.* 1993; 82:563–567. [PubMed: 8237097]
45. Jayakeerthi SR, Kanungo R. Satelliting streptococci in adult male with foetal heart. *Indian J Med Microbiol.* 2002; 20:223–224. [PubMed: 17657077]
46. Kouris NT, Sifaki MD, Kontogianni DD, et al. Patent ductus arteriosus endarteritis in a 40-year-old woman, diagnosed with transesophageal echocardiography. A case report and a brief review of the literature. *CardiovascUltrasound.* 2003:1–6.
47. Bilge M, Uner A, Ozeren A, et al. Pulmonary endarteritis and subsequent embolization to the lung as a complication of patent ductus arteriosus: a case report. *Angiology.* 2004; 55:99–102. [PubMed: 14759097]
48. Choi KN, Yang TH, Park BS, et al. A case with patent ductus arteriosus complicated by pulmonary artery endarteritis. *J Cardiovasc Ultrasound.* 2008; 16:90–92.
49. Satoh T, Nishida N. Patent ductus arteriosus with infective endocarditis at age 92. *Intern Med.* 2008; 47:263–268. [PubMed: 18277027]
50. Wilson W, Taubert KA, Gewitz M, et al. Prevention of infective endocarditis: guidelines from the American Heart Association: a guideline from the American Heart Association Rheumatic Fever, Endocarditis, and Kawasaki Disease Committee, Council on Cardiovascular Disease in the Young, and the Council on Clinical Cardiology, Council on Cardiovascular Surgery and Anesthesia, and the Quality of Care and Outcomes Research Interdisciplinary Working Group. *Circulation.* 2007; 116:1736–1754. [PubMed: 17446442]
51. Bullock LT, Jones JC, Dolley FS. The diagnosis and the effects of ligation of the patent ductus arteriosus. *J Pediatr.* 1939; 15:786–801.
52. Balzer DT, Spray TL, McMullin D, Cottingham W, Canter CE. Endocarditis associated with a clinically silent PDA. *Am Heart J.* 1993; 125:1192–1193. [PubMed: 8465758]

53. Lloyd T, Beekman RH. Clinically silent patent ductus arteriosus. *Am Heart J.* 1994; 6:1664. [PubMed: 8198009]
54. Latson LA. Residual shunts after transcatheter closure of patent ductus arteriosus: a major concern or benign “techno-malady”? *Circulation.* 1991; 84:2591–2593. [PubMed: 1959208]
55. Thilen U, Astrom-Olsson K. Does the risk of infective endarteritis justify routine patent ductus arteriosus closure? *Eur Heart J.* 1997; 18:503–506. [PubMed: 9076389]
56. Parthenakis FI, Kanakarakis MK, Vardas PE. Silent patent ductus arteriosus. *Heart.* 2000; 84:619. [PubMed: 11083739]
57. Ozkokeli M, Ates M, Uslu N, Akcar M. Pulmonary and aortic valve endocarditis in an adult patient with silent patent ductus arteriosus. *Jpn Heart J.* 2004; 45:1057–1061. [PubMed: 15655282]
58. Malnick SDH, Zimhony O. An unusual case of endocarditis. *CMAJ.* 2006; 174:1087. [PubMed: 16606955]
59. Albrecht J, Meves A, Bigby M. A survey of case reports and case series of therapeutic interventions in the Archives of Dermatology. *Int J Dermatol.* 2009; 48:592–597. [PubMed: 19538367]
60. Moscati R, Jehle D, Ellis D, Fiorello A, Landi M. Positive-outcome bias: comparison of emergency medicine and general medicine literatures. *Acad Emerg Med.* 1994; 1:267–271. [PubMed: 7621207]

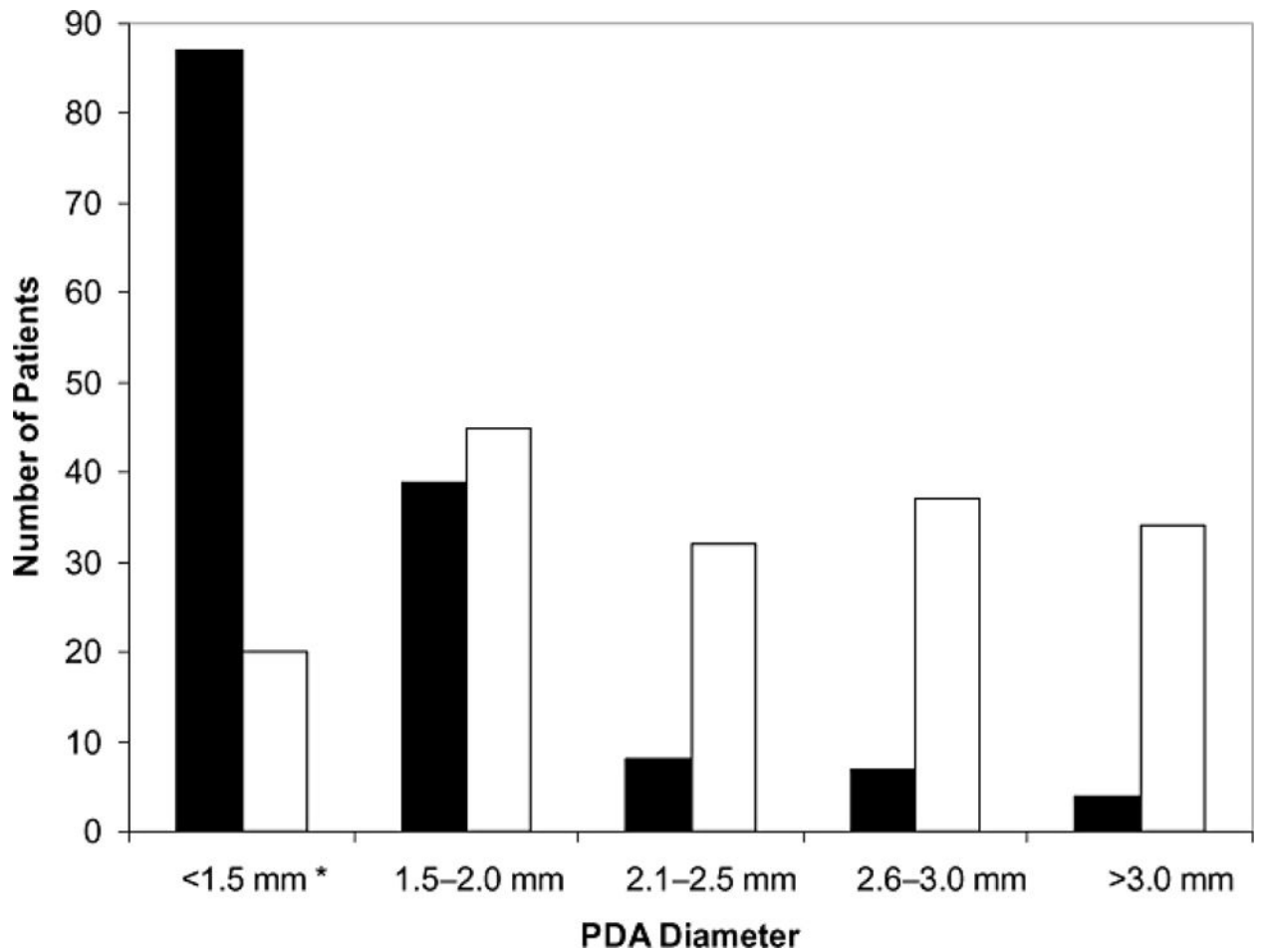


Figure 1. Diameters of PDAs closed in the catheterization lab compared with those left open, Children’s Hospital Boston, January 2005–December 2009. *Includes six open PDAs reported as “trivial” or “small” (three each) without diameter reported. The solid bars represent open PDAs; the open bars closed PDAs. PDA, patent ductus arteriosus.

Table 1

Transcatheter PDA Closure Results Summary

Authors (Study Period)	#Pts	PDA Sizes*	Closure Types [†]	% Closure at Latest Follow-Up	Adverse Outcomes [‡]
Uzun 1996 ²⁶ (not reported)	43	Not reported	Coil	3 months: 86%	Major (4.7%): major embolization (2) Minor (7.0%): minor embolization (3)
Tometzki et al. 1996 ²⁵ (1994–1995)	71	2.0 mm (1–5 mm)	Coil	6 months: 98%	Major (1.4%): major embolization (1) Minor: none
Celikler et al. 1997 ²⁴ (1994–1995)	52	3.2 mm [1–6.5 mm]	Coil	1 month: 94%	Major: none Minor (11.5%): minor embolization (5), Hemolysis (1)
Thanopoulos et al. 2000 ²³ (1997–1999)	43	3.9 mm (2.2–8 mm)	ADO	1 day: 100%	Major (2.3%): major embolization (1) Minor (2.3%): N (1)
Galal et al. 2001 ²² (1994–1998)	272	2.55 mm [0.2–7 mm]	Coil	6 months: 79%	Major (1.5%): major embolization (4) Minor (9.9%): minor embolization (27)
Pass et al. 2004 ²¹ (1999–2002)	439	2.6 mm (0.9–11.2 mm)	ADO	1 year: 99%	Major (0.5%): major embolization (1), death (1) Minor (10.7%): minor embolization (1) hemolysis (7), P (7), Ar (2), N (2), B (2), Other (8)
Wang et al. 2006 ²⁰ (1995–2000)	350	2.7 mm ±1.2 mm	Coil ADO	3 months: 96%	Major (0.3%): major embolization (1) Minor (8.9%): minor embolization (20), N (9), P (9), Hemolysis (2)
Jang et al. 2007 ¹⁹ (1999–2005)	117	4 mm (3–8 mm)	ADO BD Coil	Overall: 97%	Major (0.9%): IE (1) Minor (7.7%): minor embolization (1) N (6), Hemolysis (2)
Gudauskas et al. 2008 ¹⁸ (2000–2005)	132 132	1.7 mm ±1.0 mm	Coil ADO	6 months: 95%	Major (3.0%): major embolization (4) Minor: (6.8%): minor embolization (9)
Azhar et al. 2009 ¹⁷ (2000–2004)	121	2.9 mm (1–10 mm)	Coil ADO	Overall: 98%	Major (1.7%): major embolization (2) Minor (16.5%): minor embolization (4), N (14), P (2)
Children's Hospital Boston (2005–2009)	168	2.6 mm (1.0–6.0)	Coil ADO	Overall: 95% [§]	Major: none Minor (6.6%): minor embolization (7), N (4)
Totals //	1808	Average 2.7 mm (0.2–11.2 mm)	Coil BD ADO	Overall mean: 94.0%	Overall mean adverse outcome rates: Major: total n = 18, 1.5% (95% CI: 1.1–2.1%) Minor: total n = 169, 8.0% (95% CI: 7.3–10.0%)

* Patent ductus arteriosus (PDA) sizes presented as median (min–max), mean [min–max], or mean ± standard deviation, unless otherwise specified.

[†] Closure types: ADO, Amplatzer ductal occluder; BD, Buttoned device; Coil, Cook detachable coils.

[‡] Adverse outcomes (adverse events, AEs): Major AEs: death, device embolization requiring interventions or resulting in morbidities as defined in text, infective endocarditis (IE); Minor AEs: device embolization without major complication, aortic or left pulmonary artery narrowing requiring no intervention (N), arrhythmia (Ar), blood loss requiring transfusion (B), significant hemolysis, pseudoaneurysm, or loss of peripheral pulse (P).

[§] Early postcatheterization echocardiograms available on 60 of 168 patients, 57 completed closed.

// Overall averages listed in Totals are weighted based on number of patients in each study group. 95% confidence intervals (CI) for event frequency based on binomial estimates.

Pts, patients

Table 2

Case Series of IE in PDA patients: 1939–1971

Authors	PDA N	Other CHD N (%)	Total IE N (%)	Death from IE N (%)	PDA Closure N (%)	Follow-Up Time
Abbott 1936 ³⁹	92	0	Unknown*	28 (30)	0	N/A*
Wilson and Lubschez 1942 ⁴¹	38	0	0	0	Unknown	20 years
Keys and Shapiro 1943 ⁴⁰	60	0	Unknown*	24 (40)	0	N/A*
Benn 1947 ³⁸	46	0	5(11)	4(9) [†]	0	0–20 years
Panagopoulos et al. 1971 ⁴²	936	147 (16)	0	0	936 (100)	0–5 5 years

* Postmortem series.

[†] One IE patient received antibiotics but subsequently died 2 months later.

CHD, congenital heart disease; PDA, patent ductus arteriosus; IE, infective endocarditis; N/A, not applicable.

Table 3

Case Reports of IE in PDA Patients 2002–2008

Authors	Patient Age (years)	Symptoms	PDA Size, mm (if known)	Organism(s)	Preoperative Antibiotics	PDA Surgically Closed	Alive at Follow-Up
Jayakeerthi and Kanungo 2002 ⁴⁵	30	Fever, Breathlessness, Palpitations	Large	<i>Staphylococcus aureus, Abiotrophia*</i>	Yes	Yes	Yes
Kouris et al. 2003 ⁴⁶	40	Fever, palpitations, fatigue, weight loss	NR	<i>Streptococcus sanguis II</i>	Yes	Yes	Yes
Bilge et al. 2004 ⁴⁷	11	Fever, sweating, weight loss	NR	<i>S. viridans</i>	Yes	Yes	Yes
Choi et al. 2008 ⁴⁸	49	Fever, fatigue, weight loss	Large (9 mm)	NR	Yes	Yes	Yes
Sato and Nishida 2008 ⁴⁹	92	Fatigue, exertional dyspnea	Moderate (5 mm)	NR	NR, NA	No	No

* Culture-negative on standard culture media; fastidious culture media required for bacteria identification.
PDA, patent ductus arteriosus; IE, infective endocarditis; NR, not reported; NA, not applicable

Table 4

Case Reports of IE in Previously Healthy “Silent” PDA Patients: 1993–2006*

Authors Country of Origin	Patient Age (Years)	Presenting Symptoms	Physical Exam and Lab Findings	Cardiac Auscultation at Diagnosis	Echocardiogram Findings [†]	Treatment and Outcome
Balzar et al. 1993 ⁵² USA	19	3 days of fever, nausea, vomiting, head, neck, and back pain	Pharyngeal erythema, cervical lymphadenopathy; blood culture positive for <i>Staphylococcus aureus</i> Blood culture positive for <i>Streptococcus sanguis</i>	Soft systolic ejection murmur over left sternal border	Small (2–3mm) PDA, small echodensity at LPA consistent with vegetation at entrance of PDA	Antibiotics followed by PDA ligation
Parthenakis et al. 2000 ⁵⁶ Greece	18	6 weeks of fever	Blood culture positive for <i>Streptococcus sanguis</i>	Soft systolic murmur at second left intercostal space	Small PDA, large, mobile mass at entrance of PDA into LPA consistent with vegetation	Antibiotics followed by PDA ligation, removal of vegetation
Ozkokeli et al. ⁵⁷ 2004 Turkey	27	3 months of fever, lethargy, abdominal distention followed by acute onset dyspnea	Hepatomegaly, splenomegaly, lower extremity purpura. ESR 51mm/hour. Blood culture positive for a-hemolytic <i>Streptococcus</i>	Loud pulmonary second heart sound, diastolic murmur on right sternal border	PDA (5mm), large echodense mass on non-coronary cusp of aortic valve, vegetations on wall of pulmonary artery	Antibiotics followed by PDA ligation, removal of vegetation, excision of pulmonary valve, aortic valve replacement
Malnick and Zimhony 2006 ⁵⁸ Israel; Patient from Ethiopia	31	2 weeks of fever, generalized weakness, cough	Mild bibasilar pulmonary crackles. ESR 83 mm/ hour. Blood culture positive for <i>S. anigmus</i>	Grade 2/6 systolic murmur at cardiac apex; 6 days later: 3/6 continuous “Machinery” murmur above pulmonic region	Mild dilation of left ventricle, normal valves, no vegetations; six days later: mobile mass at LPA, small PDA	Antibiotics followed by PDA ligation, removal of LPA vegetation, pulmonary arterioplasty

* All four patients were previously healthy and had no documented history of murmur or PDA diagnosis.

[†] PDA diameters not published. All authors contacted directly for dimensions. Where PDA dimensions are not listed in the table, responses were not received from the authors.

PDA, patent ductus arteriosus; LPA, left pulmonary artery; RPA, right pulmonary artery; IE, infective endocarditis; ESR, erythrocyte sedimentation rate.