



- 7 Abrahamsson K, Holme E, Jodal E, Lindstedt S, Nordin I. Effect of short-term treatment with pivalic acid containing antibiotics on serum carnitine concentration: A risk irrespective of age. *Biochem. Mol. Med.* 1995; **55**: 77–9.
- 8 Oey NA, van Vlies N, Wijburg FA, Wanders JA, Attie-Bitach T, Vaz FM. L-Carnitine is synthesized in human fetal-placental unit: Potential roles in placental and fetal metabolism. *Placenta* 2006; **27**: 841–46.
- 9 Arenas J, Rubio JC, Martin MA, Campos Y. Biological roles of L-carnitine in perinatal metabolism. *Early Hum. Dev.* 1998; **53** (Suppl.):S43–50.

## Short QT syndrome in a boy diagnosed on screening for heart disease

Hiroshi Suzuki,<sup>1</sup> Satoshi Hoshina,<sup>1</sup> Junichi Ozawa,<sup>1</sup> Akinori Sato,<sup>2</sup> Tohru Minamino,<sup>2</sup> Yoshifusa Aizawa<sup>3</sup> and Akihiko Saitoh<sup>1</sup>  
*Departments of <sup>1</sup>Pediatrics and <sup>2</sup>Cardiovascular Biology and Medicine, Niigata University Graduate School of Medical and Dental Sciences and <sup>3</sup>Tachikawa Medical Center, Niigata, Japan*

**Abstract** We report on an asymptomatic 10-year-old boy who had a short QT interval (corrected QT interval, 260 ms). Short QT syndrome (SQTS) was detected in a school screening program for heart disease and the patient was subsequently diagnosed as having N588K mutation in the *KCNH2* gene. Quinidine prolonged the QT interval, but not the QU interval. During treadmill exercise stress test, QT and QU intervals responded differently to heart rate changes, suggesting a mechano-electrical hypothesis for the origin of the U wave. Although rare, attention should be paid to SQTS, which is associated with potential fatal arrhythmias.

**Key words** cardiac arrhythmia, channelopathy, electrocardiography, short QT syndrome 1, sudden cardiac death.

Short QT syndrome (SQTS) is a cardiac channelopathy associated with the risk of ventricular fibrillation (VF) and atrial fibrillation (AF), and is characterized by short QT and corrected QT (QTc) intervals on electrocardiogram (ECG).<sup>1</sup> Quinidine is reported to be effective in preventing VF in patients with SQTS,<sup>2</sup> but the effects of quinidine on ECG findings are poorly known. We report herein on the case of a boy with SQTS that was diagnosed in a school screening program for heart disease, and describe the effects of quinidine on ECG, evaluated during an exercise stress test.

### Case report

A 10-year-old boy was referred to hospital because of abnormality detected on ECG in a school screening program for heart disease. His ECG showed normal sinus rhythm but had a markedly short QT interval (QTc, 260 ms; Fig. 1). The patient had been asymptomatic except for two episodes of febrile convulsion at the age of 3 years. Family history was significant for a similar ECG finding in the mother and the sudden death of the maternal grandmother at the age of 45. Blood chemistry data, thyroid hormone, and testosterone were within normal limits. Twelve-lead Holter ECG showed persistence of short QT interval. Echocardiography showed a structurally normal heart. Genetic analysis of the patient and his mother was done after obtaining

written informed consent, in accordance with the study protocol approved by the Medical Ethics Committee of Niigata University Graduate School of Medical and Dental Sciences. The N588K mutation in the *KCNH2* gene was found in both patients. This mutation has been known to cause a gain of function in the rapid component of the delayed rectifying potassium current, *IKr*.<sup>3</sup>

The ECG at rest showed a short QT interval and a U wave separate to the T wave. Quinidine (20 mg/kg per day) prolonged the QT interval and shortened the interval between the T wave and the U wave (Fig. 1). In a treadmill exercise stress test, heart rate increased but the QT interval remained unchanged throughout the test (Fig. 2a). Consequently, the relationship between the Q to the peak of the T wave (QTp) interval and the RR interval was flat (Fig. 3a). In contrast, quinidine had no effect on the U wave and the Q to the peak of the U wave (QUp) interval (Fig. 1b). On treadmill stress test, the QUp interval was shortened as heart rate increased and the U wave fused with the P wave of the next beat (Figs 2b,3b).

The patient and his family refused implantable cardioverter defibrillator (ICD) implantation and has been followed on quinidine alone. We gave instructions to the patient's family and school staff regarding cardiopulmonary resuscitation and automated external defibrillator (AED) use.

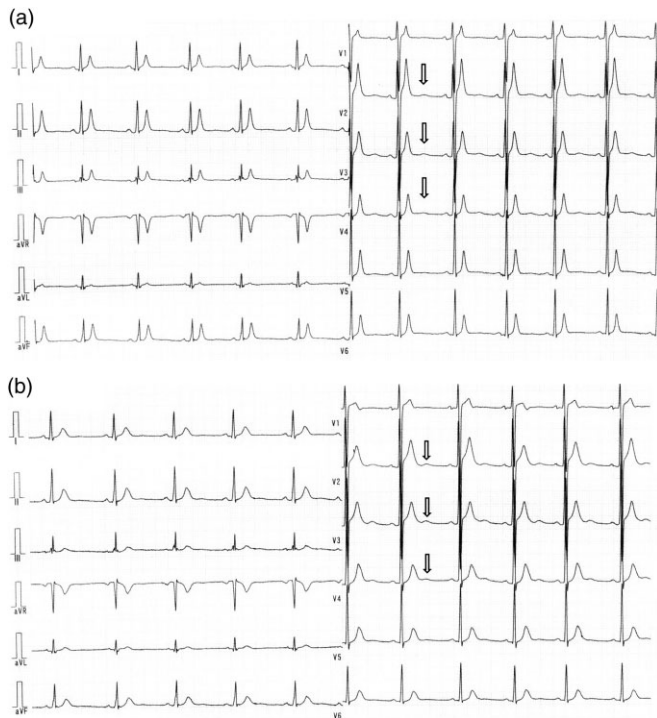
### Discussion

We herein report an asymptomatic 10-year-old boy with SQTS detected in a school screening program for heart disease. The present patient had an N588K mutation in the *KCNH2* gene. SQTS was screened for in the regular examination for school children, but he had been free from arrhythmic events. He had a

Correspondence: Hiroshi Suzuki, MD PhD, Department of Pediatrics, Niigata University Graduate School of Medical and Dental Sciences, 1-757 Asahimachi-dori, Chuo-ku, Niigata 951-8510, Japan. Email: hsuzukc5@med.niigata-u.ac.jp

Received 6 December 2013; accepted 23 January 2014.

doi: 10.1111/ped.12308

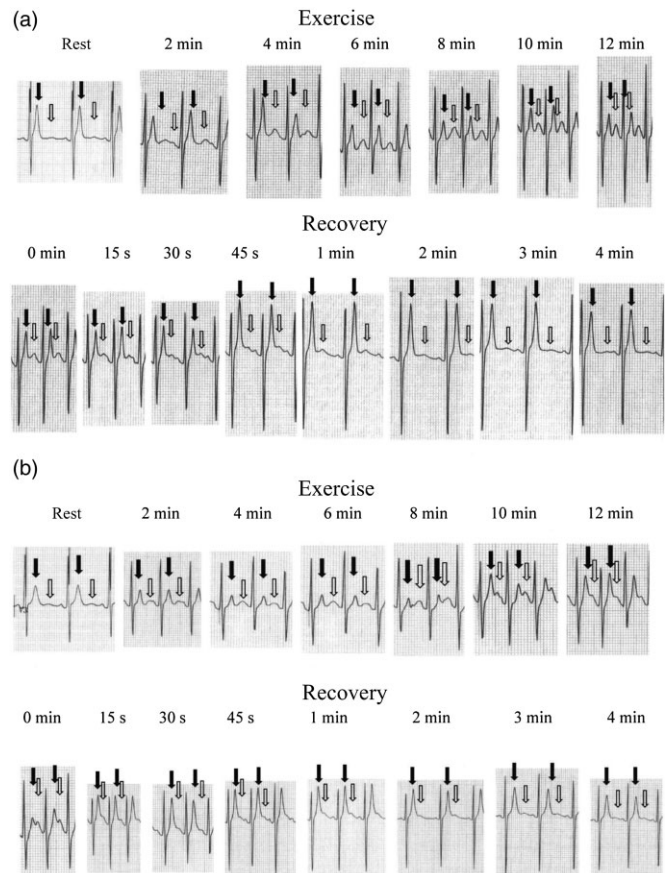


**Fig. 1** Bazett's formula was used to correct the QT interval for heart rate. White arrows, U wave. (a) Baseline 12-lead electrocardiogram (ECG) recording. The QT and QTc intervals are 260 and 283 ms, respectively. (b) Twelve-lead ECG on quinidine. The QT and QTc intervals are prolonged to 330 and 341 ms, respectively.

family history of sudden cardiac death, however, and the same mutation was observed in his mother. Exercise stress test before and after quinidine produced an electrically different response between the T wave and the U wave and suggested a mechano-electrical hypothesis of the U wave origin.

Short QT syndrome is a cause of unexpected sudden death in infants, children, and adolescents who show no evidence of structural heart disease, and the syndrome was first described by Gussak *et al.* in 2000.<sup>4</sup> Since that time, >60 cases have been reported, mainly from Western countries, and mutations were confirmed in six different genes.<sup>5</sup>

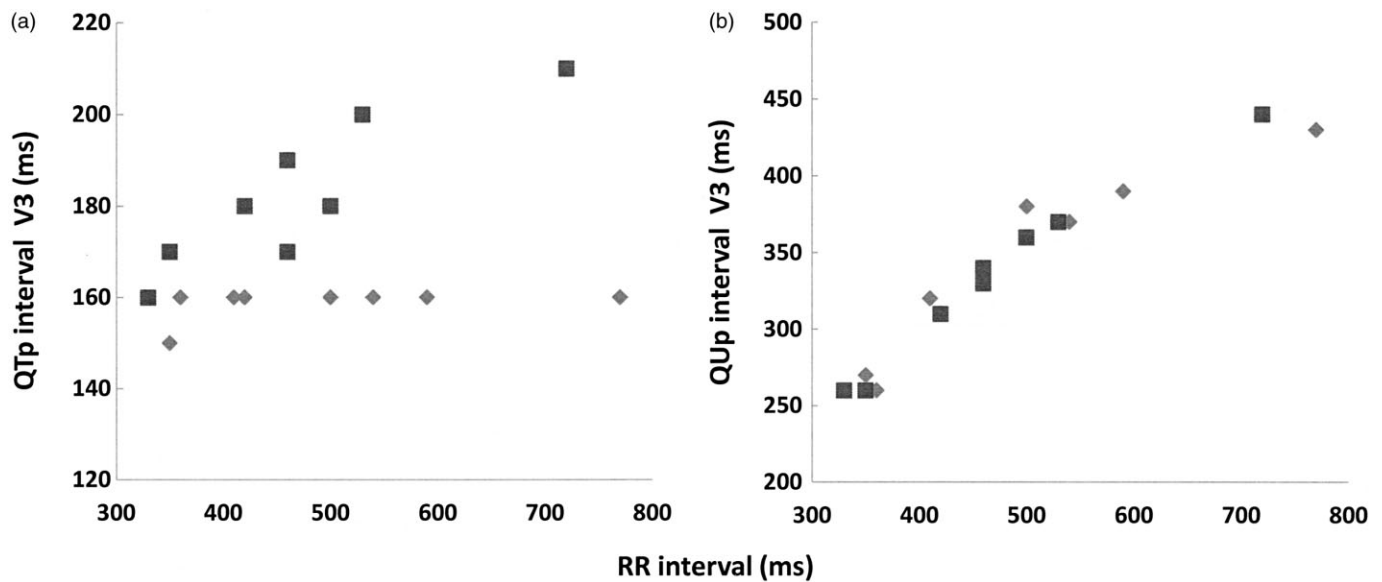
In the present case, short QT interval was observed in a screening program for heart disease. Although widely accepted criteria for diagnosis for SQTs are not available, a short QT interval on ECG indicates the diagnosis of SQTs. In the present case, the QT interval was extremely short. QTc is <300 ms in typical SQTs, similar to the present case, but QTc of 340–360 ms has also been reported. Large population studies have shown that the normal range of the QTc interval is within 350–450 ms for male subjects and 360–460 ms for female subjects.<sup>6</sup> Therefore, some experts recommend that QTc <360 ms is considered as a short QT interval.<sup>6</sup> SQTs need to be suspected in a child with a short QT interval on ECG, who has arrhythmia symptoms, AF/VF, and a family history of arrhythmic events, including sudden cardiac death. Physicians should be aware of short QT interval, as well as a long interval, during regular health check-up.



**Fig. 2** Electrocardiogram (ECG) lead V3 during the treadmill exercise test. Black and white arrows, T and U waves, respectively. (A) Baseline. The short QT interval is unchanged, whereas the QU interval is shortened. Additionally, the U wave becomes prominent and is fused with the P wave. (b) On quinidine. The U wave is encroached upon by the T wave because of a prolonged QT interval.

The N588K mutation in the *KCNH2* gene causes a gain of function of IKr, and shortens the action potential duration and the QT interval.<sup>3</sup> In SQTs, the QT interval does not shorten as normal during exercise, as found in the present case (Figs 2a,3a).<sup>7,8</sup> This is because the QT interval in a shortened state and the exercise-induced augmented slow component of the delayed rectifying potassium currents cannot shorten the QT interval any further. When IKr was inhibited by quinidine, the QT interval prolonged and shortened on exercise (Figs 2,3).<sup>8</sup> In contrast, the U wave is seen as separate from the T wave but the two waves became closer when the QT interval is prolonged by quinidine (Fig. 1). On exercise test, the QU interval was shortened, as in normal subjects. These different dynamics of the T wave and U wave indicate that the U wave is unrelated to the channelopathy in SQTs.

The genesis of the U wave is still controversial. Recently, Schimpf *et al.* found that the inscription of the U wave in SQTs patients coincided with aortic valve closure and isovolumic relaxation, and was unrelated to the T wave.<sup>9</sup> This finding would support the hypothesis that the U wave is related to mechanical stretch (= end of mechanical systole), but not to T wave (= ventricular repolarization).



**Fig. 3** Effects of quinidine on the relationship between (a) the QTp and (b) the QUp interval in lead V3 with RR interval. (a) The relationship between QTp interval and RR interval was weak at (◆) baseline, whereas there was a linear relationship between QTp interval and RR interval (■) after quinidine. (b) The linear relationship between the QUp interval and the RR interval at (◆) baseline was similar to that (■) after quinidine.

Given that the first clinical manifestation of SQTS can be sudden cardiac arrest,<sup>2</sup> ICD is indicated in SQTS patients. The present patient and his family, however, refused ICD therapy. The patient was discharged on quinidine after instruction on CPR and AED use was given to the family and the school staff.

### Conclusion

We need to pay attention to SQTS, which is associated with potential fatal arrhythmias. In the present case, the QT and QU intervals responded differently to heart rate changes, suggesting a mechano-electrical hypothesis for the origin of the U wave.

### References

- Giustetto C, Di Monte F, Wolpert C *et al.* Short QT syndrome: Clinical findings and diagnostic-therapeutic implications. *Eur. Heart J.* 2006; **27**: 2440–47.
- Giustetto C, Schimpf R, Mazzanti A *et al.* Long-term follow-up of patients with short QT syndrome. *J. Am. Coll. Cardiol.* 2011; **58**: 587–95.
- Brugada R, Hong K, Dumaine R *et al.* Sudden death associated with short-QT syndrome linked to mutations in HERG. *Circulation* 2004; **109**: 30–35.
- Gussak I, Brugada P, Brugada J *et al.* Idiopathic short QT interval: A new clinical syndrome? *Cardiology* 2000; **94**: 99–102.
- Templin C, Ghadri JR, Rougier JS *et al.* Identification of a novel loss-of-function calcium channel gene mutation in short QT syndrome (SQTS6). *Eur. Heart J.* 2011; **32**: 1077–88.
- Petel C, Yan GX, Antzelevitch C *et al.* Short QT syndrome: From bench to bedside. *Circ. Arrhythm. Electrophysiol.* 2010; **3**: 401–8.
- Anttonen O, Vaananen H, Junttila J, Huikuri HV *et al.* Electrocardiographic transmural dispersion of repolarization in patients with inherited short QT syndrome. *Ann. Noninvasive Electrocardiol.* 2008; **13**: 295–300.
- Wolpert C, Schimpf R, Giustetto C *et al.* Further insights into effect of quinidine in short QT syndrome caused by a mutation in HERG. *J. Cardiovasc. Electrophysiol.* 2005; **16**: 54–8.
- Schimpf R, Antzelevitch C, Haghi D *et al.* Electromechanical coupling in patients with the short QT syndrome: Further insights into the mechano-electrical hypothesis of the U wave. *Heart Rhythm* 2008; **5**: 241–5.