

Pathogenesis of Heterogeneity in Human Multinodular Goiter

A Study on Growth and Function of Thyroid Tissue Transplanted onto Nude Mice

Hans J. Peter, Hans Gerber, Hugo Studer, and Staffan Smeds

Department of Internal Medicine, University of Bern, Inselspital, CH-3010 Bern, Switzerland; Department of Surgery, University Hospital, S-581 85 Linköping, Sweden

Abstract

Functional and morphologic heterogeneity of human multinodular goiters was investigated in 300 samples from "cold" and "hot" regions of 20 goiters transplanted onto nude mice. Transplants were labeled with [³H]thymidine and radioiodine, while the host's thyroid-stimulating hormone (TSH) secretion was either stimulated or suppressed. Proliferation and function of follicular cells were assessed in whole follicles reconstructed from autoradiographs of serial sections.

Hot transplants had a higher autonomous iodine uptake than those of cold tissue in TSH-suppressed hosts. Functional autonomy widely varied among the follicles, but even more so among individual cells. Hot grafts differed from cold ones only by a comparatively larger fraction of autonomous cells. Intercellular differences of iodinating activity were not abolished by TSH.

Grafts faithfully reproduced the individual growth pattern of the original tissue. Between 0.5% and 7% of all follicular cells replicated despite suppression of TSH. Up to 70% of these cells were clustered, forming scattered foci of autonomously growing tissue. Other cells only started replicating after long-term TSH stimulation. Thus, goiters contained subsets of cells with high and others with low growth response. Progenies of replicating cells remained clustered, sometimes budding outwards to form new follicles.

Autonomy of growth and autonomy of function are independent traits of epithelial cells. Epithelial cells have their individual growth pattern, replication rate, and functional capacity. These traits are passed on from a mother cell to its progeny during follicle neogenesis. To this main mechanism accounting for the morphologic and functional heterogeneity of human goiters, inheritable modifications of gene expression must probably be added.

Introduction

The single most intriguing aspect of human multinodular goiter is the striking functional and morphologic heterogeneity among newly generated follicles (1–3). In previous studies on experimental goiters in animals, we have concluded that two entirely

Part of this study was presented at the 14th Annual Meeting of the European Thyroid Association, Rotterdam, The Netherlands, in September 1984 and was published as an abstract (1984. *Ann. Endocrinol. Paris* 45:81), and part was presented at the 9th International Thyroid Congress, Sao Paulo, Brazil, in September 1985.

Dr. Gerber is a Special Fellow of the Kamillo Eisner Stiftung, Heriswil, Switzerland.

Received for publication 19 June 1985.

J. Clin. Invest.

© The American Society for Clinical Investigation, Inc.

0021-9738/85/11/1992/11 \$1.00

Volume 76, November 1985, 1992–2002

different sets of mechanisms may account for part of this heterogeneity. On the one hand, changes of follicular function may result from the impact of environmental factors such as iodine supply (4, 5), failing blood supply in some areas of growing goiters (6), or aging of cell components (5). On the other hand, the generation of new follicles from genetically different cells of the mother follicle was shown to be a second, basically different mechanism that generates heterogeneity among the newly formed follicles (3). However, these two processes cannot possibly account for all characteristics of morphologic and functional variegation observed in human nodular goiters. Among the still unexplained features are regionally variable metabolic abnormalities (7), abnormal growth patterns, and the appearance of autonomy of growth and of iodine metabolism in many goiters.

Serial studies on human goiters have so far been severely limited by the lack of animal models reproducing the growth pattern of human nodular goiters. This difficulty has recently been overcome in that human thyroid tissue can now be grown through transplantation onto nude mice (8–11). Moreover, because human tissue is sensitive to mouse thyroid-stimulating hormone (TSH),¹ growth and function of goiter transplants can be studied in the presence and absence of stimulators such as TSH.

The investigations reported here are aimed at providing insight into the mechanisms that amplify—during the process of transformation of the normal human thyroid into a nodular toxic or nontoxic goiter—the natural heterogeneity of the normal thyroid epithelium and create new morphologic and functional diversity among the follicular cells. In particular, the study of human goiter growth in host mice should allow to clearly distinguish between inborn and environmental mechanisms.

Methods

Thyroid tissue from 20 patients with multinodular goiters and from one patient with neoplastic disease of the larynx, undergoing thyroid surgery, was transplanted onto 150 nude (nu/nu) ICR mice, kept under pathogen-free conditions in a 12-h light, 12-h dark cycle. The animals were fed with cereal-based mouse breeding diet (Nafag AG, Gossau, Switzerland) sterilized by irradiation with 2.5 megarads.

Transplantation procedure. Thyroid tissue surgically removed from the patient was immediately immersed into ice-cool Eagle's minimal essential medium containing 100 IU of penicillin and 100 µg of streptomycin per ml (Serva, Feinbiochemica, Heidelberg, Federal Republic of Germany). Specimens selected for transplantation were cut into fragments measuring about 3 × 1 × 1 mm. Three fragments were grafted subcutaneously under the skin on each side of the vertebral spine. Goiter specimens from scintigraphically hot goiter areas were implanted on the left, specimens from cold goiter areas on the right side.

Labeling with [³H]thymidine, ¹²⁵I, and ¹³¹I. To study the impact of host TSH suppression and TSH hypersecretion on iodine metabolism

1. *Abbreviations used in this paper:* FLC, fraction of [³H]thymidine-labeled cells; MMI, methimazole; PAS, periodic acid-Schiff; T4, L-thyroxine; TSH, thyroid-stimulating hormone.

and growth, animals grafted 3–8 wk previously with tissue from a single goiter, were divided into two groups, each including three to five animals. Subsequently, group I received L-thyroxine (T4) (Fluka AG, Buchs, Switzerland) 0.5 µg/ml in its drinking water, resulting in a daily T4 intake of ~2.5 µg per animal, whereas, for group II, methimazole (MMI) (Fluka) 0.075% and sucrose 1% were added to the drinking water. The goiter transplants of additional animals remaining untreated, were processed for histologic examination only.

Proliferating cells were labeled by injecting [³H]thymidine (New England Nuclear, Boston, MA, specific activity 15 Ci/mmol) i.p. three times daily for 2 wk, beginning 1 wk after initiation of the different feeding regimens. In one experiment comprising eight animals, [³H]thymidine was administered continuously by means of miniosmotic pumps (Alzet model 2001, Alzo Corp., Palo Alto, CA) implanted into the peritoneal cavity. In experiments involving labeling with ¹²⁵I or ¹³¹I, MMI treatment (group II) was stopped 2 d before iodine administration, whereas the T4 feeding (group I) was continued. For investigating iodine metabolism in transplants concomitantly labeled with [³H]thymidine, 50 µCi of ¹³¹I were injected intraperitoneally 1 h before sacrifice by chloroform anesthesia. Animals not labeled with [³H]thymidine but otherwise identically treated were given ¹²⁵I because of its more suitable autoradiographic properties.

The transplants were carefully freed from adjacent connective tissue and weighed before fixation. ¹²⁵I and ¹³¹I uptake were measured in a gamma counting system (MR 480, Kontron, Zürich, Switzerland) and calculated per milligram of transplant weight.

Histologic and autoradiographic procedures. Tissue fixed in 4% phosphate-buffered formaline, pH 7.4, was dehydrated in a series of alcohols and embedded in methacrylate (JB-4 embedding mixture, Polysciences Inc., Warrington, PA). For autoradiography, series of up to 40 3-µm sections per transplant were mounted on glass slides, dipped in Kodak NTB-2 nuclear emulsion (Eastman Kodak Co., Rochester, NY) and, after appropriate exposure times, developed with Kodak D-19 developer. A mean of 30 serial sections were then counterstained with nuclear fast red, and additional sections were stained with periodic acid-Schiff (PAS). In order to correlate iodine organification of the follicles with cell proliferation, tissue specimens double-labeled with ¹³¹I and [³H]thymidine were processed as follows: all odd-numbered sections of a series were processed immediately for ¹³¹I-autoradiographs, whereas the even-numbered sections were dipped 4 mo later for [³H]thymidine autoradiography. At that time ¹³¹I radioactivity had virtually disappeared. Tissue specimens labeled with [³H]thymidine or ¹²⁵I alone were processed without delay.

Because the grain density in identically exposed autoradiographs directly reflects the relative amount of radioactive iodine organified, semi-quantitative autoradiography could be done on sections from the left- and the right-sided transplants grown in the same animal. In the same way, the relative radioactivity of transplants from goiter samples derived from the same patient but growing in differently treated animals was compared.

Assessment of the fraction and the distribution pattern of [³H]thymidine-labeled follicular cells within a transplant. In transplants labeled with [³H]thymidine, 20 cell groups from different regions were evaluated, each group comprising 100 follicular cells. Cells containing five or more silver grains per nucleus were considered as labeled. The fraction of labeled cells (FLC) of a transplant is given as the mean value of the 20 samples.

To determine whether or not the distribution of the labeled cells among the sample groups corresponded to a random distribution, χ^2 testing was applied according to Riedwyl (12).

The pattern of distribution of the labeled cells within the shell of individual follicles was investigated by reconstructing entire follicles from contiguous serial sections by means of a projection microscope (Visopan, Reichert-Jung, Vienna, Austria).

Results

Histologic structure of the original goiter and its growing transplant. Out of the 300 transplants examined, 250 contained well-

preserved thyroid tissue whereas 50 transplants consisted predominantly of scarred connective tissue and were therefore excluded from further investigation. The histologic pattern of grafts from multinodular goiters grown in untreated mice was usually indistinguishable from that of the mother tissue obtained at surgery. In other words, solid mother tissue also grew in a solid pattern after transplantation, whereas transplants derived from microfollicular goiter tissue still consisted of tiny follicles. Eventually, large follicles predominated in transplants from macrofollicular tissue (Fig. 1).

In grafts from normal thyroid tissue and in those from colloid goiters grown in MMI-treated hosts, the majority of follicles were lined by epithelial cells with columnar shape and contained thin, faintly PAS-staining colloid. Occasional follicles were surrounded by flat epithelial cells and contained strongly PAS-positive colloid, suggesting unresponsiveness to TSH. The shell of a few follicles consisted of a mosaic of both columnar and flat epithelial cells arranged in clusters, indicating that morphologically responsive and unresponsive cells may coexist in the same follicle.

In grafts from T4-treated mice, follicles with flat epithelia containing intensely PAS-stained colloid were predominant. Thus, human goiter tissue responds to endogenous mouse TSH by characteristic structural changes (Fig. 2).

Effects of T4- and MMI-treatment on proliferation of follicular epithelia. T4 treatment in doses known to suppress host mouse TSH secretion (13) did not entirely suppress cell proliferation within the transplanted follicular epithelia. The size of the FLC in transplants derived from goiters exposed to [³H]thymidine for 2 wk ranged from a minimum of 0.5% in transplants from euthyroid nodular goiter to 7% in transplants from a steadily growing goiter of a thyrotoxic patient (Fig. 3). Large variations were observed between transplants taken from different regions of the same goiter.

Extending the duration of MMI treatment before [³H]-thymidine administration increased the FLC within the follicular epithelium in a time-dependent manner. An example is given in Fig. 4.

Regional variation of TSH-independent and TSH-mediated goiter growth. In transplants growing in mice with T4-suppressed TSH secretion, the number of labeled cells per 100 follicular cells varied among the different regions of the same transplant from 0 to 20. Similar regional variations were observed in transplants growing in animals with MMI-induced TSH hypersecretion. χ^2 testing ($P < 0.001$) confirmed the optical impression that the labeled cells were not randomly distributed among the sampled regions of a given transplant. Very dense clustering of labeled cells in a few distinct regions strongly suggested that some goiter areas display an exceedingly high propensity to proliferate.

Lack of correlation between cell morphology and replicating potential. Tall cuboidal or columnar cells may remain unlabeled, whereas entirely flat epithelial cells may readily incorporate the [³H]thymidine label (Fig. 5). Thus, the claim widely propagated in the literature that flat epithelial cells are inactive should not only be abandoned for iodine metabolism (1) but also for cell proliferation.

Distribution of the [³H]thymidine-labeled cells within the follicular shell. Three-dimensional reconstruction of follicles from contiguous serial sections across entire transplants from T4-treated animals containing a FLC ranging from 0.5% to 2% revealed that up to 70% of all cells within sets of 500

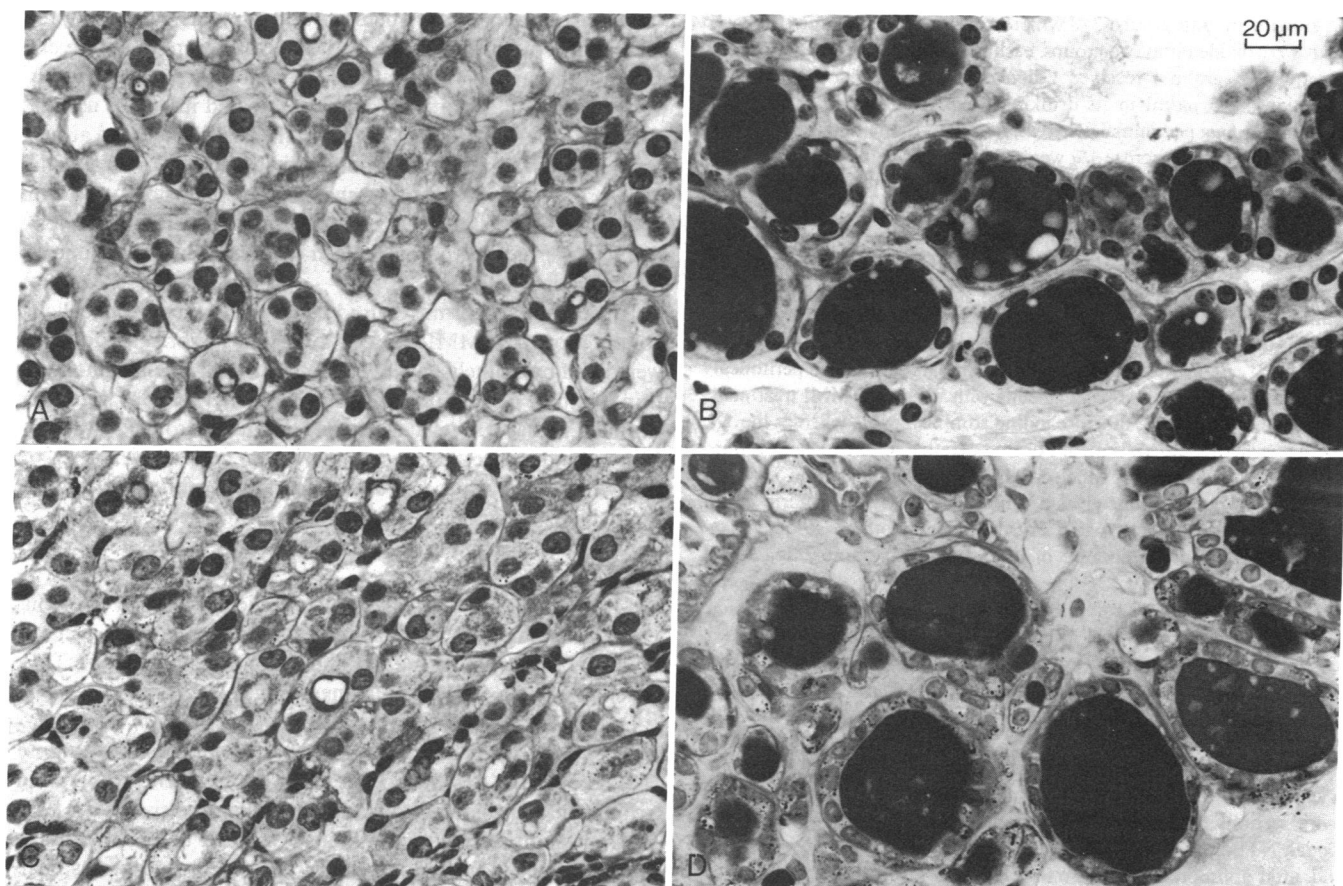


Figure 1. Two different specimens of human goiter tissue displaying a microfollicular (A) and a normofollicular growth pattern (B). The histologic appearance of the corresponding transplant (C and D) 8 wk af-

ter transplantation onto a host mouse is nearly indistinguishable from that of the original tissue (A and B).

[³H]thymidine-labeled cells were arranged in contiguous clusters comprising between 4 and 40 cells. Five sets of 500 labeled cells in five different transplants were evaluated.

In a few individual follicles of transplants growing in T4-treated mice, nearly all cells were labeled whereas the large majority of all follicles did not contain any labeled cells at all.

In follicles of MMI-treated transplants, the [³H]thymidine-labeled cells were much more numerous than in the T4-treated counterparts (Fig. 3). Again, they strongly tended to form coherent irregularly shaped patches whereas large parts of the follicular shell contained no labeled cells at all. A true-to-nature reconstruction of a labeled follicle is depicted in Fig. 6. The present observations in human goiter tissue are in full agreement with an earlier report on experimentally produced mice goiters (3).

The findings indicate that all cells of the follicular epithelium do not possess the same intrinsic growth potential, but that there are subsets of cells with a much higher than average inborn propensity to proliferate. The growth advantage appears to be conveyed from mother to daughter cells, in that the newly generated cells closely stick together to form large families (Fig. 5-7).

Other [³H]thymidine-labeled organs than the thyroid gland were also examined in all mice, including esophageal and tracheal epithelium, salivary glands, liver, adrenal glands, and kidney. No convincing evidence for cluster formation of dividing cells

was found so far except perhaps for the adrenal cortex and the renal tubular epithelium (Peter, H. J., unpublished observation).

In some follicles the proliferating cells formed papillary structures, protruding into the lumen. The underlying connective tissue also contained many [³H]thymidine-labeled cells. In other follicles, replicating cell clusters formed sprouting cell buds protruding toward the interstitial space in much the same way as previously described in experimentally produced mice goiters (Fig. 7) (3). Serial sections of radioiodine-labeled or PAS-stained transplants often revealed tiny lumina within these buds, indicating that they are the early stages of new follicles.

Interfollicular and intercellular heterogeneity of iodine organification in suppressed follicles. Residual iodine organification remaining after TSH suppression as widely varied among different follicles as that observed in autoradiographs of human goiters labeled in vivo (3). A regionally variable fraction of all follicles displayed high autonomous iodine uptake, whereas other follicles had intermediate or low uptake.

Serial sections autoradiographed before ¹²⁵I had dissipated throughout the colloid revealed that the autonomy of iodine organification is a trait of single cells or cell groups rather than a property of the entire follicle, and that cells with an identical degree of autonomous iodinating capacity form coherent families within the follicular wall, reminding of what had been demonstrated for cells with a common growth pattern (Fig. 8). Transplants from scintigraphically hot goiter nodules contained a

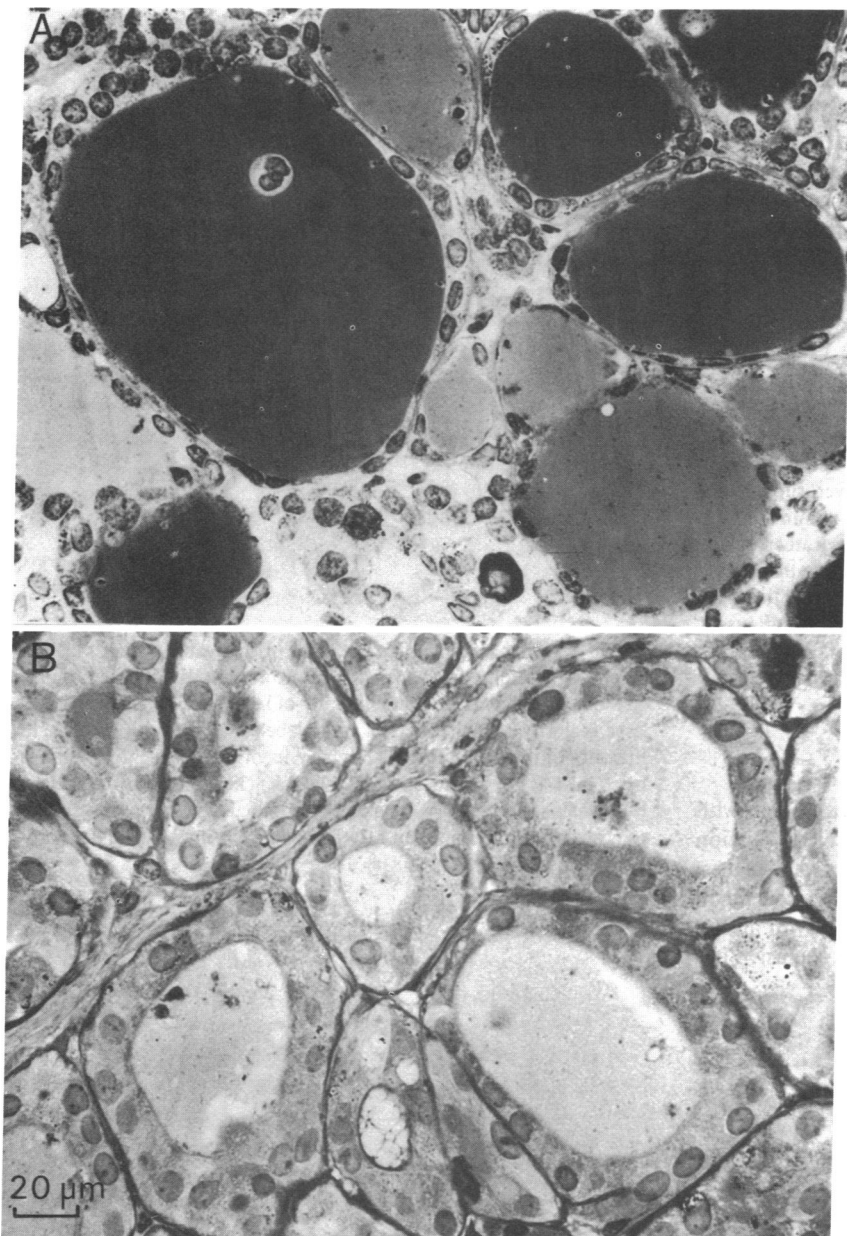


Figure 2. Two transplants derived from the same euthyroid multinodular goiter. Transplant *A*, grown in a thyroxine treated host, is built up by follicles lined by flat epithelial cells and containing abundant, strongly PAS-positive colloid. In contrast, transplant *B* grown in a MMI-treated animal contains mostly follicles surrounded by a columnar epithelium and colloid which stains only weakly for PAS. These micrographs illustrate the structural response of human goiter tissue to variations of mouse TSH secretion.

higher number of autonomously functioning follicles than those of cold nodules or from normal tissue grown in the same animal (Fig. 9). This purely quantitative characteristic was the sole and only difference that could be observed between a transplant grown out of cold mother tissue and that generated by a sample from a hot goiter nodule. In confirmation of previous observations in human goiters labeled *in vivo*, no consistent structural differences were detected between goiter tissues with genuinely high or low iodine turnover (1-3, 15).

Stimulation of the host's TSH secretion by MMI treatment strikingly increased radioiodine organification not only in the transplants derived from hot nodules but also in those taken from cold goiter nodules (Fig. 10). Therefore, both tissues were responsive to TSH. There were, however, a few follicles even in TSH-stimulated goiters that remained almost entirely cold. These follicles may be the human counterpart of the irreversibly cold follicles arising in the aging mouse thyroid through gradual failure

of endocytosis (5). The large differences of ^{125}I uptake between the individual follicles of hot as well as between those of cold transplants growing in T4-treated animals were invariably diminished by TSH stimulation, but they were never completely abolished. This observation suggests that the range of TSH responsiveness is similar in cold and hot follicles, but that the lowest intrinsic activity remaining after TSH suppression is individually different.

Correlation of follicular growth and follicular function. In goiter grafts grown in T4-suppressed hosts, [^3H]thymidine-labeled cells were present in follicles with high as well as in those with low ^{131}I uptake (Fig. 11). There was no correlation between a high replication rate of a given cell cluster and its ^{131}I uptake. Some hot follicles contained numerous labeled cells, whereas in other, identically hot follicles, only a few or no replicating cells were found. The lack of correlation between autonomous growth and autonomous function was confirmed in cold follicles and

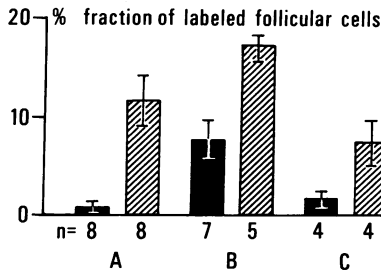


Figure 3. Effects of T4 and MMI treatment on proliferation of the follicular epithelium. This figure shows the effects of T4 (■) and MMI (▨) treatment on the fraction of labeled cells (FLC) in transplants derived from a normal thyroid (A), a toxic nodular goiter (B), and a euthyroid multinodular goiter (C), labeled with [³H]thymidine for 2 wk. In all MMI groups, the FLC is higher than in the corresponding T4-treated counterparts. This proves that mouse-TSH does in fact stimulate cell proliferation of the human follicular epithelium. However, suppressive T4 treatment does not completely abolish proliferation within the follicular epithelium neither in normal nor in goiter tissue. Rather, some cells proliferate autonomously in the absence of TSH. Note that in goiter B the fraction of autonomously dividing cells is several times higher than in the normal gland albeit with wide regional variations. The fraction of autonomously replicating cells is independent of the function of the mother tissue. Bars represent mean±SEM. n = number of transplants.

in follicles with intermediate iodine uptake. Therefore, cells with a high degree of autonomy of iodine uptake and organification are not necessarily identical with those proliferating at the highest rate. On the other hand, some cells of multinodular goiters might be autonomous in both respects. Autonomy of growth and of iodination are independent, albeit not mutually exclusive cell properties (Fig. 11).

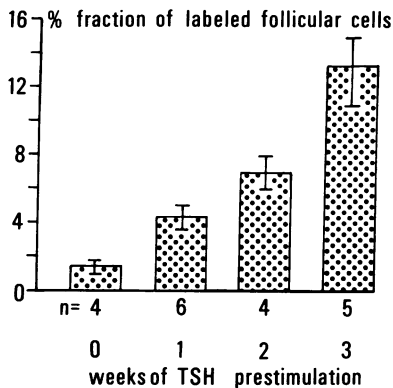


Figure 4. Effect of duration of MMI treatment preceding [³H]thymidine labeling. The fraction of proliferating cells in transplants of this euthyroid multinodular goiter increases with the duration of TSH stimulation preceding initiation of [³H]thymidine administration. Transplanted samples of the same goiter were labeled with [³H]thymidine for 2 wk. Group 1 was treated with T4; in groups 2, 3 and 4 MMI treatment was started 1, 2, and 3 wk, respectively, before initiation of [³H]thymidine labeling (n = number of transplants per group). Bars represent mean values±SEM. For calculation of the fraction of labeled cells, see Methods. With increasing stimulation time, more cells are recruited out of the G₁-pool to enter the mitotic cycle.

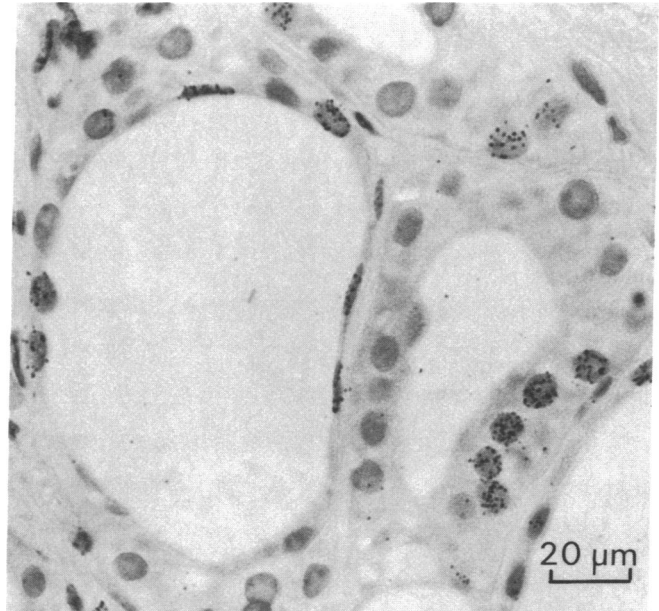


Figure 5. Goiter transplant grown in an MMI-treated animal labeled with [³H]thymidine for 2 wk. The follicle at right, lined by columnar epithelial cells, contains a small family of labeled cells, whereas the large majority of follicular cells are unlabeled. In the follicle at left, the majority of the flat epithelial cells have incorporated the thymidine label. This was confirmed on serial sections. Thus, there is no correlation whatsoever between the shape of a follicular cell and its response to growth stimulation. Even extremely flat cells may have a high propensity to replicate.




Figure 6. Model of a follicle from a transplant, grown for 6 wk in an MMI-treated animal labeled with [³H]thymidine for 2 wk, reconstructed from a complete set of 32 contiguous serial sections. The proliferating cells (darkly colored) are not scattered randomly throughout the follicle but rather form large cohorts, whereas large areas of the follicular shell contain only resting cells (lightly colored). This distribution pattern suggests the presence of subpopulations with distinctly different sensitivity to growth stimuli.

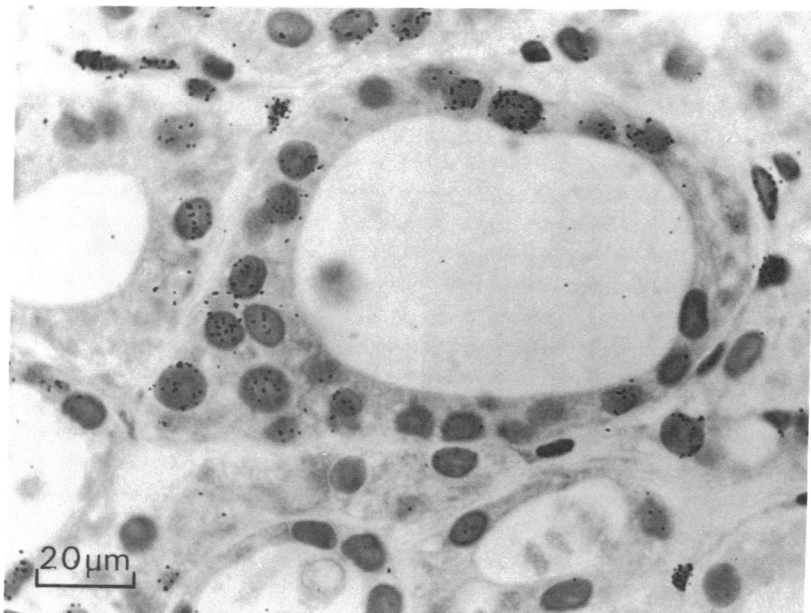


Figure 7. Follicle in a human goiter transplant, grown in a MMI-treated host mouse and labeled with [^3H]thymidine for 2 wk. One family of heavily labeled cells forms a solid bud which protrudes out of the follicular wall. As in mouse goiters (3), the bud is considered to be an early stage of new follicle formation.

These observations were confirmed in [^{131}I]- and [^3H]-thymidine-labeled thyroid tissue grown in MMI-stimulated mice. Again, follicles with a high iodine uptake did not necessarily contain a large fraction of dividing cells, and follicles with a low [^{131}I] uptake were associated with either a large, intermediate or low fraction of [^3H]thymidine labeled cells. Findings such as those illustrated in Fig. 11 suggest that TSH stimulation does not affect growth and function in all follicular cells to the same extent. Rather, some cells tend to respond predominantly with an increase of iodine uptake and iodine organification, whereas others more readily enter the mitotic cycle. Some cells are able to respond with both functions to the same extent.

Discussion

Previous studies in animals and in surgically removed human goiters labeled preoperatively with [^{125}I] had disclosed two basically

different mechanisms involved in the pathogenesis of the intriguing heterogeneity of growth and function characterizing this thyroid disease (1, 2). One mechanism was the generation of new follicles from single cells of an epithelium that is in itself composed of cells from multiple, nonidentical subpopulations (3), and the other was the impact of environmental factors interfering with follicular function during goiter growth (4, 5). Among the local factors causing heterogeneity of goiter growth are, e.g., the focal necroses subsequent to the failure of the capillary sprouts to adequately supply newly formed follicles. The dead tissue is gradually transformed into fibrous scars forcing a nodular growth pattern upon the expanding follicle population (6). Another local process is the slow transformation of normally functioning follicles into irreversibly cold ones in aging mice thyroids (5). Eventually, the amount of iodine available during goitrogenesis is increasingly recognized to have a crucial impact not only on TSH secretion but also on the size and the function

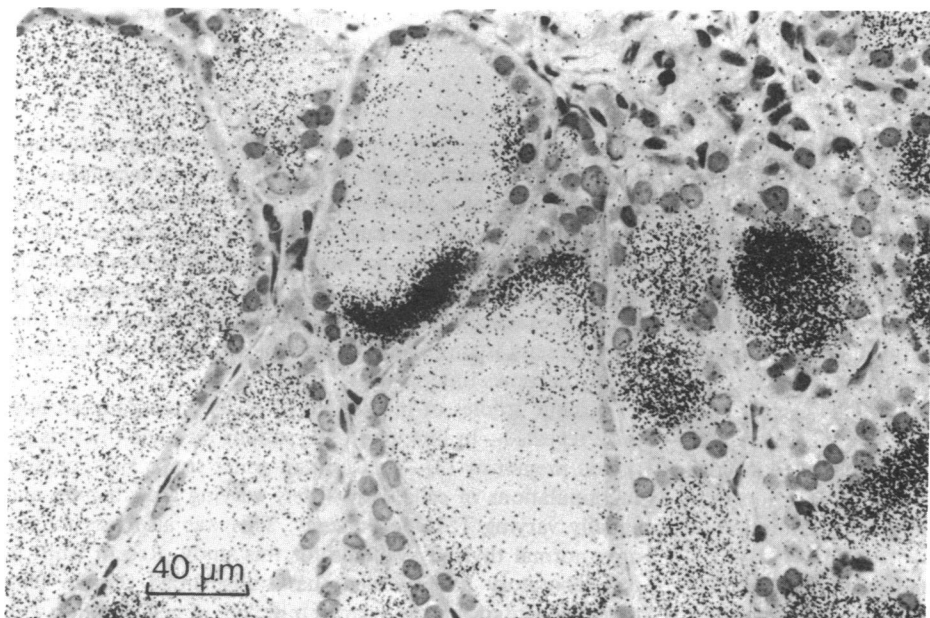


Figure 8. This autoradiograph of a goiter transplant grown in a T4-treated animal and labeled with [^{125}I] for 1 h shows that autonomous iodine organification is not a property of the follicle as a whole but rather of single cells or cell groups within the follicular wall. All hot and cold cell families shown in the figure were followed on serial sections. Some of them extended over large areas of the follicular shell. The striking differences of autonomous iodine organification among different subpopulations of goiter epithelial cells may be masked by the rapid colloid mixing (14) appearing, e.g., in some follicles shown at right and at left in the figure.

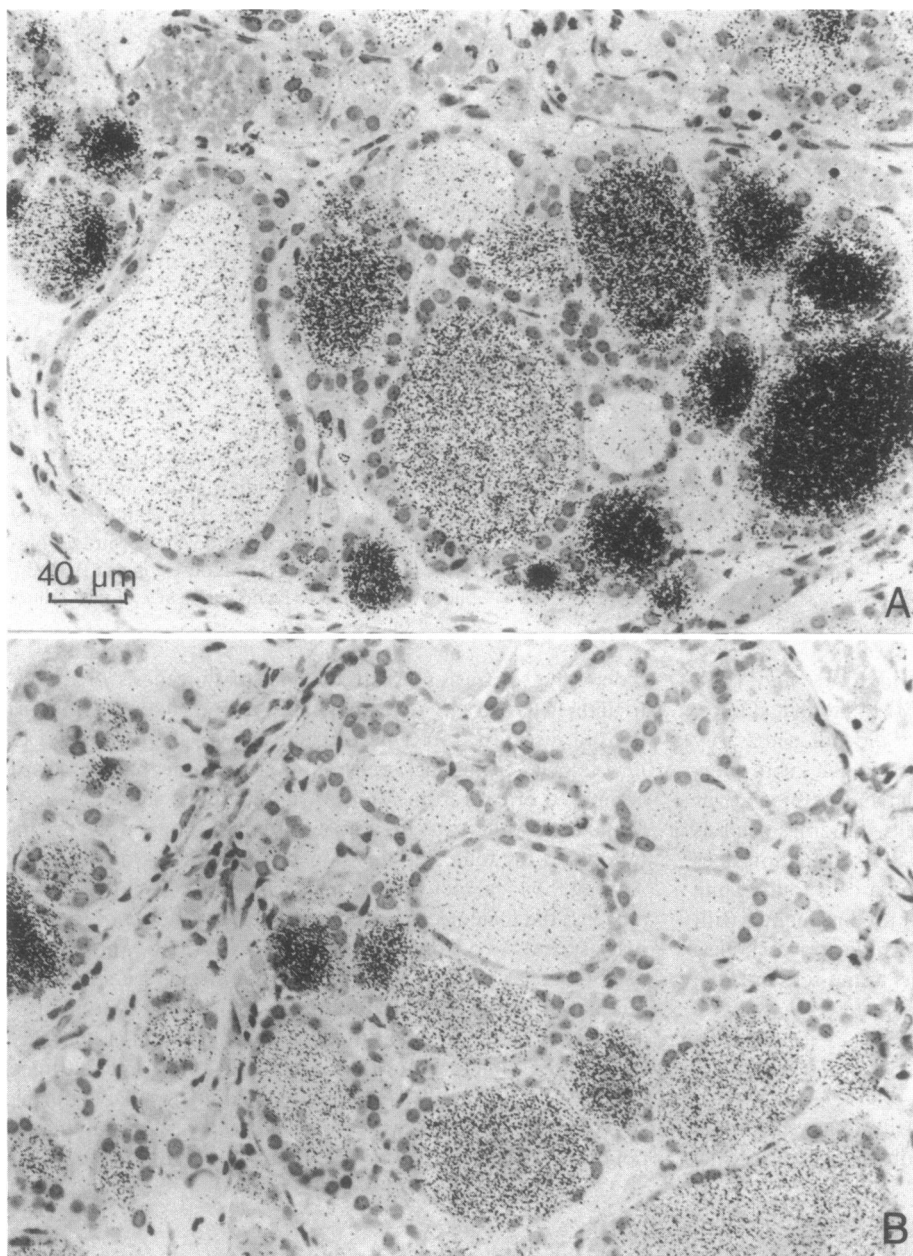


Figure 9. (A) An autoradiographed transplant derived from a scintigraphically hot goiter area, labeled with ^{125}I for 1 h while mouse TSH was suppressed by T4 treatment. Follicles with a high capacity for autonomous iodine organization are predominant, but follicles with low or intermediate uptake are still present. (B) Transplant taken from a scintigraphically cold area of the same goiter. Because it grew in the same animal and was exposed under identical conditions, the density of the silver grains indicates the relative uptake of ^{125}I by each follicle. Follicles with low autonomous iodine organization are now predominant, but a minority of follicles is highly active. Note, incidentally, that hot and cold follicles are morphologically indistinguishable.

of individual follicles (5, 16). It could, however, altogether not be expected that the interplay of these mechanisms could explain all characteristics of heterogeneous human goiters, in that this tissue displays qualities not found either in normal thyroid tissue nor in other types of goiters (1, 2, 15, 17, 18). As examples, the widely variable but frequently unique growth pattern of human nodular goiters, the regionally differing pattern of cell proliferation and iodine turnover, the dissociation of growth and of function familiar from scintigraphic investigations (19, 20), and the topographically variable abnormalities of TSH-cyclic AMP coupling (7) called for dynamic studies on human goiters and for confirmation and extension of previously obtained animal data. Such studies became feasible with the introduction into experimental thyroidology of the method of transplantation of human tissue onto nude mice (8–11).

Using this technique, we demonstrate here that a particular growth pattern of the parent tissue is faithfully reproduced by

the growing transplant. It therefore appears that an individual mode of growth such as solid, microfollicular, or macrofollicular tissue structure of a goiter does not depend mainly on the microenvironment of this tissue, but is rather an acquired quality of the epithelial cells that has become heritable and is passed on to their progeny. Because goiters growing from transplants in mice are exact replicas of the parent tissue, the old claim that heterogeneity is simply due to variable access of cells to blood supply becomes untenable.

Kinetic studies of the growth of goiter transplants in host mice revealed—in line with observations on mice thyroids reported previously (3)—that human goiter tissue also contains subpopulations of cells with widely varying growth rates and equally varying TSH dependency. This was also true for the only normal thyroid available for this study. Recent work in this laboratory has revealed that transplanted human fetal thyroids contain an even larger number of cell families with

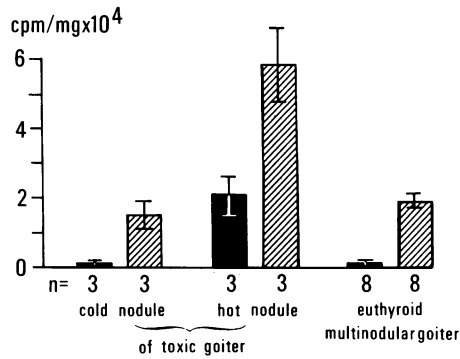


Figure 10. Effects of T4 (■) and MMI (▨) treatment on ¹³¹I uptake of human goiter transplants. MMI was given for 3 wk and stopped 48 h before ¹³¹I injection. MMI treatment increases ¹³¹I uptake in all transplants irrespective of whether they are derived from hot, cold, or intermediately active goiter tissue, as compared to T4 treatment. This indicates that human thyroid iodine metabolism is in fact sensitive to mouse TSH and that neither hot nor cold tissue is refractory to TSH. The only detectable difference between hot and cold tissue was the much higher TSH independent, autonomous, i.e., insuppressible iodine turnover of the hot tissue. Bars represent means ± SEM of counts per minute per milligram of transplanted tissue; n = number of transplants.

short replication time than any adult tissue (Peter, H. J., unpublished observation). Three-dimensional true-to-nature reconstruction of follicles from contiguous serial sections reveal that the rapidly replicating cells are not randomly distributed throughout the thyroid, but that they form colonies of adjacent cells within the follicular shell. These colonies usually have a large central body with protrusions reaching far into the follicular shell, while extended adjacent regions of the same follicle do not contain any labeled cells at all (Fig. 6). The number of cell colonies with identical labeling patterns, and therefore with similar growth rates, strikingly increased in parallel to the time of previous TSH stimulation (Fig. 4).

In TSH-suppressed mice, only an occasional follicle contained a cluster of [³H]thymidine labeled cells, comprising anything from more than three to up to several dozen replicating cells. In a few instances, nearly all cells of a single, lonely follicle were labeled whereas up to 90% of all other follicles did not contain any replicating cells on serial sections.

It is well known that cells of whatever origin in tissue culture have widely varying growth rates, too (21). We believe that the rapidly multiplying cell clones previously observed in normal mouse thyroids (3) and now in human goiter transplants reflect the same phenomenon within a cell population growing in vivo. Very recently, Westermarck et al. (22) have demonstrated the variability of follicular growth response to epidermal growth factor (EGF) in tissue culture.

The gradual increase of the fraction of labeled cells with the duration of previous TSH stimulation (Fig. 4) indicates that the thyroid contains a continuum of cell subsets with individual thresholds for growth stimuli. Vigorous stimuli, such as those resulting from the growth stimulating immunoglobulins of Graves' disease or from highly dosed thyrostatic agents in experimental goiters may eventually bring most, if not all cells into the mitotic cycle (1, 3). Less intense stimuli, such as those producing slowly growing human nodular goiters (23), may induce preferential multiplication of only those cell clones with a high intrinsic propensity for replication. They are responsive to

the most subtle stimuli or may even divide in their absence. These autonomously growing cells, once generated in large enough number, may account for the autonomous goiter growth that is well known to occur in many long-standing human goiters. The exceedingly high sensitivity of some thyroid cells to divide also explains why growth, but not simultaneous morphologic or functional stimulation, is an invariable hallmark of slowly developing human goiters caused by weak, chronically acting goitrogens (23–25). Moreover, uneven tissue growth is but another factor producing the invariable nodularity of long-standing human goiters (1, 6).

Newly generated follicular cells may be integrated into the growing goiter in one of three ways. First, they may help enlarging the shell of the mother follicle (Fig. 6) or second, they may form papillary protrusions into the follicular lumen (not illustrated here). Third, eventually they may grow out of the mother follicle to form new daughter follicles (Fig. 7) (3). This process, first demonstrated for the mice thyroid (3), is probably the basic event in goitrogenesis (1).

In addition to growth, we also studied the function of goiter transplants in terms of radioiodine turnover. Many previous conclusions (1, 2, 4, 17, 18) drawn from observations in mouse and rat thyroids and in human goiters prelabeled with ¹²⁵I were confirmed. In fact, no difference between goiters growing naturally in patients and those transplanted onto nude mice could be observed. For example, a low basal level of radioiodine turnover after TSH suppression varied enormously among different follicles of a transplant (Fig. 9) and even more so between two transplants from different regions of a goiter. No morphologic differences between a hot and a cold follicle could be defined, nor was there any consistent structural difference between transplants from scintigraphically hot and cold goiter areas. Transplants from both hot and cold nodules contained follicles with widely varying individual function just as reported for the parent tissue (1, 2, 17, 18). However, samples from areas with high autonomous iodine turnover contained a larger fraction of hot insuppressible follicles and their residual radioactivity was, on the average, higher than in follicles from poorly functioning nodules.

Using short-term labeling with ¹²⁵I, we found that many goiter follicles contained cell cohorts with widely differing iodinating potency. This intrafollicular heterogeneity had previously been seen in mice (3, 5, 26–28) and had occasionally been described in human goiters (3, 15). The phenomenon has recently been observed in tissue culture by Errick et al. (29). The number of cells with intense, autonomously functioning iodination may greatly vary from one follicle to the next. This observation suggests that, in contrast to traditional views (15), the degree of autonomous iodine turnover is not a quality of the follicle as a whole, but rather depends on the relative fractions of hot and cold cells building up its epithelium. Moreover, in that new follicles are generated from one or a few dividing cells within the mother follicle, the individual intrinsic iodine turnover of the parent cell primarily decides whether the daughter follicle has a high or low iodine turnover (3). Again, the individual iodinating capacity of epithelial cells appears to be a stable, inheritable trait.

Rather unexpected was the high responsiveness of cold as well as of hot follicles to TSH, although TSH responsiveness of hot and cold nodules has been reported earlier (30, 31). A clear-cut difference of iodine metabolism between hot and cold tissue was, however, still apparent after TSH stimulation. This suggests

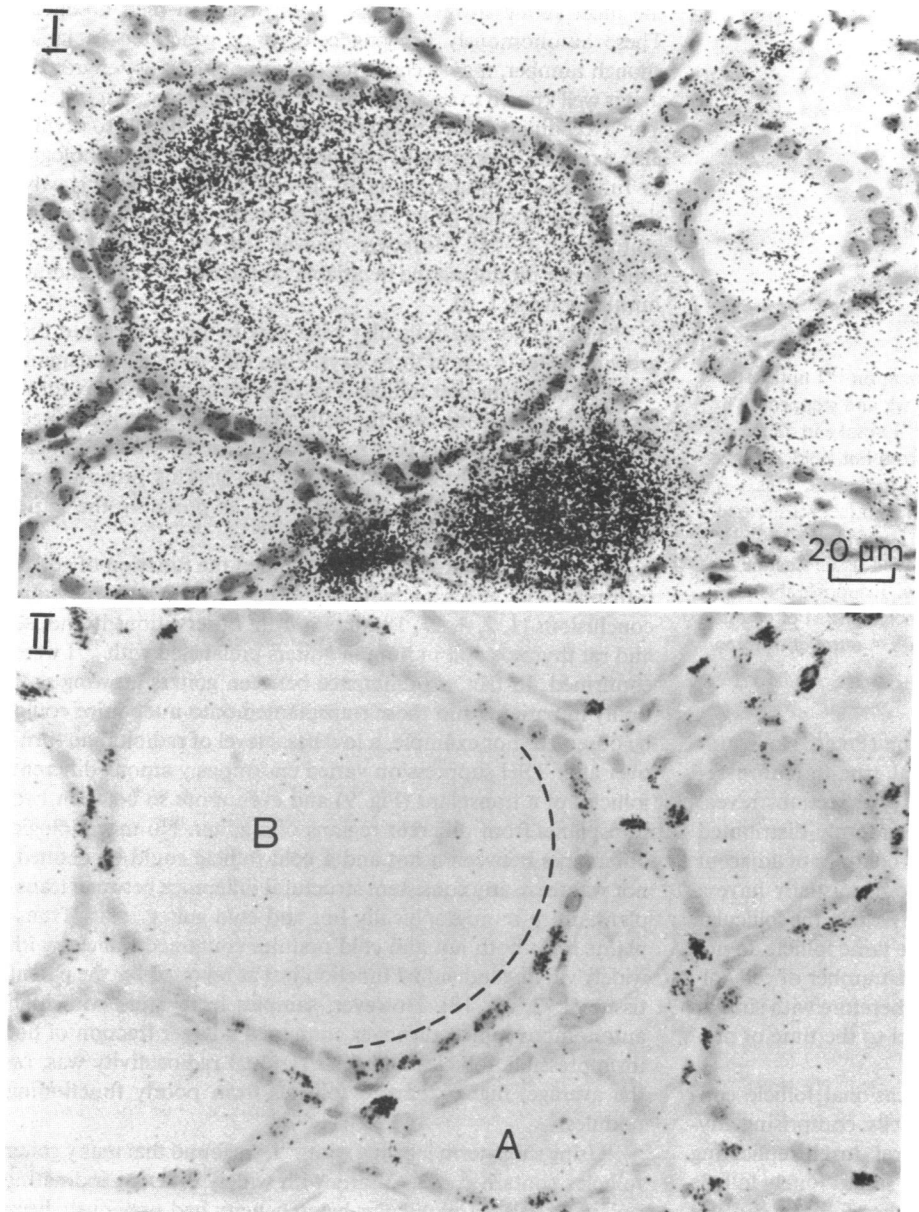


Figure 11. Transplant labeled with [^3H]thymidine for 2 wk and with ^{131}I for 1 h before sacrifice while the host's TSH was suppressed by T4 treatment. Section I autoradiographed without delay shows iodine organification; section II, exposed 4 mo later, i.e., after decay of ^{131}I , shows [^3H]thymidine incorporation. Follicle A displays the highest autonomous capacity for iodine organification but contains only a few proliferating cells. In follicle B, the ^{131}I -labeled thyroglobulin has not spread homogeneously (confirmed on serial sections). Only a very few of the highly iodinating cells at the upper left circumference have incorporated the thymidine label whereas most of the less active cells (dotted line) are labeled. Thus, autonomy of iodine metabolism of the follicular epithelial cells does not parallel their potential to proliferate autonomously.

that the range of increased radioiodine uptake after TSH stimulation is comparable in both types of follicles, but that the baseline activity is different. The observations are compatible with two alternative explanations: Either the fraction of truly hot cells in a given follicle is indeed entirely autonomous and unresponsive to TSH, while the remaining normal cells respond normally. As an alternative, all cells, even the hot ones, may be TSH sensitive, although their autonomous TSH-independent iodine metabolism is intrinsically higher than average. The failure of cold follicles to match the uptake of hot ones after intense TSH stimulation tends to indicate that a similar range of TSH response is superimposed on a basically differing iodine turnover in individual follicular cells.

Double-labeling experiments with [^3H]thymidine and rapidly decaying ^{131}I permitted answering the question of whether autonomous growth was linked to autonomous function or, in other terms, whether the follicles with the highest intrinsic growth rates were also those with the highest autonomous iodine turn-

over. The answer is clearly "no." Rather, the capacity to grow and that to metabolize iodine are two wholly unrelated phenomena. Highly growth-prone cells belonging to families with intense [^3H]thymidine labeling may just as well form follicles with high iodine turnover than follicles with low iodine uptake. This observation does of course not rule out the transitory cessation of function during S-phase of the cell cycle (32). Independency of growth and function fits well with the familiar clinical observation that cold and hot nodules do not differ in their growth behaviour.

Taken as a complement to earlier studies in mice and humans, the present investigation on growing transplants allows expanding current views on the pathogenesis of human multinodular goiter and, in particular, on the ways its most puzzling hallmark, namely morphologic and functional heterogeneity, is brought about. Besides environmental factors, discussed above and in other papers (4), and besides the genetic heterogeneity of the parent tissue from which qualitatively different daughter

follicles are generated during goiter growth (3), goiter cells undergo modifications of their phenotype which are passed on to their progeny. Examples for newly acquired traits are the many individual growth patterns arising within the same goiter or between two different goiters. The transplant may perfectly reproduce the individual morphologic structure of the parent tissue. This indicates that a distinct structure does not depend only on local intrathyroidal factors, but is more likely a newly acquired quality that has become inheritable. Likewise, the high incidence of "hot" autonomously iodinating cells in transplants from "hot" nodules indicates that this functional trait is stable and independent of the environment. It is, however, difficult to say whether a given aspect of goiter heterogeneity, such as the regionally varying TSH dependency of growth and function, is exclusively a quality inherited from the polyclonal cells of the parent follicles and amplified through the generation of new daughter follicles (1), or whether the expanding cell population has acquired some stable changes of its enzymatic outfit. However, for the concept of the pathogenesis of goiter heterogeneity through amplification of individual heritable cell traits, it is of little importance whether a given functional characteristic is primarily inborn or secondarily incorporated into the inheritable equipment that determines the phenotype of a cell.

Although our experiments do not provide any information on the much-debated molecular mechanisms generating diversity among the progeny of a single cell, a few theoretical considerations may nevertheless be appropriate. It is indeed unlikely that the rather rare event of somatic mutation in growing cell clones (33) can account for the many facets of heterogeneity of human goiters. However, modern molecular biology has revealed that the pattern of gene expression is by far less stable than thought until recently, and that a genome may well acquire new heritable traits (34, 35). In addition, there is rapidly accumulating evidence suggesting the existence of extranuclear mechanisms modulating cellular function which are passed on from mother to daughter cells (36, 37). The wide variability in the regulation of gene expression has been impressively documented by discoveries such as that of transposable genetic elements (38, 39), of somatic recombination in lymphocytes (40), and of homeotic genes which play a crucial role in development and cell differentiation (41).

Heterogeneity of malignant tumors is now firmly established. Genome-bound and epigenetic mechanisms involved in creating this heterogeneity are gradually merging into a single concept. Heterogeneity among cells within the same tissue also has become a topic of growing importance. The subject which is in the focus of actual cancer research has been recently reviewed by Heppner (42).

It may well be that heterogeneity of growth and function of human goiter tissue, which offers a rather unique experimental opportunity for assessing the functional activity of individual cells or cell subsets, may increasingly attract the interest of cell biologists eager to study the mechanisms that create variability within differentiated organs.

Acknowledgments

The authors would like to thank Prof. Dr. Riedwyl, Department of Mathematics, University of Bern, for statistical analysis of data; Prof. Dr. R. Berchtold and Dr. J. Teuscher, Department of Surgery, University of Bern, for excellent collaboration; PD Dr. P. Groscurth, Department of Anatomy, University of Zürich, for his contribution to this work; Mrs. J. Kämpf, Mr. E. Schürch, and Mr. M. Jaberg for technical assistance;

Mrs. C. von Grünigen and Mrs. L. Siebenhüner for expert secretarial assistance; and Mrs. S. Bürki for the photographs.

This work was supported by grant no. 3.987.84 from the Swiss National Science Foundation.

References

1. Studer, H., and F. Ramelli. 1982. Simple goiter and its variants: euthyroid and hyperthyroid multinodular goiters. *Endocr. Rev.* 3:40-61.
2. Studer, H., H. Gerber, and H. J. Peter. Multinodular goiter. *In* Endocrinology. Vol. 1. L. J. DeGroot, editor. Grune and Stratton New York. Second edition. In press.
3. Peter, H. J., H. Studer, R. Forster, and H. Gerber. 1982. The pathogenesis of "hot" and "cold" follicles in multinodular goiters. *J. Clin. Endocrinol. Metab.* 55:941-946.
4. Studer, H., H. Kohler, and H. Bürgi. 1974. Iodine deficiency. *Handb. Physiol.* (Sect. 7). 3:303-328.
5. Studer, H., R. Forster, A. Conti, H. Kohler, A. Haeberli, and H. Engler. 1978. Transformation of normal follicles into thyrotropin-refractory "cold" follicles in the aging mouse thyroid gland. *Endocrinology.* 102:1576-1586.
6. Ramelli, F., H. Studer, and D. Bruggisser. 1982. Pathogenesis of thyroid nodules in multinodular goiter. *Am. J. Pathol.* 109:215-223.
7. Rentsch, H. P., H. Studer, B. Frauchiger, and L. Siebenhüner. 1981. Topographical heterogeneity of basal and thyrotropin-stimulated adenosine 3',5'-monophosphate in human nodular goiter. *J. Clin. Endocrinol. Metab.* 53:514-521.
8. Smeds, S., B. Anderberg, B. Boeryd, L. E. Ericson, J. Gillquist, and J. Persliden. 1981. The nude mouse. A possible experimental model for investigation of human thyroid tissue. *J. Endocrinol. Invest.* 4:11-15.
9. Leclère, J., M. C. Bene, A. Duprez, G. Faure, J. L. Thomas, J. M. Vignaud, and C. Burlet. 1984. Behaviour of thyroid tissue from patients with Graves' disease in nude mice. *J. Clin. Endocrinol. Metab.* 59:175-177.
10. Schumm, P. M., K. Badenhop, P. Kotulla, A. Lück, H. J. C. Wenisch, K. Schöffling, H. Schleusener, and K. H. Usadel. 1984. Significance of thyroid stimulating immunoglobulins in the development of euthyroid sporadic goiter. *Ann. Endocrinol. (Paris).* 45:156. (Abstr.)
11. Dralle, H., W. Böcker, K. D. Döhler, S. Schröder, H. Haindl, H. Geerlings, R. Schwarzrock, and R. Pichlmayr. 1985. Growth and function of thirty-four human benign and malignant thyroid xenografts in untreated nude mice. *Cancer Res.* 45:1239-1245.
12. Riedwyl, M. 1978. *Angewandte Statistik in Wissenschaft, Administration und Technik.* M. Riedwyl, editor. Haupt Verlag, Bern. 1-204.
13. Sharard, A., H. D. Purves, and W. S. Cague. 1970. Effect of pretreatment of mice with varying doses of thyroxine in the assay for LATS and TSH. *Proc. Univ. Otago Med. Sch.* 48:77-78.
14. Gerber, H., H. Studer, and C. von Grünigen. 1985. Paradoxical effects of thyrotropin on diffusion of thyroglobulin in the colloid of rat thyroid follicles after long term thyroxine treatment. *Endocrinology.* 116:303-310.
15. Miller, J. M., R. C. Horn, and M. A. Block. 1967. The autonomous functioning thyroid nodule in the evolution of nodular goiter. *J. Clin. Endocrinol. Metab.* 27:1264-1274.
16. Gerber, H., H. Studer, A. Conti, H. Engler, H. Kohler, and A. Haeberli. 1981. Reaccumulation of thyroglobulin and colloid in rat and mouse thyroid follicles during intense thyrotropin stimulation. A clue to the pathogenesis of colloid goiters. *J. Clin. Invest.* 68:1338-1347.
17. Miller, J. M., R. C. Horn, and M. A. Block. 1964. The evaluation of toxic nodular goiter. *Arch. Intern. Med.* 113:72-78.
18. Miller, J. M. 1975. Plummer's disease. *Med. Clin. Am.* 59:1203-1216.
19. Emrich, D., and M. Bähre. 1978. Autonomy in euthyroid goiter: maladaptation to iodine deficiency. *Clin. Endocrinol. (Oxf).* 8:257-265.

20. Wiener, J. D. 1975. A systematic approach to the diagnosis of Plummer's disease (autonomous goiter) with a review of 224 cases. *Neth. J. Med.* 18:218-233.
21. Pardee, A. B., W. R. Dubrow, J. L. Hamlin, and R. F. Kletzien. 1978. Animal cell cycle. *Annu. Rev. Biochem.* 47:715-750.
22. Westermark, K., F. A. Karlson, L. E. Ericson, and B. Westermark. 1985. Epidermal growth factor: a regulator of thyroid growth and function in vitro. In *Thyroglobulin—The Prothyroid Hormone*. Progress in Endocrine Research and Therapy. Vol. 2. M. C. Eggo, and G. N. Burrow, editors. Raven Press, New York. 255-262.
23. Drexhage, H. A., G. F. Bottazzo, D. Doniach, L. Bitensky, and J. Chayen. 1980. Evidence for thyroid-growth-stimulating immunoglobulins in some goitrous thyroid disease. *Lancet*. ii:287-292.
24. Grubeck-Loebenstein, B., K. Derfler, H. Kassal, W. Knapp, K. Kirsch, K. Liszka, P. P. A. Smyth, and W. Waldhäusl. 1985. Immunological features of nonimmunogenic hyperthyroidism. *J. Clin. Endocrinol. Metab.* 60:150-155.
25. Brown, R. S., I. M. D. Jackson, S. Pohl, and S. Reichlin. 1978. Do thyroid stimulating-immunoglobulins cause non-toxic multinodular goiter? *Lancet*. i:904-906.
26. Wollman, S. H., and I. Wodinsky. 1955. Localization of protein-bound iodine-131 in the thyroid gland of the mouse. *Endocrinology*. 56: 9-20.
27. Leblond, C. P., and J. Gross. 1948. Thyroglobulin formation in the thyroid follicle visualized by the "coated autograph" technique. *Endocrinology*. 43:306-324.
28. Wollman, S. H. 1965. Heterogeneity of the thyroid gland. *Curr. Top. Thyroid Res. Proc. 5th Int. Thyroid Conf.* 5:1-18.
29. Errick, J. E., M. C. Eggo, and G. N. Burrow. 1985. Factors affecting synthesis of thyroid-specific proteins and iodination in cultured thyroid cells. In *Thyroglobulin—The Prothyroid Hormone*. Progress in Endocrine Research and Therapy. Vol. 2. M. C. Eggo and G. N. Burrow, editors. Raven Press, New York. 271-282.
30. DeRubertis, F., K. Yamashita, A. Dekker, P. R. Larsen, and J. B. Field. 1972. Effects of thyroid-stimulating hormone on adenyl cyclase activity and intermediary metabolism of "cold" thyroid nodules and normal human thyroid tissue. *J. Clin. Invest.* 51:1109-1117.
31. Larsen, P. R., K. Yamashita, A. Dekker, and J. B. Field. 1973. Biochemical observations in functioning thyroid adenomas. *J. Clin. Endocrinol. Metab.* 36:1009-1018.
32. Roger, P. P., and J. E. Dumont. 1983. Thyrotrophin and the differential expression of proliferation and differentiation in dog thyroid cells in primary culture. *J. Endocrinol.* 96:241-249.
33. Cairns, J. 1975. Mutation selection and the natural history of cancer. *Nature (Lond.)*. 255:197-200.
34. Roeder, G. S., P. J. Farabaugh, D. T. Chaleff, and G. R. Fink. 1980. The origins of gene instability in yeast. *Science (Wash. DC)*. 209: 1375-1380.
35. Razin, A., and H. Cedar. 1984. DNA methylation in eukaryotic cells. *Int. Rev. Cytol.* 92:159-185.
36. Albrecht-Buehler, G. 1977. Daughter 3T3 cells. Are they mirror images of each other. *J. Cell. Biol.* 72:595-603.
37. Aufderheide, K. J., J. Frankel, and N. E. Williams. 1977. Formation and positioning of surface-related structures in protozoa. *Microbiol. Rev.* 44:252-302.
38. McClintock, B. 1956. Controlling elements and the gene. *Cold Spring Harbor Symp. Quant. Biol.* 21:197-216.
39. Shapiro, J. 1983. Mobile genetic elements. New York, Academic Press. 1-63.
40. Adams, J. M. 1980. The organisation and expression of immunoglobulin genes. *Immunol. Today (Amst.)*. 1:10-17.
41. Gehring, W. J. 1985. The homeo box: a key to the understanding of development? *Cell*. 40:3-5.
42. Heppner, G. H. 1984. Tumor heterogeneity. *Cancer Res.* 44: 2259-2265.