

Decreased expression of type II tumor suppressor gene RARRES3 in tissues of hepatocellular carcinoma and cholangiocarcinoma

Shun-Yuan Jiang, Jung-Mao Chou, Fur-Jiang Leu, Yu-Yen Hsu, Yu-Lung Shih, Jyh-Cherng Yu, Meei-Shyuan Lee, Rong-Yaun Shyu

Shun-Yuan Jiang, Yu-Yen Hsu, Department of Microbiology and Immunology, National Defense Medical Center, Taipei 114, Taiwan, China

Meei-Shyuan Lee, School of Public Health, National Defense Medical Center, Taipei 114, Taiwan, China

Rong-Yaun Shyu, Yu-Lung Shih, Department of Internal Medicine, Tri-Service General Hospital, Taipei 114, Taiwan, China

Jung-Mao Chou, Department of Pathology, Armed Forces Tsoying Hospital, Kaohsiung 833, Taiwan, China

Jyh-Cherng Yu, Department of Surgery, Tri-Service General Hospital, Taipei 114, Taiwan, China

Fur-Jiang Leu, Department of Pathology, Cardinal Tien Hospital, Taipei 231, Taiwan, China

Supported by the Tri-Service General Hospital (TSGH-C91-14), Department of Defense (N91079), and National Science Council (NSC91-2314-B016-108) Taipei, Taiwan, China

Correspondence to: Dr. Rong-Yaun Shyu, Section of Gastroenterology, Tri-Service General Hospital, 325 Chengung Rd, Sec. 2, Taipei 114, Taiwan, China. ryshyu612@ndmctsgh.edu.tw

Telephone: +886-2-8792-4844 Fax: +886-2-8792-7242

Received: 2004-06-15 Accepted: 2004-07-17

Abstract

AIM: To analyze the expression of retinoic acid receptor responder 3 (RARRES3) protein in paraffin-embedded tissues of hepatocellular carcinoma (HCC) and cholangiocarcinoma (CC), and the correlation of RARRES3 production with tumor differentiation.

METHODS: Expression of RARRES3 in tissues from 21 CC (10 well-, 7 moderately- and 4 poorly-differentiated) and 32 HCC was determined by immunohistochemistry.

RESULTS: Among 21 CC tissues, RARRES3 was detected in 8 (80%) of 10 well-differentiated tumors. Only 2 (18.2%) out of 11 tumors with moderate or poor differentiation showed positive RARRES3 expression. RARRES3 expression in well-differentiated CC was significantly higher than that in tumors with moderate or poor differentiation (Fisher exact test, $P < 0.01$). Expression of RARRES3 was not different between early (I and II) and late (III and IV) stages of CC. Among 30 HCC tissues, 17 (56.7%) weakly expressed RARRES3 in HCC cells, and 25 (83.3%) normal tissues adjacent to HCC expressed the protein. RARRES3 expression was significantly decreased in HCC tissues compared to that in adjacent normal tissues (logistic regression analysis, OR = 0.27, 95% CI (0.11-0.62), $P < 0.01$).

CONCLUSION: Expression of RARRES3 is positively correlated to well-differentiated CC, which supports the

role of RARRES3 in malignant epithelial differentiation of the tumor. The decrease in RARRES3 expression in tissues of HCC and CC with moderate and poor differentiation suggests that altered RARRES3 expression may play a role in the carcinogenesis of the liver and biliary tract.

© 2005 The WJG Press and Elsevier Inc. All rights reserved.

Key words: Retinoic acid receptor responder 3; RARRES3; RIG1; TIG3; Hepatocellular carcinoma; Cholangiocarcinoma

Jiang SY, Chou JM, Leu FJ, Hsu YY, Shih YL, Yu JC, Lee MS, Shyu RY. Decreased expression of type II tumor suppressor gene RARRES3 in tissues of hepatocellular carcinoma and cholangiocarcinoma. *World J Gastroenterol* 2005; 11(7): 948-953

<http://www.wjgnet.com/1007-9327/11/948.asp>

INTRODUCTION

Retinoic acid receptor responder 3 (RARRES3), also named as TIG3^[1] or RIG1^[2] is a growth regulatory protein, a member of the HREV107 protein family. The family includes RARRES3, HREV107^[3,4] and A-C1^[5,6], which possess the NlpC/P60 functional domain^[7]. The genuine function for the HREV107 family of proteins remains unclear, although the role as enzymes that modify membrane components have been proposed^[7]. Proteins of the HREV107 family have been shown to suppress transformation induced by H-ras^[4,6,8] or kinase activities downstream of the activation of Ras proteins^[9]. The RARRES3 gene that encodes is expressed ubiquitously in normal tissues and at lower levels in cancer cell lines. *In vitro* examination of cancer cells and keratinocytes show that expression of RARRES3 leads to the suppression of cellular growth accompanied with an induction of apoptosis or differentiation^[1,9-11]. In head, neck and lung carcinoma cells, RARRES3 expression is closely associated with suppression of cellular growth induced by all-trans retinoic acid^[12]. Therefore, the increase in RARRES3 protein expression may play an important role in tumor suppressive activity of retinoids.

Analysis of the differential expression of RARRES3 between benign and malignant tissues is limited. RARRES3 is expressed in the suprabasal epidermis of normal skin, and the protein's production is reduced in tissues of basal cell carcinoma and aggressive squamous cell carcinoma^[13]. Application of the synthetic retinoid tazarotene induces RARRES3 expression and histological improvement of basal cell carcinoma^[14]. Also, expression of RARRES3

protein is positively correlated to cellular differentiation of normal and adenocarcinoma tissues of the colorectum^[15]. Colorectal adenocarcinoma with moderate and poor differentiation is coincident with the markedly decreased production of RARRES3. The positive association between the presence of RARRES3 and epidermal and colorectal differentiation *in vivo*^[13-15] as well as induction of keratinocyte terminal differentiation by RARRES3 *in vitro*^[10] suggest that RARRES3 may be important in epithelial differentiation, and altered expression of the protein may play an important role in carcinogenesis.

Mechanisms of hepatocellular carcinogenesis have been studied extensively. Exposure to the chemical carcinogen aflatoxin B1 as well as infection of hepatitis B or C virus play pivotal roles in the development of hepatocellular carcinoma (HCC). Activation of protooncogenes such as *N-ras*, *c-myc* and *c-fos* as well as inactivation or loss of expression of tumor suppressor genes like *TP53* and *DLC-1* are observed frequently in HCC tissues^[16,17]. The molecular pathogenesis of cholangiocarcinoma (CC) has not been well defined. However, multiple tumor suppressor genes and oncogenes, including *TP53* and *K-ras*, are altered in these tumors^[18].

The liver is the organ responsible for the storage and metabolic inactivation of dietary retinoids. Epidemiological analysis has shown that the decrease in serum retinol levels is associated with hepatocarcinogenesis in cirrhosis patients^[19]. Both all-trans retinoic acid and the synthetic acyclic retinoid suppress growth of HCC *in vitro* and *in vivo*^[20-22]. Furthermore, the acyclic retinoid prevents the development of second primary HCC^[23].

The role of retinoids in the carcinogenesis of CC has not been investigated before. To investigate the expression and role of retinoid inducible protein, RARRES3, in the carcinogenesis of HCC and CC, we presently analyzed the expression of RARRES3 protein in tissues from HCC and CC using immunohistochemistry.

MATERIALS AND METHODS

Specimen collection and preparation

A sample of CC tissue was obtained from 21 patients (9 males and 12 females) with a mean age of 67.0 years. A sample of HCC tissue was obtained from 30 other patients (24 males and 6 females) with a mean age of 53.9 years. Distribution of these tumors according to their level of differentiation and TNM stages are listed in Table 1. Tissue slides were prepared from paraffin-embedded blocks and used for hematoxylin and eosin staining. Each specimen was evaluated by the same pathologist to define the differentiation status of carcinoma tissues. Assessment of tumor differentiation was based on the architectural and glandular differentiation as well as nuclear features of tumors^[24].

Immunohistochemical analysis

Tissue sections were air-dried, deparaffinized, and then boiled twice for 2 min in 10% DAKO ChemMate™ solution (DAKO Corp., Carpinteria, CA) containing 0.05% Nonidet P-40. The DAKO LSAB® 2 peroxidase kit (DAKO Corp.)

Table 1 Characteristics of cancer patients and tissues

Categories	Number of cases
Cholangiocarcinoma	
M/F	9/12
Average age (yr)	67.0±8.1
Stages	
I	2
II	9
III	8
IV	2
Tumor differentiation	
Well	10
Moderate	7
Poor	4
Hepatocellular carcinoma	
M/F	24/6
Average age	53.9±15.0
Tumor differentiation	
Well	4
Moderate	23
Poor	3
Stages	
I	4
II	18
III	1
NA ¹	7

¹Not available.

was used to stain RARRES3 protein in tissue sections. Briefly, sections were blocked with 3% hydrogen peroxide (H₂O₂) and then incubated with RIG1 antiserum or preimmune serum at a dilution of 1:800 at room temperature for 1 h. After washing with phosphate-buffered saline (PBS) containing 0.2% Tween 20, sections were incubated with biotinylated goat anti-rabbit and anti-mouse immunoglobulins at room temperature for 10 min. Sections were washed and then incubated with streptavidin-biotin-peroxidase complexes at room temperature for 10 min. After washing, tissue sections were then incubated in acetate containing 3-amino-9-ethylcarbazole and 1% H₂O₂. The sections were lightly counterstained with Mayer's hematoxylin. The RARRES3 antiserum was developed from rabbits by immunizing with a RARRES3 peptide corresponding to amino acids 74-87 of the protein. Specificity of the antiserum was determined by Western blotting and competition of RARRES3 binding using the immunized peptide^[9,15].

Reviewing and scoring of sections

Patterns of staining, cellular RARRES3 localization, staining intensity and percentage of RARRES3 expressed cells were recorded. Both diffused and supranuclear granular patterns of RARRES3 staining were observed. For tissues with a diffuse staining pattern, "negative" RARRES3 expression was defined as an absence of RARRES3 staining, and "positive" was defined as weak or moderate RARRES3 staining. For tissues with supranuclear granular patterns of RARRES3 staining, evaluation of staining patterns was performed as described previously with minor modifications^[15]. Briefly, evaluation of staining patterns was performed using the immunoreactive score (IRS) in which IRS = SI (staining intensity) × PP (percentage of positive cells)^[15]. SI was scored as 0 (negative),

1 (weak), 2 (moderate), and 3 (strong). PP was defined as 1 (0-<10% positive cells), 2 (10-50% positive cells), and 3 (>50% positive cells). Ten high power visual fields from different areas of each specimen, with 100 cells per field counted, were chosen at random for IRS evaluation, and the average of IRS was calculated. Final intensity of RARRES3 staining was defined as "negative" and "positive" corresponding to the aforementioned IRS values of 0-1 and 2-9, respectively. Results of RARRES3 staining were based on the consensus of 2 investigators (Jiang SY and Chou JM).

Statistical analysis

The Fisher's exact tests were applied for comparison of positive RARRES3 expression and tumor differentiation as well as stages of CC. Differential expression of RARRES3 between adjacent normal and HCC tissues from the same cancer patient was analyzed by logistic regression. However, the estimated co-efficient and their correspondent variances were obtained through the generalized estimating equation method^[25] and the SAS/IML macro program, GEE1.SAS,

to take into account the subject correlation.

RESULTS

RARRES3 in CC tissues

Within the 21 tumor tissue samples, 7 had normal biliary ducts. Positive RARRES3 staining, ranging from 15-60% of biliary epithelial cells adjacent to tumors, was observed in 5 (71.4%) of the 7 tissues. Dysplastic tissue was observed in only 1 sample and that tissue expressed the RARRES3 protein. Staining revealed a granular pattern of RARRES3 in the supranuclear regions of biliary epithelial cells and dysplastic tissue (Figures 1A and 1B). The protein was expressed in 10 out of 21 (47.6%) CC tissues. Among these 10 tissue samples, 5 samples showed only a granular pattern of RARRES3 staining located at the supranuclear region, and 5 tissues showed both a granular as well as diffuse RARRES3 staining in the cytoplasm. Representative results of RARRES3 protein expression in well-, moderately- and poorly-differentiated tumor tissues are shown in Figure 1. RARRES3 expression was observed in the well-differentiated CC tissue (Figure 1D), whereas moderately-differentiated tumor tissue

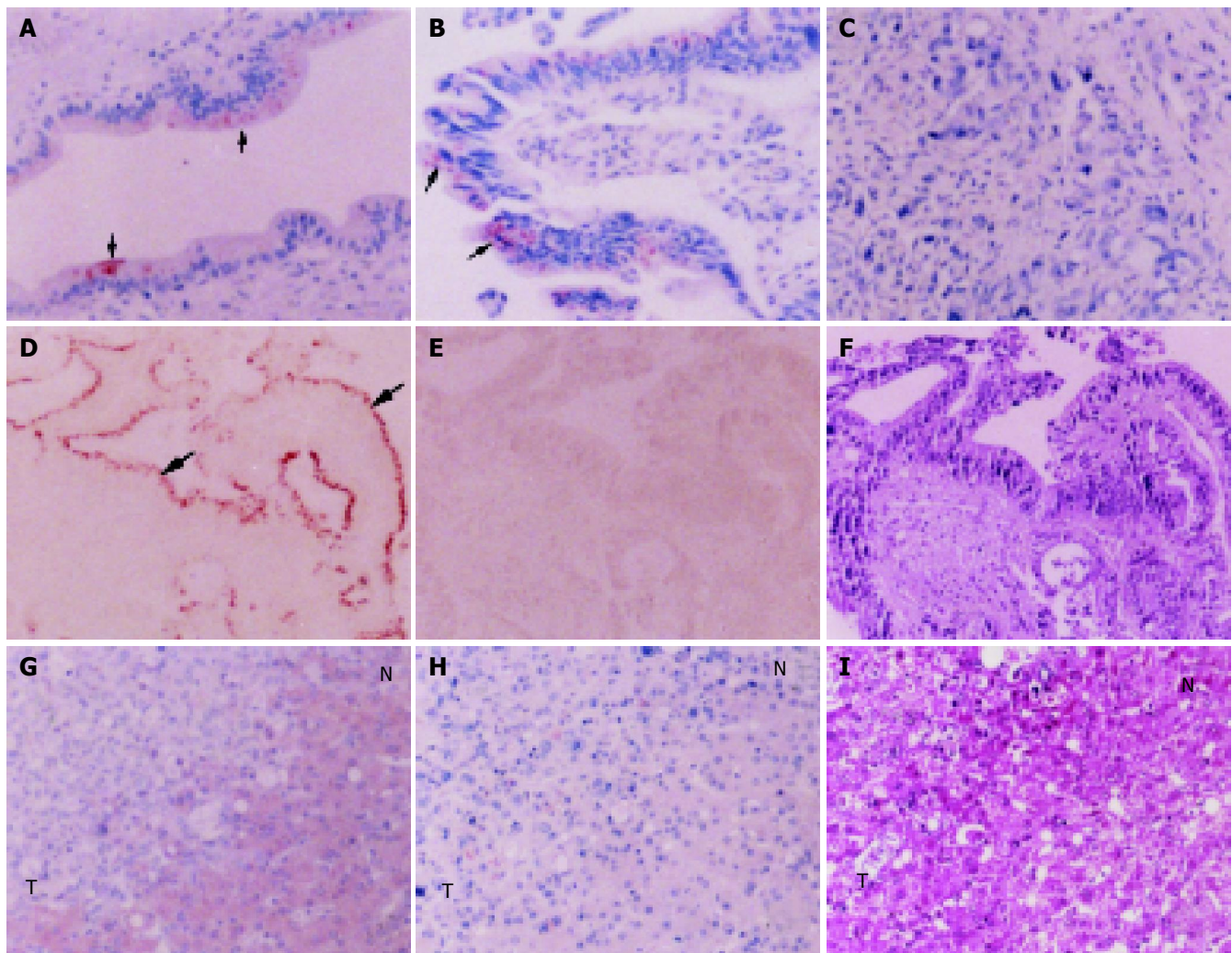


Figure 1 Expression of RARRES3 in paraffin-embedded sections of CC tissues. Tissue sections from tumors with moderate (A-C), well (D-F) and poor (G-I) differentiation were assayed for RARRES3 expression by immunohistochemistry using RARRES3 antiserum (A-C, D and G) or preimmune serum (E, H). F and I: hematoxylin and eosin staining. Arrows indicate granular patterns of RARRES3 staining. AN: adjacent normal tissues; T: tumor tissues. Original magnification: 100 \times .

did not express RARRES3 (Figure 1C). Poorly-differentiated tumor tissue was stained negative for RARRES3 protein, whereas adjacent normal liver tissues were stained positive for the protein (Figure 1G). No specific RARRES3 staining was observed in tissues incubated with preimmune serum (Figures 1E and 1H).

When RARRES3 expression was analyzed with respect to difference in tumor differentiation, 8 out of 10 (80%) well-differentiated CC tissues were stained positive for the protein. Similar positive staining was noted in only 2 (18.2%) of the 11 moderately- or poorly-differentiated CC tissues. Well-differentiated CC tumors had a significantly greater chance of expressing the protein than moderately- and poorly-differentiated tumors (Fisher's exact test, $P < 0.01$) (Table 2). No significant association between RARRES3 expression and tumor stages was found ($P = 0.40$).

Table 2 Expression of RIG1 protein in CC tissues

Categories	RIG protein staining [n (%) of cases]		Fisher's exact test
	Negative	Positive	
Differentiation			$P < 0.01$
Well	2 (20.0)	8 (80.0)	
Moderate/poor	9 (81.8)	2 (18.2)	
Stages			$P = 0.40$
I and II	7 (63.6)	4 (36.4)	
III and IV	4 (40.0)	6 (60.0)	

RARRES3 expression in HCC tissues

The detection of RARRES3 was analyzed in 30 HCC tissues and adjacent normal tissues. In contrast to CC, a diffuse pattern of staining was observed in all HCC tissues and

adjacent normal hepatocytes that showed positive RARRES3 expression (Figure 1G and Figure 2). Seventeen out of 30 (56.7%) HCC tissues were stained positive for RARRES3 protein, while 25 (83.3%) adjacent normal liver tissues were positively stained (Table 3). Logistic regression analysis revealed that HCC cells had a significantly lower chance of housing RARRES3 than the adjacent normal hepatocytes [OR = 0.27, CI (0.11-0.62), $P < 0.01$]. Due to the disproportionate distribution of tumor samples (Table 1), differences in RARRES3 expression among tumors with difference in differentiation or stages were not analyzed.

Table 3 Expression of RIG1 protein in HCC tissues

Tissues	RIG1 protein [n (%) of cases]	
	Negative	Positive
Adjacent normal	5 (16.7)	25 (83.3)
HCC	13 (43.3)	17 (56.7)

Logistic regression analysis: OR = 0.27, 95% CI (0.11-0.62), $P < 0.01$.

DISCUSSION

RARRES3 is a retinoid inducible protein that is a tumor suppressor. This study showed that RARRES3 was expressed in normal hepatocytes and biliary epithelial cells that are adjacent to HCC or CC. Compared to the adjacent normal liver tissues, HCC tumor cells were markedly reduced in RARRES3. Within CC tissues, tumors with moderate or poor differentiation also showed a significant loss in RARRES3 expression, compared to the protein level in well-differentiated tumors.

Previous studies have analyzed the expression of RARRES3 in normal and malignant tissues from skin and

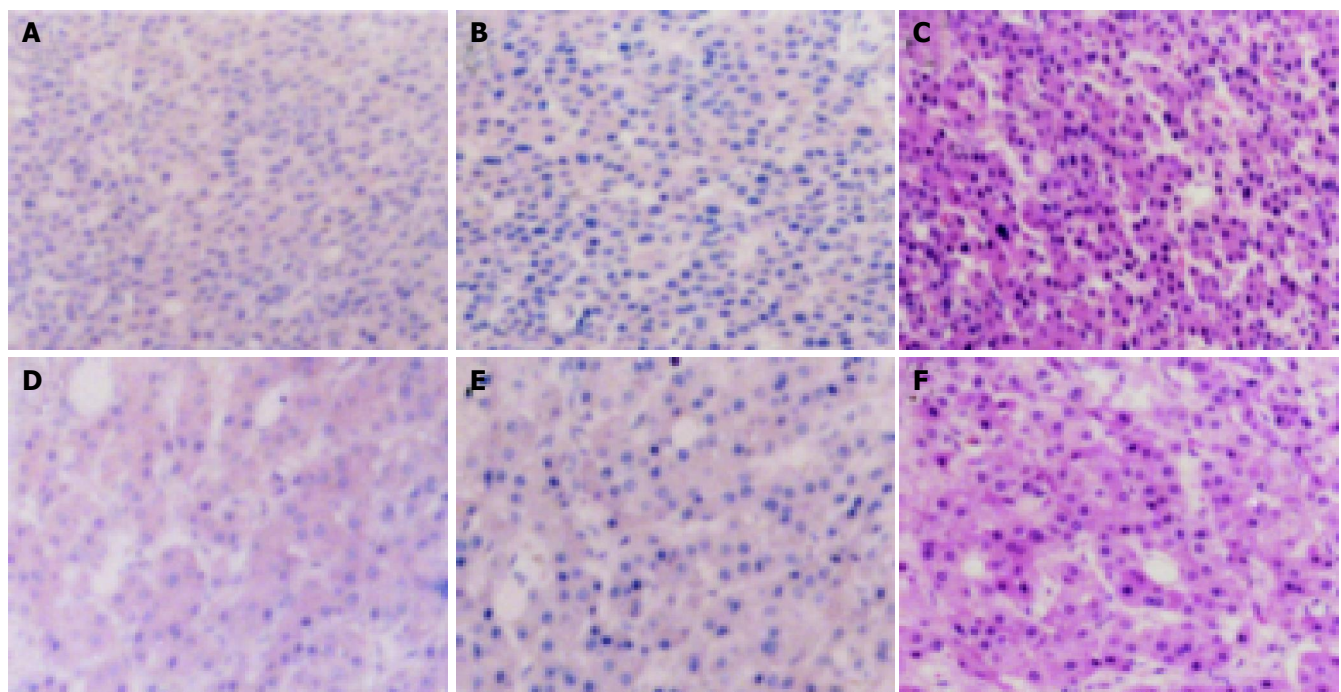


Figure 2 Expression of RARRES3 in paraffin-embedded HCC tissues. HCC (A-C) and adjacent normal tissues (D-F) were stained for RARRES3 protein using RARRES3 antiserum (A, D) or preimmune serum (B, E). C and F: hematoxylin and eosin staining. Original magnification: 100x.

colorectum that differ in their cellular differentiation. RARRES3 protein is expressed at the highest levels in terminal, differentiated colorectal epithelial cells^[15], normal suprabasal epidermis, hair follicles, and sebaceous gland^[13]. Presently, this list has been expanded to include normal biliary epithelial cells and hepatocytes. The wide spectrum of RARRES3 expression in several differentiated normal tissues and the conserved structure of the protein throughout evolution^[7] is consistent with the idea that RARRES3 plays an important role in cells of epithelial origin. Within carcinoma tissues, results from the current and our previous studies^[15] show a significant loss of RARRES3 expression in moderately- and poorly-differentiated adenocarcinomas of colorectum and CC. Expression of RARRES3 in colorectal adenocarcinoma tissues is progressively lost with the decrease in tumor differentiation. RARRES3 expression in well-differentiated tumors is relatively equal to normal or adjacent normal tissues of the colorectum. The close correlation between RARRES3 expression and cellular differentiation in various normal and tumor tissues suggests that RARRES3 may play a pivotal role in both normal and malignant epithelial differentiation.

Previous studies using transient transfection have demonstrated that RARRES3 exhibits growth suppressive and proapoptotic activities in several cancer cell lines^[1,9,11]. Recently, results from Sturniolo *et al*^[10] demonstrated that keratinocyte growth arrest, apoptosis and terminal differentiation are induced following induction of RARRES3 expression. Therefore, RARRES3 may not only function as a negative growth regulator but also may play an active role in the induction of epithelial differentiation.

RARRES3-induced terminal differentiation is mediated through the activation of type I transglutaminase in keratinocytes^[10]. There are several types of transglutaminases, whose expressions range from ubiquitous to tissue specific. Whether a specific type of transglutaminase is activated in RARRES3-mediated differentiation of colorectal and biliary epithelial cells as well as hepatocytes requires further investigation.

Retinoids are known to regulate a broad spectrum of biological processes such as cell development, growth, and differentiation. Animal and clinical studies have demonstrated the chemopreventive activity of acyclic retinoid in the formation of second primary HCC in humans^[23]. Both retinoic acid and acyclic retinoid suppress growth of human HCC cells^[20-22], an activity that is mediated through the activation of a retinoic acid receptor β and a retinoid receptor^[26]. RARRES3 is a retinoid inducible gene, which is induced through heterodimers of these receptors^[2]. Aberrant expression of nuclear retinoic acid receptors and cellular sensitivity to retinoic acid in HCC cells can occur *in vitro*^[27]. Whether the loss of RARRES3 expression in HCC tissues is parallel to the aberrant expression of nuclear retinoic acid receptors requires further investigation.

The production of RARRES3 leads to growth suppression and cellular apoptosis in several types of cancer cells. The induction of RARRES3 expression by all-trans retinoic acid is associated with the suppression of anchorage-independent growth in head and neck and lung carcinoma cells^[12]. Further analysis of the regulation of RARRES3 expression by

retinoids in HCC cells may aid in understanding the role of RARRES3 in growth suppressive activity mediated by retinoic acid and acyclic retinoids.

In conclusion, expression of RARRES3 is downregulated in moderately- and poorly-differentiated HCC and CC tissues. These results agree with previous observation demonstrating the positive association between RARRES3 expression and tissue differentiation of normal and tumor tissues from the epidermis and colorectum. Enhanced RARRES3 levels in well-differentiated CC tissues support the role of RARRES3 in malignant epithelial differentiation of the tumor. This role is further supported by the knowledge that RARRES3 can suppress downstream signal pathways of Ras and actively induce cellular differentiation *in vitro*. Further analysis of the differences in the activation of Ras signal pathways in tissues that display a variable degree of RARRES3 expression is important to understand the significance of the decreased production of this protein in HCC and CC tissues.

ACKNOWLEDGEMENTS

The authors thank Pao-Wen Chang and Kok-Wee Low for their technical assistance.

REFERENCES

- 1 DiSepio D, Ghosn C, Eckert RL, Deucher A, Robinson N, Duvic M, Chandraratna RA, Nagpal S. Identification and characterization of a retinoid-induced class II tumor suppressor/growth regulatory gene. *Proc Natl Acad Sci USA* 1998; **95**: 14811-14815
- 2 Huang SL, Shyu RY, Yeh MY, Jiang SY. Cloning and characterization of a novel retinoid-inducible gene 1 (RIG1) deriving from human gastric cancer cells. *Mol Cell Endocrinol* 2000; **159**: 15-24
- 3 Husmann K, Sers C, Fietze E, Mincheva A, Lichter P, Schafer R. Transcriptional and translational downregulation of H-REV107, a class II tumour suppressor gene located on human chromosome 11q11-12. *Oncogene* 1998; **17**: 1305-1312
- 4 Hajnal A, Klemenz R, Schafer R. Subtraction cloning of H-rev107, a gene specifically expressed in H-ras resistant fibroblasts. *Oncogene* 1994; **9**: 479-490
- 5 Ito H, Akiyama H, Shigeno C, Nakamura T. Isolation, characterization, and chromosome mapping of a human A-C1 Ha-Ras suppressor gene (HRASLS). *Cytogenet Cell Genet* 2001; **93**: 36-39
- 6 Akiyama H, Hiraki Y, Noda M, Shigeno C, Ito H, Nakamura T. Molecular cloning and biological activity of a novel Ha-Ras suppressor gene predominantly expressed in skeletal muscle, heart, brain, and bone marrow by differential display using clonal mouse EC cells, ATDC5. *J Biol Chem* 1999; **274**: 32192-32197
- 7 Anantharaman V, Aravind L. Evolutionary history, structural features and biochemical diversity of the NlpC/P60 superfamily of enzymes. *Genome Biol* 2003; **4**: R11
- 8 Sers C, Emmenegger U, Husmann K, Bucher K, Andres AC, Schafer R. Growth-inhibitory activity and downregulation of the class II tumor-suppressor gene H-rev107 in tumor cell lines and experimental tumors. *J Cell Biol* 1997; **136**: 935-944
- 9 Huang SL, Shyu RY, Yeh MY, Jiang SY. The retinoid-inducible gene I: effect on apoptosis and mitogen-activated kinase signal pathways. *Anticancer Res* 2002; **22**: 799-804
- 10 Sturniolo MT, Dashti SR, Deucher A, Rorke EA, Broome AM, Chandraratna RA, Keepers T, Eckert RL. A novel tumor suppressor protein promotes keratinocyte terminal differentiation via activation of type I transglutaminase. *J Biol Chem*

- 2003; **278**: 48066-48073
- 11 **Deucher A**, Nagpal S, Chandraratna RA, Di Sepio D, Robinson NA, Dashti SR, Eckert RL. The carboxy-terminal hydrophobic domain of TIG3, a class II tumor suppressor protein, is required for appropriate cellular localization and optimal biological activity. *Int J Oncol* 2000; **17**: 1195-1203
 - 12 **Higuchi E**, Chandraratna RA, Hong WK, Lotan R. Induction of TIG3, a putative class II tumor suppressor gene, by retinoic acid in head and neck and lung carcinoma cells and its association with suppression of the transformed phenotype. *Oncogene* 2003; **22**: 4627-4635
 - 13 **Duvic M**, Helekar B, Schulz C, Cho M, DiSepio D, Hager C, DiMao D, Hazarika P, Jackson B, Breuer-McHam J, Young J, Clayman G, Lippman SM, Chandraratna RA, Robinson NA, Deucher A, Eckert RL, Nagpal S. Expression of a retinoid-inducible tumor suppressor, Tazarotene-inducible gene-3, is decreased in psoriasis and skin cancer. *Clin Cancer Res* 2000; **6**: 3249-3259
 - 14 **Duvic M**, Ni X, Talpur R, Herne K, Schulz C, Sui D, Ward S, Joseph A, Hazarika P. Tazarotene-induced gene 3 is suppressed in basal cell carcinomas and reversed *in vivo* by tazarotene application. *J Invest Dermatol* 2003; **121**: 902-909
 - 15 **Shyu RY**, Jiang SY, Chou JM, Shih YL, Lee MS, Yu JC, Chao PC, Hsu YJ, Jao SW. RARRES3 expression positively correlated to tumour differentiation in tissues of colorectal adenocarcinoma. *Br J Cancer* 2003; **89**: 146-151
 - 16 **Wang XW**, Hussain SP, Huo TI, Wu CG, Forgues M, Hofseth LJ, Brechot C, Harris CC. Molecular pathogenesis of human hepatocellular carcinoma. *Toxicology* 2002; **181-182**: 43-47
 - 17 **Wong CM**, Lee JM, Ching YP, Jin DY, Ng IO. Genetic and epigenetic alterations of DLC-1 gene in hepatocellular carcinoma. *Cancer Res* 2003; **63**: 7646-7651
 - 18 **Okuda K**, Nakanuma Y, Miyazaki M. Cholangiocarcinoma: recent progress. Part 2: molecular pathology and treatment. *J Gastroenterol Hepatol* 2002; **17**: 1056-1063
 - 19 **Clemente C**, Elba S, Buongiorno G, Berloco P, Guerra V, Di Leo A. Serum retinol and risk of hepatocellular carcinoma in patients with child-Pugh class A cirrhosis. *Cancer Lett* 2002; **178**: 123-129
 - 20 **Hsu SL**, Lin HM, Chou CK. Suppression of the tumorigenicity of human hepatoma hep3B cells by long-term retinoic acid treatment. *Cancer Lett* 1996; **99**: 79-85
 - 21 **Murakami K**, Matsuura T, Hasumura S, Nagamori S, Yamada Y, Saiki I. Involvement of insulin-like growth factor binding protein-3 in the retinoic acid receptor-alpha-mediated inhibition of hepatocellular carcinoma cell proliferation. *Cancer Lett* 2000; **151**: 63-70
 - 22 **Yasuda I**, Shiratori Y, Adachi S, Obora A, Takemura M, Okuno M, Shidoji Y, Seishima M, Muto Y, Moriwaki H. Acyclic retinoid induces partial differentiation, down-regulates telomerase reverse transcriptase mRNA expression and telomerase activity, and induces apoptosis in human hepatoma-derived cell lines. *J Hepatol* 2002; **36**: 660-671
 - 23 **Muto Y**, Moriwaki H, Ninomiya M, Adachi S, Saito A, Takasaki KT, Tanaka T, Tsurumi K, Okuno M, Tomita E, Nakamura T, Kojima T. Prevention of second primary tumors by an acyclic retinoid, polyprenoic acid, in patients with hepatocellular carcinoma. Hepatoma Prevention Study Group. *N Engl J Med* 1996; **334**: 1561-1567
 - 24 Recommendations for the reporting of resected large intestinal carcinomas. Association of Directors of Anatomic and Surgical Pathology. *Am J Clin Pathol* 1996; **106**: 12-15
 - 25 **Zeger SL**, Liang KY. Longitudinal data analysis for discrete and continuous outcomes. *Biometrics* 1986; **42**: 121-130
 - 26 **Yamada Y**, Shidoji Y, Fukutomi Y, Ishikawa T, Kaneko T, Nakagama H, Imawari M, Moriwaki H, Muto Y. Positive and negative regulations of albumin gene expression by retinoids in human hepatoma cell lines. *Mol Carcinog* 1994; **10**: 151-158
 - 27 **Sever CE**, Locker J. Expression of retinoic acid alpha and beta receptor genes in liver and hepatocellular carcinoma. *Mol Carcinog* 1991; **4**: 138-144