

# An Evaluation of the Significance of Microscopic Colitis in Patients with Chronic Diarrhea

George W. Bo-Linn, Doris D. Vendrell, Edward Lee, and John S. Fordtran

Departments of Internal Medicine and Pathology of Baylor University Medical Center, Dallas, Texas 75246; Department of Pathology, Dallas Veterans Administration Medical Center, Dallas, Texas 75216

## Abstract

Some patients with chronic idiopathic diarrhea have an apparent nonspecific inflammation of colonic mucosa, even though their colons appear normal by barium enema and colonoscopy. This has been referred to as microscopic colitis. However, the significance of this finding is unclear, because the ability of pathologists to accurately distinguish mild degrees of abnormality has not been established. Furthermore, even if the mucosa of these patients is nonspecifically inflamed, it is not known whether this is associated with deranged colonic function that could contribute to the development of chronic diarrhea. To assess these questions, we first examined colonic biopsy specimens in a blinded fashion, comparing biopsy results from patients with microscopic colitis with biopsy specimens from subjects in two control groups. This analysis revealed that colonic mucosa from six patients with microscopic colitis was in fact abnormal. For example, their mucosa contained an excess of both neutrophils and round cells in the lamina propria, cryptitis, and reactive changes. These and other differences were statistically significant. Second, colonic absorption, measured by the steady state nonabsorbable marker perfusion method, was severely depressed in the patients. For example, mean water absorption rate was 159 ml/h in normal subjects and was reduced to only 26 ml/h in six patients with microscopic colitis. Results of net and unidirectional electrolyte fluxes and of electrical potential difference suggested that colonic fluid absorption was abnormal because of reduced active and passive sodium and chloride absorption and because of reduced  $\text{Cl}/\text{HCO}_3$  exchange. Small intestinal fluid and electrolyte absorption was abnormally reduced in two of the six patients, suggesting the possibility of coexistent small intestinal involvement in some of these patients. We conclude that nonspecific inflammation of colonic mucosa is associated with a severe reduction of colonic fluid absorption, and that the latter probably contributes to the development of chronic diarrhea.

## Introduction

In 1980, we reported a clinical study of patients with diarrhea of unknown origin (1). In the course of our evaluation, we

This work was presented in part at the 85th Meeting of the American Gastroenterological Association at New Orleans in May 1984, and was published as an abstract (1984. *Gastroenterology*. 86:1030).

Address correspondence to Dr. Fordtran, Department of Internal Medicine, Baylor University Medical Center, 3500 Gaston Ave., Dallas, TX 75246.

Received for publication 25 July 1984 and in revised form 14 January 1985.

J. Clin. Invest.

© The American Society for Clinical Investigation, Inc.

0021-9738/85/05/1559/11 \$1.00

Volume 75, May 1985, 1559-1569

observed nonspecific inflammation in colonic biopsy samples from eight of these patients. Because there was no evidence of colitis on observation by barium enema or sigmoidoscopy/colonoscopy, we designated these patients as having "microscopic colitis." We were, however, uncertain of the clinical significance of microscopic colitis for two reasons: First, in lacking control biopsy specimens from healthy subjects, we did not know if the colonic inflammation in these patients was truly abnormal. And, second, we did not know whether these histologic findings, even if abnormal, were associated with deranged colonic function that could contribute to the development of diarrhea.

In 1982, Kingham et al. (2) described six patients that were similar to ours, in that they had idiopathic diarrhea, a normal-appearing colon, and colonic biopsy specimens that revealed microscopic colitis. They carried out a blinded analysis of the mucosal biopsy samples, comparing their six patients with microscopic colitis to other patients with chronic diarrhea whose colon biopsy specimens had not revealed increased inflammatory cells. The increased inflammation in their patients with microscopic colitis was confirmed by this analysis. However, in our opinion, their study does not constitute strong proof of an association between microscopic colitis and diarrhea; first, because there is an inherent bias in comparing preselected normal and preselected abnormal biopsy specimens and, second, because they performed no studies to evaluate colonic function. Nevertheless, their report stimulated and enhanced interest in the possible role of microscopic colitis in patients with chronic diarrhea.

The purpose of the present paper is to report studies that were designed to further evaluate the significance of microscopic colitis in patients with chronic diarrhea. There were three main parts of our research: (a) double-blinded analysis of biopsy specimens of colonic mucosa from patients with microscopic colitis compared with prospectively obtained biopsy specimens from control subjects; (b) intestinal perfusion to evaluate water and electrolyte absorption by the colon; and (c) intestinal perfusion to evaluate water and electrolyte absorption by the small intestine.

## Methods

**Informed consent.** This project was approved by the Institutional Review Board for Human Protection of the Baylor University Medical Center and the Subcommittee on Human Studies of the Dallas Veterans Administration Medical Center. Informed written consent was obtained from each subject.

**Patients with microscopic colitis.** The six patients with microscopic colitis were referred to us for evaluation of chronic idiopathic diarrhea. Before referral, each had had a negative conventional diagnostic evaluation which included normal proctosigmoidoscopy and normal double-contrast barium studies of the colon in all six patients, and in addition, normal colonoscopy in three of the patients. They underwent an in-depth diagnostic evaluation for chronic diarrhea, as previously

described (3). No cause of diarrhea could be established. However, either in biopsy specimens obtained by us at proctosigmoidoscopy, or in biopsies reviewed by us from other institutions, we thought the colonic mucosa was nonspecifically inflamed. We therefore did two additional studies: (a) colonoscopy to obtain biopsy samples from multiple areas of the colon, and (b) segmental perfusion to measure intestinal absorption of water and electrolytes. There was no consistent order in which these two procedures were carried out.

The age and sex of the patients and duration of illness are provided in Table I. Chronic and persistent diarrhea and urgency were the major symptoms in each instance. Two of the patients also suffered from fecal incontinence, and three had lost a moderate amount of weight. The patients had some cramping abdominal discomfort associated with diarrhea, but abdominal pain was not a prominent symptom in any patient. None of the patients had ever noted gastrointestinal bleeding, and stool specimens were free of occult blood. There were no physical or laboratory findings suggestive of systemic disease; specifically hemoglobin, serum albumin, and erythrocyte sedimentation rates were normal in each instance. The patients were on no medication at the time of our research studies. However, multiple therapeutic trials had been (or were later) attempted in each patient, with no consistent benefit. One patient (no. 3) improved in association with azulfidine therapy, but this drug did not help the other five patients. Two patients were treated with oral prednisone, with questionable benefit in one instance. None of the patients has, during our follow-up, developed evidence of ulcerative colitis or Crohn's disease.

Using previously described methods (4), we determined the weight, osmolality, and electrolyte composition of stool collected quantitatively while the patients ate a normal diet (for 72 h) and while they fasted. Patients fasted for 12 h before fasting stool collections were begun. During the fast the patients ingested nothing by mouth (not even water); maintenance fluids and glucose were provided intravenously. In most instances, the period of stool collection during fasting continued for 48 h; in some instances the period of stool collection during fasting was only 24 h.

Table I shows the results of stool analysis in the six patients. The mean daily stool output when the patients ate a normal diet was 672 g and was liquid in consistency. During a period of fasting, the diarrhea improved greatly or resolved in all patients except patient 5. Stool osmolality while patients were eating a normal diet ranged from 293 to 366 mosmol/kg. A small-to-moderate sized "osmotic gap" was present (3). None of the patients had blood in the stool or steatorrhea.

Stool and/or urine was analyzed for phenolphthalein, anthraquinone,

sulfate, and magnesium to rule out surreptitious laxative ingestion (3); normal results were obtained in each patient.

**Nondiarrhea control group.** Nine control subjects of a similar age underwent colonoscopy prospectively in order to obtain biopsy specimens for double-blinded comparison. Four of the subjects were recruited by advertising in the newspaper for normal women between the ages of 35 and 70. The ages of the four such women we studied were 37, 58, 68, and 70 yr, respectively. We also obtained colonic biopsy specimens from five men with normal bowel function who were undergoing colonoscopy. The ages of these five men, their reason for colonoscopy, and their colonoscopic findings were as follows: (a) 48 yr, blood per rectum, cecal hyperplastic polyp at colonoscopy; (b) 51 yr, blood per rectum, normal colonoscopy; (c) 62 yr, iron deficiency anemia, normal colonoscopy; (d) 63 yr, blood per rectum, normal colonoscopy except hemorrhoids; (e) 69 yr, follow-up for polyp that had been previously removed, normal colonoscopy. These control subjects did not undergo intestinal perfusion.

**Diarrhea control group.** After initial editorial review of this paper, we were asked to provide an additional control group of patients with chronic diarrhea without colonic inflammation (diarrhea control group). To obtain such a group, we included all other patients that we had examined for chronic diarrhea since 1979, in whom we had carried out both colonoscopy with biopsies from multiple sites and colon perfusion. The colonoscopy in these patients and the histologic interpretation of the biopsy specimens had been considered to be normal. Some clinical data on these patients are provided in Table II.

**Colonoscopy and histologic studies.** Subjects were prepared for colonoscopy with Golytely™ lavage (Braintree Laboratories, Inc., Braintree, MA) (5). The presence or absence of mucosal edema, bleeding, friability, granularity, ulceration, exudate, abnormal visible vascular pattern, and color was noted. Biopsy specimens were taken from the cecum, ascending colon, transverse colon, descending colon, sigmoid colon, and rectum. After routine processing and embedding in paraffin, sections were cut and stained with hematoxylin and eosin. The six specimens from the colon of each subject were read by one or two pathologists (Drs. Vendrell and/or Lee) without knowledge of whether the specimens were from a patient or control subject, or the location of the colon whence the individual biopsy specimens were taken. The pathologist interpreted the colon to be normal or abnormal as regards inflammation. Furthermore, each biopsy specimen was assessed for severity of inflammation on a scale of 0 (normal), 1 (mild inflammation), 2 (moderate inflammation), and 3 (severe inflammation).

**Intestinal perfusion.** Using a balanced electrolyte solution and 0.2%

Table I. Clinical Findings in Six Patients with Microscopic Colitis

Case no.	Age and sex of patients and duration of diarrhea yr	Diet	Stool						
			Weight g/24 h	Osmolality mosmol/liter	Na mM	K mM	Cl mM	HCO <sub>3</sub> mM	Fat g/24 h
1	69, F, 13	Regular	1,105 (liquid)	293	66	41	57	15	3.2
		Fasting	114 (formed)	—	—	—	—	—	—
2	42, F, 1½	Regular	424 (liquid)	328	58	36	43	12	3.1
		Fasting	259 (liquid)	271	53	43	56	16	—
3	59, F, 1½	Regular	401 (liquid)	362	71	57	50	10	4.2
		Fasting	No stool	—	—	—	—	—	—
4	52, F, 5/12	Regular	516 (liquid)	305	58	62	76	15	3.7
		Fasting	20 (soft)	—	—	—	—	—	—
5	57, F, 3/12	Regular	1,078 (liquid)	300	98	24	70	27	2.6
		Fasting	1,513 (liquid)	302	131	13	93	44	—
6	60, M, 2½	Regular	509 (liquid)	366	58	58	34	11.6	5.6
		Fasting	246 (soft)	—	—	—	—	—	—

Table II. Clinical and Colon Perfusion Findings in Nine Patients with Chronic Diarrhea and Apparently Normal Colonic Mucosa

Case no.	Age and sex of patients and duration of diarrhea <i>yr</i>	Stool weight		Final diagnosis	Colon absorption rate <i>ml/h</i>
		Regular diet <i>g/24 h</i>	Fasting <i>g/24 h</i>		
1	54, F, 4	329	59	Idiopathic diarrhea	-168
2	56, M, 4 <sup>1</sup> / <sub>2</sub>	555	600	Idiopathic diarrhea	-127
3	64, F, 9	600	0	Idiopathic diarrhea	+24
4	65, M, 4 <sup>1</sup> / <sub>2</sub>	1,406	1,193	Idiopathic diarrhea	-60
5	72, F, 9 <sup>1</sup> / <sub>2</sub>	1,655	926	Idiopathic diarrhea	-49
6	50, M, 15	169	—	Irritable bowel syndrome	-318
7	36, M, 4	899	—	Pancreatic insufficiency	-306
8	37, F, 9	755	—	Radiation ileitis	-204
9	57, M, 10	327	—	Pancreatic insufficiency	-345

polyethylene glycol as a nonabsorbable marker, water and electrolyte absorption rates in 30-cm segments of jejunum and ileum and in the entire colon were measured in each patient with microscopic colitis (4). Small bowel studies were carried out with a 3-lm tube wherein test solution was infused continuously through one port and collected distally 10 and 40 cm beyond the infusion site. For the colon studies, the test solution was infused into the terminal ileum, and samples were collected from the cecum and from the rectum. The test solution infusion rate was 11 ml/min in the small intestine and 20 ml/min for colon studies. The test solutions for small bowel perfusion contained 10 mM D-xylose so that small bowel absorption of this pentose could be measured. Test solutions were isotonic to plasma and were continuously bubbled with 5% CO<sub>2</sub> and 95% O<sub>2</sub>. Collected samples were analyzed for electrolytes and polyethylene glycol, and absorption rates for the 30-cm jejunal and ileal test segments and for the entire colon (cecum to rectum) were calculated as in previous reports (4). In some instances, <sup>36</sup>Cl and, if available, <sup>24</sup>Na were added to the colon perfusion solution in order to measure unidirectional flux rates of chloride and sodium. The amounts of added isotope and the methods of calculating unidirectional flux rates have been previously described (6).

Normal values for these perfusion studies were established in healthy volunteers who had been previously studied in our laboratory by identical methods. In addition, patients in the diarrhea control group had colon perfusion by the same method.

**Electrical potential difference (PD).**<sup>1</sup> PD was measured in the jejunum, ileum, cecum, and rectum by using a perfused electrolyte solution as a flowing intraluminal electrode and a subcutaneous reference electrode, as previously described (6). The electrodes were connected via 3 M KCl agar bridges and calomel half-cells to the input terminals of a battery-charged electrometer (Keithley Instruments, Inc., Cleveland, OH), and the output was displayed on a chart recorder (Rikadenki, Tokyo, Japan). For jejunal and ileal studies, PD was recorded as part of the intestinal perfusion experiment described in the previous paragraph. Cecal PD was measured at the end of the colon perfusion experiment; the electrolyte solution that formed the intraluminal electrode was infused directly into the cecum. For rectal studies, the lower colon was cleansed with a 750-ml saline enema; after this was evacuated, 750 ml of the same solution was infused into the lower colon over a 15-min period, and a continuous infusion of this solution was then instituted at a rate of 10 ml/min for PD measurement.

## Results

**Colonoscopy and biopsy results in patients with microscopic colitis and nondiarrhea control group.** Each of the patients and

nondiarrhea control subjects had normal-appearing colonic mucosa at the time of colonoscopy. Table III shows the results of blinded review of the six colon biopsy specimens from the six patients and nine control subjects. It is evident that biopsies from the patients were, as a group, readily distinguishable from biopsies from the control subjects. In most instances the pathologists agreed on the interpretation.

Approximately 6 wk after these initial readings, without knowledge of how well the first reading had correlated with clinical findings or with the other pathologist, each pathologist reread all of the coded biopsies. Pathologist A again read each control subject as normal and each patient as abnormal; thus, there was agreement in every instance between the first and second reading. Pathologist B again reread one of the controls as abnormal. However, this control subject was a different subject from that read as abnormal in the first reading. Otherwise, pathologist B interpreted each set of specimens the same way on both occasions.

As described in Methods, each biopsy specimen was evaluated blindly for severity of inflammation on a scale of 0 (normal) to 3 (severe inflammation). Fig. 1 shows the percentage of biopsy specimens from each patient that were interpreted as abnormal (on the first reading). In most but not all instances, all of the biopsy samples from a given patient were judged to be abnormal. The average severity of inflammation from the six specimen sites in each patient is provided in Table IV. The average severity of inflammation in the six patients at each of the six specimen sites is shown in Fig. 2. As noted in this figure, the average severity of inflammation was approximately the same at each site; however, no one specimen site in a given patient would necessarily be representative of the average degree of inflammation throughout the colon.

Table III. Results of Blinded Review of Colon Biopsies

	Interpretation	Controls (n = 9)	Patients (n = 6)	P value*
Pathologist A	Normal	9	0	<0.01
	Inflammation	0	6	
Pathologist B	Normal	8	1	<0.05
	Inflammation	1	5	

\* P value by Fisher's exact test.

1. Abbreviation used in this paper: PD, potential difference.

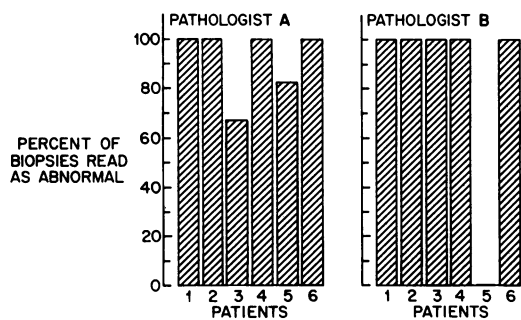


Figure 1. Percentage of the six biopsy specimens from various colonic sites that were read as abnormal in a blinded analysis (first reading).

Fig. 3 shows how the pathologists agreed with each other in their first interpretation of the individual biopsy slides, and Fig. 4 shows a comparison of each pathologist's first and second interpretation of the individual slides. The statistics for these correlations are provided in the figure legends.

The results presented above represent an analysis under strictly blinded conditions, wherein two pathologists did not know if they were reading biopsy specimens from control subjects or from patients. No preliminary discussions took place between the two pathologists to establish criteria or guidelines for normalcy or severity of inflammation. After the blinded analysis was completed, all of the authors examined the biopsy specimens in an open fashion in an attempt to determine the criteria that had been used in the blinded study to grade severity of inflammation, and in order to choose photomicrographs for illustrative purposes.

Representative photomicrographs are shown in Figs. 5-7.

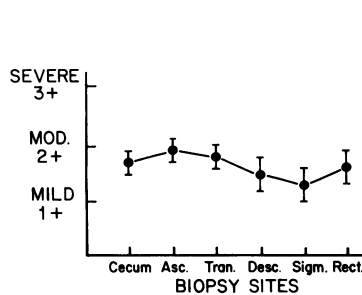


Figure 2. Average severity of colonic inflammation by specimen site. To obtain these results, we first averaged the reading of pathologists A and B to obtain one grade for each biopsy specimen site for each patient. The mean  $\pm$  SEM at each biopsy site ( $n = 6$ ) was then calculated.

In specimens read as showing mild inflammation, the lamina propria was expanded by inflammatory cells, and the surface epithelium usually had reactive changes (i.e., decreased mucus, loss of cellular polarity, and nuclear irregularity). Specimens read as showing moderate inflammation contained either more excessive inflammation of the lamina propria, or similar inflammation plus cryptitis. Two of the patients had at least one of their specimens read as severely inflamed (patients 1 and 6). These specimens had even more inflammation in the lamina propria (patient 1) or were interpreted as having a crypt abscess (patient 6). In patient 6, crypt abscesses were read in four of the six biopsies by pathologist A, and in one of the six biopsies by pathologist B.

As is evident from the previous paragraph and from the average results depicted in Table IV, the photomicrographs shown in Figs. 6 and 7 are representative of the spectrum of abnormality that was present in most of the biopsy specimens from most of the patients. A few isolated biopsies were read as showing more severe inflammation than is shown in Fig. 7, either because of more intense inflammation in the lamina propria or because of what was interpreted as a crypt abscess.

Table IV. Average Severity of Colonic Inflammation and Results of Colonic Perfusion with a Balanced Electrolyte Solution in Patients and Healthy Subjects

Patient	Severity of inflammation according to pathologist*		Net movement‡					PD§	
	A	B	H <sub>2</sub> O	Na	Cl	HCO <sub>3</sub>	K	Proximal	Rectal
			ml/h	meq/h	meq/h	meq/h	meq/h	mV	mV
1	1.5	1.5	-28	-8.0	-7.4	-0.1	+1.0	-32	-37
2	1.2	1.8	-12	-5.8	-4.1	-0.5	+1.4	—	—
3	1.2	1.5	-32	-4.5	-5.6	+3.0	+0.5	—	-47
4	1.5	2	0	-3.1	-4.7	-0.5	+0.1	-12	-45
5	0.8	0	-72	-14.8	-16.5	+0.2	+1.3	-37	-46
6	2.0	2.8	-12	-8.3	-11.2	0	+0.9	—	-34
Mean	1.4	1.6	-26 <sup>  </sup>	-7.4 <sup>  </sup>	-8.2 <sup>  </sup>	+0.3 <sup>¶</sup>	+0.9 <sup>¶</sup>	-27	-42
Healthy subjects**									
Mean	—	—	-159	-24.2	-26.4	+3.2	+0.2	-22	-34
SEM	—	—	13	2.0	2.1	0.5	0.1	3	4
SD	—	—	63	9.6	9.9	2.5	0.5	12	13
Range	—	—	-70, -270	-11.0, -40.2	-10.1, -42.2	+7.7, -1.1	+1.0, -1.0		

\* Severity graded 0-4, i.e., normal to severe inflammation (see text). ‡ (-) Net absorption; (+) net secretion; values are for entire colon. § (-) Lumen negative. <sup>||</sup>  $P < 0.001$  by group  $t$  test. <sup>¶</sup>  $P < 0.01$  by group  $t$  test. \*\*  $n = 23$  for colonic perfusion;  $n = 20$  for proximal colon PD;  $n = 10$  for rectal PD.

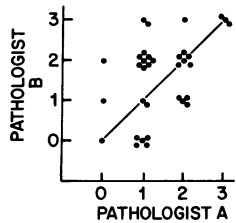


Figure 3. Comparison of two pathologists' readings of severity of inflammation in individual biopsies from patients with microscopic colitis (first reading). 0, normal; 1, mild inflammation; 2, moderate inflammation; 3, severe inflammation. Results from control biopsies are not shown since the vast majority were read as normal by both pathologists.  $P$  value

(by  $\chi^2$  analysis): patients only (as in figure),  $P < 0.01$ ; if controls also considered,  $P < 0.001$ .

None of the biopsy specimens contained mucosal ulcerations or granulomas, and none of the biopsies contained an exudate.

Several months after the analyses described above, the slides from the nine control subjects and the six patients with microscopic colitis were recoded and reread by pathologist B with regard to 14 different histologic criteria. When the slides were decoded, the patients were found to be abnormal (by  $\chi^2$  test) in the following nine respects: cryptitis ( $P < 0.005$ ); neutrophils in the surface epithelium ( $P < 0.001$ ); reactive changes in the surface epithelium ( $P < 0.001$ ); excess mitotic figures in the crypt epithelium ( $P < 0.005$ ); goblet cell depletion ( $P < 0.001$ ); excess inflammatory cells in the lamina propria ( $P < 0.001$ ); excess neutrophils in the lamina propria ( $P < 0.001$ ); excess lymphocytes in the lamina propria ( $P < 0.001$ ); and excess plasma cells in lamina propria ( $P < 0.001$ ). In the following five respects, the biopsy specimens from the patients were not statistically significantly different from specimens from the control group: crypt abscesses, epithelial exudate and/or ulceration, paneth cell metaplasia, crypt distortion, and granuloma formation.

**Reanalysis of biopsy specimens to include diarrhea control group.** Approximately 4 mo after having reviewed the slides from the microscopic colitis patients and from the healthy controls, the slides from all three groups were recoded and submitted to pathologist A for blinded reading. The nine healthy controls and the nine diarrhea controls were all read as normal. Five of the patients with microscopic colitis were read as abnormal, and one was read as normal. This last patient had earlier been read as abnormal by pathologist A but was the same patient that had been read as normal by pathologist B. The  $P$  value for the differences in these readings was  $< 0.01$ .

**Colonic absorption and PD.** Table IV shows the results of colonic perfusion and PD in each patient (average severity of colonic inflammation is shown for comparison). Mean net

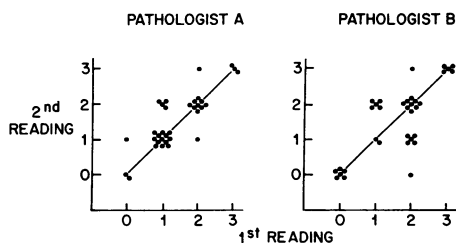


Figure 4. Comparison of first and second reading of individual biopsy specimens from the patients with microscopic colitis. See legend of Fig. 3 for code.  $P$  value (by  $\chi^2$  analysis):  $P < 0.001$  for both pathologists, with patients only (as in figure) or with both patients and controls.

colonic water absorption rate in the six patients was 26 ml/h, which is severely reduced compared with the normal value of 159 ml/h. Net sodium and chloride absorption was also reduced, but net potassium movement was similar in the patients and normal subjects. Normally, bicarbonate is secreted by the colon; this secretion was reduced in the patients with microscopic colitis. PD values were approximately the same in the patients as in the normal subjects. The patient whose biopsy specimens were read as having the smallest amount of inflammation and whose biopsies were sometimes read as normal (patient 5) had the highest rate of colonic absorption. Otherwise, the severity of inflammation could not be well correlated with the degree of colonic malabsorption, possibly because there was so little variation in severity of inflammation and in severity of fluid malabsorption.

Unidirectional fluxes of sodium and chloride were measured in some of the patients, and the results are shown in Table V. Average lumen-to-plasma and plasma-to-lumen fluxes of sodium and chloride were reduced in the patients when compared with control subjects. The difference in chloride fluxes was statistically significant; only two studies were done with isotopic sodium, so statistical analysis of the difference in average sodium flux rates was not possible.

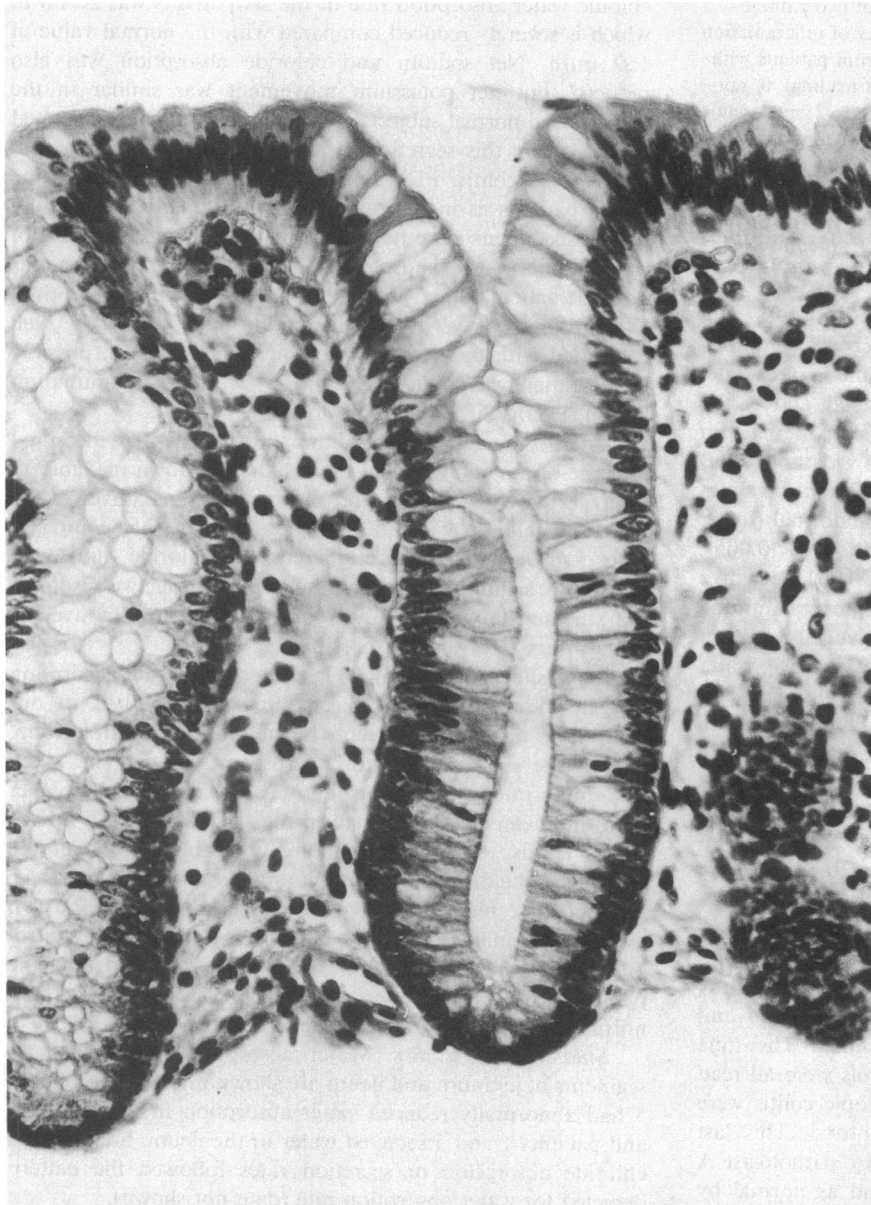
Fig. 8 shows individual values for colonic water absorption rate in the 23 normal subjects previously studied in our laboratory, in the nine patients in the diarrhea control group, and in the six patients with microscopic colitis. The mean absorption rate in both control groups was significantly higher than the mean absorption rate in the six patients with microscopic colitis. As previously noted in Table II, five of the patients in the diarrhea control group had idiopathic diarrhea; three of these had reduced colonic water absorption and two absorbed normally. The three patients in the diarrhea control group in whom a specific diagnosis was established, and the patient in whom we diagnosed irritable bowel syndrome, had normal colonic absorption (Table II and Fig. 8).

**Small bowel studies.** Water absorption rates in 30-cm segments of jejunum and ileum are shown in Table VI. Patient 5 had abnormally reduced water absorption in the jejunum, and patients 1 and 5 secreted water in the ileum. Sodium and chloride absorption or secretion rates followed the pattern depicted for water absorption rate (data not shown).

The test solutions perfused into the small bowel contained 10 mM D-xylose to serve as a marker for nonelectrolyte absorption rate. As shown in Table VI, D-xylose absorption was within the normal range in the two patients who secreted fluid in the ileum and in the jejunum of the patient who absorbed no fluid in the jejunum. Thus, the small bowel transport abnormality in these two patients was somewhat specific for electrolytes and water, and did not involve a generalized depression of absorptive function.

## Discussion

**Colonic inflammation.** We evaluated whether the apparent nonspecific inflammation in colonic mucosa from patients with "microscopic colitis" (see Introduction) was actually abnormal when compared with biopsy specimens from people who had normal bowel function (nondiarrhea control group) and when compared with patients with chronic diarrhea and apparently normal colonic mucosa (diarrhea control group).

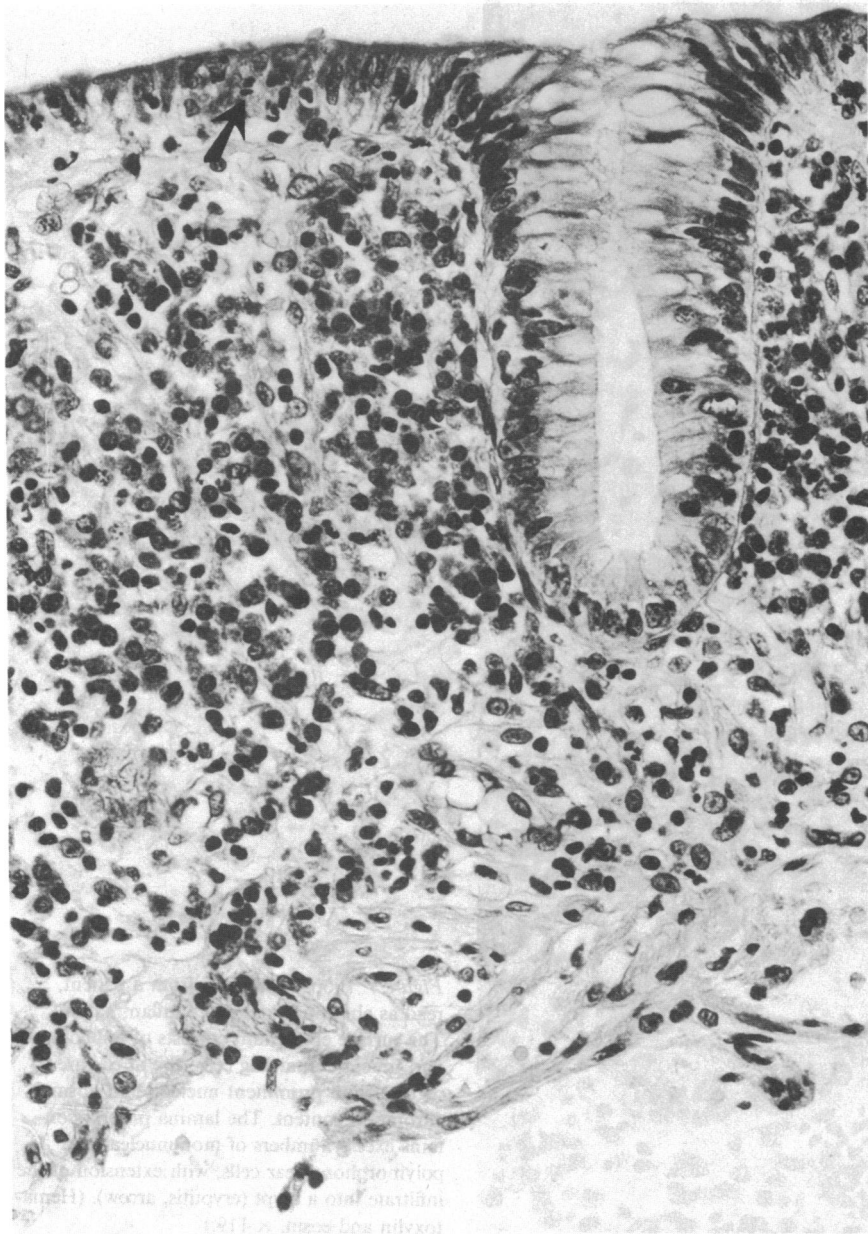


*Figure 5.* Biopsy specimen from a normal subject, read as normal. The epithelium consists of tall columnar, mucus-secreting cells. The lamina propria contains sparse numbers of mononuclear cells. (Hematoxylin and eosin,  $\times 119$ .)

The results of a blinded evaluation clearly showed that colonic biopsy specimens from patients with microscopic colitis are abnormal. These biopsies contained neutrophils in the surface epithelium, excess neutrophils and round cells in the lamina propria, cryptitis, reactive changes, and goblet cell depletion. Although not all of the six specimens from different areas of the colon were considered abnormal in every patient, most of them were. Thus, the abnormality is best characterized as diffuse rather than patchy. None of the biopsy specimens revealed an exudate, erosion, or ulceration of the mucosa; this is consistent with the completely normal appearance of the colonic mucosa by barium x-ray and by colonoscopy.

The cause of this inflammation is not known. The observation that patients with chronic diarrhea due to noncolonic disease have normal colonic histology (cases 6–9 in Table II) suggests that chronic diarrhea per se does not cause inflammation of the colonic mucosa. If it is assumed, for the sake of

discussion, that the diarrhea and the inflammation began at approximately the same time, the abrupt onset (within a week) of the diarrhea that was noted by our patients might suggest an infectious process. However, extensive and repeated cultures in our routine hospital laboratory have not revealed a pathogen. In addition, it is possible that while an infection initiated the onset of inflammation, the chronicity is due rather to host immune responses. However, no evidence for an autoimmune process has been found. Since the etiology of other chronic inflammatory bowel diseases is unknown, it is impossible to know whether our patients have a forme fruste of chronic ulcerative colitis or Crohn's disease of the colon. It should be noted, however, that some of our patients have had diarrhea for as long as 13 yr and yet none of them has developed other features of ulcerative colitis or Crohn's disease, such as rectal bleeding, fever, arthralgia, abnormal barium studies of the small or large bowel, or visual abnormality of colonic or



*Figure 6.* Biopsy specimen from a patient, read as abnormal, mild inflammation. The surface epithelium shows loss of polarity, decreased cell height, and contains decreased mucus. An occasional polymorphonuclear leukocyte is present within the surface epithelium (arrow). The lamina propria demonstrates an increased number of mononuclear and polymorphonuclear cells. There is no distortion of crypt architecture. (Hematoxylin and eosin,  $\times 119$ .)

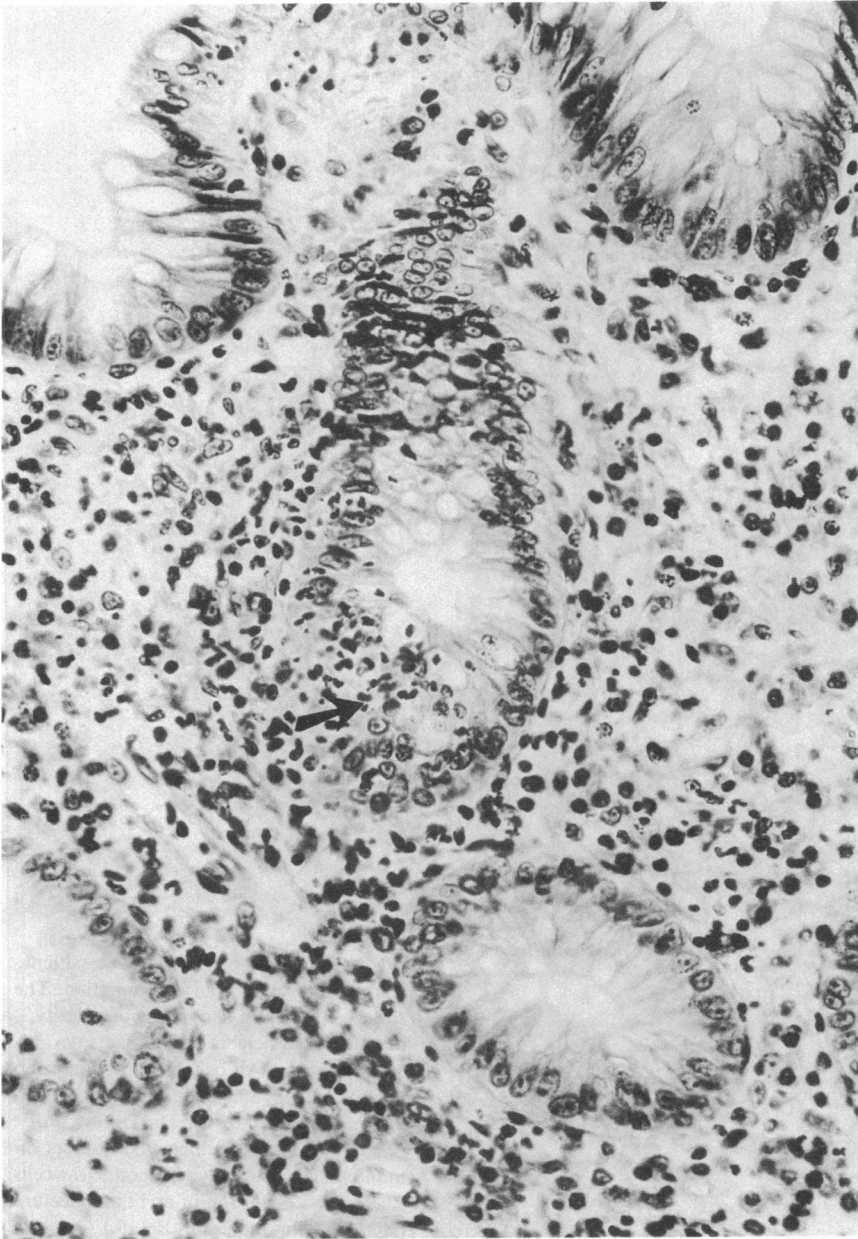
rectal mucosa as seen by colonoscopy or sigmoidoscopy. Therefore, if our patients do have a mild form of ulcerative colitis or Crohn's disease, this form must be relatively nonprogressive and persistent with diarrhea as its only clinical manifestation. Furthermore, our patients do not have so-called "minimal change colitis" (7), in that patients with that particular entity often present with bloody diarrhea, have laboratory abnormalities of systemic illness (e.g., elevated sedimentation rate, anemia, and hypoalbuminemia), and have overt mucosal abnormalities seen by colonoscopy.

*Colonic absorption.* A second major part of our research dealt with the question of whether the nonspecific colonic inflammation in these patients was associated with reduced colonic absorption of water and electrolytes. Using the steady state perfusion method, we showed that colonic fluid absorption was severely impaired. We should emphasize that the healthy controls we used for perfusion studies were neither age-

sex-matched to the patients. However, the group of normal subjects contained women and men in the same age range as our patients.

Colon absorption rate in the patients with microscopic colitis was also significantly less than in our diarrhea control group. However, three of the five patients in the diarrhea control group with idiopathic diarrhea also had decreased colonic absorption. The reason for defective colonic absorption in patients with idiopathic diarrhea and normal colonic histology is unknown, but it conceivably could be mediated by a toxin, an undetected hormone abnormality, or by abnormal nerve or paracrine activity. The findings in these three patients make it clear that normal colonic histology does not guarantee normal colonic function. On the other hand, in our experience, colonic inflammation is uniformly associated with reduced colonic absorption of water and electrolytes.

Our studies cannot establish the precise mechanism of



*Figure 7.* Biopsy specimen from a patient, read as abnormal, moderate inflammation. The surface epithelium consists of tall columnar, mucus-containing cells; the nuclei are irregular, with prominent nucleoli and normal chromatin content. The lamina propria contains excess numbers of mononuclear and polymorphonuclear cells, with extension of the infiltrate into a crypt (cryptitis, arrow). (Hematoxylin and eosin,  $\times 119$ .)

reduced colonic absorption in patients with microscopic colitis, but the results are consistent with three effects: (a) reduced active sodium and chloride absorption, (b) inhibition of chloride/bicarbonate exchange (8), and (c) decreased passive permeability of the mucosa. The evidence favoring reduced active ion absorption consists of the reduction of lumen-to-plasma flux of sodium and chloride. The evidence suggesting inhibition of chloride/bicarbonate exchange is the reduced bicarbonate secretion rate in association with reduced chloride absorption. The evidence for decreased passive permeability is the reduction of plasma-to-lumen flux of sodium and chloride. Our finding of a normal PD across the mucosa is consistent with these effects, in that reduced active sodium absorption would reduce PD, whereas reduced passive permeability to chloride would be expected to increase PD in response to the residual active

sodium absorption; the opposing results could yield no net change in the PD.

Assuming that deranged colonic absorption in patients with microscopic colitis is due to the nonspecific inflammation, the mechanism by which inflammation results in deranged absorption is highly speculative. Possibilities would include local release of substances from inflammatory cells that inhibit active absorption and tighten mucosal barriers to passive ion movement.

In considering the meaning of the observed colonic malabsorption of water and electrolytes, it should be pointed out that the perfusion method measures colonic absorptive capacity under steady state, high flow rate conditions. The average absorptive capacity of our control subjects was  $\sim 3,800$  ml/24 h (159 ml/h), whereas for our patients with microscopic colitis



Table V. Unidirectional Fluxes of Sodium and Chloride during Colonic Perfusion with a Balanced Electrolyte Solution

Patient	Mean concentration in test segment*		Unidirectional fluxes			
	Sodium	Chloride	Sodium		Chloride	
	meq/liter	meq/liter	L → P	P → L	L → P	P → L
1	141	105	—	—	11.8	3.1
4	141	106	9.8	3.1	6.4	1.7
5	142	104	—	—	24.1	7.6
6	141	104	9.7	1.3	21.5	10.3
Mean	141	105	9.8	2.2	15.9‡	5.7‡
Healthy subjects (n = 9)						
Mean	141	100	28.7	7.6	36.5	15.4
SEM	1	1	4.0	1.1	5.0	2.3
SD	3	2	11.9	3.2	14.9	7.0
Range	135–145	97–104	14.5–47.0	3.7–13.2	18.6–58.0	5.8–27.4

L → P, lumen-to-plasma flux; P → L, plasma-to-lumen flux. \* Mean concentration is the arithmetic mean of the concentration at the proximal and distal sites; the entire colon is the test segment. ‡ P < 0.025 by group t test.

the average absorptive capacity was only 624 ml/24 h (26 ml/h). Under normal conditions, 0.6–1.5 liters of fluid is delivered to the colon each day (3), probably in boluses (after meals), rather than at a steady rate; consequently, even moderate reductions in absorptive capacity (as measured by steady state perfusion) might result in diarrhea. There seems little doubt, therefore, that the severely reduced colonic absorptive capacity for water and electrolytes in our patients could contribute to the development of their diarrhea. This does not, of course, exclude a role for other contributing factors, such as abnormal small bowel function (see below) or abnormal colonic motility.

The magnitude of colon malabsorption of water and electrolytes is approximately the same in our patients with microscopic colitis as has been previously reported in patients with proctocolitis due to idiopathic inflammatory bowel disease (9). However, in Crohn's colitis, the plasma-to-lumen flux is abnormally increased (10), rather than decreased as in microscopic colitis. Moreover, in ulcerative colitis the PD is markedly reduced (11), whereas it is normal in microscopic colitis. These results in ulcerative and Crohn's colitis suggest abnormally increased mucosal permeability, whereas the results in microscopic colitis suggest reduced mucosal permeability. Perhaps

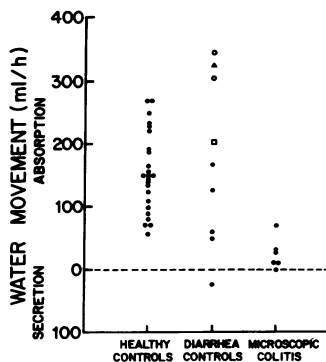


Figure 8. Rate of water movement in the colon for individual subjects and patients. In the diarrhea control group, (●) patients with idiopathic diarrhea; (○) patients with exocrine pancreatic insufficiency; (□) patient with radiation ileitis; and (Δ) patient with probable irritable bowel syndrome.

this difference is explained by the mucosal ulceration that is characteristic of ulcerative and Crohn's colitis, whereas the epithelial lining is intact in microscopic colitis.

*Small bowel studies.* Two of our six patients had ileal secretion of water and electrolytes, and one of these also had abnormally low fluid absorption in the jejunum. In the other four patients, water and electrolyte absorption rates were within normal limits.

In the one patient with jejunal malabsorption of water and electrolytes, a jejunal biopsy specimen was interpreted retrospectively as showing a mild increase in inflammatory cells in the lamina propria. Although this was not a "blinded" analysis, as in our colon biopsy results, this finding suggests that this patient had mild inflammation of her jejunum as well as in her colon. The other five patients had a normal jejunal biopsy specimen, consistent with their normal absorption of water and electrolytes. Ileal biopsy samples were not obtained in any of the six patients, so we do not know whether or not the ileal water and electrolyte malabsorption in two of our patients was associated with inflammation.

As far as we can tell, small bowel absorption of other substances was grossly intact, since none of our patients had an abnormal xylose test, abnormal Schilling test, or steatorrhea, and since intestinal absorption of D-xylose during the small bowel perfusion was within normal range (even in the two patients who exhibited ileal secretion of water, sodium and chloride). An apparently selective malabsorption of water and electrolytes is suggestive of diarrhea produced by neuroendocrine hormones, such as vasoactive intestinal polypeptide or calcitonin. However, in all but one of our cases the jejunum was absorbing normally, and this is strong evidence against hormone-induced diarrhea (4). In addition, serum levels of vasoactive intestinal polypeptide and calcitonin were normal in each patient.

Small bowel malabsorption of water and electrolytes might have contributed to the diarrhea in some of our patients. In

Table VI. Net Water and Xylose Absorption during Small Intestinal Perfusion with a Balanced Electrolyte Solution in Patients and Healthy Subjects

	Jejunum		Ileum	
	H <sub>2</sub> O	Xylose	H <sub>2</sub> O	Xylose
	ml/h per 30 cm	mmol/h per 30 cm	ml/h per 30 cm	mmol/h per 30 cm
<b>Patient</b>				
1	-109	-1.36	+7	-0.40
2	-162	-1.41	-36	-0.23
3	-113	-1.74	-36	-0.57
4	-120	-1.49	-54	-0.41
5	0	-1.12	+18	-0.38
6	-48	-0.63	-48	-0.60
<b>Healthy subjects*</b>				
Mean	-107	-1.53	-76	-0.53
SEM	10	0.12	8	0.07
SD	48	0.54	40	0.23
Range	-18 to -217	-0.83 to -2.98	-6 to -175	-0.11 to -0.89

\* For water absorption:  $n = 23$  for jejunal perfusion;  $n = 26$  for ileal perfusion. For xylose absorption:  $n = 20$  for jejunal perfusion;  $n = 12$  for ileal perfusion.

this regard, it is interesting that the two patients with the most severe diarrhea had ileal malabsorption of water and electrolytes, and that the patient whose diarrhea was most severe during a fast had jejunal as well as ileal and colonic malabsorption of water and electrolytes.

**Clinical significance.** In the past, most critical clinicians and investigators have tended to disregard "mild-to-moderate, nonspecific inflammation" of intestinal (and biliary) mucosa. There are several reasons for this attitude. First, normal mucosa contains some chronic inflammatory cells, and in most instances a clear delineation of when the number and/or the type of inflammatory cells in the lamina propria becomes abnormal is not made. Second, there is usually no evidence that such changes are associated with abnormal function to explain the patient's symptoms. Finally, there is concern that overtreatment, including inappropriate steroid therapy or surgery, might result if clinical significance were attributed to such inflammation.

It is on the background of these important considerations that we set out to evaluate the significance of an apparent nonspecific inflammation of colonic mucosa in patients with idiopathic chronic diarrhea. We have shown that this inflammation, which is called microscopic colitis to denote the fact that colonic mucosa appears normal to the naked eye, actually represents a histologic abnormality, and that it is associated with colonic malabsorption of water and electrolytes. The cause of the inflammation is unknown, and it must be emphasized that our data do not prove that colonic inflammation is the primary event in this syndrome. Most likely, rigorous testing of such a hypothesis would require the isolation of a transmissible cause of the colitis so that Koch's postulates could be applied; another alternative would be to eliminate the inflammation with an effective therapy, and see if diarrhea disappeared. Unfortunately, neither approach is possible at the present time. Therefore, on the one hand, it would be incorrect to say that microscopic colitis has been shown to be a cause

of chronic diarrhea. On the other hand, the fact that microscopic colitis is associated with colonic malabsorption of water and electrolytes indicates that this histologic abnormality has clinical significance, inasmuch as such malabsorption almost certainly is a major contributing cause of the patient's chronic diarrhea. For the moment, we think it is best to refer to this syndrome as microscopic colitis, but to keep in mind that the abnormality may be more generalized (microscopic enterocolitis) in some patients.

Although we believe it is helpful to know that microscopic colitis has this clinical significance, we fear that our report might be used to justify prednisone therapy in these patients. In our opinion, the risks of such therapy are likely to be greater than the possible and unproved benefits.

### Acknowledgments

The authors thank Stephen Morawski and Carol Santa Ana for their expert assistance, Jean Harber and Janie Francis for preparing the manuscript, and Drs. Larry Schiller and Mark Feldman for their helpful suggestions.

This work was supported by grant AM-26794 from the National Institute of Arthritis, Diabetes, Digestive and Kidney Diseases; grant 1-K08-AM-01204, Clinical Investigator Award, to Dr. Bo-Linn from the same source; and The Southwestern Medical Foundation's Abbie K. Dreyfuss Fund, Dallas, Texas.

### References

1. Read, N. W., G. J. Krejs, M. G. Read, C. A. Santa Ana, S. G. Morawski, and J. S. Fordtran. 1980. Chronic diarrhea of unknown origin. *Gastroenterology*. 78:264-271.
2. Kingham, J. G. C., D. A. Levison, J. A. Ball, and A. M. Dawson. 1982. Microscopic colitis—a cause of chronic watery diarrhoea. *Br. Med. J.* 285:1601-1604.
3. Krejs, G. J., and J. S. Fordtran. 1983. Diarrhea. In *Gastrointestinal Disease: Pathophysiology, Diagnosis, Management*. M. H. Sleisenger

and J. S. Fordtran, editors. W. B. Saunders Company, Philadelphia. 257-280.

4. Krejs, G. J., J. H. Walsh, S. G. Morawski, and J. S. Fordtran. 1977. Intractable diarrhea: intestinal perfusion studies and plasma VIP concentrations in patients with pancreatic cholera syndrome and surreptitious ingestion of laxatives and diuretics. *Am. J. Dig. Dis.* 22: 280-292.

5. Davis, G. R., C. A. Santa Ana, S. G. Morawski, and J. S. Fordtran. 1980. Development of a lavage solution associated with minimal water and electrolyte absorption or secretion. *Gastroenterology*. 78:991-995.

6. Davis, G. R., C. A. Santa Ana, S. G. Morawski, and J. S. Fordtran. 1982. Permeability characteristics of human jejunum, ileum, proximal colon, and distal colon: results of potential difference measurements and unidirectional fluxes. *Gastroenterology*. 83:884-850.

7. Elliott, P. R., C. B. Williams, J. E. Lennard-Jones, A. M.

Dawson, C. L. Bartram, B. M. Thomas, E. T. Swarbrick, and B. C. Morson. 1982. Colonoscopic diagnosis of minimal change colitis in patients with a normal sigmoidoscopy and normal air-contrast barium enema. *Lancet*. I:650-651.

8. Davis, G. R., S. G. Morawski, C. A. Santa Ana, and J. S. Fordtran. 1983. Evaluation of chloride/bicarbonate exchange in the human colon in vivo. *J. Clin. Invest.* 71:201-207.

9. Harris, J., and R. Shields. 1970. Absorption and secretion of water and electrolytes by the intact human colon in diffuse untreated proctocolitis. *Gut*. 11:27-33.

10. Head, L. H., J. W. Heaton, and R. M. Kivel. 1969. Absorption of water and electrolytes in Crohn's disease of the colon. *Gastroenterology*. 56:571-579.

11. Rask-Madsen, J., and M. Dalmark. 1973. Decreased transmural potential difference across the human rectum in ulcerative colitis. *Scand. J. Gastroenterol.* 8:321-326.