

humans and livestock in Mauritania and other African countries.

**Martin Eiden,
Ariel Vina-Rodriguez,
Bezeid O. El Mamy,
Katia Isselmou, Ute Ziegler,
Dirk Höper, Susanne Jäckel,
Anne Balkema-Buschmann,
Hermann Unger, Baba Doumbia,
and Martin H. Groschup**

Author affiliations: Friedrich-Loeffler-Institut, Greifswald-Insel Riems, Germany (M. Eiden, A. Vina-Rodriguez, U. Ziegler, D. Höper, S. Jäckel, A. Balkema-Buschmann, M.H. Groschup); Centre National de l'Élevage et de Recherches Vétérinaires, Nouakchott, Mauritania (B.O. El Mamy, K. Isselmou, B. Doumbia); Joint FAO/IAEA Division of Nuclear Techniques in Food and Agriculture, Vienna, Austria (H. Unger); and Ministère du Développement Rural, Nouakchott (B. Doumbia)

DOI: <http://dx.doi.org/10.3201/eid2012.140787>

References

- Gerrard SR, Li L, Barrett AD, Nichol ST. Ngari virus is a Bunyamwera virus reassortant that can be associated with large outbreaks of hemorrhagic fever in Africa. *J Virol.* 2004;78:8922–6. <http://dx.doi.org/10.1128/JVI.78.16.8922-8926.2004>
- Briese T, Bird B, Kapoor V, Nichol ST, Lipkin WI. Batai and Ngari viruses: M segment reassortment and association with severe febrile disease outbreaks in East Africa. *J Virol.* 2006;80:5627–30. <http://dx.doi.org/10.1128/JVI.02448-05>
- Zeller HG, Diallo M, Angel G, Traoré-Lamizana M, Thonnon J, Digoutte JP, et al. Ngari virus (Bunyaviridae: Bunyavirus). First isolation from humans in Senegal, new mosquito vectors, its epidemiology [in French]. *Bull Soc Pathol Exot.* 1996;89:12–6.
- Bowen MD, Trappier SG, Sanchez AJ, Meyer RF, Goldsmith CS, Zaki SR, et al. RVF Task Force. A reassortant bunyavirus isolated from acute hemorrhagic fever cases in Kenya and Somalia. *Virology.* 2001;291:185–90. <http://dx.doi.org/10.1006/viro.2001.1201>
- Jäckel S, Eiden M, El Mamy BO, Isselmou K, Vina-Rodriguez A, Doumbia B, et al. Molecular and serological studies on the Rift Valley fever outbreak in Mauritania in 2010. *Transbound Emerg Dis.* 2013;60(Suppl 2):31–9. <http://dx.doi.org/10.1111/tbed.12142>
- Lambert AJ, Lanciotti RS. Consensus amplification and novel multiplex sequencing method for S segment species identification of 47 viruses of the *Orthobunyavirus*, *Phlebovirus*, and *Nairovirus* genera of the family *Bunyaviridae*. *J Clin Microbiol.* 2009;47:2398–404. <http://dx.doi.org/10.1128/JCM.00182-09>
- Steglich C, Grund C, Ramp K, Breithaupt A, Höper D, Keil G, et al. Chimeric Newcastle disease virus protects chickens against avian influenza in the presence of maternally derived NDV immunity. *PLoS ONE.* 2013;8:e72530. <http://dx.doi.org/10.1371/journal.pone.0072530>
- Groseth A, Weisend C, Ebihara H. Complete genome sequencing of mosquito and human isolates of Ngari virus. *J Virol.* 2012;86:13846–7. <http://dx.doi.org/10.1128/JVI.02644-12>
- Gonzalez JP. Activités du laboratoire d'écologie virale. Rapp sur la fonct tech de l'Institut Pasteur de Dakar. 1988;89:100–18.
- El Mamy AB, Baba MO, Barry Y, Isselmou K, Dia ML, El Kory MO, et al. Unexpected Rift Valley fever outbreak, northern Mauritania. *Emerg Infect Dis.* 2011;17:1894–6. <http://dx.doi.org/10.3201/eid1710.110397>

Address for correspondence: Martin H. Groschup, Friedrich-Loeffler-Institut, Südufer 10, 17493 Greifswald-Insel Riems, Germany; email: martin.groschup@fli.bund.de

Peste des Petits Ruminants Virus, Eastern Asia

To the Editor: Peste des petits ruminants virus (PPRV) is reported globally with increasing frequency. Recently, PPRV has been detected in areas where it is considered endemic and in neighboring areas where it previously has not been reported. The reporting of “first cases” in regions where PPRV has been considered endemic is of little surprise and perhaps represents increased interest both in agricultural practices and diagnostic capacity (1–3). Increased

development of the small ruminant health sector, expanding small ruminant populations, increased trade movement, and rinderpest eradication might all have affected PPRV detection (4). The latter theory is of great interest because rinderpest eradication may have affected the epidemiology of PPRV through complete removal of cross-protective rinderpest infection of small ruminants and cessation of small ruminant vaccination with the rinderpest vaccine to prevent PPRV infection. Indeed, the potential effect of rinderpest eradication on PPRV epidemiology should not be understated because it might have profoundly affected PPRV emergence by enabling free transmission and spread of the virus, perhaps overcoming the genetic and geographic bottlenecks created by rinderpest circulation and/or the use of rinderpest vaccines. In addition, rinderpest eradication has highlighted the possibility that PPRV could be eradicated by using comparable systems and tools (5).

Historically, PPRV has been identified across much of the developing world; genetic analyses has grouped viruses into 4 lineages that were originally thought to be phylogeographically restricted (6). However, in recent years, lineages of PPRV have apparently emerged in new areas. This has been most convincingly demonstrated with the detection of lineage IV virus—a lineage thought restricted to the Indian subcontinent and the Middle East—across northern and central Africa (online Technical Appendix Figure, <http://wwwnc.cdc.gov/EID/article/20/12/14-0907-Techapp1.pdf>) (7,8). However, reporting of PPRV in areas where it has not been previously detected is perhaps of greater interest. This is increasingly the case across southern and eastern Asia where virologic and serologic evidence of circulating PPRV has been reported (6)

During 2014, PPRV caused extensive agricultural losses across

China. Although regions within China had previously reported relatively small outbreaks, during December 2013–June 2014, the virus appears to have greatly extended its distribution. In 2007, PPRV was detected for the first time in the Ngari region of southwestern Tibet (9). This emergence was thought to have arisen through the circulation of mild forms of PPRV infection and the unfamiliarity of agricultural workers and professionals (e.g., veterinarians, farmers, livestock owners) with the disease and the inability to differentiate between mild forms of PPRV infections and other diseases of small ruminants. PPRV returned in 2008 and 2010 and was controlled by using stamping-out procedures, animal movement control, and increased screening of herds. The disease was controlled without the use of vaccines in 2008; vaccination was used in 2010 (10).

Three years passed without reports of PPRV infections in Tibet or elsewhere in China before the virus was detected in Xinjiang, China's largest administrative division, in December 2013. Xinjiang, an area of 1.6 million km², borders Afghanistan, India, Kazakhstan, Kyrgyzstan, Mongolia, Pakistan, Russia, and Tajikistan, several of which have reported PPRV infection. Within 2 months, PPRV had caused 3 outbreaks with rates of illness (and death) of 17% (2%), 58% (11%), and 79% (19%), respectively. Measures to contain these outbreaks were implemented as in 2007; however, during April and May 2014, the number of PPRV outbreaks increased sharply across much of China, including in Anhui, Guizhou, Guangxi, Hubei, Hunan, Shanxi, Xinjiang, Yunnan, and Zhejiang Provinces (Figure). The origin of these outbreaks remains undefined; however, the ability of the virus to circulate causing mild clinical disease and its presence in numerous bordering countries suggest several possibilities regarding the source of disease, including spread from the

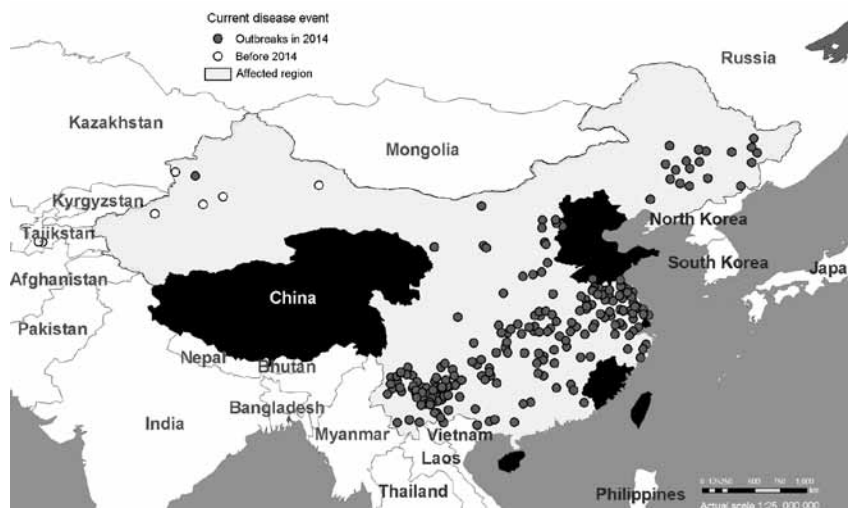


Figure. Outbreaks of peste des petits ruminants virus across China during December 2013–May 2014. Data are from ProMed alerts during the period described (10).

original China outbreaks. Similarly the threat of further spread from China to neighboring countries cannot be ignored.

Once the current situation has been resolved, full genetic analysis of the viruses causing the outbreaks should be conducted because it might indicate the direction of spread. A further area of interest is the application and choice of control measures. Although predicting the spread of a viral pathogen is impossible, especially across the vast distances involved in the current reports, the experiences in China might influence future responses to incursions of PPRV into areas where PPRV previously has not been documented. The current lack of disease in areas where vaccination was reported in 2010 could explain the continued absence of disease from such areas while other regions are significantly affected (10). Effective vaccines against PPRV have been available for decades and will now, as both reactive and preventive tools, aid in controlling and preventing onward transmission of this viral pathogen. Once the situation in China is under control, where this emerging infection of small ruminants will appear next remains to be seen.

Acknowledgments

We thank Helen Roberts for generating the Figure.

A.C.B. and S.P. are funded in part by a Biotechnology and Biological Sciences Research Council Combating Infectious Diseases of Livestock for International Development grant BB/H009485/1.

**Ashley C. Banyard,
Zhiliang Wang,
and Satya Parida**

Author affiliations: Animal and Plant Health Agency, Weybridge, UK (A.C. Banyard); Ministry of Agriculture of the People's Republic of China, Qingdao, China (Z. Wang); and The Pirbright Institute, Pirbright, UK (S. Parida)

DOI: <http://dx.doi.org/10.3201/eid2012.140907>

References

1. Cosseddu GM, Pinoni C, Polci A, Sebhatu T, Lelli R, Monaco F. Characterization of peste des petits ruminants virus, Eritrea, 2002–2011. *Emerg Infect Dis.* 2013;19:160–1. <http://dx.doi.org/10.3201/eid1901.121072>
2. El Arbi AS, El Mamy AB, Salami H, Isselmou E, Kwiatek O, Libeau G, et al. Peste des petits ruminants virus, Mauritania. *Emerg Infect Dis.* 2014;20:333–6. <http://dx.doi.org/10.3201/eid2002.131345>
3. Munir M, Zohari S, Suluku R, Leblanc N, Kanu S, Sankoh FA, et al. Genetic

- characterization of peste des petits ruminants virus, Sierra Leone. *Emerg Infect Dis.* 2012;18:193–5. <http://dx.doi.org/10.3201/eid1801.111304>
4. Libeau G, Diallo A, Parida S. Evolutionary genetics underlying the spread of peste des petits ruminants virus. *Anim Front.* 2014;4:14–20. <http://dx.doi.org/10.2527/af.2014-0003>
 5. Baron MD, Parida S, Oura CA. Peste des petits ruminants: a suitable candidate for eradication? *Vet Rec.* 2011;169:16–21. <http://dx.doi.org/10.1136/vr.d3947>
 6. Banyard AC, Parida S, Batten C, Oura C, Kwiatak O, Libeau G. Global distribution of peste des petits ruminants virus and prospects for improved diagnosis and control. *J Gen Virol.* 2010;91:2885–97. <http://dx.doi.org/10.1099/vir.0.025841-0>
 7. De Nardi M, Lamin Saleh SM, Batten C, Oura C, Di Nardo A, Rossi D. First evidence of peste des petits ruminants (PPR) virus circulation in Algeria (Sahrawi territories): outbreak investigation and virus lineage identification. *Transbound Emerg Dis.* 2012;59:214–22. <http://dx.doi.org/10.1111/j.1865-1682.2011.01260.x>
 8. Kwiatak O, Ali YH, Saeed IK, Khalafalla AI, Mohamed OI, Obeida AA, et al. Asian lineage of peste des petits ruminants virus, Africa. *Emerg Infect Dis.* 2011;17:1223–31. <http://dx.doi.org/10.3201/eid1707.101216>
 9. Wang Z, Bao J, Wu X, Liu Y, Li L, Liu C, et al. Peste des petits ruminants virus in Tibet, China. *Emerg Infect Dis.* 2009;15:299–301. <http://dx.doi.org/10.3201/eid1502.080817>
 10. ProMedMail. Peste des petits ruminants—China (11): Sheep, goat, spread, OIE, request for information. ProMed 2014 May 5. <http://www.promedmail.org.archive.no.20140511.2465094>.

Address for correspondence: Ashley C. Banyard, Wildlife Zoonoses and Vector Borne Disease Research Group, APHA, Weybridge, New Haw, Surrey KT15 3NB, UK; email: ashley.banyard@apha.gsi.gov.uk

**EMERGING
INFECTIOUS DISEASES**
On the web
www.cdc.gov/eid

Possible *Exiguobacterium sibiricum* Skin Infection in Human

To the Editor: The genus *Exiguobacterium* was first described in 1983 by Collins et al., who characterized the species *E. aurantiacum* (1). Since then, 9 new species have been added: *E. acetylicum*, *E. antarcticum*, *E. undae*, *E. oxidotolerans*, *E. aestuarii*, *E. marinum*, *E. mexicanum*, *E. artemiae*, and *E. sibiricum* (2,3). The genus *Exiguobacterium* belongs to the group of coryneform bacteria, which encompasses aerobically growing, non-spore-forming, irregularly shaped, gram-positive rods (2). *Exiguobacterium* spp. have been isolated from a wide range of habitats, including cold and hot environments (3). Although strains of *Exiguobacterium* spp. have been isolated from human clinical specimens (e.g., skin, wounds, and cerebrospinal fluid), the clinical significance of these bacteria is poorly understood (4). We present a case of cutaneous infection possibly caused by *E. sibiricum*.

In January 2014, a previously healthy 66-year-old farmer was admitted to the Health Center of Molina de Aragón (Guadalajara, Spain) with a 7-day history of an ulcer on the dorsal surface of the second finger on his right hand with a painful black eschar surrounded by edema, greenish exudate, erythema, and a broken blister. The lesion had progressively increased in size. The patient was a hunter who had handled the skin of a deer and a wild boar 4 days before. He had no history of trauma or receipt of antimicrobial drugs. At admission, he was afebrile with no systemic symptoms. Cutaneous anthrax was suspected on the basis of the clinical appearance of the lesion and the patient's contact with animals. An exudate sample was obtained for culture, and treatment with oral ciprofloxacin (500 mg/12 hour) was initiated. The Gram-stained sample showed leukocytes

without organisms. Culture was performed according to standard practice.

Colonies observed after 24 hours of incubation on blood agar in pure culture were gray but turned orange after 48 hours. The colonies appeared mucoid and were nonhemolytic. Gram staining revealed wide, short, non-spore-forming, gram-positive rods. The isolate was motile, catalase positive, oxidase negative, and it fermented glucose and lactose. Reactions for indole, urea, and bile esculin were negative. The strain did not grow on McConkey agar and was facultatively anaerobic. The strain was initially identified as *Bacillus* spp. and was sent to the National Reference Laboratory of Majadahonda (Madrid, Spain) for species identification. There, the isolate was identified as *E. sibiricum* by means of 16S rRNA sequence analysis according to a previously reported method (5). The fragment of 16S RNA gene obtained from this isolate was 1,413 bp, and similarity with GenBank sequences was 99.6% (GenBank accession nos. CP00122, GQ869573, and others).

After the organism was identified, we found that it was able to grow on blood agar at 4°C after 6 days of incubation. Antimicrobial drug susceptibility testing was performed by using the Etest method (AB Biodisk, Solna, Sweden) on Mueller-Hinton agar plates incubated at 37°C for 24 hours. The isolate was susceptible to penicillin (MIC 0.023 mg/L), cefotaxime (0.5 mg/L), imipenem (0.047 mg/L), levofloxacin (0.19 mg/L), vancomycin (0.5 mg/L), clindamycin (0.125 mg/L), erythromycin (0.047 mg/L), gentamicin (0.094 mg/L), doxycycline (0.032 mg/L), linezolid (0.5 mg/L), and daptomycin (0.5 mg/L). The patient's clinical outcome was good, and the lesion resolved after 10 days of continuous ciprofloxacin therapy.

This patient's cutaneous infection and the morphologic appearance of the lesion resembled cutaneous anthrax.