

Reconstruction using a pedicled upper arm fillet flap after excision of a malignant peripheral nerve sheath tumor: A case report

Parteek Singla, Swapnil D Kachare, Timothy L Fitzgerald, Richard S Zeri, Enamul Haque

Parteek Singla, Brody School of Medicine, East Carolina University, Greenville, NC 27834, United States

Swapnil D Kachare, Timothy L Fitzgerald, Richard S Zeri, Enamul Haque, Department of Surgery, The Brody School of Medicine, East Carolina University, Greenville, NC 27834, United States

Author contributions: Singla P, Kachare SD, Fitzgerald TL, Zeri RS, Haque E all made equal and substantial contributions to the conception, design, drafting, and revisions of the manuscript.

Correspondence to: Parteek Singla, BS, Medical Student IV, Brody School of Medicine, East Carolina University, 600 Moye Boulevard, Greenville, NC 27834,

United States. singlap07@students.ecu.edu

Telephone: +1-252-5615537 Fax: +1-252-7445777

Received: July 25, 2014 Revised: August 29, 2014

Accepted: October 14, 2014

Published online: December 16, 2014

Key words: Reconstruction; Flaps; Neurofibromatosis; Malignant Peripheral Nerve Sheath Tumor; Sarcoma

Core tip: Here we present a rare case on the use of a pedicled fillet flap of the upper arm for chest wall reconstruction after excision of a malignant peripheral nerve sheath tumor in a patient with neurofibromatosis. This case report describes a reconstructive procedure that is rarely described in the literature as a viable option for soft tissue coverage of shoulder and chest wall defects after an oncologic resection.

Singla P, Kachare SD, Fitzgerald TL, Zeri RS, Haque E. Reconstruction using a pedicled upper arm fillet flap after excision of a malignant peripheral nerve sheath tumor: A case report. *World J Clin Cases* 2014; 2(12): 899-902 Available from: URL: <http://www.wjgnet.com/2307-8960/full/v2/i12/899.htm> DOI: <http://dx.doi.org/10.12998/wjcc.v2.i12.899>

Abstract

Non-salvageable extremities have been utilized for harvesting fillet flaps as part of the "spare parts" concept in traumatic and oncologic settings. Here we report on the use of a pedicled fillet flap of the upper arm for chest wall reconstruction after excision of a malignant peripheral nerve sheath tumor in a patient with neurofibromatosis. Pedicled flaps as part of the "spare parts" concept provide the advantage of reduced donor-site morbidity, immediate closure, intact vasculature, and adequate soft tissue coverage of large defects. Malignant peripheral nerve sheath tumor is a rare aggressive tumor with a poor prognosis that may result in large defects post resection. Limited data describes the use of pedicled fillet flaps of the upper extremity. We report the use of a pedicled fillet flap of the upper arm as a viable option that can be successfully used for coverage of soft tissue defects of the shoulder and chest wall post complex resections in an oncologic setting.

© 2014 Baishideng Publishing Group Inc. All rights reserved.

INTRODUCTION

The use of non-salvageable extremities for harvesting fillet flaps has been utilized for reconstruction as part of the "spare parts" concept in traumatic and oncologic settings. Fillet flaps have been extensively characterized based on their clinical value and can be used as pedicled or free flaps^[1], however there is limited data describing the use of fillet flaps of the upper extremity^[2]. Here we report a rare case of harvesting a pedicled fillet flap of the upper arm for chest wall reconstruction after excision of a malignant peripheral nerve sheath tumor (MPNST) in a patient with neurofibromatosis.

CASE REPORT

A 42-year-old female with a history of neurofibromatosis presented to plastic surgery clinic with complaints

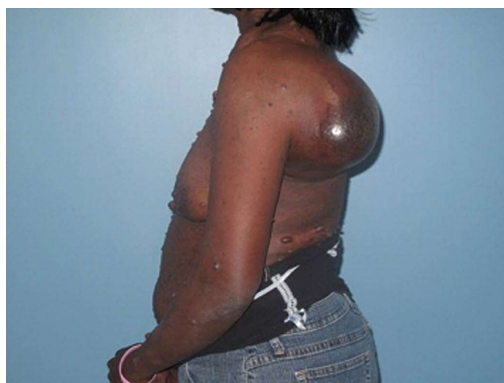


Figure 1 Left shoulder mass at initial presentation.

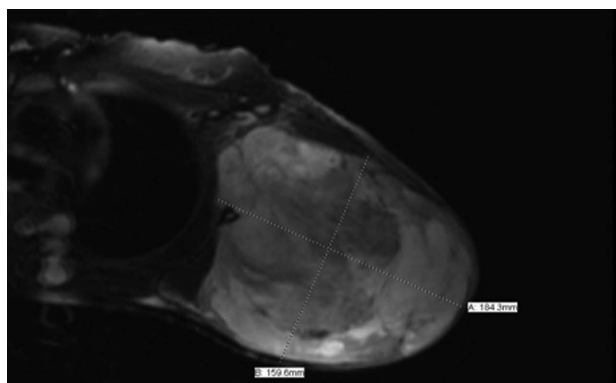


Figure 2 Magnetic resonance imaging of left shoulder, Mass: 18.4 cm × 15.9 cm × 20 cm.

of a left shoulder mass growing for the past two years that caused significant pain with movement (Figure 1). Magnetic resonance imaging (MRI) revealed 18.4 cm × 15.9 cm × 20 cm mass concerning for possible malignant degeneration of a neurofibroma based on size and clinical history (Figure 2). Neoadjuvant chemoradiation per National Comprehensive Cancer Network guidelines for resectable soft tissue sarcomas with potential for adverse functional outcomes^[3] was discussed. Patient was lost to follow up after initial planning and when she returned, she was unable to lay supine secondary to pain from the tumor, which had obvious necrosis with bleeding. Chest computerized tomography (CT) revealed a left large axillary mass with scapular erosion as well as small pulmonary nodules suggestive but not diagnostic of metastatic disease. A decision was made to abandon neoadjuvant therapy and surgically resect the axillary mass followed by adjuvant therapy with close observation of pulmonary lesions.

After the scapula was disarticulated and the tumor excised, it became clear that the arm would be of limited functional use and a modified forequarter amputation with vascular preservation of the upper extremity was performed. A regional flap could not be done due to the wide defect and need for post-operative radiotherapy. Use of a pedicled latissimus dorsi was contraindicated due to tumor invasion, therefore in order to provide immediate closure, without the added time and risk of performing

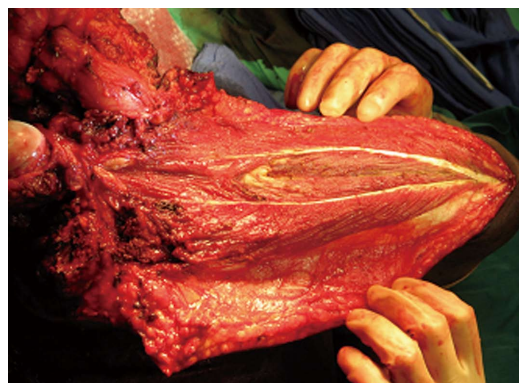


Figure 3 Fillet flap of the upper arm post subperiosteal dissection and removal of the humerus.

a free flap, a musculocutaneous pedicled fillet flap of the left upper arm was chosen for reconstruction.

An incision was made on the posterior aspect of the left upper extremity starting at the shoulder joint and extending below the elbow. Skin and triceps muscles were dissected in the midline and then a subperiosteal dissection was performed (Figure 3). Next, the humerus was removed and the arm transected just below the elbow after identifying and ligating the neural and vascular structures. The flap was rotated into the defect without any tension (Figure 4).

Post-operative pathology report demonstrated a T2bN0 grade 2 or stage II b^[3] MPNST. The tumor was 24 cm × 24 cm × 19 cm in size with focally positive margins. After meeting with radiation and medical oncology, the patient agreed to undergo adjuvant chemoradiation. The patient was initiated on a chemotherapy regimen consisting of doxorubicin and ifosfamide and scheduled for radiation therapy. However, three months after surgery, patient had local recurrence of a mass at her left shoulder. Patient was referred to an outside facility closer to home for adjuvant therapy and this was delayed secondary to patient compliance. CT of the chest and shoulder revealed large recurrent solid and cystic mass in the left shoulder region and left upper anterolateral chest wall. The patient died 5 mo postoperatively from hemorrhagic conversion of metastatic lesions in the brain.

DISCUSSION

The use of fillet flaps from non-salvageable or amputated extremities has been successfully used for reconstruction as part of the “spare parts” concept^[1]. Pedicled musculocutaneous flaps are commonly used for reconstruction; however, the use of a pedicled fillet flap of the upper arm has not been well reported in the literature^[2].

Forequarter amputations may be necessary for locally aggressive bone and soft tissue tumors invading the axilla, shoulder or scapula^[4]. However, multiple variables, such as size and location of the defect, exposure of nerves, tendons, vessels and bones, as well as need for post-operative radiation, must be taken into consideration when deciding on type of reconstruction. Skin grafts do not

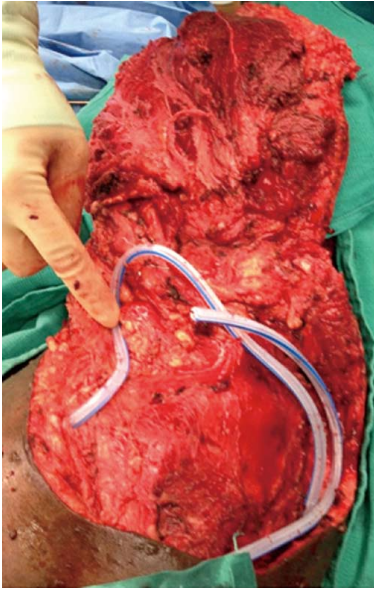


Figure 4 Fillet flap with drains, prior to closure.

provide adequate coverage for large, deep wounds, and are not durable in patients needing post-operative radiation. Therefore, flap coverage with either a pedicled or free flaps are the appropriate choice to provide adequate, immediate coverage post-resection in order to initiate adjuvant radiation therapy^[5]. In patients undergoing an amputation, the use of fillet flaps as part of the “spare parts” concept provides these similar advantages with the added benefit of reduced donor-site morbidity^[1,5].

Previous studies describe the use of free forearm fillet flaps in patients who underwent an upper extremity amputation for cancer, however the use of an upper arm pedicled fillet flap has not been well reported^[2,6]. The use of an upper arm flap may have been contraindicated due to local invasion of the tumor^[2]. However, in our patient, the lack of tumor invasion into the upper arm or into the vascular inflow in the axilla allowed the opportunity to perform a pedicled fillet flap. Not only did the upper extremity flap allow for adequate, tension free coverage, it reduced the risks associated with a free flap. Chao and colleagues demonstrated that patients who received adjuvant radiotherapy after free fillet flaps were significantly more likely to have graft loss as compared to those who received neo-adjuvant radiation^[7]. Since our patient was not appropriate for neo-adjuvant radiation, performing an upper-extremity pedicled fillet flap allowed us to reduce the risk of post-operative wound complications associated with adjuvant radiation therapy. Pedicled latissimus dorsi flaps for reconstruction after forequarter amputations have also been described^[8], but due to tumor invasion in our patient as well as added donor site morbidity, an upper arm fillet flap was decided to be the most appropriate choice for reconstruction.

MPNST is a rare primary chest wall tumor with an incidence of 0.001% in the general population. It commonly presents as an enlarging painful mass and arises from Schwann cells or neural crest cells in a peripheral

nerve or its sheath. Patients with NF-1 are at increased risk of developing MPNST through malignant degeneration of plexiform neurofibromas^[9]. MPNSTs are considered highly malignant, associated with a poor prognosis, have a high risk of local recurrence, and are associated with distant metastasis, most commonly to the lungs^[9,10]. MRI remains the gold standard for diagnosis after which the treatment of choice is surgical resection^[9]. Definite wide excision, negative surgical margins, with neo-adjuvant or adjuvant radiotherapy is currently recommended for treatment of resectable tumors in patients with MPNSTs^[3,9]. Poor prognostic indicators include tumor size greater than 5 cm, local recurrence, high tumor grade, positive surgical margins, association with neurofibromatosis type I (NF-1), and truncal location^[9]. Patients with NF-1 should be educated about the increased risk for developing MPNST and be advised to contact their physician should rapidly enlarging masses, pain, or neurologic changes occur. Given the poor prognosis for MPNST, early initiation of treatment provides the best chance for survival^[9].

Overall, this case represents a rare description of the use of a pedicled musculocutaneous flap from the upper arm for reconstruction after resection of MPNST. Given that MPNST is an aggressive tumor that may present with large defects post resection, the use of a pedicled fillet flap of the upper arm is a viable option that can be successfully used for coverage of soft tissue defects of the shoulder and chest wall^[9]. The advantage of immediate wound closure, avoidance of donor-site morbidity, and reduced operative time over a free flap makes this procedure a reliable method for complex reconstructions in an oncologic setting^[11].

COMMENTS

Case characteristics

A 42-year-old female with a history of neurofibromatosis presented to plastic surgery clinic with complaints of a left shoulder mass growing for the past two years that caused significant pain with movement.

Clinical diagnosis

Patient has a tense, large, protruding mass over her left scapula that is excruciatingly tender with intact flexor and extensor function of the hand and elbow and gross sensation but limited shoulder function secondary to significant pain.

Differential diagnosis

Malignant peripheral nerve sheath tumor, cellular schwannoma, fibrosarcoma, synovial sarcoma.

Laboratory diagnosis

White blood cell: 9.80 k/ μ L; hemoglobin: 9.9 g/dL.

Imaging diagnosis

Magnetic resonance imaging revealed 18.4 cm \times 15.9 cm \times 20 cm mass concerning for possible malignant degeneration of a neurofibroma based on size and clinical history and chest computerized tomography revealed a left large axillary mass with scapular erosion.

Pathological diagnosis

Post-operative pathology report demonstrated a T2bN0 grade 2 or stage IIb malignant peripheral nerve sheath tumor and the tumor was 24 cm \times 24 cm \times 19 cm in size with focally positive margins.

Treatment

Surgical resection of the mass using a pedicled upper arm fillet flap was performed and post operatively, the patient was initiated on a chemotherapy regimen consisting of doxorubicin and ifosfamide and scheduled for radiation

therapy.

Related reports

Pedicled musculocutaneous flaps are commonly used for reconstruction; however, the use of a pedicled fillet flap of the upper arm has not been well reported in the literature.

Term explanation

A pedicled flap contains tissue that remains attached to the original donor site with intact vasculature and is transposed to a new location which is in contrast to a free flap where tissue is detached from its original donor site and transferred to another location.

Experiences and lessons

The advantage of immediate wound closure, avoidance of donor-site morbidity, and reduced operative time over a free flap makes the use of a pedicled fillet flap of the upper arm a viable option that can be successfully used for coverage of soft tissue defects of the shoulder and chest wall for complex reconstructions in an oncologic setting.

Peer review

This case report describes a novel reconstructive procedure that can be used to cover the amputated upper arm with a pedicled fillet flap.

REFERENCES

- 1 **Küntschner MV**, Erdmann D, Homann HH, Steinau HU, Levin SL, Germann G. The concept of fillet flaps: classification, indications, and analysis of their clinical value. *Plast Reconstr Surg* 2001; **108**: 885-896 [PMID: 11547143 DOI: 10.1097/00006534-200109150-00011]
- 2 **Lee G**, Mohan S. Complex reconstruction of a massive shoulder and chest wall defect: de-bone appetit flap. *J Surg Case Rep* 2010; **2010**: 1 [PMID: 24946171]
- 3 **Soft Tissue Sarcoma**. NCCN Clinical Practice Guidelines in Oncology (NCCN Guidelines®). Available from: URL: http://www.nccn.org/professionals/physician_gls/pdf/sarcoma.pdf
- 4 **Kuhn JA**, Wagman LD, Lorant JA, Grannis FW, Dunst M, Dougherty WR, Jacobs DI. Radical forequarter amputation with hemithoracectomy and free extended forearm flap: technical and physiologic considerations. *Ann Surg Oncol* 1994; **1**: 353-359 [PMID: 7850535 DOI: 10.1007/bf02303573]
- 5 **Moreira-Gonzalez A**, Djohan R, Lohman R. Considerations surrounding reconstruction after resection of musculoskeletal sarcomas. *Cleve Clin J Med* 2010; **77** Suppl 1: S18-S22 [PMID: 20179182 DOI: 10.3949/ccjm.77.s1.04]
- 6 **Ver Halen JP**, Yu P, Skoracki RJ, Chang DW. Reconstruction of massive oncologic defects using free fillet flaps. *Plast Reconstr Surg* 2010; **125**: 913-922 [PMID: 20195119 DOI: 10.1097/prs.0b013e3181cb6548]
- 7 **Chao AH**, Chang DW, Shuaib SW, Hanasono MM. The effect of neoadjuvant versus adjuvant irradiation on microvascular free flap reconstruction in sarcoma patients. *Plast Reconstr Surg* 2012; **129**: 675-682 [PMID: 22373973 DOI: 10.1097/prs.0b013e3182412a39]
- 8 **Tukiainen E**. Chest wall reconstruction after oncological resections. *Scand J Surg* 2013; **102**: 9-13 [PMID: 23628630 DOI: 10.1177/145749691310200103]
- 9 **Gupta G**, Mammis A, Maniker A. Malignant peripheral nerve sheath tumors. *Neurosurg Clin N Am* 2008; **19**: 533-543, v [PMID: 19010279 DOI: 10.1016/j.nec.2008.07.004]
- 10 **Hsu CC**, Huang TW, Hsu JY, Shin N, Chang H. Malignant peripheral nerve sheath tumor of the chest wall associated with neurofibromatosis: a case report. *J Thorac Dis* 2013; **5**: E78-E82 [PMID: 23825788]

P- Reviewer: Chen GS, Rapidis AD, Vernimmen FJ
S- Editor: Tian YL **L- Editor:** A **E- Editor:** Wu HL





Published by **Baishideng Publishing Group Inc**

8226 Regency Drive, Pleasanton, CA 94588, USA

Telephone: +1-925-223-8242

Fax: +1-925-223-8243

E-mail: bpgoffice@wjgnet.com

Help Desk: <http://www.wjgnet.com/esps/helpdesk.aspx>

<http://www.wjgnet.com>

