

## CASE REPORT

# Vulval cancer and HPV vaccination in recurrent disease

L. W. Gustafson, Melina Gade<sup>a</sup> & Jan Blaakær<sup>a</sup>

Department of Obstetrics and Gynecology, Aarhus University Hospital, Brendstrupgaardsvej 100, 8200, Aarhus N, Denmark

### Correspondence

Line Winther Gustafson, Department of Obstetrics and Gynecology, Aarhus University Hospital, Brendstrupgaardsvej 100, 8200 Aarhus N, Denmark. Tel: +45 26237874; Fax: 0045 78453392; E-mail: line.winther@skejby.rm.dk

### Funding Information

No funding information provided.

Received: 7 February 2014; Revised: 10 May 2014; Accepted: 20 May 2014

*Clinical Case Reports* 2014; 2(6): 243–246

doi: 10.1002/ccr3.93

<sup>a</sup>The authors contributed equally to the manuscript.

## Introduction

Worldwide 15,000 new cases of vulval and vaginal cancer, respectively, are estimated annually and vulval cancer accounts for ~4% of all gynecological malignancies with a slightly increasing incidence rate [1].

In Denmark 80–100 women are diagnosed with vulval carcinoma every year and the median age is 60 years [2, 3]. At the time of diagnoses about 25% of the women have metastasis to the inguinal nodes and their 5-year survival is ~50% compared to women with no metastasis and a 5-year survival of more than 90% [2, 3].

Human papilloma virus (HPV) is a double stranded DNA virus and it is transmitted by direct contact of the skin and mucous membranes. More than 100 human types of HPV have been identified and ~40 HPV types infect the skin and mucous membranes of the anogenital region. HPV are divided into low- and high-risk types according to their ability to induce premalignant and malignant transformation. Studies have shown that more than 40% of vulval carcinomas are associated with HPV and the association is higher in younger women [4–6]. HPV 16, 18, 31, and 33 constitute the most frequent high-risk viruses associated with vulval carcinoma [6].

### Key Clinical Message

A woman diagnosed with a recurrent vulval carcinoma after initial treatment with radiochemotherapy is presented. After three additional relapses she was vaccinated with Gardasil. She has had no relapses in her vulvar area for 39 months and an overall progression-free survival of almost 24 months.

### Keywords

Human papillomavirus (HPV), therapeutic HPV vaccination, vulvar cancer.

The prophylactic effect of the HPV vaccine is well documented regarding cervical and vulval premalignant lesions (cervical and vulval intraepithelial neoplasia II and III) especially in HPV naïve women [7, 8]. A possible therapeutic effect in established HPV infection is still to be investigated [9].

We present the case of a 67-year-old woman diagnosed with a recurrent vulval carcinoma who after three additional episodes of relapse is offered the Gardasil vaccination. Twenty-two months after removal of a metastatic lymph node no relapse has occurred.

## Case Presentation

In July 2010, a 67-year-old woman with recurrent vulval carcinoma was referred from another Danish gynecologic oncology department. Eleven months earlier she had radical chemoradiotherapy for a vulval T3, N0, M0 tumor with 66 Gy on 33 fractions against the tumor site, 50 Gy to the entire vulva, and 7 series concomitant Cisplatin, 72 mg intravenous. Sentinel node procedure, PET/CT, and magnetic resonance imaging (MRI) were performed and no metastasis was found.

Biopsy prior to chemoradiotherapy showed a squamous cell carcinoma, grade 1. The patient was not primarily

surgically treated because it required a permanent stoma, which the patient did not want.

A gynecological examination in July 2010 demonstrated a 2.5-cm perineal, necrotizing tumor with a depth of 1.2 cm. In cooperation with the plastic surgery ward the woman was treated surgically 3 days later. A resection of the tumor with 2-cm-free margins was done. To obtain wound healing and regain anatomical function a gluteal transposition skin graft and construction of a temporary colostomy were performed. The surgery was the only possible solution as the patient had received the maximum dose of radiation and chemotherapy was evaluated as inferior to surgery.

The pathology revealed a squamous cell carcinoma with an aggressive growth pattern and invasion of the vessels. There were no tumor cells in the resection margins; the lateral resection margin was 8 mm and the deep margin was 12 mm away from the tumor. In the beginning of September 2010 another relapse was verified by biopsy, revealing a squamous cell carcinoma. The relapse was located on the left major labium more than 3 cm away from the previous recurrence. In early September 2010, the relapse was surgically removed and a normal MRI scan without contrast was performed. The pathology revealed a poorly differentiated squamous cell carcinoma with no tumor in the resection margin; the lateral resection margin was 13 mm and the deep margin was 11 mm away from the tumor.

In late October 2010, the colon was reanastomosed. Unfortunately, at the preoperative gynecological examination three suspicious areas were revealed; one in close proximity to the mons pubis and two others almost fused together just laterally to the mons pubis on the left-hand side. The suspected areas were removed and again the pathology revealed a squamous cell carcinoma. The free resection margins varied between 1 and 4 mm to the lateral margin and 5 and 11 mm to the deep margin away from the tumor.

In light of the frequent recurrences the woman was vaccinated against human papilloma virus (Gardasil<sup>®</sup>, MERCK & CO, INC. One Merck Drive, P.O. Box 100, Whitehouse Station, NJ 08889-0100 U.S.A.) from October 2010 and received the third and last injection in April 2011. In July 2011, a MRI scan without contrast was performed. It showed a single enlarged (1.1 cm) lymph node in the lesser pelvis, but otherwise no signs of relapse. Therefore, a new MRI without contrast was performed in late October 2011 in which the lymph node size decreased and appeared fibrotic.

Fifteen months later in January 2012, the patient discovered a tumor in the right groin. A PET-CT scan (Figure 1) confirmed a metastatic lymph node measuring  $0.5 \times 4.0 \times 4.5$  cm. Aside from the metastatic lymph

node the PET-CT showed no other signs of metabolic activity.

In February 2012, the lymph node was removed and the pathology revealed a high-grade squamous cell carcinomas growing through the lymph node capsule.

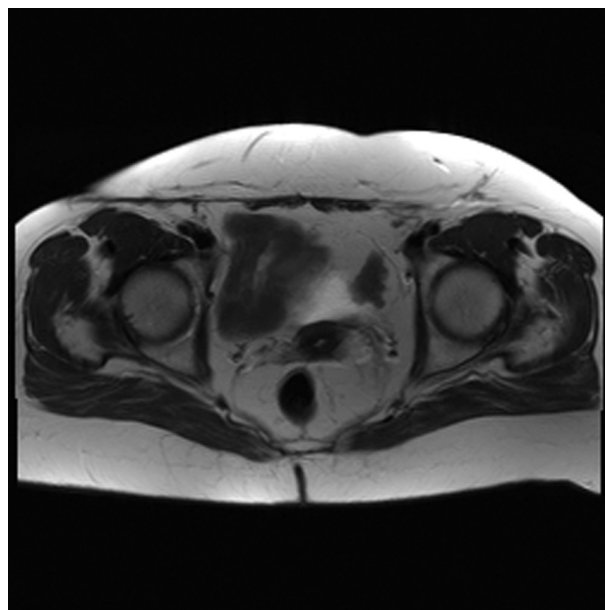
The patient is currently being followed up with MRI scans every 6 months and the last MRI scan (Figure 2) without contrast in November 2013 showed no sign of relapse.

In June 2013, we have tested the patient's biopsy for HPV type, but unfortunately this has not been possible because of insufficient amount of DNA. We have made another attempt to test the HPV type for the patient's cancer, but unfortunately this has not been possible because of poor quality of the DNA taken from the lymph node and from the vulval squamous cell carcinoma.

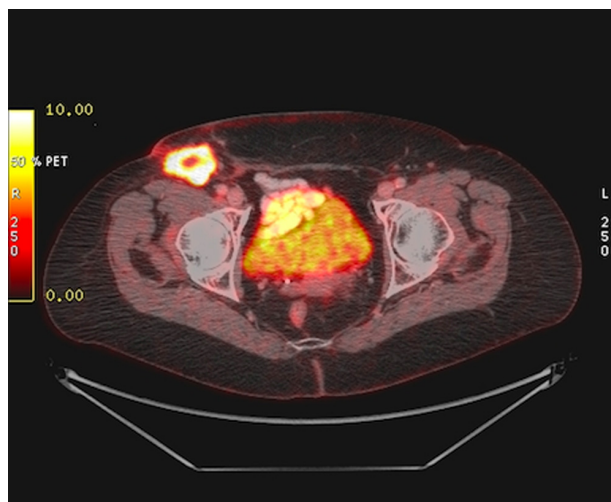
## Discussion

This woman diagnosed with a recurrent vulval carcinoma was treated with a maximum of radiation therapy and several surgical procedures were performed. Advanced vulval cancer is associated with a high mortality and in view of the multiple relapses, vaccination was offered to the patient, as no other treatment options were available. The decision to offer HPV vaccination was nonevidence based.

Previous studies have shown a nearly 100% prophylactic effect of the HPV vaccinations in premalignant lesions, but a therapeutic effect regarding established infections, dysplasia, or cancer is yet to be investigated.



**Figure 1.** MRI scan from 19.11.2013 with no sign of relapse.



**Figure 2.** PET-CT scan from January 2012 with a metastatic lymph node in the right groin, measuring (0.5 × 4.0 × 4.5) cm.

Mudry et al. presented in 2011 a case of a 5-year-old girl treated several times with surgery for laryngeal papillomatosis. After vaccination with Gardasil the patients has had no evidence of papillomatosis for 17 months [10].

Only few other studies have tested the possibility of a cellular immune response when vaccinating against HPV. Kenter et al. vaccinated a group of women with HPV 16, high-grade vulval intraepithelial neoplasia (VIN) with a mix of synthetic long peptides from HPV16 viral oncoproteins E6 and E7 in incomplete Freund's adjuvant. Twelve months after last vaccination, 15 of the 19 patients had a clinical response and 9 of the 19 showed a complete response. This response was maintained after 24 months [11].

Daayana et al. recruited women with VIN to Imiquimod treatment followed by therapeutic HPV vaccination (TA-CIN, fusion protein HPV-16 E6E7L2). After 52 weeks, 12 (63%) of the 19 patients had complete regression of VIN histological [12].

When aging our immune system will become weakened and as a result there is an increased risk of serious infections [13]. Thirty percent of all cervical cancers in Denmark are diagnosed in women aged 60 years or older and one theory that could explain this phenomenon is latency of the HPV infection in the cervical or vulval mucosa. When the immune system is weakened, reactivation of an HPV infection may provoke dysplastic or invasive malignant features. When vaccinated with Gardasil® the humoral immune response starts to create specific antibodies against HPV. The antibody–antigen binding will control and stabilize the cervical or vulval dysplasia or cancer [14, 15].

There may be a possibility that the vaccine has stimulated a T-cell-specific response against HPV, despite that the vaccine only is known to produce serum neutralizing antibodies toward HPV major capsid protein L1. At the moment our patient has had no relapse in her vulval area for 39 months. Taking the metastatic lymph node in consideration, she has now had a progression-free survival of almost 24 months. That is to our best knowledge the longest seen in literature to date.

## Conclusion

Recurrent vulval cancer is associated with high mortality and this case demonstrates that one might consider HPV vaccination when other treatment possibilities have been exhausted.

We advocate for an international randomized controlled study to be performed.

## Acknowledgments

None.

## Conflict of Interest

Line Winther Gustafson and Melina Gade have no relevant financial, personal, political, intellectual, or religious interests. Jan Blaakaer has received lecture fees and advisory board fees from Merck, Sanofi Pasteur MSD, and Glaxo Smith Kline.

## References

1. Arbyn, M., S. de Sanjose, M. Saraiya, M. Sideri, J. Palefsky, C. Lacey, et al. 2012. EUROGIN 2011 roadmap on prevention and treatment of HPV-related disease. *Int. J. Cancer* 131:1969–1982.
2. Podratz, K. C., R. E. Symmonds, and W. F. Taylor. 1982. Carcinoma of the vulva: analysis of treatment failures. *Am. J. Obstet. Gynecol.* 143:340–351.
3. Hacker, N. F., R. S. Leuchter, J. S. Berek, T. W. Castaldo, and L. D. Lagasse. 1981. Radical vulvectomy and bilateral inguinal lymphadenectomy through separate groin incisions. *Obstet. Gynecol.* 58:574–579.
4. De Vuyst, H., G. M. Clifford, M. C. Nascimento, M. M. Madeleine, and S. Franceschi. 2009. Prevalence and type distribution of human papillomavirus in carcinoma and intraepithelial neoplasia of the vulva, vagina and anus: a meta-analysis. *Int. J. Cancer* 124:1626–1636.
5. Monk, B. J., R. A. Burger, F. Lin, G. Parham, S. A. Vasilev, and S. P. Wilczynski. 1995. Prognostic significance of human papillomavirus DNA in vulvar carcinoma. *Obstet. Gynecol.* 85(5 Pt. 1):709–715.

6. Insinga, R. P., K. L. Liaw, L. G. Johnson, and M. M. Madeleine. 2008. A systematic review of the prevalence and attribution of human papillomavirus types among cervical, vaginal, and vulvar precancers and cancers in the United States. *Cancer Epidemiol. Biomarkers Prev.* 17:1611–1622.
7. Castellsague, X., N. Munoz, P. Pitisuttithum, D. Ferris, J. Monsonego, K. Ault, et al. 2011. End-of-study safety, immunogenicity, and efficacy of quadrivalent HPV (types 6, 11, 16, 18) recombinant vaccine in adult women 24–45 years of age. *Br. J. Cancer* 105:28–37.
8. Garland, S. M., M. Hernandez-Avila, C. M. Wheeler, G. Perez, D. M. Harper, S. Leodolter, et al. 2007. Quadrivalent vaccine against human papillomavirus to prevent anogenital diseases. *N. Engl. J. Med.* 356:1928–1943.
9. Brotherton, J. M., M. Fridman, C. L. May, G. Chappell, A. M. Saville, and D. M. Gertig. 2011 Jun 18. Early effect of the HPV vaccination programme on cervical abnormalities in Victoria, Australia: an ecological study. *Lancet* 377:2085–2092.
10. Mudry, P., M. Vavrina, P. Mazanek, M. Machalova, J. Litzman, and J. Sterba. 2011. Recurrent laryngeal papillomatosis: successful treatment with human papillomavirus vaccination. *Arch. Dis. Child* 96:476–477.
11. Kenter, G. G., M. J. Welters, A. R. Valentijn, M. J. Lowik, D. M. Berends-van der Meer, and A. P. Vloon, et al. 2009. Vaccination against HPV-16 oncoproteins for vulvar intraepithelial neoplasia. *N. Engl. J. Med* 361:1838–1847.
12. Daayana, S., E. Elkord, U. Winters, M. Pawlita, R. Roden, P. L. Stern, et al. 2010. Phase II trial of imiquimod and HPV therapeutic vaccination in patients with vulvar intraepithelial neoplasia. *Br. J. Cancer* 102:1129–1136.
13. Effros, R. B., C. V. Fletcher, K. Gebo, J. B. Halter, W. R. Hazzard, F. M. Horne, et al. 2008. Aging and infectious diseases: workshop on HIV infection and aging: what is known and future research directions. *Clin. Infect Dis.* 47:542–553.
14. Stanley, M. 2010. HPV – immune response to infection and vaccination. *Infect. Agent Cancer* 5:19 9378-5-19.
15. Schwarz, T. F., M. Spaczynski, A. Schneider, J. Wysocki, A. Galaj, K. Schulze, et al. 2011. Persistence of immune response to HPV-16/18 AS04-adjuvanted cervical cancer vaccine in women aged 15–55 years. *Hum. Vaccin.* 7: 958–965.