



Contents lists available at ScienceDirect

International Journal of Surgery Case Reports

journal homepage: www.casereports.com

Primary intrahepatic malignant epithelioid mesothelioma



Iraklis Perysinakis^{a,*}, Alexander M. Nixon^a, Ioannis Spyridakis^a, George Kakiopoulos^b, Charalampos Zorzos^b, Ilias Margaritis^a

^a Third Surgical Department, "George Gennimatas" General Hospital of Athens, Mesogeion Ave 154, 156 69 Athens, Greece

^b Pathology Department, "George Gennimatas" General Hospital of Athens, Mesogeion Ave 154, 156 69 Athens, Greece

ARTICLE INFO

Article history:

Received 17 June 2014

Received in revised form 9 November 2014

Accepted 9 November 2014

Available online 13 November 2014

Keywords:

Malignant mesothelioma

Intrahepatic

Epithelioid type

ABSTRACT

INTRODUCTION: Primary malignant hepatic mesotheliomas are extremely rare. We report the case of a patient with primary intrahepatic malignant mesothelioma who was treated in our department.

PRESENTATION OF CASE: A 66-year old male patient was admitted to our department for the evaluation of anemia. An abdominal computed tomography scan revealed a large space occupying lesion in the right liver lobe.

DISCUSSION: The tumor was subsequently resected and a diagnosis of primary intrahepatic malignant mesothelioma was made after pathologic examination. The patient did not receive adjuvant therapy and is currently alive and free of disease, 36 months after the resection.

CONCLUSION: To our knowledge this is the eighth adult case of primary intrahepatic malignant mesothelioma reported in the literature. These tumors are rarely diagnosed preoperatively. Absence of previous asbestos exposure does not exclude malignant mesothelioma from the differential diagnosis. Proper surgical treatment may offer prolonged survival to the patient, without adjuvant therapy.

© 2014 Published by Elsevier Ltd. on behalf of Surgical Associates Ltd. This is an open access article under the CC BY-NC-ND license (<http://creativecommons.org/licenses/by-nc-nd/3.0/>).

1. Introduction

Mesothelioma is an insidious neoplasm arising from the mesothelial surfaces of the pleural and peritoneal cavities, the tunica vaginalis, or the pericardium. Eighty percent of all cases are pleural in origin. The predominant cause of malignant mesothelioma is inhalational exposure to asbestos. The annual incidence of mesothelioma in the United States is estimated to be approximately 3300 cases per year.¹ Primary malignant mesotheliomas arising in the liver are extremely rare. We present the case of a 66-year old male patient with primary intrahepatic malignant mesothelioma who was treated in our department.

2. Presentation of case

A 66-year old male patient was referred to our department in November 2011 with a history of malaise during the previous two months. The patient's medical history was significant only for arterial hypertension, being treated with two antihypertensive drugs. The patient had no history of prior asbestos exposure or chronic liver disease. Previous laboratory examinations had revealed anemia (Hb=8.5 g/dL, Hct%=29.3%) and the

patient had received oral iron supplementation for two months with no improvement. Colonoscopy and gastroscopy had no significant findings, apart from mild gastritis and hemorrhoids.

Upon presentation, physical examination revealed a palpable mass in the right upper abdomen. There were no signs of jaundice or abdominal tenderness. Significant results of laboratory tests on admission were as follows: hemoglobin=7.5 g/dL, hematocrit = 23.8%, INR = 1.4, alkaline phosphatase (ALP)=227 IU/L (normal range 40–150), total proteins=9.1 g/dL (normal range 6.7–8.8), albumin=2.3 g/dL (normal range 3.5–5), C-reactive protein=67 mg/L (normal range <5), carcinoembryonic antigen (CEA)=1.9 µg/L (normal range <5), a-fetoprotein (AFP)=2.4 µg/L (normal range <20), Ca19-9 <2 U/mL (normal range <37), Ca125=259.7 U/mL (normal range <35), Ca15-3=69 U/mL (normal range <30). The rest of the laboratory examinations were within normal range.

The patient underwent computed tomography of the chest and abdomen, which revealed an extensive space occupying lesion in the right liver lobe, measuring 17 cm in diameter. The tumor displayed abnormal enhancement following intravenous administration of contrast material (Figs. 1 and 2). A core needle biopsy which was performed was not helpful as it contained only necrotic material without evidence of malignancy.

On November 7, 2011 the patient underwent exploratory laparotomy which revealed a sizable mass in the right liver lobe without evidence of metastatic disease in the abdomen. A typical right hepatectomy was undertaken. In the first postoperative

* Corresponding author at: Kountouriotou 46, Holargos, 15562 Athens, Greece. Tel.: +30 2117006178; mobile: +30 6973621867.

E-mail address: iraklisper@gmail.com (I. Perysinakis).

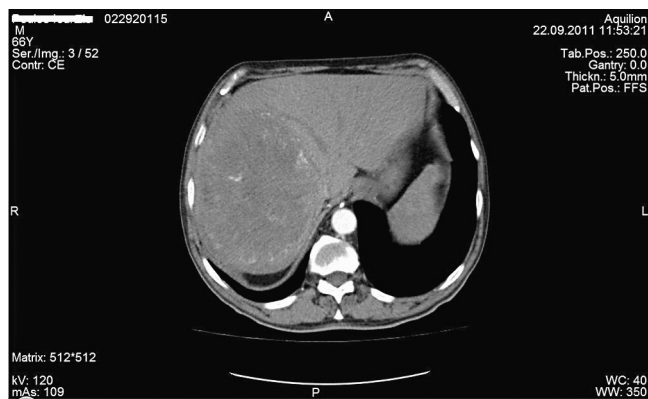

Fig. 1. Computed tomography showing an ill defined, intraparenchymal tumor obliterating most of the right lobe of the liver (transverse section).

day liver function tests revealed a sudden increase in bilirubin and transaminases levels, which was attributed to hemolysis and transient liver failure. Liver function tests returned progressively to normal and the patient was discharged on the seventh postoperative day.

On gross examination the lobectomy specimen was massively infiltrated by a brown, partly hemorrhagic tumor, with soft consistency, measuring 18 × 15.5 × 8 cm, extending to the capsular surface (Fig. 3). Microscopically, the tumor was composed of tubular or cord like arrangements of epithelioid cells with eosinophilic cytoplasm and atypical nuclei (Fig. 4). Immunohistochemically, tumor cells were positive for EMA, CK-7, CK 5/6, Calretinin (Fig. 5), Pankeratin and Vimentin, but negative for CEA (monoclonal), P-63, CD-10, CK-20, Synaptophysin, Chromogranin, CD-56, TTF-1, HepPar-1, HBsAg, CD-15, CD-30, PLAP and β-HCG. Immunohistological analysis of the proliferation marker Ki-67 showed expression in 15–20% of the tumor cells. These findings were consistent with our diagnosis of primary intrahepatic malignant mesothelioma of the epithelioid type. Resection margins were free of disease.

After oncology consultation, the patient did not receive adjuvant chemotherapy postoperatively. He remains alive and free of disease 36 months after the operation.

3. Discussion

Primary intrahepatic malignant mesotheliomas are extremely rare. To our knowledge this is the eighth adult case of primary intrahepatic malignant mesothelioma reported in the literature.^{2–8} There have been reports of mesotheliomas originating in the

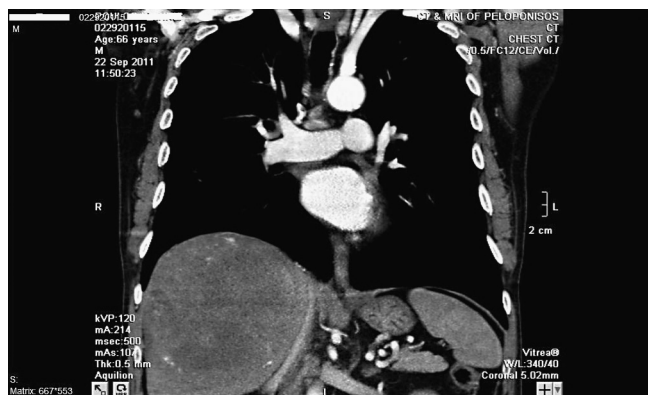


Fig. 2. Computed tomography showing an ill defined, intraparenchymal tumor obliterating most of the right lobe of the liver (coronal section).

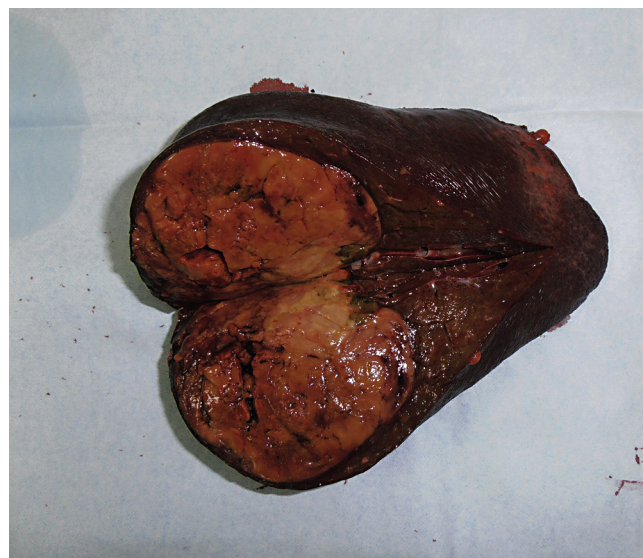


Fig. 3. Macroscopic view of the surgical specimen, showing a large intraparenchymal tumor of the right liver lobe.

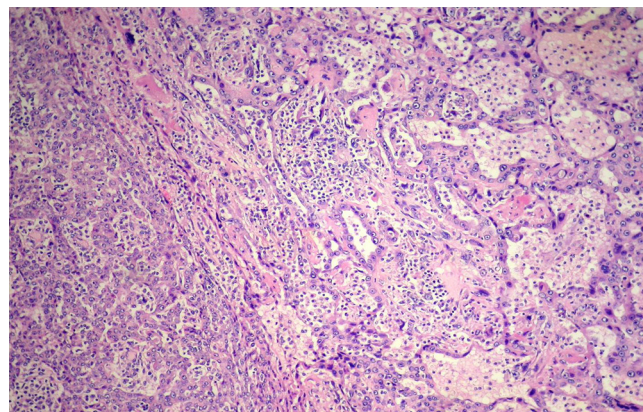


Fig. 4. Irregular cystic and tubular spaces lined by a single layer of mesothelial cells or compact pattern of anastomosing cords of neoplastic cells.

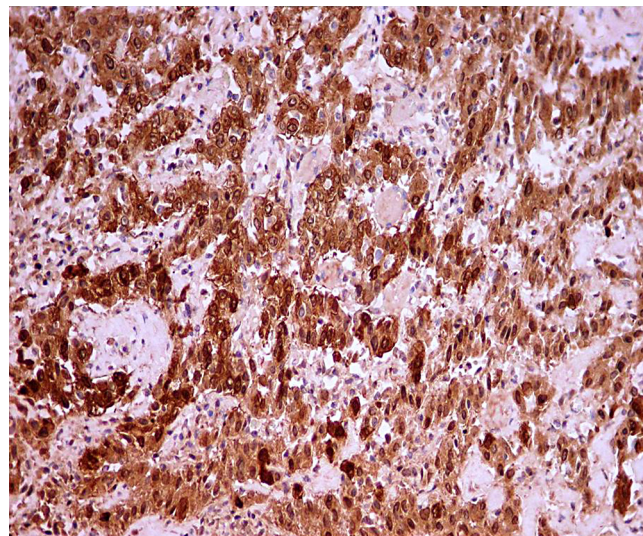


Fig. 5. Antibody against calretinin is the most specific and reproducible positive marker of epithelioid mesothelioma. Cells labeled by the antibody display both a cytoplasmic and a nuclear staining pattern.

Table 1
Primary intrahepatic malignant mesotheliomas reported in the literature.

Author	Year	Sex	Age (years)	Asbestos exposure	Viral hepatitis	Size (cm)	Type	Treatment	Reported survival (months)
Imura et al. ²	2002	Male	64	No	HepC	3.2	Epithelioid	Surgical	40
Leonardou et al. ³	2003	Female	54	Not reported	No	16	Epithelioid	Surgical	2
Gutgemann et al. ⁴	2006	Male	62	No	No	5.8	Epithelioid	Surgical	36
Sasaki et al. ⁵	2009	Male	66	Yes	No	4.4	Biphasic	Surgical	6
Dong et al. ⁶	2013	Female	50	No	No	Not reported	Epithelioid	Surgical	Not reported
Kim et al. ⁸	2008	Male	53	No	No	13.0	Biphasic	Surgical	Not reported
Inagaki et al. ⁷	2013	Female	68	No	No	7.0	Epithelioid	Supportive	Not reported

falciform ligament⁹ or the liver surface,¹⁰ which probably represent peritoneal mesotheliomas involving the liver.

Three different characteristic histological patterns can be discriminated based on routine hematoxylin–eosin staining: epithelioid, sarcomatoid and biphasic. Six cases (including ours) out of eight reported in the literature, were of the epithelioid type, while two were of the biphasic type.

In detail, there were four men and three women, aged between 50 and 68 years old. Five patients had no history of asbestos exposure, one patient had occupational exposure to asbestos and pulmonary asbestosis and in another case there was no indication. One patient without asbestos exposure had chronic hepatitis C. Tumor size ranged between 3.2 and 16 cm. All patients except from one had solitary lesions. Seven patients were surgically treated. In one patient hepatic rupture occurred due to rapid tumor growth with consequent clinical deterioration, thus not allowing surgical resection. Another patient developed subsequent lymph node metastases and was treated with repeated lymphadenectomy, resulting in prolonged survival.^{4,11} No clinical or radiological evidence of recurrent disease has been detected in our patient up to 36 months following resection. Table 1 summarizes the seven cases of primary intrahepatic malignant mesotheliomas reported in the literature.

4. Conclusion

In conclusion malignant mesothelioma of the liver is rarely diagnosed preoperatively, as there are no specific radiologic features for this tumor. Absence of previous asbestos exposure does not exclude malignant mesothelioma from the differential diagnosis. Proper surgical treatment may offer prolonged survival to the patient, without adjuvant therapy.

Conflict of interest statement

I. Perysinakis, A. Nixon, I. Spyridakis, G. Kakiopoulos, C. Zorzos and I. Margaris have no conflicts of interest or financial ties to disclose.

Funding

None.

Ethical approval

Written informed consent was obtained from the patient for publication of this case report and accompanying images. A copy of the written consent is available for review by the Editor-in-Chief of this journal on request.

Author contributions

Study concept: Margaris I; Study design: Perysinakis I, Nixon A; Data collection: Spyridakis I, Kakiopoulos G, Zorzos Ch; Data analysis: Margaris I, Nixon A, Kakiopoulos G; Writing: Perysinakis I, Spyridakis I.

References

1. Teta MJ, Mink PJ, Lau E, Scurman BK, Foster ED. US mesothelioma patterns 1973–2002: indicators of change and insights into background rates. *Eur J Cancer Prev* 2008;**17**:525–34.
2. Imura J, Ichikawa K, Takeda J, Iwasaki Y, Tomita S, Kubota K, et al. Localized malignant mesothelioma of the epithelial type occurring as a primary hepatic neoplasm: a case report with review of the literature. *APMIS* 2002;**110**: 789–94.

3. Leonardou P, Semelka RC, Kanematsu M, Braga L, Woosley JT. Primary malignant mesothelioma of the liver: MR imaging findings. *Magn Reson Imaging* 2003;**21**:1091–3.
4. Gutgemann I, Standop J, Fischer HP. Primary intrahepatic malignant mesothelioma of epithelioid type. *Virchows Arch* 2006;**448**:655–8.
5. Sasaki M, Araki I, Yasui T, Kinoshita M, Itatsu K, Nojima T, et al. Primary localized malignant biphasic mesothelioma of the liver in a patient with asbestosis. *World J Gastroenterol* 2009;**15**:615–21.
6. Dong A, Dong H, Zuo C. Multiple primary hepatic malignant mesotheliomas mimicking cystadenocarcinomas on enhanced CT and FDG PET/CT. *Clin Nucl Med* 2014;**39**:619–22.
7. Inagaki N, Kibata K, Tamaki T, Shimizu T, Nomura S. Primary intrahepatic malignant mesothelioma with multiple lymphadenopathies due to non-tuberculous mycobacteria: a case report and review of the literature. *Oncol Lett* 2013;**6**:676–80.
8. Kim DS, Lee SG, Jun SY, Kim KW, Ha TY, Kim KK. Primary malignant mesothelioma developed in liver. *Hepatogastroenterology* 2008;**55**:1081–4.
9. Marubayashi S, Ohdan H, Asahara T, Ikeda M, Hinoi T, Fukuma K, et al. Malignant mesothelioma originating in the hepatic falciform ligament: report of a case. *Surg Today* 1998;**28**:929–31.
10. Rout P, Rameshkumar K, Srikrishna NV. Hepatic mesothelioma. *Indian J Gastroenterol* 1999;**18**:176–7.
11. Buchholz BM, Gutgemann I, Fischer HP, Gorschluter M, Turler A, Kalf J, et al. Lymph node dissection in primary intrahepatic malignant mesothelioma: case report and implications for diagnosis and therapy. *Langenbecks Arch Surg* 2009;**394**:1123–30.

Open Access

This article is published Open Access at scimedirect.com. It is distributed under the [IJSCR Supplemental terms and conditions](#), which permits unrestricted non commercial use, distribution, and reproduction in any medium, provided the original authors and source are credited.