

Contents lists available at [ScienceDirect](http://www.sciencedirect.com)

International Journal of Surgery Case Reports

journal homepage: www.casereports.com

Ileosigmoid knotting—A disastrous double closed loop obstruction

Manoj Bhambare¹, Sudatta Waghmare¹, Ajeet Tiwari¹, Jayashri Pandya*

Department of General Surgery, Topiwala National Medical College and Bai Yamunabai Laxman Nair Hospital, Mumbai Central, Mumbai 400008, India

ARTICLE INFO

Article history:

Received 12 August 2014

Accepted 22 September 2014

Available online 22 October 2014

Keywords:

Ileosigmoid knotting

Gangrenous bowel

Peritonitis

Ileostomy

Obstruction

ABSTRACT

INTRODUCTION: Ileosigmoid knotting (ISK) is a rare entity which needs prompt recognition and immediate surgical intervention to avoid catastrophic complications caused by gangrenous bowel and subsequent peritonitis. Preoperative investigations are only diagnostic of obstruction and CT findings are helpful but are not always available.

PRESENTATION OF CASE: This case report describes a 22 year old male presenting with acute abdomen managed with emergency exploration in view of findings of peritonitis. Intra-operatively an ileal segment was wrapped around the base of sigmoid colon with gangrenous ileal segment suggesting ISK. Resection of gangrenous ileal segment with double barrel ileostomy was done. Patient tolerated procedure well.

DISCUSSION: Patients with ileosigmoid knotting present with frank obstruction and require immediate medical and surgical treatment. This condition rapidly progresses to gangrenous bowel, generalized peritonitis and sepsis with very high mortality.

CONCLUSION: Early diagnosis, prompt fluid resuscitation, preoperative antibiotics and immediate surgical exploration are keys for optimal management of this condition.

© 2014 The Authors. Published by Elsevier Ltd. on behalf of Surgical Associates Ltd. This is an open access article under the CC BY-NC-ND license (<http://creativecommons.org/licenses/by-nc-nd/3.0/>).

1. Introduction

Ileosigmoid knotting (ISK) is uncommon cause of obstruction when compared to other causes of intestinal obstruction. Here the ileum turns around the base of sigmoid colon and forms a knot. This situation rapidly progresses to gangrenous bowel, generalized peritonitis and sepsis with very high mortality.¹ Preoperative diagnosis is difficult with occasional findings of double closed loop obstruction in plain X-ray radiograph.⁵ CT scan can help in diagnosis but severity of the condition might not always permit to have a preoperative CT scan.²

2. Case report

A 22-year-old male presented with pain in abdomen with distension since 3 days, not passing flatus and stool since 2 days and nausea and vomiting since 1 day. Patient was dehydrated with blood pressure 90 mm Hg systolic, pulse 102/min and CVP 1–2 cm H₂O. Abdomen was distended. Tenderness, guarding and rigidity were present in all four quadrants. Preoperative blood investigations were normal except for total WBC counts (22,500/ μ L) and Serum Creatinine (2.2 mg/dl) which were raised. Abdominal

radiograph showed gas filled bowel loops. No evidence of pneumoperitoneum. Ultrasonography revealed dilated bowel loops with moderate ascites. A provisional diagnosis of obstruction was made and emergency exploration was performed after stabilization. Intraoperative findings included 500 cc of hemorrhagic fluid with long segment of gangrenous ileal loops wrapped anticlockwise around the sigmoid colon which too showed dusky wall due to volvulus. Entire gangrenous small bowel 1 feet from ileocaecal junction was resected (60 cm approximately) and double barrel ileostomy was done with derotation of sigmoid volvulus. Viability of sigmoid colon was confirmed with warm mops and 100% oxygen. Patient tolerated surgery well. Ileostomy became functional on day 4. Patient was started on orals on day 5 and the pelvic drain was removed on day 6. Patient was discharged on day 9 of the surgery after proper dietary advice. Stoma closure was done after 6 weeks. Patient was asymptomatic at last follow up (Figs. 1 and 2).

3. Discussion and conclusion

Ileosigmoid knotting is a double closed loop obstruction rare among whites predominantly found in African, Asians and Middle east nations and commonly affecting men in 4th decade of life.¹ The incidence of this condition is not known.³ The probable etiology being anatomical factors like hypermobile small intestine with elongated mesentery, redundant sigmoid colon with long mesocolon and short attachment at the base of mesentery. Ileosigmoid knotting has been classified into 3 types. In type I, the ileum (active component) wraps itself around the sigmoid colon (passive

* Corresponding author. Tel.: +02223027148.

E-mail addresses: manoj.bhambare@gmail.com (M. Bhambare), sudattaw@gmail.com (S. Waghmare), drajeetramantiwari@gmail.com (A. Tiwari), smruti63@hotmail.com (J. Pandya).

¹ Tel.: +02223027148.

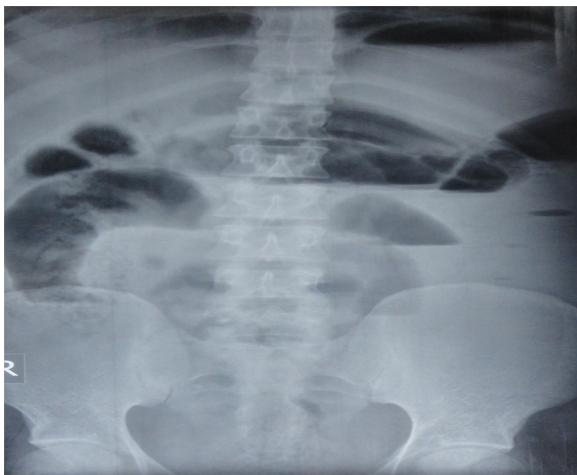


Fig. 1. Multiple air fluid levels with dilated bowel loops.

component) in a clockwise or anticlockwise direction (type A when clockwise and type B when anticlockwise). In type II, the sigmoid colon (active component) wraps itself around a loop of ileum (passive component) in a clockwise or anticlockwise direction. In type III, the ileocaecal segment (active component) wraps itself

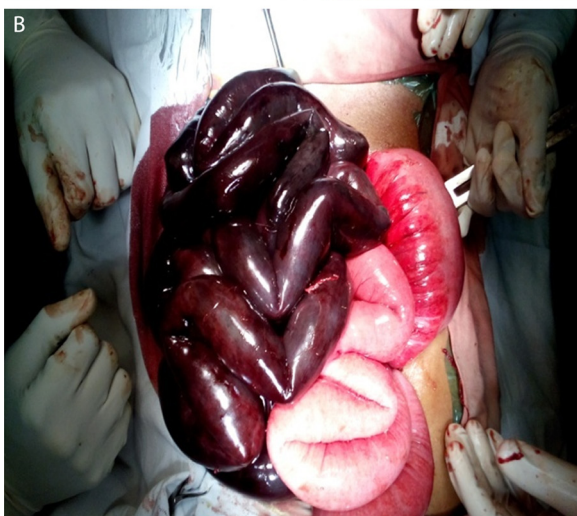
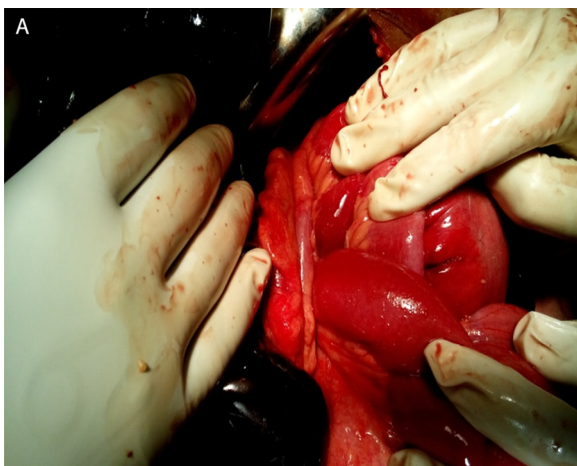
Fig. 2. Intraoperative findings (a) loop of ileum wrapping around dilated sigmoid colon. (b) Gangrenous ileum with dilated sigmoid colon after unwrapping twisted ileum.

around the sigmoid colon (passive component). The most common type of ISK reported is type I (53.9–57.5%), followed by type II (18.9–20.6%), type III (1.5%), and others undetermined.¹ Our case was Type I B. In the new classification, the patients with ISK are classified as follows: Class 1, patients with no risk factor (advanced age, associated disease); Class 2, those with no shock or bowel gangrene but other risk factors mentioned above; Class 3, those with shock; Class 4, those with ileum or sigmoid colon gangrene; Class 5, those with both shock and ileum or sigmoid colon gangrene; Class 6, those with both ileum and sigmoid colon gangrene.⁴ Our case was class 5. X-ray shows characteristic double closed loop obstruction with sigmoid colon on right side and small bowel loops on left side of abdomen but these are occasional findings. CT Scan findings of this condition are (1) whirl sign of volvulus due to twisted loops of intestine and mesocolon. (2) Signs of bowel ischemia. (3) Medial deviation of descending colon with pointed appearance of its medial border, a distinct feature of ileosigmoid knot. (4) Stretched and elongated superior and inferior mesenteric vessels converging toward sigmoid colon indicates diagnosis.^{2,8} Clinically, it is a tricky diagnosis with features of both small and large bowel obstruction. While vomiting suggests a small bowel obstruction the radiographic features of distended large bowel which is not common in small bowel obstruction.^{5–7} A diagnostic triad of clinical features of small bowel obstruction with radiological features of large bowel obstruction and inability to pass a sigmoidoscope might be a useful adjunct in clinching this life threatening condition.⁷ Patients with ileosigmoid knotting present with frank obstruction and require immediate medical and surgical treatment. Early diagnosis, prompt fluid resuscitation, pre-operative antibiotics and immediate surgical exploration are keys for optimal management of this condition. The extent of surgical resection depends upon the clinical stability of the patient intraoperatively with diversion preferable in haemodynamically unstable patients.

Conflict of interest

None.

Funding

No source of funding.

Ethical approval

Informed consent has been taken.

Author contributions

Manoj Bhambare: Assistant surgeon, was responsible for study design, data collection.

Sudatta Waghmare: Assistant surgeon, helped in data analysis.

Ajeet Tiwari: Assistant surgeon, contributed toward data analysis, writing.

Jayashri Pandya: Operating surgeon, revising the article critically for important intellectual content and final approval of the version to be submitted.

References

1. Norman O. Ileosigmoid knot: a case report and literature review of 280 cases. *Ann Saudi Med* 2009;29(September–October (5)):402–6 [PMID: 3290047].
2. Akshay B, Darshana P, Priya H, Donald B. Ileosigmoid knot: a case report. *Indian J Radiol Imaging* 2011;21(April–June (2)):147–9 [PMID: 3137853].
3. Mallick IH, Winslet MC. Ileosigmoid knotting. *Colorectal Dis* 2004;6(July (4)):220–5 [PMID: 15206962].

4. Atamanalp SS, Ozturk G, Aydinli B, Yildirgan MI, Basoglu M, Oren D, et al. A new classification for ileosigmoid knotting. *Turk J Med Sci* 2009;**39**:541–5.
5. Puthu D, Rajan N, Shenoy GM, Pai US. The ileosigmoid knot. *Dis Colon Rectum* 1991;**34**:161–6 [PMID: 1993413].
6. Alver O, Oren D, Tireli M, Kayabasi B, Akdemis D. Ileosigmoid knotting in Turkey: review of 68 cases. *Dis Colon Rectum* 1993;**36**:1139–47 [PMID: 8253011].
7. Raveenthiran V. The ileosigmoid knot: new observation and changing trends. *Dis Colon Rectum* 2001;**44**:1196–200 [PMID: 11535862].
8. Hirano Y, Hara T, Horichi Y, Nozawa H, Nakada K, Oyama AK, et al. Ileosigmoid knot: case report and CT findings. *Abdom Imaging* 2005;**30**:674–6 [PMID: 15834675].

Open Access

This article is published Open Access at scimedirect.com. It is distributed under the [IJSCR Supplemental terms and conditions](#), which permits unrestricted non commercial use, distribution, and reproduction in any medium, provided the original authors and source are credited.