

Simultaneous Prosthetic Mesh Abdominal Wall Reconstruction with Abdominoplasty for Ventral Hernia and Severe Rectus Diastasis Repairs

Jennifer E. Cheesborough,
M.D.
Gregory A. Dumanian, M.D.
Chicago, Ill.

Background: Standard abdominoplasty rectus plication techniques may not suffice for severe cases of rectus diastasis. In the authors' experience, prosthetic mesh facilitates the repair of severe rectus diastasis with or without concomitant ventral hernias.

Methods: A retrospective review of all abdominal wall surgery patients treated in the past 8 years by the senior author (G.A.D.) was performed. Patients with abdominoplasty and either rectus diastasis repair with mesh or a combined ventral hernia repair were analyzed.

Results: Thirty-two patients, 29 women and three men, underwent mesh-reinforced midline repair with horizontal or vertical abdominoplasty. Patient characteristics included the following: mean age, 53 years; mean body mass index, 26 kg/m²; average width of diastasis or hernia, 6.7 cm; and average surgery time, 151 minutes. There were no surgical-site infections and two surgical-site occurrences—two seromas treated with drainage in the office. After an average of 471 days' follow-up, none of the patients had recurrence of a bulge or a hernia.

Conclusions: For patients with significant rectus diastasis, with or without concomitant hernias, the described mesh repair is both safe and durable. Although this operation requires additional dissection and placement of prosthetic mesh in the retrorectus plane, it may be safely combined with standard horizontal or vertical abdominoplasty skin excision techniques to provide an aesthetically pleasing overall result. (*Plast. Reconstr. Surg.* 135: 268, 2015.)

CLINICAL QUESTION/LEVEL OF EVIDENCE: Therapeutic, IV.



The overwhelming majority of abdominoplasties involve suture manipulation of the abdominal wall and resection of skin as described by Pitanguy in 1967.¹ For the abdominal wall, correction of mild to moderate rectus diastasis by means of suture approximation of the anterior rectus sheath gives excellent results. Small umbilical hernias and epigastric defects are often repaired at the time of abdominoplasty through suture plication.

Although there is consensus that hernias are best repaired using mesh as opposed to simple suturing, no such agreement exists for the repair

of severe cases of rectus diastasis. The return of muscle laxity in certain patient populations has been reported as high as 100 percent with use of the plication technique.² Previous authors have recommended mesh overlay to support the midline plication in patients with marked musculoaponeurotic laxity.^{3,4} Some surgeons have recommended posterior rectus sheath plication, rectus advancement, and anterior rectus aponeurosis fixation to the posterior rectus sheath.⁵ General surgeons have recommended a laparoscopic mesh-reinforced technique and consider rectus diastasis a “hernia without a defect” and worthy of hernia repair techniques.⁶ Still others do not believe that rectus diastasis repair will last in the

From Northwestern University, Feinberg School of Medicine.
Received for publication March 27, 2014; accepted June 3, 2014.

Copyright © 2014 by the American Society of Plastic Surgeons

DOI: 10.1097/PRS.0000000000000840

Disclosure: The authors have no financial interest to declare in relation to the content of this article.

setting of large intraabdominal fat volume or male pattern rectus diastasis and therefore recommend against repair.⁷ In *Schwartz's Principles of Surgery*, by Schwartz and Brunickardi, the authors express concern that rectus plication could actually introduce the risk of ventral hernia development.⁸ These concerns have prevented many surgeons from attempting repair of significant diastasis, particularly in men. Regarding the use of mesh, an entire industry of bioprosthetic meshes has developed to avoid feared prosthetic mesh complications of abdominal wall reconstruction. Surgical-site occurrences are quoted in the 14 to 43 percent range for clean or clean-contaminated abdominal wall reconstruction—a number not compatible with aesthetic procedures.⁹

Over the years, we have developed familiarity with the use of prosthetic mesh for the repair of moderate to large ventral hernias. We hypothesized that prosthetic mesh support of severe female and male pattern rectus diastasis, and moderate to large ventral hernias, could be safely and effectively combined with simultaneous abdominoplasty. Although many would view the use of mesh for an aesthetic procedure to be unwarranted, the low complication rate and the reliability of the procedure in 32 patients has led us to document our indications and technique.

PATHOPHYSIOLOGY

Rectus Diastasis

The condition of rectus diastasis is familiar but without standard definition.¹⁰ Rectus diastasis, although not a true hernia, causes biomechanical alterations of the abdominal wall, leading to patient discomfort and an aesthetically displeasing torso. Increased intraabdominal pressure causes tissue expansion of the abdominal wall, particularly at the linea alba. Although certain conditions (such as genetic predisposition, aging, ascites, and chronic obstructive pulmonary disease) increase the risk of developing rectus diastasis, most women develop rectus diastasis after pregnancy, particularly those involving multiple gestations or sequential large infants. Female pattern rectus diastasis is centered at the level of the umbilicus, but can extend up to the xiphoid and down to the symphysis pubis. Male pattern rectus diastasis, in contrast, more frequently develops as a sequela of increased intraabdominal fat volume, occurs primarily supraumbilically, and occurs in the fifth to sixth decades of life (Fig. 1).⁷ In addition, lateral insertion of the rectus muscles along the costal margin can contribute to both

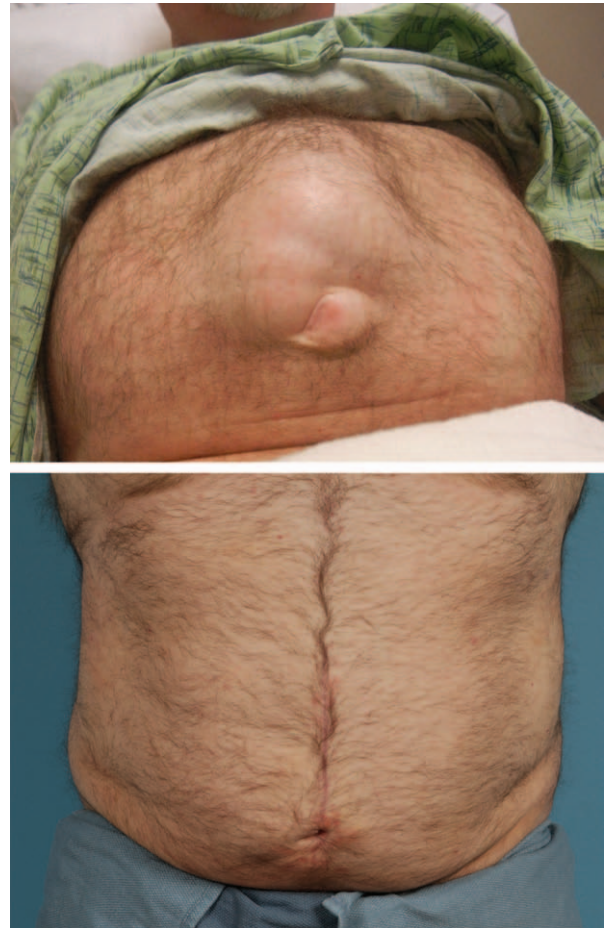

Fig. 1. (Above) The best physical examination for rectus diastasis is a reversed sit-up maneuver. (Below) This male rectus diastasis patient with umbilical hernia underwent a retrorectus mesh repair and skin tailoring through the vertical incision.

development of rectus diastasis and recurrence after plication repair. There is no risk of bowel incarceration with rectus diastasis, because of the smooth contour of the peritoneum.¹¹

Rectus diastasis is associated with epigastric and umbilical hernias. Some authors believe that the male abdominal wall is stiffer, thus contributing to the coexistence of these hernias.¹² Epigastric hernias represent true tears (rather than stretching) of the linea alba fibers, allowing preperitoneal fat and sometimes omentum to emerge. These epigastric hernias can be painful but typically do not contain bowel and are not at risk for bowel strangulation. The physical stretching of the linea alba can be uncomfortable and even painful.

Significant rectus diastasis (and large hernias) causes a decrease in abdominal wall pressure and function. Abdominal wall pressure is necessary for the upper torso to “push-off” and to perform an effective Valsalva maneuver. There is increased

muscle work from the isotonic contracture that occurs at the sarcomere level compared with the isometric contractions that occur with normal abdominal wall muscle activity when muscles tighten rather than shorten with contracture. With the increased abdominal circumference from the stretching of the linea alba, intraabdominal pressure lowers, and a new steady state occurs. Some elastic recoil of the tissues is possible. Exercise and physical therapy may allow a patient to compensate, but the rectus muscles will not reapproximate spontaneously.¹⁰ Because of overuse of the back musculature to compensate for lost abdominal wall stability, low back pain is frequent in cases of significant rectus diastasis. There are few studies that evaluate pain as an outcome, but those that do note overall improvement in pain with rectus diastasis repair.¹³

Ventral Hernia

Lateral displacement of the rectus muscles, decreased intraabdominal pressure, local discomfort, increased muscle work, and back pain all accompany large ventral hernias. A major difference between rectus diastasis and a true hernia is that, for ventral hernias, scar tissue (rather than the linea alba) created at the time of a previous laparotomy incision has pulled apart in the midline. When the scar stretches, the peritoneal surface is no longer smooth and assumes an omega shape, permitting bowel to enter the hernia sac. Therefore, there is a risk of incarceration and strangulation with ventral hernias. Large ventral hernias often coexist with rectus diastasis, occurring after a laparotomy or laparoscopy incision is made through the linea alba in a patient with a prior rectus muscle separation.

PATIENTS AND METHODS

An institutional review board–approved, retrospective chart review of all patients undergoing abdominal wall surgery between 2007 and 2014 performed by the senior author (G.A.D.) revealed 32 patients who underwent abdominoplasty combined with either rectus diastasis repair with mesh or a prosthetic ventral hernia repair. As the majority of ventral hernia repairs will remove some element of skin and subcutaneous tissue, only those patients for whom there was an additional out-of-pocket payment for skin contouring were included. The rectus diastasis repairs were entirely out-of-pocket expenses. These patients were analyzed for patient characteristics, operative features, and postoperative course, including

surgical-site infections and surgical-site occurrences. Follow-up is defined as the last clinic visit or telephone contact. Although these are aesthetic procedures, the lack of any validated aesthetic scoring scales left only the number of revisions as a proxy for patient satisfaction.

Surgical Technique

Rectus Diastasis

Skin is elevated to expose the linea alba and at least 4 cm of the anterior rectus fascia bilaterally. The retrorectus space is developed by incising the anterior rectus fascia along the medial muscle border. The muscle is freed from the underlying posterior rectus sheath with blunt dissection, analogous to a pedicle transverse rectus abdominis myocutaneous flap. The anterior rectus sheath is left attached to the rectus muscle to maintain its vascularity. For the majority of patients, the plane of dissection extends from the xiphoid to the symphysis pubis (Fig. 2, *above, left*, and *above, center*). For men with isolated supraumbilical rectus diastasis, the rectus muscles are elevated to just below the umbilicus (Fig. 3, *above*).

Midweight macroporous polypropylene uncoated mesh, 7 cm in transverse dimension, is anchored with up to 40 interrupted transrectus 0-polypropylene sutures with bites taken 4 cm from the incised edge of anterior rectus fascia. These sutures are each placed approximately 2 to 3 cm apart. The inferior epigastric artery is carefully avoided during suture placement, as are intercostal nerves. When these sutures are tied down, the mesh is flat and tight across the midline. This is a high-tension closure, but the force is distributed across many individual sutures, thus avoiding suture pull-through. The rectus muscles and overlying anterior rectus fascia are then approximated in the midline with interrupted figure-of-eight 0 polypropylene sutures to achieve a direct supported repair (Fig. 2, *above, center* and *right*, and *below, left*).

Ventral Hernia

After exposure of the hernia sac and entry into the abdomen, adhesions of the viscera to the posterior aspect of the sac and the abdominal wall are taken down bluntly. The retrorectus space is entered bilaterally and extended both superiorly and inferiorly. For the majority of the patients, this dissection was from the symphysis pubis to the xiphoid. The posterior sheath is closed in the midline with an absorbable running 0 monofilament suture, recreating the identical appearance of the rectus diastasis patients. Midweight macroporous polypropylene uncoated

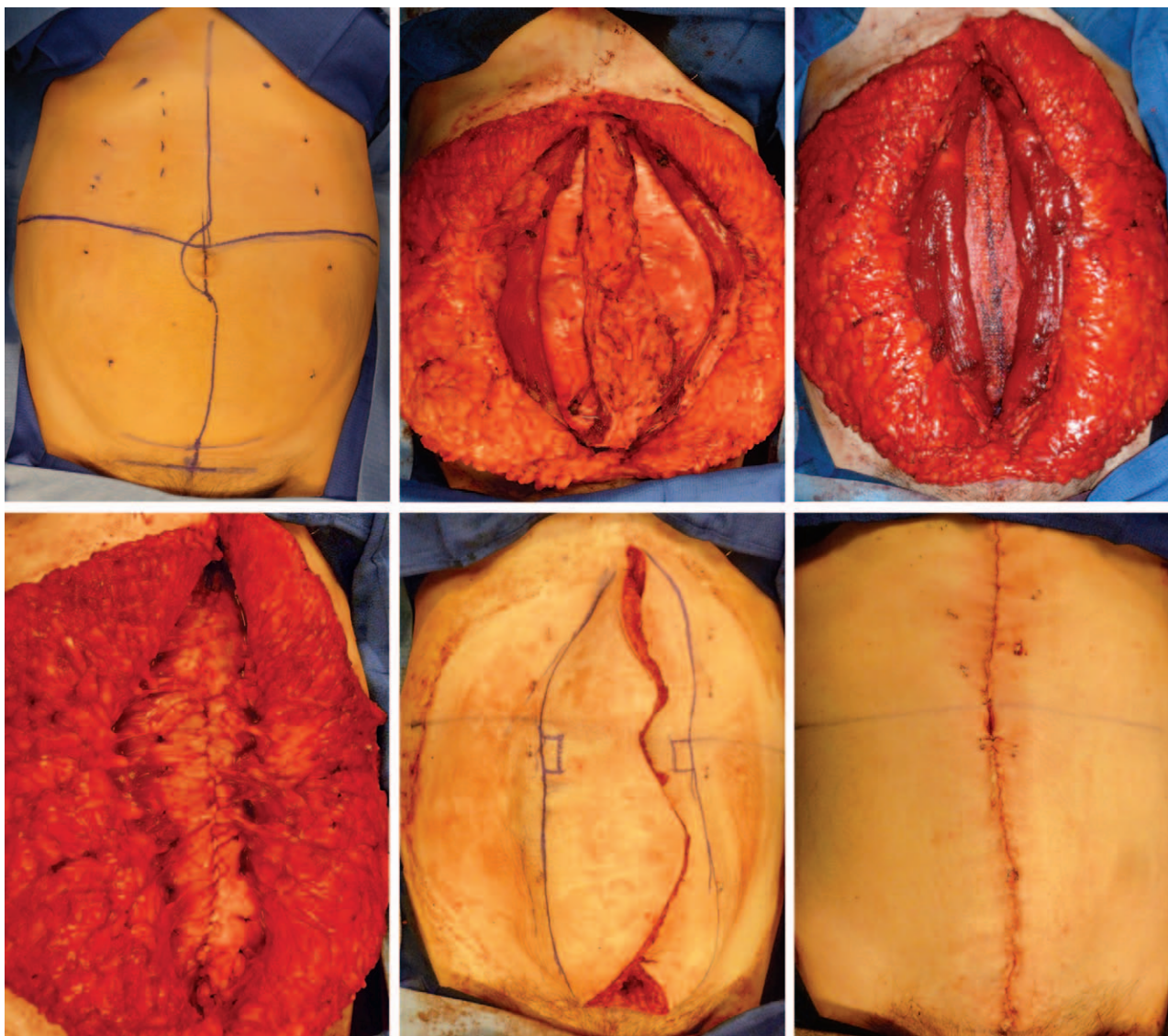


Fig. 2. Female patient with a large rectus diastasis undergoing retrorectus diastasis repair, preservation of skin perforators, and excision of excess skin with vertical abdominoplasty and neoumbilicus formation.

mesh 7-cm in transverse dimension and running the length of the abdominal muscle dissection is placed in the retrorectus plane. The abdominal muscles are closed over the mesh using up to 40 interrupted 0 polypropylene sutures total to achieve a direct supported repair.

Skin Handling

Male pattern rectus diastasis repair is most frequently performed through a vertical incision from xiphoid to umbilicus. Female pattern rectus diastasis repair is more often performed through a standard horizontal abdominoplasty incision. Skin elevation must be wide enough to reach the midportion of the anterior rectus fascia for suture placement and may progress even farther to achieve proper skin redraping

when completed (Fig. 2, *above, right*, and Fig. 3, *below, left*).

Simultaneous ventral hernia repair with abdominoplasty can be performed through either a vertical or a horizontal incision. Many of the hernia patients already have a midline incision. The vertical incisions minimize skin undermining and improve the torso hourglass shape (Fig. 4).

Preoperative markings are crucial for either pattern. Standard low transverse abdominoplasty markings are made for horizontal approaches. For the vertical approach, skin staples are placed equidistant from the midline in the epigastrium, at the level of the umbilicus to facilitate equal skin excision and a centered final closure (Fig. 2, *above, left*). The standard low horizontal incision

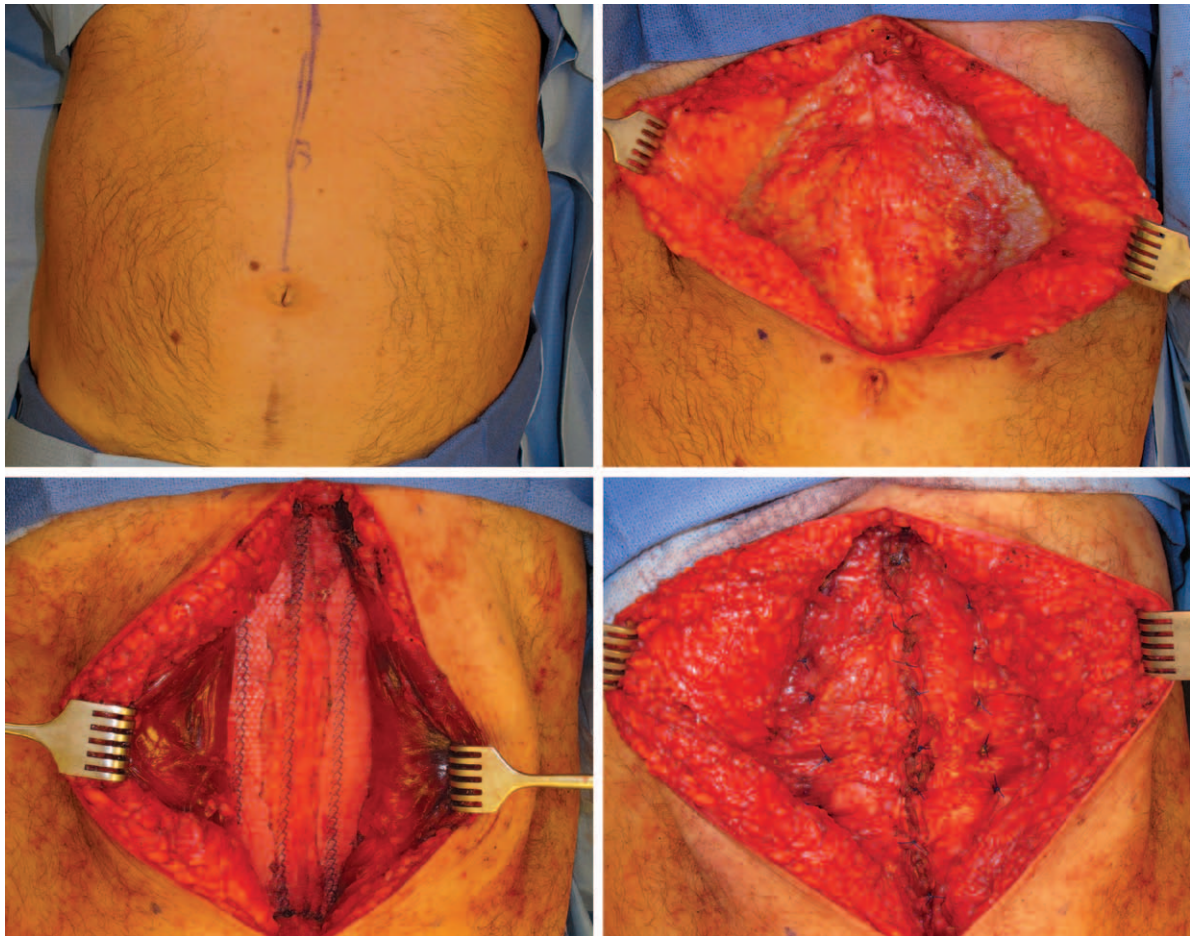


Fig. 3. Male patient undergoing epigastric rectus diastasis repair with retrorectus mesh placement.

is easier to camouflage but comes at the cost of greater skin flap elevation.

Umbilicus Creation

For vertical skin patterns, the umbilicus is excised and reconstructed. Initial marking of the umbilical position in the coronal plane is helpful in orienting these skin flaps. To create a neoumbilicus, “pumpkin teeth” flaps are designed along the medial aspect of the planned skin excision as shown in Figure 2, *below, center*, and tacked down to the abdominal wall.¹⁴ A circular dermal “scratch” is made with the no. 15 blade to create a circular scar. Umbilicus reconstruction may not be wise in hirsute men, as the hair-bearing skin may cause unacceptable hair growth within the umbilicus.

RESULTS

From 2007 through 2014, 32 patients underwent cosmetic abdominal contour procedures combined with either a ventral hernia repair with mesh or a rectus diastasis repair with mesh. Five patients had rectus diastasis alone. The mean age

of the patients was 53 years, with a range of 32 to 73 years of age. Twenty-nine (91 percent) of the patients were female. The mean body mass index of the patients was 26 kg/m² (range, 18 to 34 kg/m²). The most common comorbidity was hypertension ($n = 11$), followed by smoking ($n = 4$) and diabetes ($n = 3$). For the patients with preoperative computed tomographic scans, the greatest separation of the rectus complexes was measured to be a mean of 6.7 cm (range, 3.2 to 9.5 cm).

The average time from entry into the operating room to leaving the room with dressings in place was 151 minutes (range, 80 to 243 minutes). The more complex ventral hernia repairs had longer operative times. The three patients with operative times over 200 minutes had abdominal wall procedures combined with additional mastopexy, bowel resection, or excision of a chronic seroma cavity.

The Ventral Hernia Working Group grade of the patients included in this study ranged from 1 to 3. The majority ($n = 17$) of the patients were grade 1 (low risk), 12 were classified as grade 2

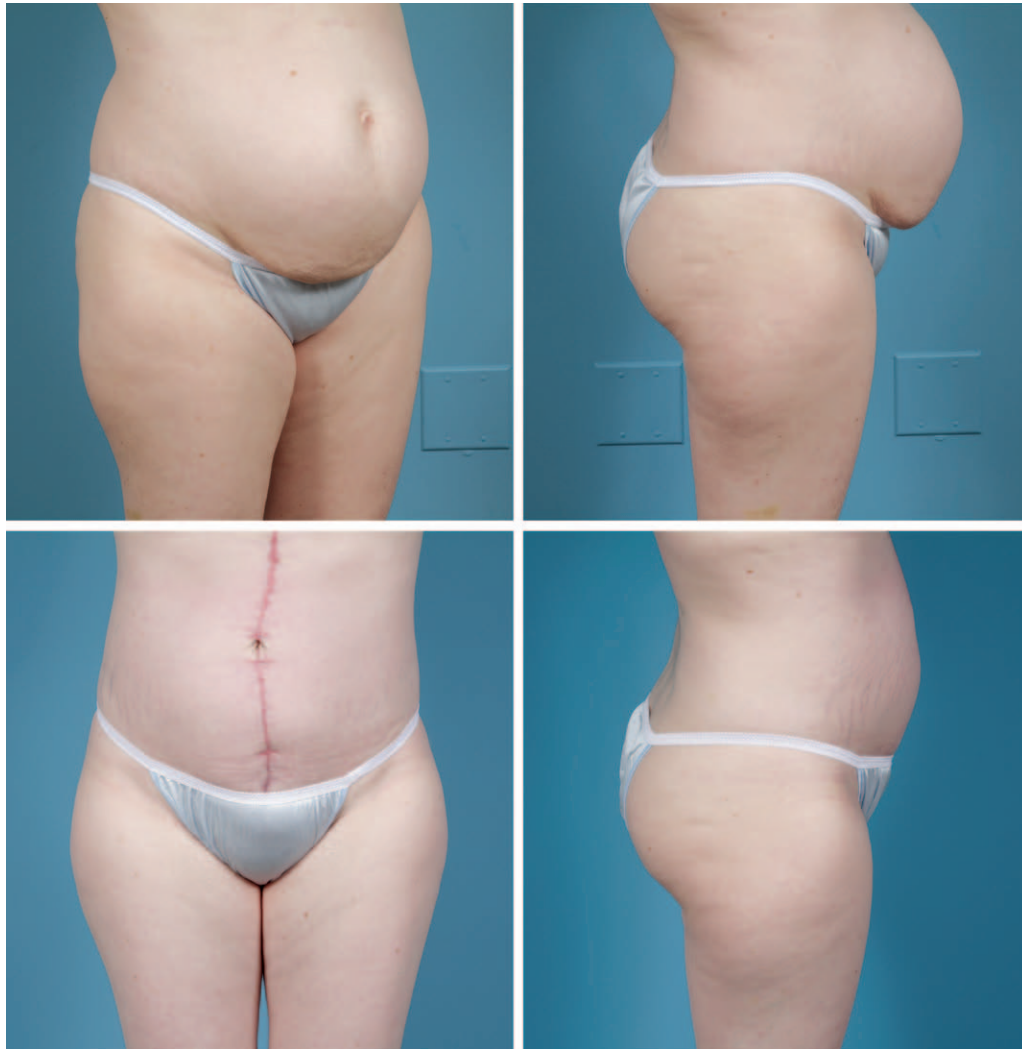

Fig. 4. Female patient with significant rectus diastasis undergoing retrorectus diastasis repair and vertical abdominoplasty with neoumbilicus formation.

because of comorbidities, and 3 were grade 3 because of potentially contaminated fields.

Early Outcomes

During the first 30 days of follow-up, there were no superficial or deep surgical-site infections. The Ventral Hernia Working Group defines surgical-site occurrences for abdominal wall surgery as an infection, a wound dehiscence, a seroma, or the development of an enterocutaneous fistula.¹⁵ Two patients had a surgical-site occurrence—both had prolonged seromas requiring office drainage. One patient had partial skin loss at the inferior aspect of her abdominal skin flap that was successfully treated with local wound care alone (did not meet American College of Surgeons criteria for wound disruption). One patient was readmitted to the hospital 3 days

after discharge for gastrointestinal tract bleeding thought to be related to nonsteroidal antiinflammatory drug use (not requiring transfusion), and another patient with a known patent foramen ovale had a transient ischemic attack during her postoperative course necessitating evaluation by the neurology department.

Late Outcomes

With a mean of 471 days of follow-up (range, 60 to 2292 days), there were no hernia or bulge recurrences. There were no reoperations for abdominal wall complications. Three patients requested touch-up liposuction performed in the office for refining of the abdominal contour. All other patients had uneventful postoperative courses. Results are shown in Figures 1, 4 and 5.

DISCUSSION

There is a need for cosmetically sensitive and lasting abdominal wall reconstruction for patients with both hernias and significant rectus diastases. Even though it is well established that repair of ventral hernias with mesh is more durable than suture repair alone, prosthetic mesh is avoided by many because of concerns regarding risk of infection, extrusion, pain, and the need for removal of the mesh. High rates of surgical-site occurrences would not be compatible with cosmetic surgery procedures. Therefore, a surgical technique that reproducibly allows reestablishment of the linea alba with a low rate of surgical-site occurrences would be an important addition to the care and treatment of patients.

Al-Qattan noted a frustrating 100 percent return of musculoaponeurotic laxity 1 year after vertical midline plication and abdominoplasty in 20 multiparous women with severe abdominal wall laxity. The author questions the durability of plication alone and suggests that a reinforced mesh repair may be more suitable.² In a systematic

literature review, Hickey et al.¹⁶ noted varying evidence for recurrence after plication alone. This ranged from 0 percent in computed tomography follow-up of 12 women in a study by Nahas et al. at an average of 81 months after surgery,¹⁷ to 40 percent in 63 women at an average of 64 months on ultrasound evaluation by van Uchelen et al.¹⁸

The main reason that simple suture approximation of the rectus muscles may not provide a durable repair for both rectus diastasis and hernias is suture pull-through. Both running and interrupted sutures, when placed under tension, can cut through the anterior rectus fascia like a cheese wire cutter, leading to hernia recurrence and “stretching” of rectus diastasis procedures. However, the best aesthetic abdominoplasty procedure is probably the technique that achieves the highest tension. A high-tension tightening of the stomach muscles is achieved with mesh with this technique, rather than sutures alone, as is performed for the standard abdominoplasty. The mesh is quilted into place by numerous sutures placed in three vertically oriented lines. An increased number

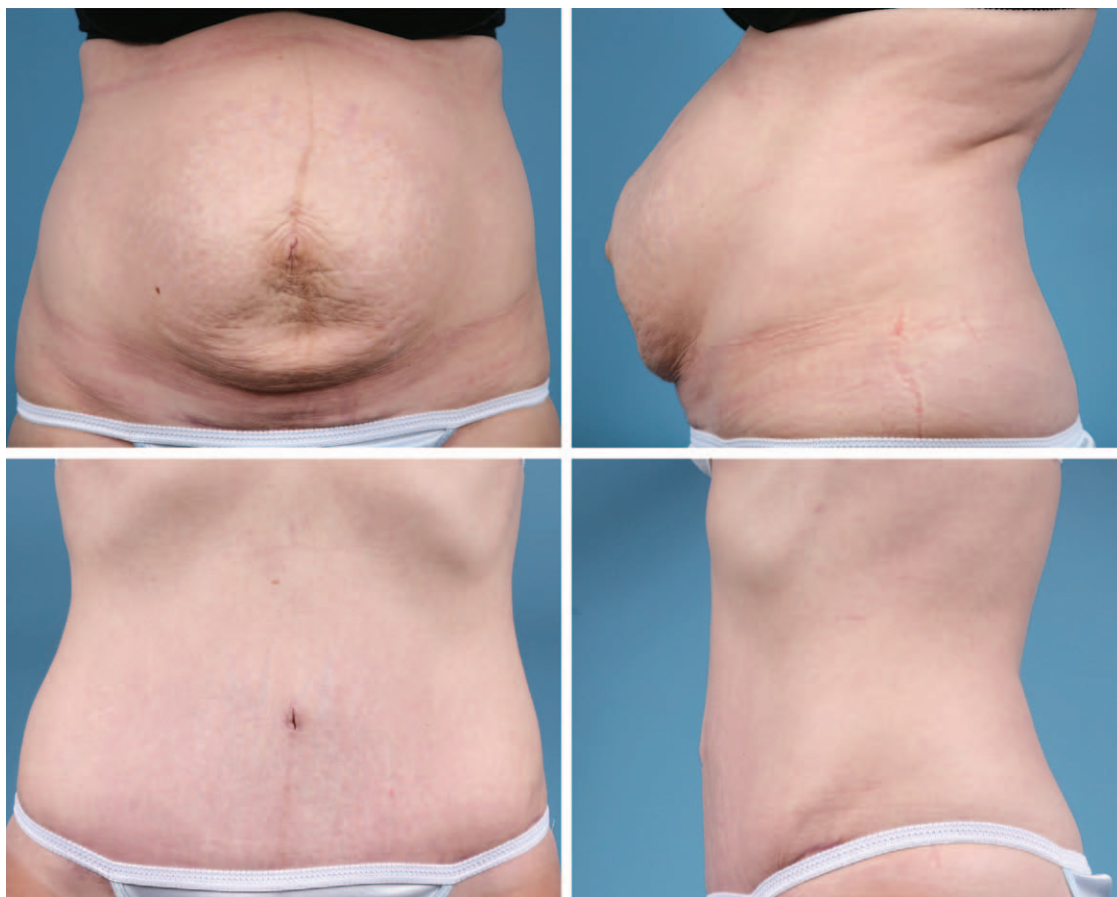

Fig. 5. Female patient with severe rectus diastasis undergoing retrorectus diastasis repair and a standard abdominoplasty incision.

of sutures lowers the force at each suture-tissue interface, thereby decreasing suture pull-through despite the high overall tension of the repair.¹¹ We attribute the low rate of surgical-site occurrence to a central tenet of maxillofacial surgery—that a well-fixed implant in a vascularized soft-tissue bed does not become infected. Macroporous mesh (pore size >1000 μm) incorporates well, improving the distribution of forces across the repair site as scar incorporates the mesh polypropylene fibers. A study of 185 patients by Zemlyak et al. demonstrates the safety of combining abdominal wall mesh repair and skin surgery, as there was no statistically significant differences between panniculectomy alone versus ventral hernia repair with mesh and panniculectomy.¹⁹

A review by Montgomery supports the idea that placement of mesh in the retromuscular plane is the safest position and provides the most durable repairs.⁹ Iqbal et al. reported long-term outcomes for the modified Rives-Stoppa technique for hernia repair, with a relatively low 3 percent prosthetic infection in complex incisional hernias.²⁰ Although the procedure described in our study places the mesh in the same retrorectus plane, current iterations of the retromuscular Rives-Stoppa hernia repair often involve posterior component releases, use large meshes, and develop the retrorectus space from psoas muscle to psoas muscle.²¹ The meshes are typically held in place with several anchoring sutures placed far from the midline. To avoid nerve irritation, some hernia surgeons completely avoid suture fixation of the mesh entirely. The extended Rives-Stoppa technique with extremely large meshes introduces more foreign material, creates more scar, and likely stiffens the abdominal wall more than the limited mesh technique described in this study. The procedure described above uses a narrow mesh as a suture line pledget—distributing the forces to decrease suture pull-through to provide a durable repair. Because they are so close to the midline, the transmuscular sutures are unlikely to entrap a sizeable nerve ending, and therefore long-term postsurgical nerve pain has been extremely uncommon in patients treated with this technique.

The concept of combining abdominoplasty and mesh reinforcement is not new; Marques et al. first described use of a 20 \times 30-cm polypropylene (Marlex; Bard, Covington, Ga.) mesh overlay to support three lines of vertical plication of rectus diastasis in 1995.³ They followed 18 women for 6 or more months and observed no infection, dehiscence, or extrusion related to the mesh. They encouraged use of the mesh overlay in patients

with marked musculoaponeurotic weakness “as though an extensive hernia was being managed.” A decade later, Prado et al. described their experience with three different patterns of polypropylene mesh strip overlay reinforcement of the abdominal wall in 20 women with rectus diastasis with or without midline hernias.⁴ At an average of 36 months’ follow-up, none of the patients had infectious complications or notable recurrence of abdominal bulge.

In a Letter to the Editor, Horndeski and Gonzalez describe a technique of midline hernia repair using the horizontal abdominoplasty skin incision for exposure.²² They then use a large mesh overlay to cover the entire lower half of the anterior abdominal wall to prevent shearing at the midline and prevent further “biomechanical failure.” None of their 14 patients developed a new hernia or infection. All of these three aforementioned studies include use of a mesh overlay, the placement of which, as noted by Marques et al., can obscure normal abdominal muscle contour. The technique described in this study uses a mesh underlay, which allows for the normal muscular contour to be appreciated through the redraped skin flap. In addition, limited undermining preserves both the subtle aesthetics of the semilunar lines and blood flow to the skin flaps.

The cosmetic result is the patient’s greatest concern, and this technique allows for both abdominal wall functional repair and safe skin contouring. The ability of this technique to tighten the abdomen with confidence is far greater than for suture alone. For the 11 patients who already had a vertical scar, the midline incision was used for the procedure. The vertical abdominoplasty allows for excellent narrowing of the waistline and the creation of a new umbilicus as described. The minimal mesh technique preserves the attachments of the semilunar line, improving the final aesthetic contours. For patients without a preexisting vertical scar, the standard horizontal abdominoplasty incision allows for complete access to the hernia or rectus diastasis and excellent postoperative contour.

This study, the largest case series to date of abdominoplasty combined with prosthetic mesh, demonstrates the safety and feasibility of aesthetically sensitive repair of significant rectus diastasis and ventral hernias. This procedure uses familiar techniques combined in a straightforward manner that allows for a durable repair achieved within operative times acceptable to most surgeons. The concept that aesthetics and prosthetic mesh are incompatible is no longer valid, thereby giving

additional options for repair in men and women with separation of their rectus muscles.

Gregory A. Dumanian, M.D.
 Division of Plastic Surgery
 675 North St. Clair, Suite 19-250
 Chicago, Ill. 60610
 gdumania@nmh.org

REFERENCES

- Pitanguy I. Abdominal lipectomy: An approach to it through an analysis of 300 consecutive cases. *Plast Reconstr Surg.* 1967;40:384–391.
- al-Qattan MM. Abdominoplasty in multiparous women with severe musculoaponeurotic laxity. *Br J Plast Surg.* 1997;50:450–455.
- Marques A, Brenda E, Pereira MD, de Castro M, Abramo AC. Plicature of abdominoplasties with Marlex mesh. *Ann Plast Surg.* 1995;34:117–122.
- Prado A, Andrades PR, Benitez S. Abdominoplasty: The use of polypropylene mesh to correct myoaponeurotic-layer deformity. *Aesthetic Plast Surg.* 2004;28:144–147.
- Nahas FX. An aesthetic classification of the abdomen based on the myoaponeurotic layer. *Plast Reconstr Surg.* 2001;108:1787–1795; discussion 1796.
- Palanivelu C, Rangarajan M, Jategaonkar PA, Amar V, Gokul KS, Srikanth B. Laparoscopic repair of diastasis recti using the ‘Venetian blinds’ technique of plication with prosthetic reinforcement: A retrospective study. *Hernia* 2009;13:287–292.
- Brauman D. Reply. *Plast Reconstr Surg.* 2009;124:334–335.
- Seymour NE, Bell RL. Abdominal wall, omentum, mesentery, and retroperitoneum. In: Schwartz SI, Brunnicardi FC, eds. *Schwartz’s Principles of Surgery.* New York: McGraw-Hill; 2010:1267–1283.
- Montgomery A. The battle between biological and synthetic meshes in ventral hernia repair. *Hernia* 2013;17:3–11.
- Akram J, Matzen SH. Rectus abdominis diastasis. *J Plast Surg Hand Surg.* 2014;48:163–169.
- Dumanian GA. Abdominal wall reconstruction. In: Thorne CH, Chung KC, Gosain AK, et al., eds. *Grabb and Smith’s Plastic Surgery.* 7th ed. Philadelphia: Wolters Kluwer; 2014:933–940.
- Nahas FX, Ferreira LM, Mendes Jde A. An efficient way to correct recurrent rectus diastasis. *Aesthetic Plast Surg.* 2004;28:189–196.
- Oneal RM, Mulka JP, Shapiro P, Hing D, Cavaliere C. Wide abdominal rectus plication abdominoplasty for the treatment of chronic intractable low back pain. *Plast Reconstr Surg.* 2011;127:225–231.
- Franco D, Medeiros J, Farias C. Umbilical reconstruction for patients with a midline scar. *Aesthetic Plast Surg.* 2006;30:595–598.
- Breuing K, Butler CE, Ferzoco S, et al. Incisional ventral hernias: Review of the literature and recommendations regarding the grading and technique of repair. *Surgery* 2010;148:544–558.
- Hickey F, Finch JG, Khanna A. A systematic review on the outcomes of correction of diastasis of the recti. *Hernia* 2011;15:607–614.
- Nahas FX, Ferreira LM, Augusto SM, Ghelfond C. Long-term follow-up of correction of rectus diastasis. *Plast Reconstr Surg.* 2005;115:1736–1741.
- van Uchelen JH, Kon M, Werker PM. The long-term durability of plication of the anterior rectus sheath assessed by ultrasonography. *Plast Reconstr Surg.* 2001;107:1578–1584.
- Zemlyak AY, Colavita PD, El Djouzi S, et al. Comparative study of wound complications: Isolated panniculectomy versus panniculectomy combined with ventral hernia repair. *J Surg Res.* 2012;177:387–391.
- Iqbal CW, Pham TH, Joseph A, Mai J, Thompson GB, Sarr MG. Long-term outcome of 254 complex incisional hernia repairs using the modified Rives-Stoppa technique. *World J Surg.* 2007;31:2398–2404.
- Pauli EM, Rosen MJ. Open ventral hernia repair with component separation. *Surg Clin North Am.* 2013;93:1111–1133.
- Horndeski G, Gonzalez E. Abdominoplasty with mesh reinforcement ventral herniorrhaphy. *Plast Reconstr Surg.* 2011;128:101e–102e.