

Received: 2014.07.15  
Accepted: 2014.08.26  
Published: 2014.12.30

## SPICE/K2 Synthetic Marijuana-Induced Toxic Hepatitis Treated with *N*-Acetylcysteine

Authors' Contribution:  
Study Design A  
Data Collection B  
Statistical Analysis C  
Data Interpretation D  
Manuscript Preparation E  
Literature Search F  
Funds Collection G

ABEF 1 **Israr A. Sheikh**  
CE 2 **Miha Lukšič**  
DE 1 **Richard Ferstenberg**  
ADEF 1 **Joan A. Culpepper-Morgan**

1 Division of Gastroenterology, Department of Medicine, Columbia University, Harlem Hospital Center, New York, NY, U.S.A.  
2 Faculty of Chemistry and Chemical Technology, University of Ljubljana, Ljubljana, Slovenia

**Corresponding Author:** Israr Sheikh, e-mail: [is2389@columbia.edu](mailto:is2389@columbia.edu)  
**Conflict of interest:** None declared

**Patient:** **Male, 45**  
**Final Diagnosis:** **Spice/K2 induced liver injury**  
**Symptoms:** **Lethargy • somnolence • fatigue**  
**Medication:** ***N*-acetylcysteine**  
**Clinical Procedure:** —  
**Specialty:** **Gastroenterology**

**Objective:** **Rare disease**

**Background:** Spice/K2 is one of several street names for synthetic marijuana. These hallucinogens are increasingly sold over the internet and in “head” shops. They are usually household herbs that are sprayed with chemicals that become centrally active compounds when burned together and inhaled by smoking.

**Case Report:** We present a case of a 45-year-old male substance abuser who was admitted with evidence of hepatocellular necrosis and worsening liver failure. Tests for acetaminophen were negative, as were tests for alcohol. The patient was empirically treated with *N*-acetylcysteine. Hepatocellular damage was abated and the patient made a full recovery. Upon regaining consciousness, the patient admitted to smoking Spice/K2. Other toxicities have been reported with synthetic marijuana use, but not liver toxicity.

**Conclusions:** Physicians need to have a high index of suspicion for unknown hepatotoxins in substance abusers. *N*-acetylcysteine can be given if there is no contraindication.

**MeSH Keywords:** **Acetylcysteine • Cannabinoids • Drug-Induced Liver Injury • Liver Failure, Acute**

**Full-text PDF:** <http://www.amjcaserep.com/abstract/index/idArt/891399>



1614



1



1



22



## Background

Ethanol and anabolic steroids are the most frequent drugs of abuse that are associated with hepatocellular injury [1]. Patients do not often report use of alternative therapies, supplements, and drugs of abuse to their physicians. Abuse of synthetic khat (bath salts) and synthetic marijuana (Spice/K2) is on the rise [2]. Toxicities reported with these synthetic hallucinogens include chest pain, cardiac arrhythmias, and acute kidney injury. To the best of our knowledge, this is the first case of toxic hepatitis due to use of Spice/K2.

## Case Report

A 45-year-old Hispanic man presented to the emergency room with somnolence, fatigue, and lethargy. The patient was not coherent enough to answer questions at length on the initial encounter. The medical record confirmed his current active medications. There was no history of blood transfusion, recent alcohol abuse, herbal supplementation, or recent travel. His comorbid medical conditions included remote heroin abuse. He was enrolled in a methadone maintenance treatment program. He had received 90 mg of methadone daily for the past 9 years. He also had a diagnosis of bipolar disorder and seizure disorder, both of which were well controlled over the past 2 years with sertraline 100 mg daily, trazodone 50 mg daily, and gabapentin 300 mg 3 times a day. No recent change in medication or drug dosage was noted.

On physical exam, vital signs were stable, with blood pressure 123/71 mmHg, temperature 97.4°F, and oxygen saturation of 100% in ambient air. He was anicteric. There was no jugular venous distention and no axillary or neck lymphadenopathy. He was oriented to his name and place but not to time. He could not cooperate for testing of asterixis. No nuchal rigidity could be elicited. Heart sounds were regular, with good-volume pulses throughout. The chest was clear to auscultation. The abdomen was soft with no organomegaly or abdominal tenderness. Bowel sounds were present. There were no stigmata of chronic liver disease. No peripheral edema was noticed. There were some “track” marks on the upper extremities, suggestive of remote intravenous drug abuse.

Initial laboratory studies revealed hemoglobin and hematocrit of 16 g/dL and 48%, respectively. White blood cell count was 9300 cells/L with 85.1% neutrophils, 8% lymphocytes, 1.4% eosinophils, and 0.2% basophils. The platelet count was 256 000 cells/L. Blood urea nitrogen and creatinine was normal at 10 and 0.6 mg/dL, respectively. There were no electrolyte abnormalities. Transaminases were elevated: AST 793 IU/L (normal <37 IU/L) and ALT 799 IU/L (normal <45 IU/L), and gamma glutamyl trans-peptidase 260 IU/L (normal <200 IU/L). Total bilirubin was

normal at 0.7 mg/dL (normal <1 mg/dL) and direct bilirubin was 0.2 mg/dL (normal <0.5 mg/dL). Alkaline phosphatase was elevated at 260 U/L (normal <136 U/L). INR was 1.0 (normal <1.1). Blood alcohol levels were less than 3 mg/dL (normal <3 mg/dL), acetaminophen level was 0.0 µg/mL, and the ammonia level was 24 µmol/L (normal <32 µmol/L). His urine toxicology was positive only for methadone and negative for all other toxins, including opiates, benzodiazepines, barbiturates, and marijuana. Given his clinical status, he was admitted to the medical ward for further management. All of his current medications were stopped. He was volume expanded with normal saline.

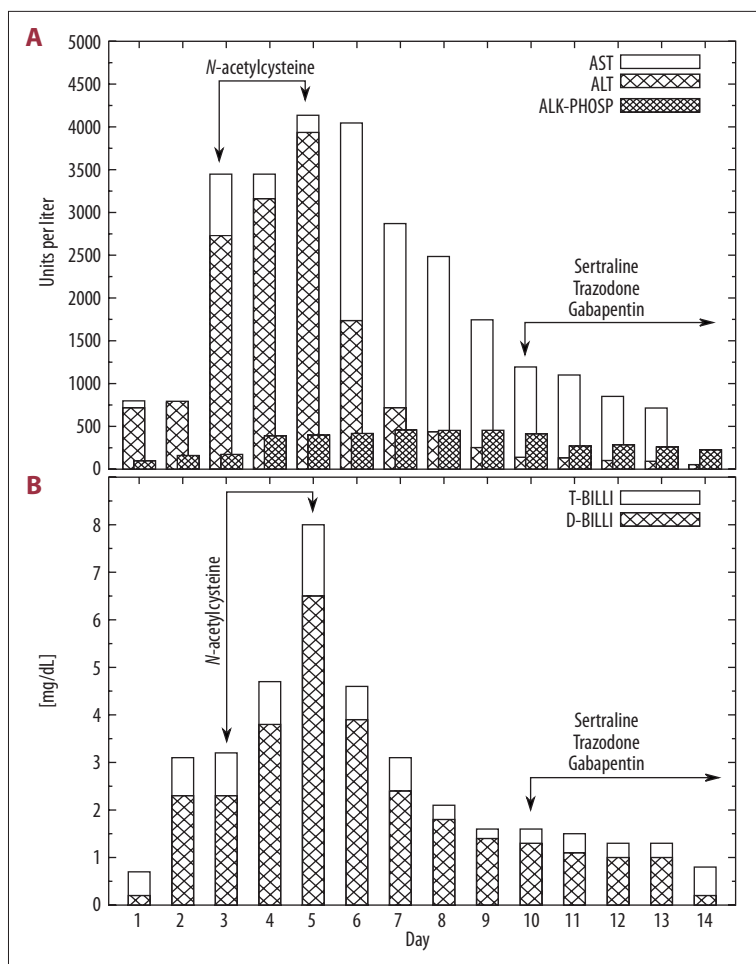
Hepatic profile worsened as hospitalization progressed: AST 3935 IU/L, ALT 4136 IU/L, and alkaline phosphatase 390 U/L, total bilirubin 3.1 mg/dL, and direct 2.3 mg/dL. The INR was 1.3. Viral serologies revealed immunity to hepatitis A virus and hepatitis B virus. Antibody against hepatitis C virus was negative. Further hepatic evaluation for metabolic parameters also did not reveal any pathology. Transferrin saturation was 7%. Alpha-1 antitrypsin levels and ceruloplasmin levels were also within normal limits. Autoimmune parameters, including anti-nuclear antibody, anti-smooth muscle antibody, anti-liver kidney microsomal antibody, and anti-mitochondrial antibody, were all negative. PCR assays for hepatitis B DNA and hepatitis C viral RNA did not detect any virus. Creatine kinase levels were normal at 42 IU/L. Ultrasound of the right upper quadrant did not reveal any pathology. The common bile duct was normal in caliber (4 mm) with no intra- or extra-hepatic biliary duct dilation. No noticeable fluid was seen around the porta hepatis.

Due to concern for worsening liver failure without a clear etiology, intravenous *N*-acetylcysteine was initiated as per 20-h protocol. The patient received an initial loading dose of 150 mg/kg IV over 60 min, followed by a 4-h infusion at 12.5 mg/kg per h, with a 16-h infusion at 6.25 mg/kg per h at the end. Intravenous hydration with normal saline was continued at 100 mL/h. As the patient's hospitalization progressed, bilirubin and transaminase levels began to normalize (Figure 1A, 1B) and his mental status improved. The INR peaked at 1.34 on Day 3 and returned to 0.90 on discharge. Upon awakening, the patient admitted using 2 grams of Spice/K2 regularly for 7 days prior to this presentation.

On hospital Day 10, his regular medications were restarted with no significant change in the hepatic profile (Figure 1A, 1B). The patient was discharged in stable clinical condition. A follow-up telephone call was made and the patient reported no further symptoms and endorsed complete abstinence from Spice/K2.

## Discussion

A search of the medical literature (PubMed from 1966 through 2014) produced no previously reported case of Spice/K2-induced



**Figure 1.** Change in levels of AST, ALT, and alkaline phosphatase (ALK-PHOSP) (A), and total and direct bilirubin (T-BILLI, and D-BILLI, respectively) (B) with time (days). AST and ALT are given in international units (IU) per liter, while ALK-PHOSP is in units (U) per liter. Arrows indicate the administration of selected medications.

hepatotoxicity. Our patient had evidence of hepatocellular toxicity. There were no other identifiable agents that could explain his hepatic injury except Spice/K2 ingestion. There had been no change in the dose or frequency of his regular medications. Extended urine toxicology did not detect any other substance of abuse. Unfortunately, like most conventional laboratories, our hospital did not have any assay that would confirm the ingestion of Spice/K2. Nevertheless, our patient’s admission of its use was accepted as verification. We also assessed the degree of causality using the validated Council for International Organizations of Medical Sciences (CIOMS) scale for causality assessment [3]. In our patient, the time of onset of symptoms from the beginning of drug use was about 1 week (2 points). Clinical chemistries altered to greater than 50% within 8 days (3 points). The patient endorsed alcohol use (1 point). Search for non-drug-related causes of abnormal liver function tests did not reveal a cause (1 point) (Table 1).

Our patient’s ingestion of Spice/K2 suggests its pathogenic role in liver toxicity. Spice/K2 abuse has previously been reported to be associated not only with appetite stimulation, but, paradoxically, also with nausea and vomiting [4–8]. There

are no randomized controlled trials of Spice/K2 and available human information is anecdotal (internet blogs, self-reported stories). Symptoms may occur immediately, minutes, or hours after use. Symptoms may be transient or last for hours. The association of symptoms with Spice/K2 use therefore is easily missed [9,10].

Synthetic cannabinoids, which were introduced in the United States in 2009 to facilitate the study of cannabinoid receptor pharmacology, have recently been implicated as drugs of abuse [11]. These drugs are becoming more popular because they are thought to produce a better “high”, be cheaper than regular marijuana, and lack detectability by routine toxicology screening [12]. NIDA reports that in the United States, Spice/K2 has become the second most frequently used illicit substance after cannabis. The synthetic drug industry that includes Spice/K2 is growing at an estimated \$5 billion a year, according to Rick Broider, president of the North American Herbal Incense Trade Association [13].

“Synthetic marijuana” is an oversimplification for this group of psychoactive designer drugs with the brand names K2 or

**Table 1.** Validating Spice/K2 as probable cause of hepatotoxicity according to the Council for International Organizations of Medical Sciences scale for causality assessment (the CIOMS scale) [3]. The total score in our case is 7, indicating Spice/K2 as 'probable' cause of hepatotoxicity.

Criteria	Hepatocellular injury type	Points
Time of onset to the event	First exposure	
Time from drug intake to reaction onset	7 days	2
Time from drug withdrawal to reaction onset	Not applicable	0
Alcohol risk factor	Applicable	1
Age risk factor (>55 years)	Not applicable	0
Course of reaction	>50% improvement in 8 days	3
Concomitant therapy	Not applicable	0
Exclusion of non-drug related causes	Ruled out group I**,**	1
Previous information on hepatotoxicity	Not applicable	0
Response to re-administration	Not applicable	0
<b>Total score</b>		<b>7</b>

\* Group I Recent viral infection with HAV (IgM anti HAV) or HBV (IgM anti HBV) or HCV (anti HCV/RNA PCR); Biliary obstruction (ultrasonography); Alcoholism (AST/ALT  $\geq 2$ ); \*\* Group II context suggesting CMV, EBV or Herpes virus infection, Acute recent hypotension history (particularly if heart disease).

Spice. These drugs are made by spraying dried natural herbs with 1 or more compounds from several classes of drugs including: cannabinoids, benzoylindoles, naphthoylindoles, phenylacetylindoles, and/or cyclohexylphenoles [14–19]. The chemicals become centrally active compounds when burned together and inhaled by smoking. The composition of Spice/K2 is therefore not unique and depends on the manufacturer. The constituents of Spice/K2 also change with time, mainly because the producers want to be one step ahead of legislation. Unlike (–)-trans- $\Delta^9$ -tetrahydrocannabinol (THC) present in the *Cannabis sativa* plant, the compounds in Spice/K2 act as high-potency full agonists at the brain cannabinoid type 1 receptor (CB<sub>1</sub>) [4,20]. Spice/K2 causes changes in mood, perception, thinking, memory, and attention, as well as changes in neurological, cardiovascular, and gastrointestinal function. These effects are similar to those caused by THC, but they vary in both spectrum and intensity.

On-site laboratory tests for the constituents of Spice/K2 in urine, oral fluid, or serum samples are not available at most institutions. Lack of detectability is one of the reasons why people use Spice/K2 rather than cannabis. The other reason is that it is considered a safe and legal drug that can give its user similar if not stronger satisfaction than natural cannabis.

Management of Spice/K2 ingestion is mainly supportive. The exact mechanism of liver injury is not known. However, the occurrence after several days of use and response to *N*-acetylcysteine suggests a dose-related cumulative oxidative hepatocellular necrosis. The low eosinophil count argues against an immune-mediated idiosyncratic reaction. There may be a risk for long-term hepatic injury with the use of Spice/K2 due to post-necrotic cirrhosis. Our patient was treated with *N*-acetylcysteine because it acts as a hepato-protective agent by restoring hepatic glutathione, serving as a glutathione substitute, and enhancing the nontoxic sulfate conjugation of hepatotoxins. It also has the ability to scavenge oxygen-derived free radicals and improve endothelium-dependent vasodilation, which offers protection from ongoing injury [21,22].

## Conclusions

Healthcare providers should suspect Spice/K2 as a possible cause of unexplained liver injury and failure, especially when caring for individuals with a history of substance abuse. More data is needed to better understand the mechanism of hepatocellular injury, course of action, and best treatment for Spice/K2-induced hepatotoxicity. Empiric use of *N*-acetylcysteine should be considered because it is relatively safe, and, as with our patient, leads to a favorable clinical outcome.

## References:

1. Schwingel PA, Cotrim HP, Salles BR et al: Anabolic-androgenic steroids: a possible new risk factor of toxicant-associated fatty liver disease. *Liver Int*, 2011; 3: 348–53
2. Aoun EG, Christopher PP, Ingraham JW: Emerging drugs of abuse: clinical and legal considerations. *Rh I Med J*, 2014; 96: 41–45
3. Teschke R, Wolff A, Frenzel C et al: Drug and herb induced liver injury: Council for international Organizations of Medical Sciences scale for causality assessment. *World J Hepatol*, 2014; 6: 17–32
4. Marriot KS, Huffman JW: Recent advances in the development of selective ligands for the cannabinoid CB(2) receptor. *Curr Top Med Chem*, 2008; 8: 187–204
5. Canning JC, Ruha A-M, Pierce R et al: Severe GI distress after smoking JWH-018. *Clin Toxicol*, 2010; 48: 618
6. Hermanns-Clausen M, Kneisel S, Szabo B, Auwarter V: Acute toxicity due to the confirmed consumption of synthetic cannabinoids: clinical and laboratory findings. *Addiction*, 2013; 108: 534–44
7. Modern-Famicom. The seller of religions, and hell. 2012. Available from: URL: <http://www.erowid.org/experiences/exp.php?ID=80051>
8. Simmons J, Cookman L, Kang C, Skinner C: Three cases of spice exposure. *Clin Toxicol*, 2011; 49: 431–33
9. Sobolevsky T, Prasolov I, Rodchenkov G: Detection of JWH-018 metabolites in smoking mixture post-administration urine. *Forensic Sci Int*, 2010; 200: 141–47
10. Benford DM, Caplan JP: Psychiatric sequelae of Spice, K2, and synthetic cannabinoid receptor agonists. *Psychosomatics*, 2011; 52: 295
11. Fattore L, Fratta W: Beyond THC: The new generation of cannabinoid designer drugs. *Front Behav Neurosci*, 2011; 5: 60
12. Bebartha VS, Ramirez S, Varney SM: Spice: a new legal herbal mixture abused by young active duty military personnel. *Substance Abuse*, 2012; 33: 191–94
13. Rose J: Fake pot is a real problem for regulators. *National Public Radio News* 2012. Available from: URL: <http://m.npr.org/news/U.S./156615024>
14. Ashton, JC: Synthetic cannabinoids as drugs of abuse. *Curr Drug Abuse Rev*, 2012; 5: 158–68
15. Gunderosn, EW, Haughey HM, Ait-Daoud N, Hart CL: Spice and K2 herbal highs. *Am J Addiction*, 2012; 21: 320–26
16. Seely KA, Lapoint J, Moran JH, Fattore L: Spice drugs are more than harmless herbal blends: a review of pharmacology and toxicology of synthetic cannabinoids. *Prog Neuro-Psychoph*, 2012; 39: 234–43
17. Bhatta S, Wu W: Organic and synthetic cannabinoid use in adolescents. *Pediatr Ann*, 2013; 42: 31–35
18. Psychoyos D, Vinod KY: Marijuana, Spice herbal high and early neural development: implications for rescheduling and legalization. *Drug Test Anal*, 2013; 5: 27–45
19. Spaderna M, Addy PH, D'Souza DC: Spicing things up: synthetic cannabinoids. *Psychopharmacology*, 2013; 228: 525–40
20. Atwood BK, Huffman J, Straiker A, Mackie K: JWH108, a common constituent of Spice herbal blends, is a potent and efficacious cannabinoid CB receptor agonist. *Br J Pharmacol*, 2010; 160: 585–93
21. Srinivasan PK, Yaqi S, Naqai K et al: Impact of oxygen free radicals in rat partial liver transplantation. *J Surg Res*, 2014; 14: 441–47
22. Lee WM, Hynan LS, Rossaro L et al: Intravenous N-acetylcysteine improves transplant-free survival in early stage non-acetaminophen acute liver failure. *Gastroenterology*, 2009; 137: 856–64