

Received: 28th March 2014 Accepted: 9th June 2014 Conflict of Interest: None

Original Research

Source of Support: Nil

In Search of a Better Option: Dexamethasone Versus Methylprednisolone in Third Molar Impaction Surgery

Dattatraya A Darawade¹, Santosh Kumar², Rupal Mehta³, Anant Raghav Sharma⁴, G Sharaschandra Reddy⁵

Contributors:

¹Professor and Head, Department of Oral and Maxillofacial Surgery, Rungta College of Dental Sciences, Bilai, Chattisgarh, India; ²Assistant Professor, Department of Periodontology, Karnavati School of Dentistry, Gandhinagar, Gujarat, India; ³Professor and Head, Department of Periodontology, Karnavati School of Dentistry, Gandhinagar, Gujarat, India; ⁴Senior Lecturer, Department of Periodontology, Pacific Dental College and Hospital, Udaipur, Rajasthan, India; ⁵Reader, Department of Conservative Dentistry and Endodontics, Vydehi Institute of Dental Sciences, Bengaluru, Karnataka, India.

Correspondence:

Dr. Kumar S. Department of Periodontology, Karnavati School of Dentistry, Gandhinagar, Gujarat, India. Email: drsantoshkumar2004@gmail.com

How to cite the article:

Darawade DA, Kumar S, Mehta R, Sharma AR, Reddy GS. In search of a better option: Dexamethasone versus methylprednisolone in third molar impaction surgery. J Int Oral Health 2014;6(6):14-7.

Abstract:

Background: Post-surgical complications like pain, swelling, impaired function cause transient morbidity for the patients leading to refrainment of the treatment. Various preemptive drugs are prescribed to prevent patients from such unpleasant situations. Both dexamethasone and methyl prednisolone can be used for this purpose in surgery of third molar impactions.

Materials and Methods: This was a split-mouth study consisting 25 patients having Pell and Gregory's Class II position B bilateral impactions. About 8 mg dexamethasone and 40 mg methyl prednisolone were prescribed randomly 1 hour prior to the surgery. Pain, swelling and trismus were noted on 1st, 2nd, 3rd and 7th day following surgery. Wilcoxon test was used to assess the significance between the parameters.

Results: Reduction in swelling and trismus was found to be significantly more with dexamethasone than methyl prednisolone. However, no statistical significant difference was found in post-operative pain.

Conclusion: Dexamethasone can be used as a potent preemptive drug for controlling post-operative complications in the removal of third molar impactions.

Key Words: Dexamethasone, Methylprednisolone, Third molar, Trismus

Introduction

Oral invasive procedures like surgical removal of the impacted third molars can give nightmares to the patients. It involves severe laceration and tissue trauma to soft and hard tissues surrounding it.¹⁻³ This causes pain, swelling and limited mouth

opening to the patients. Although inflammatory response is good for healing but an exacerbated response can cause all of the above mentioned complications. To overcome these complications, clinicians mostly prescribe corticosteroids.^{4,5}

In the initial phase of the inflammatory process, corticosteroid acts by suppressing the production of vasoactive substances such as prostaglandins and leukotrienes. This reduces fluid transudation and hence reduces chances of swelling.² These drugs help to control mild pain hence they should be used in conjugation with potent analgesics.¹ Few complications like stomach irritation, indigestion, tachycardia, nausea, insomnia, metallic taste in the mouth are present, but it all depends on the dose and mode of administration of the drug. Prolonged use can delay healing and increase patient's susceptibility to infections. But in dental extraction the doses are for shorter duration, hence chances of adverse effects are very rare. Till date, only one study has been carried out which relates the type, dosage, time and mode of administration of these drugs. further, the use of these drugs in surgical extractions have remained under-investigated. Also, in international research scenario, this topic is very much debated.⁶

The aim of this study was to find out which drug among the two is better for surgical dental extractions.

Materials and Methods

This study was a split-mouth study conducted in the Department of Oral and Maxillofacial Surgery. About 25 patients were selected from the patient pool of the department based on the inclusion and exclusion criterias. The study was approved by the ethical committee of the institution and an informed consent was signed by all the patients. Patients having bilateral mandibular third molars with Pell and Gregory's Class II position B impaction assessed clinically and radiographically were included in the study. Patients on any anti-inflammatory or analgesic drugs 15 days prior to study or having any known allergy to drugs used in the study were excluded from the study. Pregnant and lactating females were also excluded from the study. Both the surgeries were performed with a gap of 3-4 weeks by the same surgeon. The side of surgery and the drug to be prescribed were randomly selected on the day of the first surgery. The drugs either dexamethasone 8 mg or methyl prednisolone 40 mg were administered to the patients orally, 1 h prior to the surgery.

On the day of surgery, extraoral asepsis was performed by 10% povidine iodine. Anesthesia was achieved by administration of 2% lidocaine with 1:100,000 epinephrine.⁷ First incision was placed from distal to mesial on the alveolar ridge till the distolingual region of the second molar. Then intrasulcular incision was placed encircling the second molar till the interdental papilla between the second and first molar region. Following the incisions, a full thickness mucoperiosteal flap was raised. After sectioning the tooth, it was removed and the surgical site was cleaned with copious irrigation of saline. The flaps were sutured with 3-0 silk sutures. The duration of the surgery was measured in minutes from time of incision to suture placement. Postoperatively patients were instructed to keep the surgical site clean and restrict physical exertion. Analgesics were prescribed to the patient immediately after surgery.

After surgery, the intensity of the pain was measured by a 10-point visual analog scale. Pain was assessed at 8 h intervals for the first 3 days of the post-operative period and the number of analgesics consumed in 7 days postoperatively were also noted.

Post-operative swelling was evaluated by the method described by Ustun *et al.*⁸ The assessment of the swelling was carried out before the beginning of the surgical procedure (baseline) and after 1, 2, 3 and 7 days following surgery. Trismus was assessed by measuring the distance between the right upper and lower central incisors with the help of a caliper. The evaluation of trismus was also done preoperatively (baseline) and after 1, 2, 3 and 7 days following surgery. All the measurements were performed by a single trained examiner.

Results

This study was carried out with 25 patients maintaining all the protocols. All the patients were cooperative and reported on all the follow-up visits. There were no cases of any post-operative complication. Wilcoxon test was applied to see the significance of the different parameters.

When duration of surgery and number of analgesics (Group A mean 14 tabs and Group B mean 13.25 tabs) were compared, no significant differences ($P = 0.680$) were found (Table 1). It was noted that maximum swelling resulted at 48 h in both the groups (Group A mean 4.95 and Group B mean 8.66). Statistically significant differences were observed in all phases of swelling (Table 2) between both the groups ($P = 0.023, 0.002, 0.025,$ and 0.19 respectively). Patients were more comfortable with dexamethasone than methylprednisolone. Mouth opening reduction was noted in all groups regardless of the drug used, but reduction was more following surgery in which methylprednisolone was prescribed. Statistically significant differences were found at 24th, 48th and 72nd h ($P = 0.201, 0.031$ and 0.431), whereas on 7th day the mouth opening reduction was nonsignificant ($P = 0.698$) (Table 3).

No statistically significant difference was noted in post-operative pain during the follow-up visits. However, low pain scores were obtained with the use of dexamethasone before surgery (Figure 1).

Discussion

Corticosteroids are very well-known for controlling inflammation, and reducing transudation and edema. Most of the surgeons prescribe corticosteroids to control surgical outcomes and yield a comfortable post-surgical healing period. However, there are no definite protocols related to different molecules or regimes, time and route of administration.⁶ There is limited information on the use of corticosteroids as a single oral pre-surgical dose to reduce pain during third molar extractions. The drug doses used in the present study were based

Table 1: Comparison of number of analgesic consumed and duration of surgical procedure.

	Dexamethasone 8 mg mean	Methylprednisolone 40 mg mean	P value
Analgesic consumption (n)	14	13.25	0.680
Duration of surgery (Min)	30.50	27.25	0.609

Table 2: Comparison of facial swelling on different visits.

Time of visit (H)	Dexamethasone 8 mg mean (SD)	Methylprednisolone 40 mg mean (SD)	P value
24 h	3.64 (3.03)	5.91 (2.43)	0.023
48 h	4.95 (3.63)	8.66 (2.59)	0.002
72 h	3.50 (3.61)	6.74 (3.12)	0.025
168 h	0.27 (0.62)	1.65 (1.92)	0.019

SD: Standard deviation

Table 3: Comparison of reduction in mouth opening during each post-operative visits.

Time of visit (h)	Dexamethasone 8 mg mean (SD)	Methylprednisolone 40 mg mean (SD)	P value
24 h	-12.45 (7.78)	-14.64 (7.30)	0.201
48 h	-12.98 (8.83)	-17.97 (7.09)	0.031
72 h	-12.26 (8.19)	-14.03 (5.64)	0.431
168 h	-4.5 (5.90)	-5.82 (3.88)	0.698

SD: Standard deviation

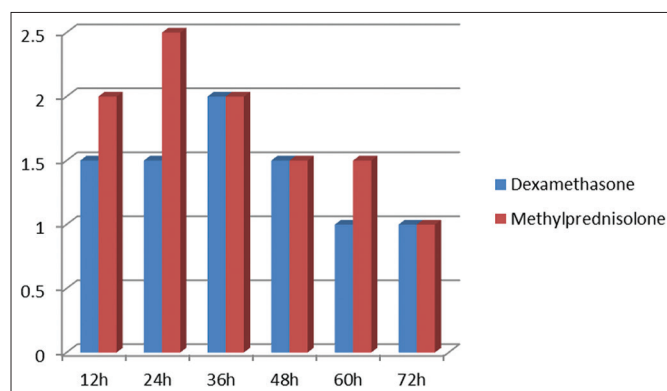


Figure 1: Comparison of pain intensity during post-operative evaluation.

on the previous literature available. The dose of the drug should be more than the cortisol released normally by the body. Due to this reason, in the present study 8 mg⁹ dexamethasone and 40 mg^{8,10} methylprednisolone were used which corresponded to 200 mg of cortisol.

The present study was done as a split-mouth study as it reduces the subject variability and reduces confounders. Furthermore, same position or levels of impacted teeth were selected with the help of a radiograph as it is a good indicator for complications occurring after surgery.¹¹ Thus, Pell and Gregory's classification was used in the study.

Duration of surgery and analgesics consumed by the patients were evaluated and checked for their effect on the parameters taken in the study, but no statistically significant result was found which was in accordance to various other studies.^{8,12,13}

Inability to open the mouth completely is a complication after surgery that hinders patients' activities such as eating, drinking and performing oral hygiene procedures.

Dexamethasone caused less trismus out of the two drugs which was significant on the 2nd day of evaluation. This could be due to the long lasting action of the drug as compared to methyl prednisolone which is intermediate acting drug and has a shorter half-life than dexamethasone.² This result was in accordance to a study done by Vegas-Bustamante *et al*.

Facial swelling is another complication that can occur after surgery. It can be caused by the response of the tissues to manipulation and trauma caused during surgery. Its onset is gradual and maximum swelling is present during 48 h after surgery. In the present study, dexamethasone significantly reduced the incidence of swelling as compared to methyl prednisolone. This is again attributed to the half-life of the drug which is more than methyl prednisolone.^{2,14} The efficacy of dexamethasone is also due to the reason that it reduces the formation of thromboxane A2 which in turn reduces the amount of prostaglandin E2 that is formed.¹³

Graziani *et al*. in his study with 43 patients stated that dexamethasone in conjugation with augmentin 12 hourly for 5 days best controlled the edema and swelling.¹¹

Patients were asked to take acetaminophen 750 mg as a rescue drug in case the pain persisted. A numerical rating scale was used to rate the pain caused to the patients in the early post-operative period. Patients rated less pain in all surgeries where dexamethasone was administered as compared to methyl prednisolone. The production of prostaglandins that influence the peripheral pain response is not controlled,^{13,15} thus emphasizing the result obtained. The effect of corticosteroids is not influenced by the amount of analgesics taken.^{2,8,13}

Conclusion

From the present study, it can be concluded that 8 mg dexamethasone is more efficient in controlling swelling and trismus as compared to 40 mg methyl prednisolone. But both drugs have similar pain controlling ability. Although much attention is given to post-operative medications, radiography, dental morphology and depth of impaction, but age of the patient as well as experience of the surgeon should also be taken into account. Further studies are needed to be undertaken which include all parameters mentioned above to establish this fact.

References

1. Alexander RE, Thronson RR. A review of perioperative corticosteroid use in dentoalveolar surgery. *Oral Surg Oral Med Oral Pathol Oral Radiol Endod* 2000;90(4):406-15.
2. Kim K, Brar P, Jakubowski J, Kaltman S, Lopez E. The use of corticosteroids and nonsteroidal antiinflammatory medication for the management of pain and inflammation after third molar surgery: A review of the literature. *Oral Surg Oral Med Oral Pathol Oral Radiol Endod* 2009;107(5):630-40.
3. Carriches LC, González MJM, Rodríguez DM. The use of methylprednisolone versus diclofenac in the pre-emptive effect of dexamethasone and methylprednisolone in the treatment of inflammation and trismus after surgical removal of lower third molars. *Med Oral Patol Oral Cir Bucal* 2006;11(5):E440-5.
4. Baxendale BR, Vater M, Lavery KM. Dexamethasone reduces pain and swelling following extraction of third molar teeth. *Anaesthesia* 1993;48(11):961-4.
5. Klongnoi B, Kaewpradub P, Boonsiriset K, Wongsirichat N. Effect of single dose preoperative intramuscular dexamethasone injection on lower impacted third molar surgery. *Int J Oral Maxillofac Surg* 2012;41(3):376-9.
6. Sortino F, Cicciù M. Strategies used to inhibit postoperative swelling following removal of impacted lower third molar. *Dent Res J (Isfahan)* 2011;8(4):162-71.
7. Lenka S, Jain N, Mohanty R, Singh DK, Gulati M. Clinical comparison of three techniques of mandibular local anaesthesia. *Adv Hum Biol* 2014;4:13-9.
8. UStün Y, Erdogan O, Esen E, Karsli ED. Comparison of the effects of 2 doses of methylprednisolone on pain, swelling, and trismus after third molar surgery. *Oral Surg Oral Med Oral Pathol Oral Radiol Endod* 2003;96(5):535-9.
9. Laureano Filho JR, Maurette PE, Allais M, Cotinho M, Fernandes C. Clinical comparative study of the effectiveness of two dosages of Dexamethasone to control postoperative swelling, trismus and pain after the surgical extraction of mandibular impacted third molars. *Med Oral Patol Oral Cir Bucal* 2008;13(2):E129-32.
10. Vegas-Bustamante E, Micó-Llorens J, Gargallo-Albiol J, Satorres-Nieto M, Berini-Aytés L, Gay-Escoda C. Efficacy of methylprednisolone injected into the masseter muscle following the surgical extraction of impacted lower third molars. *Int J Oral Maxillofac Surg* 2008;37(3):260-3.
11. Graziani F, D'Aiuto F, Arduino PG, Tonelli M, Gabriele M.

- Perioperative dexamethasone reduces post-surgical sequelae of wisdom tooth removal. A split-mouth randomized double-masked clinical trial. *Int J Oral Maxillofac Surg* 2006;35(3):241-6.
12. Beirne OR, Hollander B. The effect of methylprednisolone on pain, trismus, and swelling after removal of third molars. *Oral Surg Oral Med Oral Pathol* 1986;61(2):134-8.
 13. Dionne RA, Gordon SM, Rowan J, Kent A, Brahim JS. Dexamethasone suppresses peripheral prostanoïd levels without analgesia in a clinical model of acute inflammation. *J Oral Maxillofac Surg* 2003;61(9):997-1003.
 14. Grossi GB, Maiorana C, Garramone RA, Borgonovo A, Beretta M, Farronato D, *et al*. Effect of submucosal injection of dexamethasone on postoperative discomfort after third molar surgery: A prospective study. *J Oral Maxillofac Surg* 2007;65(11):2218-26.
 15. Alcântara CE, Falci SG, Oliveira-Ferreira F, Santos CR, Pinheiro ML. Pre-emptive effect of dexamethasone and methylprednisolone on pain, swelling, and trismus after third molar surgery: A split-mouth randomized triple-blind clinical trial. *Int J Oral Maxillofac Surg* 2014;43(1):93-8.